

# Applicability of Heparin-Bonded Hybrid Vascular Grafts

A case-based review in various vascular settings.

**BY BRANT W. ULLERY, MD; BEN M. JACKSON, MD; JOSEPH BAVARIA, MD;  
AND EDWARD Y. WOO, MD**

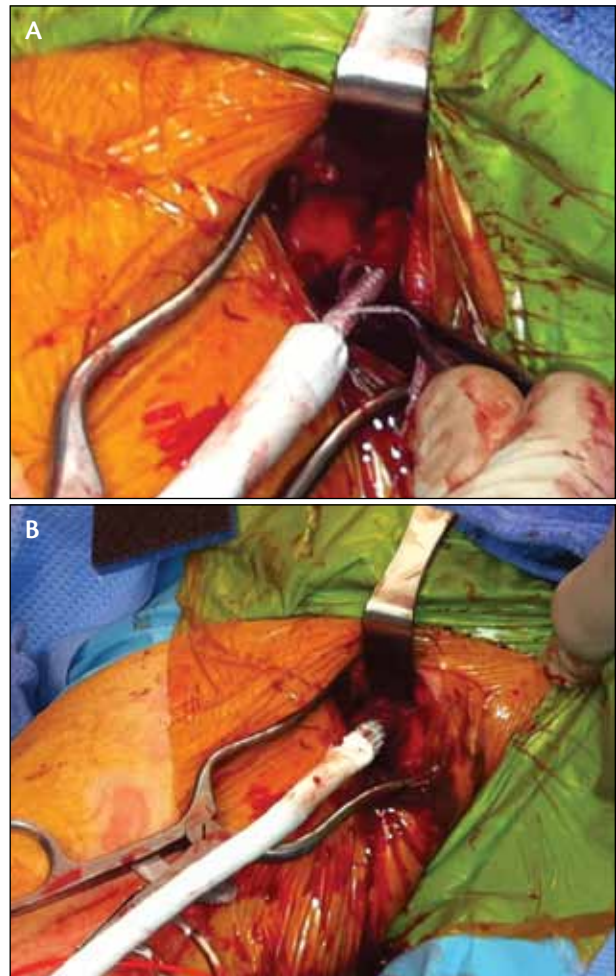
Since receiving US Food and Drug Administration approval in 2010, the Gore Hybrid vascular graft (Gore & Associates, Flagstaff, AZ) has served as a novel tool in the armamentarium of vascular surgeons. Reports to date regarding this device have focused on its applicability in the dialysis access setting.<sup>1</sup> Early experiences with these grafts have demonstrated promising results, and their applicability has since expanded to therapeutic interventions targeting diseases of the aorta and peripheral arteries.

In this article, we describe the versatility of the Gore Hybrid vascular graft to create a sutureless, endoluminal anastomosis in a wide variety of operative settings, including cases involving arteriovenous access, thoracoabdominal aortic aneurysm (TAAA) repair, aortic arch hybrid repair, abdominal aortic aneurysm (AAA) repair, and lower extremity revascularization.

## CASE 1: DIALYSIS ACCESS

A 66-year-old woman with a history of end-stage renal disease secondary to diabetic nephropathy presented to our office following multiple previous failed dialysis access attempts. At the time of consultation, she was receiving hemodialysis via a chest wall tunneled dialysis catheter.

The patient was taken to the operating room for another attempt at dialysis access. A 1-cm longitudinal incision was made in her right axilla. Dissection of the brachial vein was performed. Guidewire access to the vein was achieved after cannulating the vein with a micropuncture needle. The vein was then dilated with a 7-F dilator and then a 12-F dilator. A 9-mm Gore Hybrid vascular graft (usually oversized by 1 to 2 mm) composed of expanded polytetrafluoroethylene (PTFE) with a 9-mm X 5-cm proximal section that is reinforced



**Figure 1.** Dialysis access. The nitinol-reinforced portion of the hybrid vascular graft is advanced approximately 2.5 cm into the brachial vein (A) and is subsequently deployed into the vessel by pulling the deployment line (B).

with a nitinol stent was threaded over the guidewire directly into the vessel. Often, a peel-away sheath can be used to help track the stent directly into the vessel. The stent is typically placed halfway (2.5 cm) in, and tacking sutures are optional in this configuration (end-side), as there is enough resistance so that the stent is not able to be dislodged. Postdeployment angioplasty is not necessary.

The stent component of the graft was then deployed, with adequate apposition of the stent to the walls of the vein (Figure 1). The graft was trimmed to an appropriate length, and the end-to-side arterial anastomosis was performed in routine fashion using a running nonabsorbable suture (Figure 2). A palpable radial pulse and graft thrill were present at the conclusion of the procedure. The graft remains patent at 9-month follow-up.

## CASE 2: TAAA REPAIR

A 46-year-old woman was transferred to our institution with a 6.8-cm extent III TAAA, with occlusion of the celiac artery, high-grade stenosis of the superior mesenteric artery (SMA), and 50% stenosis of the left renal artery. In addition, a 3.6-cm right common iliac artery aneurysm was noted.

The patient underwent an extent III TAAA repair. For the visceral segment, a 6-mm Gore Hybrid vascular graft, due to a small SMA and narrow orifice, was used for individual cannulation of the SMA and renal arteries. The celiac axis was already occluded. After insertion of the stent portion of the hybrid grafts into the native arteries, the proximal PTFE portion of the hybrid grafts was trimmed and sewn directly to the branches of a branched Dacron graft. Each individual branch graft was performed in a sequential fashion to allow for staged reperfusion of the visceral segment. Despite disease within the orifice, we have found that the nitinol stent expands well and has not required postdeployment angioplasty.

Next, the proximal right external iliac artery was cannulated with the stent portion of a 9-mm Gore Hybrid vascular graft, and the PTFE portion of the graft was then anastomosed to the distal end of the Dacron graft. As this was a left retroperitoneal approach, the hybrid graft made anastomosis to the right external iliac artery much easier by circumventing the need to sew an anastomosis deep in the contralateral pelvis in a large patient. The left iliac was reconstructed in a standard manner. Tacking sutures were placed in all hybrid anastomoses, as these were end-end reconstructions. A three-dimensional reconstruction of postoperative computed tomographic angiography is shown in Figure 3. In this case, use of the hybrid graft decreased isch-

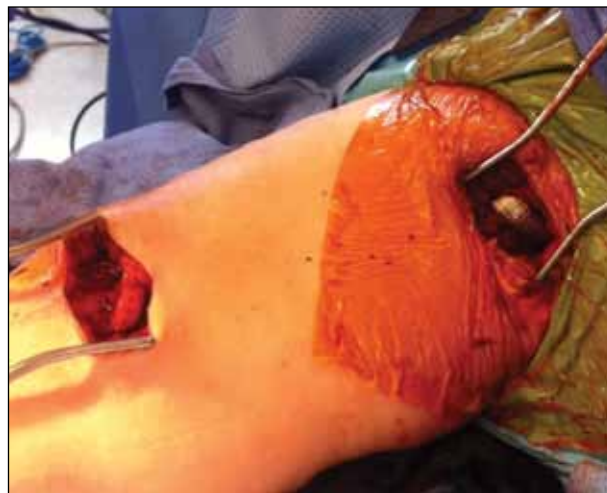

Figure 2. Dialysis access. Completion of the right brachial artery-to-brachial vein vascular access procedure using a hybrid graft.

emic time and also circumvented potentially difficult anastomoses, especially to the right external iliac artery given the left retroperitoneal approach. The visceral vessels remain patent at 6-month follow-up.

## CASE 3: AORTIC ARCH HYBRID REPAIR

A 69-year-old man was evaluated for an 8.1-cm descending thoracic aortic aneurysm and a 5.8-cm ascending aortic aneurysm. An elective three-stage arch hybrid approach was undertaken, involving proximal aortic reconstruction followed by stent grafting of the descending thoracic aorta.

The patient underwent proximal aortic reconstruction with ascending and transverse aortic arch replacement. Standard arch reconstruction was performed. However, the left common carotid artery was difficult to reach due to the aneurysmal aorta and distortion of the normal anatomy. In order to facilitate this anastomosis, the vessel was transected and cannulated with a 9-mm Gore Hybrid vascular graft. The proximal PTFE end of the graft was then trimmed and anastomosed to the left carotid limb of the Dacron graft (Figure 4). The aortic reconstruction remains intact and patent at 6-month follow-up.

## CASE 4: LOWER EXTREMITY REVASCULARIZATION

A 76-year-old man with a history of a 5.5-cm AAA and bilateral peripheral vascular occlusive disease had previously undergone endovascular aortic aneurysm repair and right lower extremity revascularization 6 months earlier. His postoperative course was compli-

cated by a draining left groin seroma that was treated with a muscle flap. The patient subsequently developed a nonhealing wound on his left toe. Subsequent arteriography demonstrated a totally occluded left common femoral and superficial femoral artery down to the level of the knee. There was reconstitution of the left profunda femoris artery just distal to the left femoral artery bifurcation, as well as reconstitution of the popliteal artery below the knee. The patient had a diffusely atherosclerotic left external iliac artery. Given the presence of the muscle flap over the left common femoral artery, the patient underwent left external iliac artery stenting, left iliac-to-left profunda femoris artery bypass, and left profunda femoris to below-knee bypass.

A 9-mm Gore Hybrid vascular graft was used in lieu of a proximal anastomosis to the external iliac artery. This avoided clamping and sewing to the diseased external iliac artery. The distal PTFE portion of the graft was then trimmed and anastomosed to the left profunda femoris in an end-to-side fashion. A 6-mm PTFE heparin-bonded graft was used to create the below-knee bypass. Duplex ultrasound at 6-month follow-up demonstrated continued graft patency. The patient's left toe wounds are healing well, and he is walking without any symptoms of claudication.

### CASE 5: LEFT RENAL LIMB DURING OPEN AAA REPAIR

A 79-year-old woman was seen in consultation for interval growth of a 6.9-cm type IV thoracoabdominal aortic aneurysm. She underwent elective open repair, and a left retroperitoneal approach was used. A 6-mm Gore Hybrid vascular graft was sewn to a prefabricated Dacron tube graft with a 6-mm limb for the left renal artery (Figure 5). Following the proximal anastomosis, which included the celiac, SMA, and right renal arteries, the hybrid stent was inserted and deployed into the left renal artery. Perfusion was immediately reestablished, thus eliminating any extra ischemic time that would be involved in sewing the anastomosis. Tacking sutures were placed from the left renal artery onto the hybrid stent graft. There was a palpable pulse in all of the visceral vessels, including the left renal artery at the conclusion of the operation. The patient is 6 months postprocedure with normal renal function.

### DISCUSSION

The proposed mechanism of vascular graft failure involves a complex pathway of shear wall stress, smooth muscle cell activation and proliferation, neointimal thickening, neointimal hyperplasia, stenosis, and, ultimately, thrombosis.<sup>2</sup> A leading hypothesis

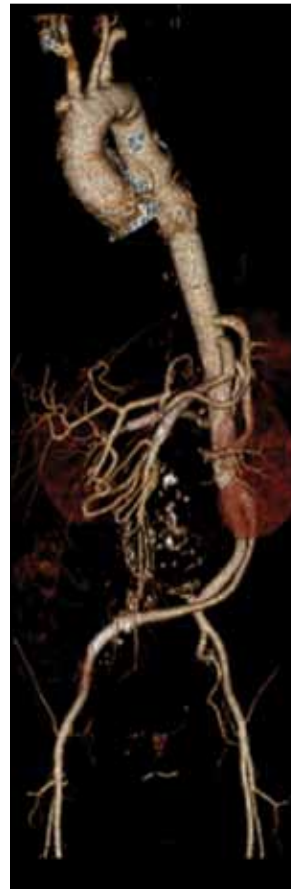

Figure 3. Extent III TAAA repair. Hybrid grafts were placed in the SMA, bilateral renal arteries, and right external iliac artery.

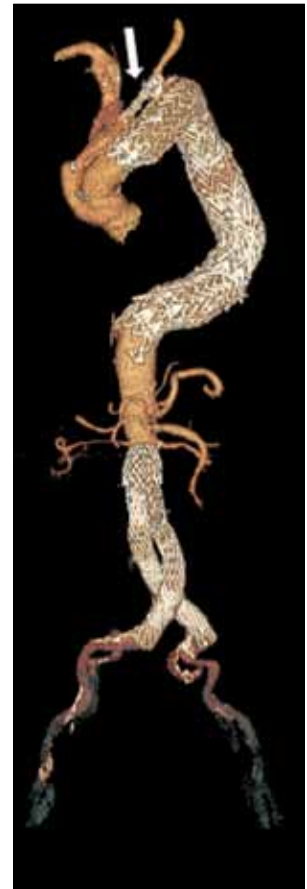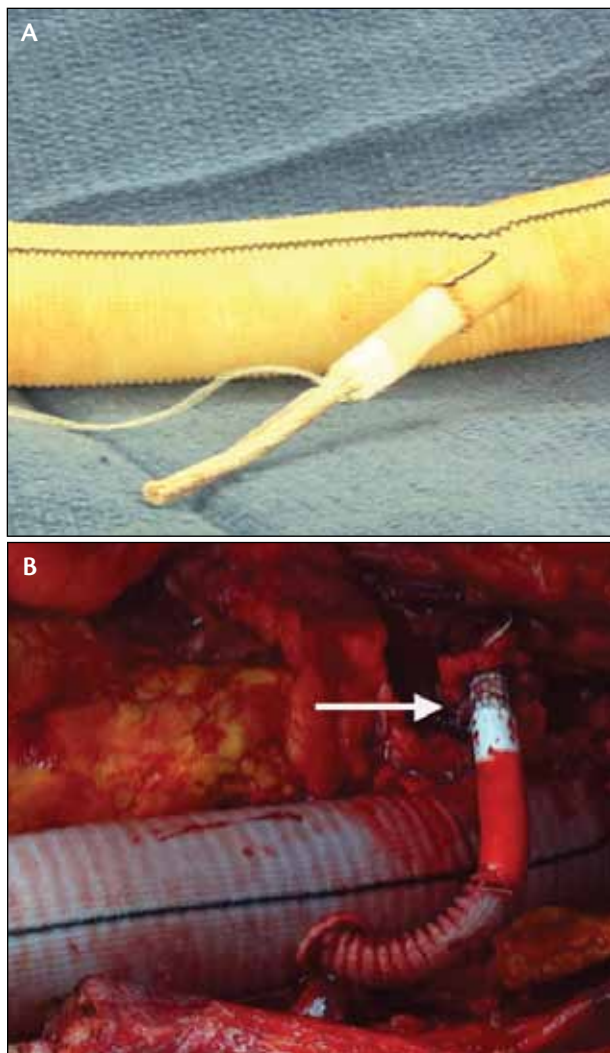


Figure 4. Aortic arch hybrid. The left common carotid artery was reconstructed with a hybrid graft (arrow).

involves the subjection of the vessel wall to turbulent flow related to the abrupt geometric change at the anastomosis.<sup>3,4</sup> Additional anastomotic turbulence is produced as a result of the mismatch in the compliance between the native vessel and relatively rigid graft material.

The Gore Hybrid vascular graft described in these cases is a new device aimed at optimizing anastomotic patency. The nitinol stent–reinforced portion of the hybrid graft provides a sutureless, endoluminal anastomosis for a more gradual hemodynamic transition and less variation in wall shear stress compared to the standard end-to-side anastomosis. The hybrid graft is designed to direct outflow in a laminar direction with the intention of reducing wall shear stress, endothelial injury, and the subsequent development of neointimal hyperplasia at the site of the distal anastomosis. Thus, this geometry generates flow characteristics that may





**Figure 5.** Left renal limb for open AAA repair. Ex vivo image of the prefabricated Dacron graft with a pre-sewn hybrid graft (A). Intraoperative image after deployment of the hybrid graft into the left renal artery (B, arrow).

reduce intimal hyperplasia and, as a result, increase graft patency. In addition, in an end-end reconstruction, the stent alleviates any stenosis that may result from suturing directly to a diseased orifice.

Deployment of these grafts requires limited exposure, potentially facilitating a difficult anastomosis in either difficult-to-reach anatomy or reoperative fields. In addition, use of the hybrid graft can allow for more rapid vascular anastomosis, which may translate into the potential to decrease critical ischemic times. Once deployed, the graft becomes fixed in the artery and is very difficult to dislodge.

Thus, the hybrid graft clearly demonstrates benefit from a technical standpoint. However, the potential of hemo-

In our experience to date, hybrid grafts demonstrate a promising adjunct in reducing graft outflow stenosis while simultaneously providing the technical benefits of a sutureless anastomosis.

dynamic benefits and improved patency have not been proven. Increased experience and follow-up will demonstrate whether the stent ultimately assists in improving long-term patency. In addition, as with other heparin-lined grafts, extra consideration must be taken in case where heparin-induced thrombocytopenia may exist.

In our experience to date, hybrid grafts demonstrate a promising adjunct in reducing graft outflow stenosis while simultaneously providing the technical benefits of a sutureless anastomosis. ■

*Brant W. Ullery, MD, is a Chief Surgical Resident at the University of Pennsylvania in Philadelphia. He has disclosed that he has no financial interests related to this article.*

*Ben M. Jackson, MD, is Assistant Professor of Surgery, Division of Vascular Surgery at the Hospital of the University of Pennsylvania in Philadelphia. He has disclosed that he has no financial interests related to this article.*

*Joseph Bavaria, MD, is the Brooke Roberts-William Maul Measey Professor of Surgery, Vice Chief of the Division of Cardiovascular Surgery, and Director of the Thoracic Aortic Surgery Program at the Hospital of the University of Pennsylvania in Philadelphia. He has disclosed that he has no financial interests related to this article.*

*Edward Y. Woo, MD, is Associate Professor of Surgery, Vice-Chief and Program Director for the Division of Vascular Surgery and Endovascular Therapy, and Director of the Vascular Laboratory at the Hospital of the University of Pennsylvania in Philadelphia. He has disclosed that he has no financial interests related to this article. Dr. Woo may be reached at (215) 662-7836; edward.woo@uphs.upenn.edu.*

1. Afaneh C, Aronova A, Ross JR, Leeser DB. Use of hybrid vascular grafts in failing access for hemodialysis: report of two cases. *J Vasc Access*. In press.
2. Meyerson SL, Skelly CL, Curi MA, et al. The effects of extremely low shear stress on cellular proliferation and neointimal thickening in the failing bypass graft. *J Vasc Surg*. 2001;34:90-97.
3. Haruguchi H, Teraoka S. Intimal hyperplasia and hemodynamic factors in arterial bypass and arteriovenous grafts: a review. *J Artif Organs*. 2003;6:227-235.
4. Hofstra L, Bergmans DC, Leunissen KM, et al. Prosthetic arteriovenous fistulas and venous anastomotic stenosis: influence of a high flow velocity on the development of intimal hyperplasia. *Blood Purif*. 1996;14:345-349.