

Endovascular Options for Chronic DVT

What's available and when to use these options.

BY MARK J. GARCIA, MD, FSIR

Deep vein thrombosis (DVT) is a common problem affecting between 250,000 and 2 million people annually in the US.¹ The most common complication of DVT is postthrombotic syndrome (PTS), which can affect between 25% to 60% of acute DVT patients.² Despite therapeutic anticoagulation and elastic compression stocking therapy (ECS), a significant proportion of DVT patients may progress to develop postthrombotic sequelae and significant quality-of-life limitations. The severity of PTS symptoms is directly proportional to the degree of ambulatory venous pressures: the higher the pressure, the more severe the symptoms.

The goal in treating chronic DVT is to relieve the obstruction by restoring flow in the occluded venous segment, decreasing the venous pressures and subsequently the severity of PTS.

Although there are no level 1 data, it has been the author's experience, as well as shown in single-center retrospective registry findings, that recanalization of chronically occlusive DVT can safely and successfully be performed to provide significant improvement in this population's venous flow, which led to relief in their symptoms, and improvement in their quality of life.³ These early reported findings beg for a randomized trial evaluating the long-term benefits of treating symptomatic patients with chronic occlusive DVT and PTS with standard-of-care medical therapy (anticoagulation and ECS) compared to those treated with endovascular therapies and recanalization.

PATIENT EVALUATION

Initial evaluation of a patient presenting with chronic DVT and PTS includes obtaining a full medical history, the date of symptom onset, and determining whether a full hypercoagulable workup has been adequately performed or is indicated. Assessment of adequate medical therapy should be undertaken to ensure the patient has failed conservative therapy. Risk factors should be eluted, and contraindications for thrombolytic therapy, excluded. The

severity of PTS should be graded by using the CEAP classification, Villalta score, or Venous Clinical Severity Score.⁴⁻⁶ A quality-of-life questionnaire should be completed to elicit a patient's baseline function and what benefit can be reasonably expected. A physical exam should include identification of PTS sequelae including varicosities, superficial collaterals, hyperpigmentation, lipodermatosclerosis, venous wounds, and limb measurements at defined locations on each extremity (for example, 15 cm above the uppermost margin of the patella, proximal calf, and ankle).

After a complete review of bloodwork and imaging, one can determine the need for further imaging based on physical exam findings. For example, if by exam, a central venous occlusion is suspected, consider CT venography or MR venography. The extent and location of DVT and occlusion can help plan the access site and what therapy may initially be considered.

When considering intervention, it has been the author's anecdotal experience that the use of low-molecular-weight heparins have improved early patency; patients are placed on enoxaparin before initiating endovascular treatment and continued throughout the case. I usually have patients on low-molecular-weight heparins for 3 months and then transition to Coumadin. The use of enoxaparin has negated the need for weekly blood draws as well as the waxing and waning international normalized ratio levels, which can greatly affect the potential of rethrombosis and patency rates. By improving flow and maintaining patency, the vessel can remodel the diseased venous segment. Using low-molecular-weight heparin therapy, combined with early exercise and appropriate ECS therapy, our mid- and long-term patency rates and symptomatic outcomes have considerably improved.³

PREPROCEDURE PLANNING

Despite the lack of level 1 evidence, it is becoming clear that we are on the verge of providing patients with chronic DVT and PTS a means of symptomatic

TABLE 1. ALGORITHM FOR AGGRESSIVE MANAGEMENT OF CHRONIC DVT AND POSTTHROMBOTIC SYNDROME

Preprocedural Evaluation:

- History and physical exam with documentation of PTS signs and symptoms
- Confirm occlusive DVT by recent venous Doppler examination
- If signs or symptoms suggest more central involvement, consider CT or MRV
- Maximize medical management with therapeutic anticoagulation elastic compression stocking therapy if pulses are present, or sequential lymphedema pump therapy if indicated
- If venous ulcers are present, make referral for wound care

Procedure. If significant symptoms persist despite medical management, consider intervention:

- Preprocedural laboratory tests: CBC, electrolytes, DIC screen/coagulation panel
- Initiate therapy with enoxaparin sodium (1 mg/kg twice a day)
- Ultrasound-guided micropuncture access
 - Popliteal vein if femoral-popliteal DVT present
 - Femoral vein if no infrainguinal DVT present
 - Consider IJ if unable to cross DVT from lower extremity access
- Once occlusion is successfully crossed:
 - Balloon maceration of occlusive DVT segments with 8- or 10-mm balloons
 - Initiation of overnight EKOS ultrasound-accelerated thrombolysis
 - Follow-up venography with venous angioplasty of residual stenoses
 - Venous stenting of chronically narrowed segments in iliac and IVC segments
 - Stenting of common or upper femoral segments only if no flow from superficial femoral to common femoral veins
 - Pneumatic compression boots while in hospital receiving lytic therapy and at bedrest

Postprocedural Care:

- Discharge on enoxaparin sodium therapy for 8 weeks, and at minimum, provide appropriate knee-high elastic compression stocking therapy
- Follow-up venous Doppler examination and office visits at 1, 3, 6, and 12 months
- Re-evaluate and remeasure for ECS if swelling improves
- Consider adjunctive therapies if indicated (wound care, lymph pump, etc.)

Abbreviations: CBC, complete blood count; CT, computed tomography; DIC, disseminated intravascular coagulation; DVT, deep vein thrombosis; ECS, elastic compression stocking; EKOS, EkoSonic Endovascular System; IJ, internal jugular; IVC, inferior vena cava; MRV, magnetic resonance venography; PTS, postthrombotic syndrome

Table modified and used with permission from Medscape, 2012. Found at: <http://www.medscape.com/viewarticle/728409>.

relief and improved quality of life. This is best accomplished by achieving the ultimate goal of re-establishing inflow and outflow within the vein. In treating chronic DVT, interventionists utilize currently available devices and common catheter techniques used in treating both acute DVT and peripheral arterial disease.

Access site is determined by the extent of occlusive disease. In treating unilateral disease, access via the popliteal vein is reasonable if popliteal inflow is present from the calf. If no inflow is present, one may want to consider use of either the contralateral common femoral vein (CFV) or jugular access to allow for recanalization of the entire popliteal into tibial segments.

Infrequently, tibial access may be needed to help restore flow into the popliteal segment. Re-establishing popliteal inflow will significantly improve the chances to maintain long-term patency. If there is only supraguinal occlusion, one can safely use the ipsilateral CFV. If IVC and extensive bilateral occlusions are present, then jugular access may allow for the optimum ability to treat the entire occluded segments. One of the greatest difficulties is gaining access into a chronically occluded and echogenic tibiopopliteal segment that may not be readily evident on sonographic evaluation.

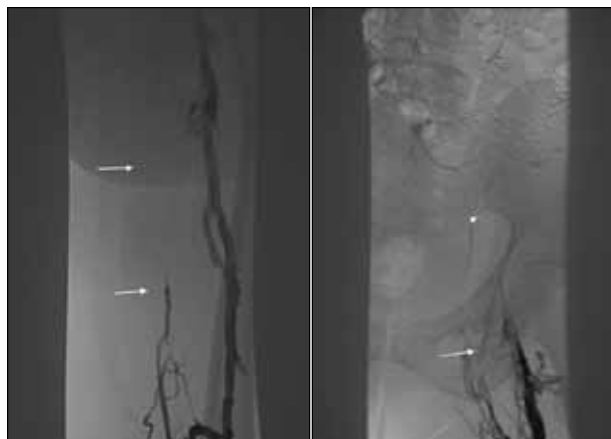

Figure 1. Initial venogram demonstrates occlusion of femoral, CFV, and iliac veins (arrows) with ligation clip (arrow-head).

TECHNIQUE

Once venous access has been achieved, standard catheter and wire techniques are utilized to cross the chronic, hard, and occlusive clot. It has been this author's experience that if you are able to successfully cross the DVT, then you can usually re-establish flow and restore patency. Traversing the chronic occlusive clot is often the greatest challenge in these cases. Techniques may include the use of a stiff Glidewire (Terumo Interventional Systems, Somerset, NJ), sharp recanalization, and CTO catheters and wires; if a wire can be passed but not the diagnostic catheter, then serial dilatation is needed to create some "working space." Support for better pushability can be obtained by using a graduated system, such as a 4-F tibial sheath coaxially through a 6-F standard sheath placed through an 8-F sheath.

Mechanical devices, such as the Jetstream (Bayer Radiology and Interventional, Indianola, PA) (off-label use), have been used to create a channel otherwise unable to be crossed with a device other than a wire. Once the occlusion has been successfully crossed, balloon dilatation of the chronic clot is initially performed to create working space and to macerate/crack the hard thrombus. Cracking the chronic clot may allow for better penetration of the tissue plasminogen activator. If a component of acute clot is identified, one may consider performing pharmacomechanical thrombolysis to debulk that segment.

For pure chronic thrombus, once venoplasty has been performed throughout the entire diseased segment, I proceed directly to ultrasound-accelerated thrombolysis, by placing the Ekos device (Ekos Corporation, Bothell, WA) for overnight thrombolytic therapy. I usually infuse at a rate of 0.5 mg tPA/h, but may go to 1 mg/h for a more extensive clot. The typical concentration is 10 mg tPA/500

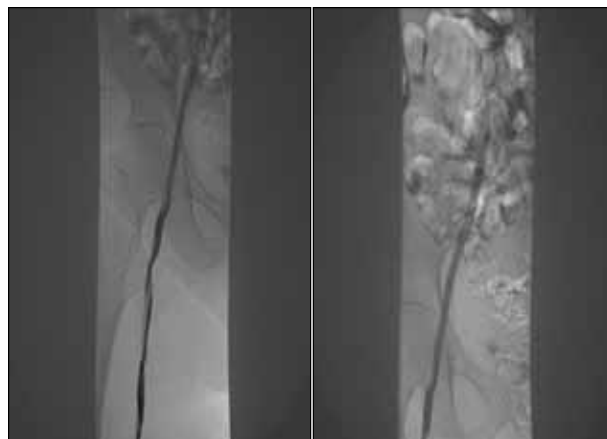


Figure 2. Post-PTA and overnight Ekos lysis demonstrates recanalization with excellent flow in the femoral vein. Patency seen after Supera stenting of the common femoral and external iliac veins with a Protégé stent in the common iliac vein.

mL NSS. I prefer the Ekos system, as the device has been shown to allow for a more effective penetration of tissue plasminogen activator into the clot by thinning the fibrin latticework and exposing the plasminogen receptors.

The use of mechanical devices such as the Angiojet (Bayer Radiology and Interventional) or Trellis (Covidien, Mansfield, MA) to physically macerate the clot, with or without the added use of catheter-directed thrombolysis, might also be considered.

Another technique that has been described is the "full-metal jacket" stenting technique, although not preferred by this author. In our single-center experience with known chronic DVT, occluded venous segments have been successfully recanalized using the maceration/Ekos technique with follow-up patency remaining up to 20 months (Table 1).

Typically, Ekos thrombolysis is continued overnight with adjuvant treatments consisting of additional venoplasty and/or stenting performed as necessary. Although there is no FDA-approved venous stent currently available, several medical device companies have demonstrated interest in designing a venous-indicated stent. Self-expanding, bare-metal stents are most commonly used in the venous system, with the only pearl offered here being with the use of the Supera (IDEV Technologies, Inc., Webster, TX) (off-label use) stent when crossing the inguinal ligament and CFV into the femoral vein. In my experience, the Supera stent provides more radial strength and compression resistance than other nitinol stents in this anatomy. Stenting across the groin is only considered when there is poor flow from the femoral vein into the CFV and iliacs, and all other measures have been exhausted.

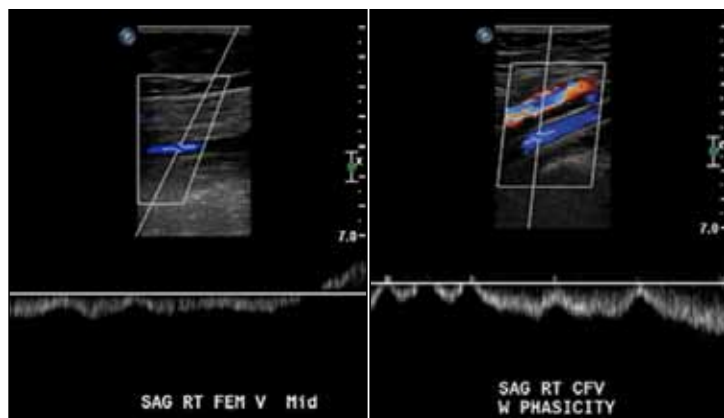


Figure 3. Eighteen-month follow-up color Doppler shows wall-to-wall patency throughout the right lower extremity.

POSTPROCEDURE MANAGEMENT

After intervention, the patient is discharged on 30 to 40 mm Hg ECS and enoxaparin (1 mg/kg bid preferred over 1.5 mg/kg) for 3 months with follow-up Doppler exams and office visits to include limb measurements and review of symptoms at 1 and 3 months. We have been successful in getting the majority of insurance companies to cover the cost of medications for the potential of symptomatic improvement and hope to resolve PTS. It is imperative that color Doppler be carefully utilized to document patency, as there will commonly be persistent wall thickening and chronic venous changes, but wall-to-wall patency can be demonstrated. It is crucial to review the images and not just read the report because the chronic changes will often be officially read as persistent DVT. If limb swelling and discomfort is too great for standard ECS use, then leg wraps, elevation, and even pumps can be used to reduce the swelling and pain and allow for earlier ECS use. The patient is also encouraged to ambulate and exercise early and often. Continued follow-up evaluation is made with Doppler studies and physical exam at 6, 12, 18, and 24 months, and yearly thereafter.

After successfully restoring flow in chronically diseased venous segments, the patient must be aware that the vein is permanently damaged, as are the valves, so venous insufficiency/reflux is to be expected. For this reason, I will explain to the patient that to help prevent symptoms associated with reflux, they will need to wear ECS indefinitely. The length of anticoagulation is based on the clinical scenario and identification of underlying etiologic factors.

CASE EXAMPLE

The patient is a 65-year-old woman who underwent a hysterectomy complicated by a right iliac vein rup-

ture in 1998. The vascular surgeon was unable to repair the vein, resulting in ligation. The patient immediately developed pain and swelling with extensive right lower extremity DVT. The patient has been managed with anticoagulation and ECS for 12 years but developed severe limitations in activity and poor quality of life (Figures 1 through 3). The patient was referred for DVT intervention and had successful restoration of venous flow utilizing balloon maceration and EKOS thrombolysis followed by stenting. At 18 months, the patient is exercising daily with no pain and rare swelling, although she maintains daily ECS use.

SUMMARY

Recanalization of chronic, occlusive DVT can safely and effectively be performed with subsequent improvement in symptoms and quality of life for patients with PTS. By utilizing techniques and devices readily available to the interventionist, we can significantly change the outcomes for those impaired by this common medical problem. Successful development of a chronic DVT treatment program not only involves the knowledge and expertise in the treatment of venous disease and catheter techniques but also the patience and perseverance needed in these often difficult and lengthy cases, as well as having access to the variety of devices needed to successfully treat patients with chronic venous occlusions. ■

Mark J. Garcia, MD, FSIR, is Section Chief of Interventional Radiology and Medical Director of Peripheral Labs Center for Heart & Vascular Health, Christiana Care Health Services in Newark, Delaware. He has disclosed that he serves on the speaker and advisory committee for the PEARL registry, sponsored by Medrad Interventional/Possis (now Bayer Radiology and Interventional) and that he serves on the steering committee for IDEV. Dr. Garcia may be reached at (302) 733-5625; magarcia@christianacare.org.

- Goldhaber S, Morrison R. Pulmonary embolism and deep vein thrombosis. *Circulation*. 2002;106:1436.
- Ashrani AA, Heit JA. Incidence and cost burden of post-thrombotic syndrome. *J Thromb Thrombolysis*. 2009;28:465-476.
- Grilli CJ, McGarry M, Ali M, et al. Aggressive management of chronic DVT: technical and clinical outcomes. Presented at: SIR 37th Annual Scientific Meeting; March 24 to 29, 2012; San Francisco, CA.
- Eklof B, Rutherford RB, Bergan JJ, et al. Revision of the CEAP classification for chronic venous disorders: consensus statement. *J Vasc Med Biol*. 2004;16:231-242.
- Kahn SR. Measurement properties of the Villalta scale to define and classify the severity of the post-thrombotic syndrome. *J Thromb Haemost*. 2009;9:884-888.
- Rutherford RB, Padberg FT Jr, Comerota AJ, et al. American Venous Forum's Ad Hoc Committee on Venous Outcomes Assessment. Venous severity scoring: an adjunct to venous outcome assessment. *J Vasc Surg*. 2000;31:1307-1312.