Evaluation and Management of Chronic Thoracic Venous Obstructions

Clinical presentation, anatomic patterns of TCVO, and revascularization strategies.

BY BRIAN HOLLY, MD, AND MARK L. LESSNE, MD

Chronic thoracic central vein obstruction (TCVO), including both stenosis and occlusion, is a potentially morbid condition, especially in patients with end-stage renal disease who rely on a patent central venous system to preserve hemodialysis access. Unfortunately, TCVO is a common complication for patients on hemodialysis. The true incidence of TCVO in patients requiring hemodialysis is unknown and reports vary greatly, affecting anywhere from 4% to 50% of this population.[1,2] Aside from the development of venous obstructive symptoms, venous occlusions often lead to placement of dialysis catheters at suboptimal access sites, such as in the femoral veins, which in turn may increase the risk of infection and morbidity. Still, for some patients, even alternative access sites may have been exhausted and the ability to restore access through a TCVO can be lifesaving.

ETIOLOGY AND CLINICAL PRESENTATION

There are several possible etiologies of TCVO. Most commonly, the obstructions relate to catheter use, which can lead to endoluminal obstruction by thrombus or intravascular scarring from catheter-induced trauma to the venous endothelium. This subsequently causes inflammatory changes and turbulence from arterialized flow into the vein.[3] Extrinsic compression of the vein can also lead to a chronic occlusion. Compression can be due to overlying musculoskeletal structures (thoracic inlet or brachiocephalic vein [BCV] compression syndromes) or tumor compression.

TCVO usually develops slowly over time, allowing the formation of collateral veins, which may mitigate or prevent symptoms.[4] In some instances, a chronic asymptomatic obstruction may become symptomatic through the establishment of an ipsilateral arteriovenous access. When a TCVO becomes symptomatic, the results can be severely debilitating. Facial, breast, or upper extremity edema are common. If the obstruction is severe, it can also lead to dialysis access dysfunction or occlusion, dyspnea, pain, visual or other neurologic changes, headaches, and syncope.[3,5] The presence, severity, and progression or regression of these symptoms must be assessed on initial and all subsequent patient encounters. Additionally, the presence and creation of reliable hemodialysis access must be assessed and prioritized.

When evaluating a patient with TCVO, the anatomy and clinical presentation must be carefully delineated. The Society of Interventional Radiology has released guidelines to help ensure TCVO reporting is comprehensive and reproducible.[5] In fact, even the terms central and peripheral veins lack standard definitions; therefore, one of the objectives of the guideline was to standardize terminology in order to improve reporting. For the purposes of this article, the thoracic central veins include the intrathoracic portions of the internal

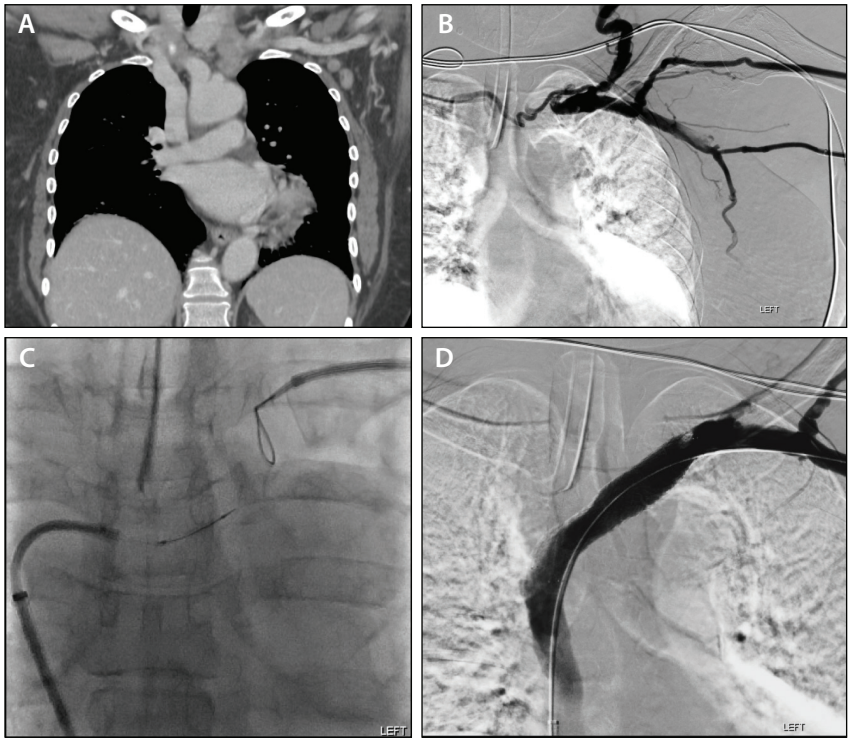

Figure 1. Type 2 TCVO in a 60-year-old woman with a poorly functioning left arm arteriovenous fistula (AVF) and end-stage renal disease requiring hemodialysis. A preprocedural CT venogram revealed a patent right BCV and SVC but suggested a chronically occluded left BCV (A). The left arm AVF was accessed, and a venogram confirmed chronic total occlusion of the left BCV (type 2 TCVO) (B). Antegrade recanalization from the upper extremity was unsuccessful. An 8-F angled sheath was placed from the groin into the central left BCV stump, and a 10-mm snare was placed in the SC vein from the upper extremity access to be used as a target for crossing the occluded segment. The occlusion was successfully traversed using an 0.018-inch hydrophilic wire and crossing catheter. The wire was then snared and externalized for through-and-through wire access (C). The completion venogram demonstrated restoration of inline flow after placement of a 14-mm self-expanding BMS across the left BCV occlusion (D). After stent placement, the patient continued with hemodialysis via the left arm AVF without incident.

jugular (IJ) and subclavian (SC) veins, as well as the BCVs and superior vena cava (SVC). The anatomic boundaries of the thorax are the C7-T1 intervertebral disc space and the lateral margin of the first rib.

A precise definition for the pattern of TCVO is important. There are four predominant anatomic patterns of TCVO.[5] Type 1 describes patent bilateral BCVs and a patent SVC with occlusion of only one IJ or SC vein. Type 2 is any TCVO that includes unilateral BCV obstruction or occlusion of both the IJ and ipsilateral SC veins (functionally similar to a single BCV obstruction) (Figure 1). Type 3 requires bilateral BCV occlusion with a patent SVC (Figure 2). Type 4 is any SVC occlusion irrespective of the patency of other thoracic veins (Figure 3).

REVASCULARIZATION STRATEGIES

Open surgical bypass has largely fallen out of favor compared with endovascular recanalization techniques. Once a decision has been made to proceed with thoracic venous recanalization, there are several preprocedural steps the interventionalist can take to maximize the chances for a safe and successful procedure. Imaging with chest CT venography can be invaluable because it provides useful information about the obstruction, including exact location, length of obstruction, and nearby critical structures (ie, arteries, lungs). Additionally, it allows the operator to create a crossing strategy before the procedure, which can save valuable time during the case. Thoracic magnetic resonance venography has also been utilized for these purposes in centers with familiarity and expertise. Doppler ultrasound of the bilateral neck, chest, and upper extremities can be helpful to determine patency of peripheral venous inflow, as well as identify potential venous access points if revascularization is attempted.

Before proceeding with revascularization, the goal of the procedure must be clear: are TCVO symptoms being treated, or is the procedure purely to establish hemodialysis access? The former requires restoration of venous inflow and outflow for symptom resolution and maintenance of patency, whereas the latter requires only safe access into the right atrium, even if an extravascular route is required along the way. The next step is to determine the ideal venous access points. Multiple points of access are often required, and having these access points prepared from the outset saves valuable time during the procedure. Consideration of mechanical advantage can drastically reduce procedure times and increase technical

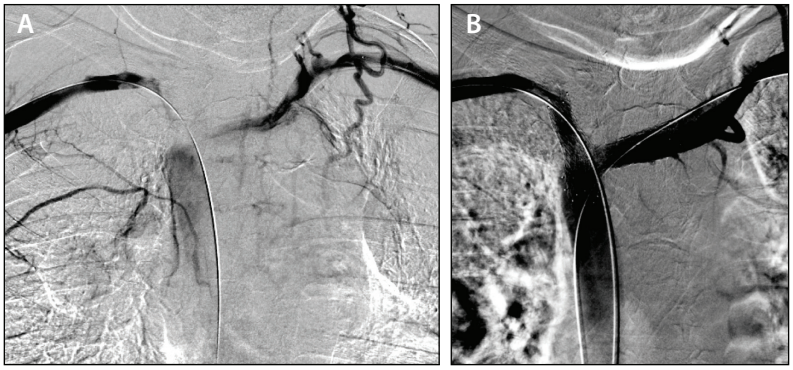

Figure 2. Type 3 TCVO in a 68-year-old man with bilateral facial swelling and postural light-headedness. Bilateral basilic vein access was established and bilateral thoracic venography was performed, demonstrating chronic occlusion of the bilateral BCVs but a patent SVC (type 3 TCVO) (A). The occluded segments of both BCVs were crossed using a long vascular sheath (which was advanced into the SC vein), a crossing catheter, and a stiff hydrophilic wire. After "kissing" self-expanding BMS reconstruction, inline flow into the SVC was restored (B). The patient subsequently experienced complete resolution of venous obstructive symptoms.

success. For example, when managing an SVC occlusion, a right IJ approach allows direct caudal transmission of forces versus an upper extremity approach, which necessitates navigating angles into the BCV.

After venous access is established, a robust triaxial support system is created with long sheaths, guide catheters, and diagnostic or dedicated crossing catheters. To cross the obstruction, 0.035-inch hydrophilic wires in long lengths (260 cm) are typically used as a first-line tool and are successful in the majority of cases. It may be helpful to use 0.018-inch or arterial chronic total occlusion wires with weighted tips to engage and traverse particularly fibrotic occlusions.

When traditional endovascular methods fail, experienced interventionalists may utilize sharp or radiofrequency (RF)-assisted recanalization techniques. Sharp recanalization techniques require the use of the back end of a wire, 20- to 22-gauge (15–20 cm) percutaneous or transseptal needles, or transjugular intrahepatic portosystemic shunt needles.[6] A target—such as a catheter, snare (Figure 1), balloon, or partially deployed vascular plug or stent—is typically placed from the opposite approach to allow precise targeting under fluoroscopy using meticulous triangulation techniques. The RF-energized guidewire is a very useful tool in the interventionalist's armamentarium for occlusions that are completely recalcitrant to other endovascular techniques.[7] The RF wire is advanced and activated in stepwise 1- to 2-second bursts to cross the occluded vessel; however, much like a needle, the RF wire has the ability to penetrate both intended and unintended structures and requires a high level of expertise to avoid catastrophic complications.

Once the occlusion has been crossed and a safe crossing route has been confirmed, which can be done with over-the-wire tractography or cone-beam CT if needed,

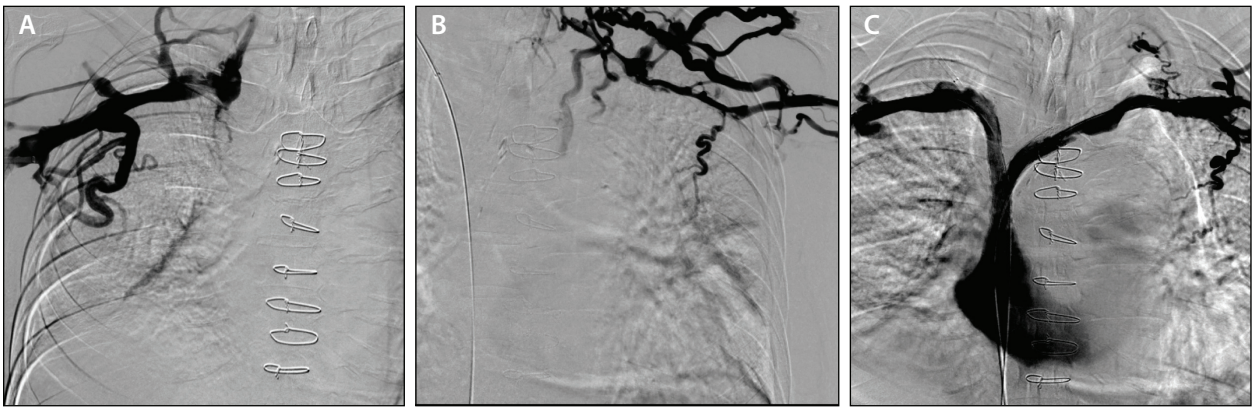

Figure 3. Type 4 TCVO in a 39-year-old man with a history of chronic SVC syndrome and a chronically occluded surgical IJ–right atrial saphenous vein bypass. Bilateral thoracic venograms revealed chronically occluded bilateral BCVs and a chronically occluded SVC (type 4 TCVO); the surgical bypass was obliterated and could not be visualized (A, B). The occluded segments were crossed from the bilateral upper extremity access using a triaxial system. The native BCVs and SVC were endovascularly reconstructed with "kissing" self-expanding BMSs extending down into the cranial aspect of the right atrium (C). Subsequently, the patient's venous obstructive symptoms were totally resolved.

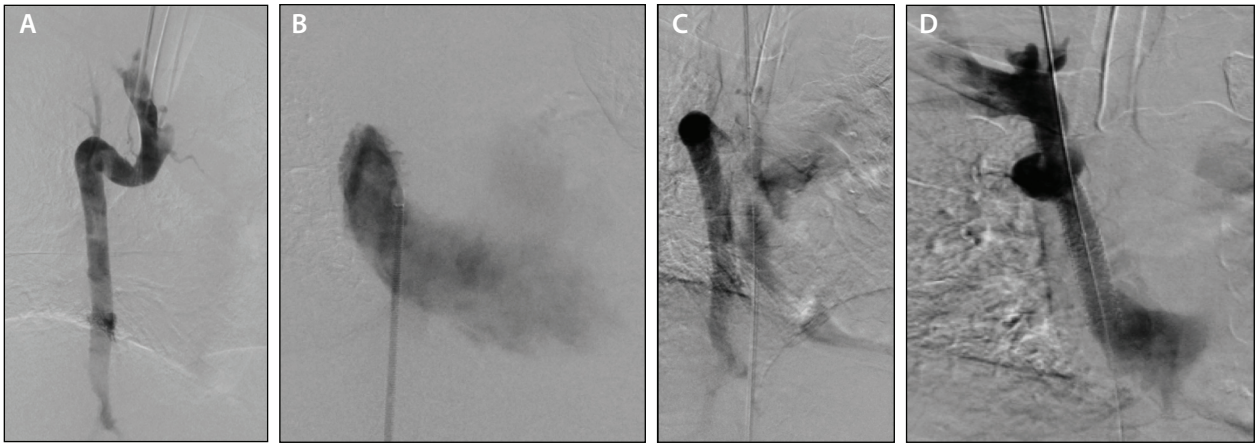

Figure 4. A 55-year-old woman presented with severe, chronic SVC syndrome. Venography performed from the right IJ (A) and right atrium (B) demonstrated a flush chronic occlusion of the SVC from the BCV confluence to the right atrium. Flow from the IJ vein had collateralized into the azygous vein. After RF wire–assisted recanalization, the tract from the right IJ vein to the right atrium was dilated with an 8-mm balloon. Venography immediately after confirmed active pericardial hemorrhage (C), and the patient experienced immediate hypotension. The patient was stabilized after rapid balloon tamponade and stent graft reconstruction (D), followed by ultrasound-guided pericardial fluid aspiration. The patient experienced postprocedural pericarditis but was discharged approximately 1 week later with resolution of SVC syndrome symptoms at in-clinic follow-up.

angioplasty balloons are used to dilate the track. It is the authors' strategy to attempt angioplasty alone for lesions that are fairly easily crossed using traditional techniques and show a good angiographic result after dilation. For lesions that demonstrate immediate postangioplasty recoil or short-term recurrence or require advanced recanalization techniques, stent support is generally provided. Both balloon-expandable and self-expanding stents can be used centrally, but balloon-mounted stents should be avoided at points of potential external compression. Similarly, both bare-metal stents (BMSs) and covered stents are utilized for TCVOs, each with advantages and disadvantages. Covered stents can be lifesaving in areas where vessel injury may lead to significant hemorrhage, such as below the pericardial reflection. However, covered stents may unintentionally and unnecessarily occlude draining veins such as the azygos or contralateral BCV. An alternative approach when only catheter placement is necessary is to pass a needle from the level of the occlusion toward the skin surface. This allows passing of a wire to establish stable access, which can then be used to place a catheter. Newer commercially available devices have been designed to aid in this approach. As with all sharp recanalization techniques, care must be taken to avoid nearby critical structures.

After the procedure, patients may require anticoagulation (eg, warfarin, enoxaparin, apixaban) or antiplatelet therapy (eg, clopidogrel, acetylsalicylic acid), but data are lacking to provide high-level guidance. Patients are generally followed in clinic at 1, 3, and 6 months and then annually to assess for symptom resolution, dialysis access function, and recurrence of symptoms.

MANAGING COMPLICATIONS

Even seemingly straightforward treatment of TCVOs can result in devastating consequences, considering the anatomic location of the central thoracic chest veins in relation to the pericardial reflection and adjacent cardiac and arterial structures. Interventionalists must always bear in mind that the exact location of the pericardial reflection in relation to the SVC is somewhat variable and cannot be visualized. Small wire venous perforations into the mediastinum are largely inconsequential, but large vein rupture or ongoing hemorrhage in the pericardial sac can lead to clinically significant symptoms, pericardial tamponade, or even death.

Injury to adjacent structures such as the lung, trachea, aorta, and pulmonary arteries can be avoided by meticulous targeting techniques. Cone-beam CT can be useful, although it may be limited by a patient's body habitus or respiratory or cardiac motion.

For any procedure requiring treatment of SVC occlusion, an ultrasound-guided window to the pericardium should be marked and prepped prior to the start of revascularization. Should pericardial tamponade occur, emergent pericardial aspiration or drain placement can then proceed quickly at the previously marked site. Additionally, appropriately sized occlusion balloons and covered stents should be readily available in the procedure room to control hemorrhage (Figure 4).

CONCLUSION

TCVO can cause profound symptoms and impair effective renal replacement therapies. Clinical evaluation and delineation of obstructive etiologies and anatomy allow for targeted revascularization strategies. Thoracic venous recanalization can be performed effectively and safely by experienced and cautious interventionalists to allow amelioration of patients' symptoms and facilitate long-term hemodialysis access. ■

1. Adwaney A, Lim C, Blakey S, et al. Central venous stenosis, access outcome and survival in patients undergoing maintenance hemodialysis. Clin J Am Soc Nephrol. 2019;14:378-384.
2. Krishna VN, Eason JB, Allon M. Central venous occlusion in the hemodialysis patient. Am J Kidney Dis. 2016;68:803-807.
3. Kundu S. Review of central venous disease in hemodialysis patients. J Vasc Interv Radiol. 2010;21:963-968.
4. Trerotola SO, Kothari S, Sammarco TE, Chittams JL. Central venous stenosis is more often symptomatic in hemodialysis patients with grafts compared with fistulas. J Vasc Interv Radiol. 2015;26:240-246.
5. Dolmatch BL, Gurley JC, Baskin KM, et al. Society of Interventional Radiology reporting standards for thoracic central vein obstruction: endorsed by the American Society of Diagnostic and Interventional Nephrology (ASDIN), British Society of Interventional Radiology (BSIR), Canadian Interventional Radiology Association (CIRA), Heart Rhythm Society (HRS), Indian Society of Vascular and Interventional Radiology (ISVIR), Vascular Access Society of the Americas (VASA), and Vascular Access Society of Britain and Ireland (VASBI). J Vasc Interv Radiol. 2018;29:454-460.e3.
6. Cohen EI, Beck C, Garcia J, et al. Success rate and complications of sharp recanalization for treatment of central venous occlusions. Cardiovasc Intervent Radiol. 2018;41:73-79.
7. Guimaraes M, Schonholz C, Hannegan C, et al. Radiofrequency wire for the recanalization of central vein occlusions that have failed conventional endovascular techniques. J Vasc Interv Radiol. 2012;23:1016-1021.

Brian Holly, MD
Assistant Professor of Radiology and Radiological Sciences
The Johns Hopkins Medical Institute
Baltimore, Maryland
bholly3@jhmi.edu
Disclosures: None.

Mark L. Lessne, MD
Vascular & Interventional Specialists of Charlotte Radiology
Charlotte, North Carolina
Adjunct Assistant Professor of Radiology and Radiological Sciences
The Johns Hopkins Medical Institute
Baltimore, Maryland
mark.lessne@charlotteradiology.com
Disclosures: None.