

# Dialysis Catheter Tip Placement: The Functional Tip

A different look at a contentious topic.

BY MICHAEL TAL, MD, MBA; TAMIR FRIEDMAN, MD; AND HAMID MOJIBIAN, MD

The “optimal” positioning of a chronic dialysis catheter tip has been long debated, with a myriad of conflicting recommendations from various organizations such as the US Food and Drug Administration and the National Kidney Foundation Kidney Disease Outcomes Quality Initiative (KDOQI).<sup>1,2</sup> Considering that in 2009, an estimated 571,000 patients had end-stage renal disease, and 57% of those patients who needed dialysis needed at least one dialysis catheter, it stands as no surprise that an agreement of optimal catheter tip position is of paramount importance.<sup>3,4</sup> Despite the preponderance of patients affected, optimal catheter tip position remains a moving target. In fact, up until 2006, KDOQI guidelines recommended placing the dialysis catheter tip in the superior vena cava (SVC) in order “not to cause cardiac perforations.”<sup>5,6</sup>

The changing recommendations are not meritless. As a result of updated practices, such as the manda-

tory use of fluoroscopy and suggested ultrasound guidance for venous access, as well as the evolution of catheter design and materials, the risk of cardiac and venous perforations has significantly decreased.<sup>7-10</sup> In recent literary reviews and the most current iteration of KDOQI guidelines, the recommended catheter tip position was in the “mid-atrium with arterial lumen facing the mediastinum.”<sup>10,11</sup>

However, even these recommendations are marred by inaccuracy because they make no distinction between the different tip designs of the currently available dialysis catheters and dynamic interplay between catheter function, side hole design, and resulting complications.<sup>12-14</sup>

In this article, we will introduce a new concept: the functional tip (Figure 1). This concept is aimed at allowing accurate placement of various dialysis catheters while taking into consideration the different chronic dialysis catheter tip designs.

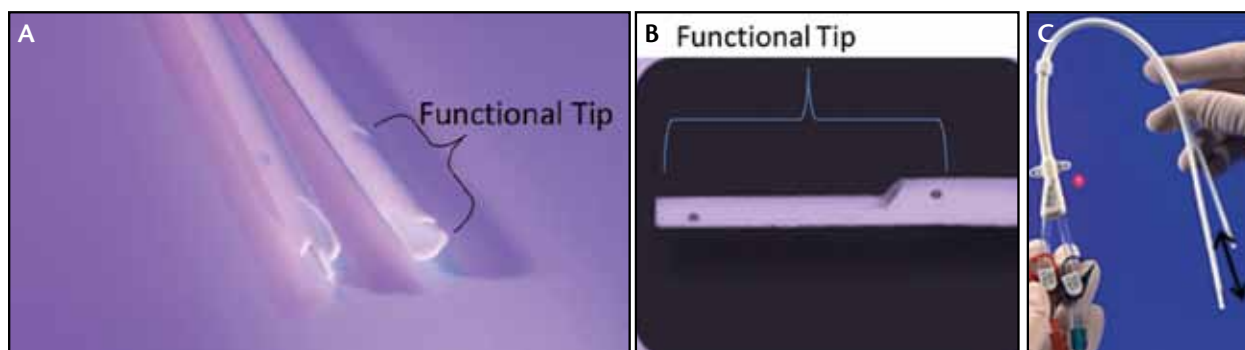
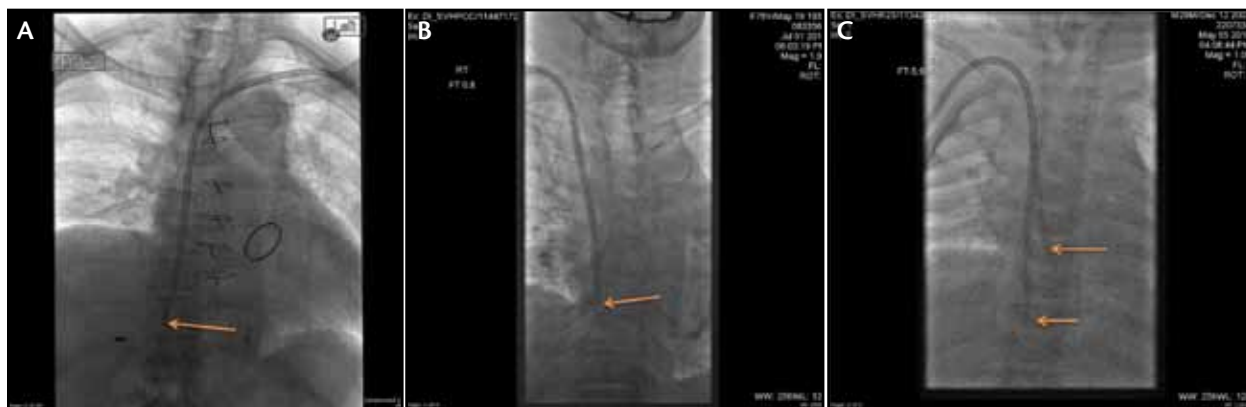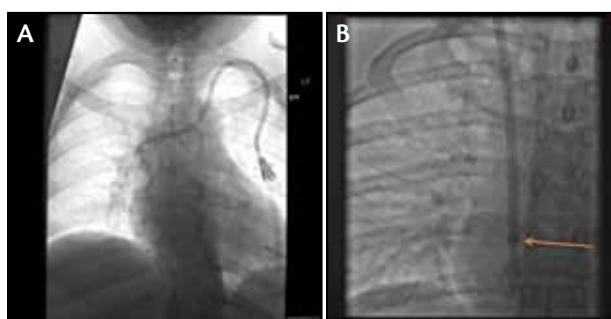


Figure 1. Palindrome dialysis catheter (Covidien, Mansfield, MA) demonstrating the “functional tip” measured from proximal side holes to catheter tip (A). The functional tip of a staggered-tip chronic hemodialysis catheter (B). The functional length of a split-tip catheter from the most proximal side hole to the tip (black arrow) (C).



**Figure 2.** A staggered-tip chronic hemodialysis catheter with the tip touching the floor of the atrium; the catheter was subsequently repositioned (A). Palindrome dialysis catheter with the tip (arrow) too low, likely touching the atrium floor (B). A split-tip chronic dialysis catheter placed too low with the venous tip (short arrow) in the inferior vena cava (C). The location of the proximal side holes on the arterial lumen is marked by a long arrow. Ideally, this should be placed just below the right atrium/SVC junction.



**Figure 3.** The Palindrome dialysis catheter tip placed high (A). The functional length is in the upper SVC. The catheter was subsequently repositioned. The Palindrome Precision dialysis catheter in the appropriate position (B). The marker (arrow) is proximal to the side slots and is placed below the right atrium/SVC junction, indicating that the functional length is within the right atrium.

## RECOMMENDATIONS FOR ACCURATE TIP PLACEMENT

**Recommendation No. 1.** Do not place the catheter tip too deep in the right atrium, so as to avoid touching the floor of the atrium. If the catheter tip touches the atrial floor, there is increased risk of atrial mural thrombus, perforation, and arrhythmias (Figure 2).<sup>1,10</sup>

**Recommendation No. 2.** Do not place the catheter too high. Side holes in the SVC may cause suction of the venous wall, positional occlusion, and/or malfunction.<sup>10,15</sup> Positioning of the dialysis catheter tip within the SVC may also lead to higher recirculation rates.<sup>16,17</sup> Damage to the vessel wall and thrombus creation can cause delayed vascular stenosis and occlusion (Figure 3).<sup>18</sup>

In addition, the whipping motion of the split-tip catheter during high-flow dialysis may further damage

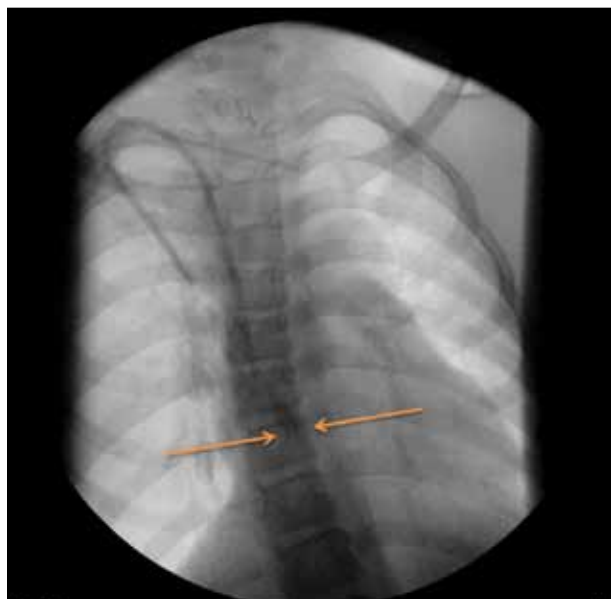
the vessel wall if the catheter terminates within the SVC; thus, accurate placement of split-tip catheters is of great importance.<sup>18</sup>

The chronic dialysis catheter should be placed with the side holes outside of the SVC. The anatomic location of the cavoatrial junction is well-established; however, its precise position on fluoroscopy and conventional chest radiography has been far more difficult.<sup>19</sup> The complex, three-dimensional heart proves to be unfavorable to conventional anatomic landmark localization on a two-dimensional modality. Multiple investigators have tried to establish criteria, using simple landmarks such as the carina, to allow radiologists to be more precise when attempting to place devices at the lower superior vena cava.<sup>20,21</sup> These criteria have proven cumbersome and inaccurate, given the complex anatomical variations from one patient to the next.<sup>19</sup> In our experience, even dedicated chest radiologists struggle to establish the precise location of catheter tips on chest radiographs. Placing the functional tip of the catheter within the right atrium allows the interventionist higher certainty of final catheter tip position.

We see that the tip of the catheter determines how low or how deep the catheter may be advanced. In contradistinction, the most proximal side holes determine how high the catheter may be placed, which brings us to the concept of the “functional tip” or “functional catheter length.”

## THE FUNCTIONAL TIP

The functional tip is the part of the catheter from the most proximal side hole to the catheter tip (Figures 1, 2C, 3B, and 4). The catheter functional length or functional tip is the part of the catheter where all the action



**Figure 4.** A split-tip catheter in the appropriate position. The functional length is within the right atrium. The arrows illustrate the positions of both catheter tips.

takes place. All catheters proximal to the functional length are, in essence, identical and serve as a simple blood conduit. Their length changes according to the total catheter length. Therefore, there should be only one tip—the functional tip.

**Recommendation No. 3.** Place the catheter so that the entire functional length is within the right atrium, but not too deep to avoid touching the floor of the right atrium.

Another important caveat to take into consideration is superior migration of the dialysis catheter when the patient is erect or semierect, as catheters are usually placed in the supine position.<sup>17,22</sup> One should envision the position of the patient during dialysis, because it is in this setting that the location of the functional length is clinically relevant. Superior migration of the catheter tip is magnified in obese patients and in women with large, pendulous breasts as result of soft tissue movement upon erect posture.<sup>1,22,23</sup> In obese patients, the catheter may be placed deeper within the right atrium; however, care should be maintained not to touch the right atrial floor. One way to minimize migration is to create a shorter and more lateral tunnel. This lateral tunnel reduces the downward migration of the external part of the catheter when the patient sits up.

## CONCLUSION

The debate should probably center around where to place the functional tip rather than where to place the

physical catheter tip. We believe that the catheter should be placed so that the functional length is as high as possible within the right atrium during dialysis. This allows all the activity to take place within the right atrium, potentially improving catheter function, reducing thrombosis and positional occlusion, and possibly reducing fibrin sheath formation and delayed venous damage. ■

*Michael Tal, MD, MBA, is Associate Clinical Professor, Yale Diagnostic Radiology, Yale University School of Medicine in New Haven, Connecticut. He has disclosed that he is a consultant to Covidien. Dr. Tal may be reached at michael.tal@aya.yale.edu.*

*Tamir Friedman, MD, is with Yale Diagnostic Radiology, Yale University School of Medicine in New Haven, Connecticut. He stated that he has no financial interests related to this article.*

*Hamid Mojibian, MD, is Associate Professor of Radiology, Yale University School of Medicine in New Haven, Connecticut. He stated that he has no financial interests related to this article.*

1. Vesely TM. Central venous catheter tip position: a continuing controversy. *J Vasc Interv Radiol.* 2003;14:527-534.
2. Scott WL. Central venous catheters. An overview of Food and Drug Administration activities. *Surg Oncol Clin N Am.* 1995;4:377-393.
3. Atlas of End-Stage Renal Disease in the United States. United States Renal Data System: 2011 USRDS Annual Data Report. 2011;2:142-409.
4. Danese MD, Liu Z, Griffiths RJ, et al. Catheter use is high even among hemodialysis patients with a fistula or graft. *Kidney Int.* 2006;70:1482-1485.
5. National Kidney Foundation-Dialysis Outcomes Quality Initiative. NKF-DOQI clinical practice guidelines for vascular access. *Am J Kidney Dis.* 1997;30(4 suppl 3):S150-S191.
6. III. NKF-K/DOQI Clinical practice guidelines for vascular access: update 2000. *Am J Kidney Dis.* 2001;37(1 suppl 1):S137-S181.
7. Chan MR, Yezlin AS. Tunneled dialysis catheters: recent trends and future directions. *Adv Chronic Kidney Dis.* 2009;16:386-395.
8. Cimino JE. Historical perspective on more than 60 years of hemodialysis access. *Semin Vasc Surg.* 2007;20:136-140.
9. Forauer AR, Glockner JF. Importance of US findings in access planning during jugular vein hemodialysis catheter placements. *J Vasc Interv Radiol.* 2000;11(2 pt 1):233-238.
10. Morgan D, Ho K, Murray C, et al. A randomized trial of catheters of different lengths to achieve right atrium versus superior vena cava placement for continuous renal replacement therapy. *Am J Kidney Dis.* 2012;60:272-279.
11. Vascular Access Work Group. Clinical practice guidelines for vascular access. *Am J Kidney Dis.* 2006;48(suppl 1):S176-S247.
12. Ash SR. Fluid mechanics and clinical success of central venous catheters for dialysis—answers to simple but persisting problems. *Semin Dial.* 2007;20:237-256.
13. Dwyer A. Surface-treated catheters—a review. *Semin Dial.* 2008;21:542-546.
14. Fry AC, Stratton J, Farrington K, et al. Factors affecting long-term survival of tunneled haemodialysis catheters—a prospective audit of 812 tunneled catheters. *Nephrol Dial Transplant.* 2008;23:275-281.
15. Moore HL. Side holes at the tip of chronic hemodialysis catheters are harmful. *J Vasc Access.* 2001;2:8-16.
16. Depner TA. Catheter performance. *Semin Dial.* 2001;14:425-431.
17. Schwab SJ, Beathard G. The hemodialysis catheter conundrum: hate living with them, but can't live without them. *Kidney Int.* 1999;56:1-17.
18. Petersen J, Delaney JG, Brakstad MT, et al. Silicone venous access devices positioned with their tips high in the superior vena cava are more likely to malfunction. *Am J Surg.* 1999;178:38-41.
19. Hsu JH, Wang CK, Chu KS, et al. Comparison of radiographic landmarks and the echocardiographic SVC/RA junction in the positioning of long-term central venous catheters. *Acta Anaesthesiol Scand.* 2006;50:731-735.
20. Mahlon MA, Yoon HC. CT angiography of the superior vena cava: normative values and implications for central venous catheter position. *J Vasc Interv Radiol.* 2007;18:1106-1110.
21. Baskin KM, Jimenez RM, Cahill AM, et al. Cavoatrial junction and central venous anatomy: implications for central venous access tip position. *J Vasc Interv Radiol.* 2008;19:359-65.
22. Nazarian GK, Hjarnason H, Dietz CA Jr, et al. Changes in tunneled catheter tip position when a patient is upright. *J Vasc Interv Radiol.* 1997;8:437-441.
23. Karam JL, Haddad FF, Medawar W, et al. Tunneled dialysis catheter tip migration in obese and large-breasted individuals. *Kidney Int.* 2009;75:760.