

Treatment of AVG Venous Anastomotic Stenosis

Clinical indicators and treatment techniques for this common cause of arteriovenous graft failure.

BY BART L. DOLMATCH, MD

Few occlusive problems in arteriovenous access circuits are as predictable as the development of arteriovenous graft (AVG) stenosis. Most of these stenoses are in the region of the venous anastomosis, although they often have the greatest degree of stenosis in the venous segment just beyond the surgical anastomosis (Figure 1). Despite the fact that the true anastomosis is often spared, I will continue to call this type of problem a *venous anastomotic stenosis* to keep with clinical convention and the published literature.

Venous anastomotic stenosis is the most common cause of poor AVG flow. It is also the leading cause of AVG thrombosis. As Dixon and colleagues showed in the multicenter Dialysis Access Consortium prospective study, venous anastomotic stenosis was not only the leading cause of AVG failure, but it occurred predominantly within the first year after AVG creation.¹ Because of this, the number of annual interventions to maintain patency and the cost per patient/per year are much higher for patients with AVGs compared to those with arteriovenous fistulas.²

CLINICAL INDICATORS

I adhere to the National Kidney Foundation Kidney Disease Outcome Quality Initiative guideline that describes clear criteria for treatment of an AVG venous anastomotic stenosis.³ There must be both a clinical measure of dysfunction and significant stenosis. Clinical indicators include findings during physical examination, such as increased pulsatility, loss of a palpable thrill, prolonged

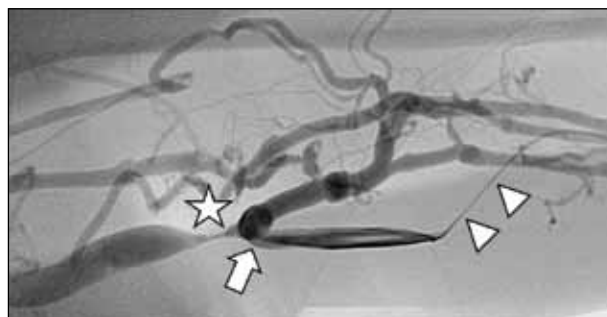

Figure 1. Angiogram of an upper arm AVG. There is a venous anastomotic stenosis (star) just beyond the surgical anastomosis (arrow). Catheterization of this AVG (arrowheads) has been performed in the direction of flow and directly in line with the stenosis to permit intervention.

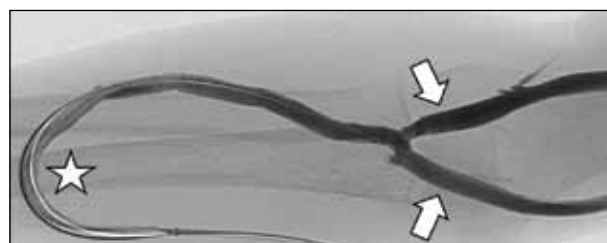


Figure 2. A typical forearm loop AVG angiogram. This forearm loop AVG has been accessed from a puncture within the arterial side of the graft, and any intervention from this access requires negotiation around the apex of the graft (star). Note the dual-venous outflow (arrows) just beyond the venous anastomosis.

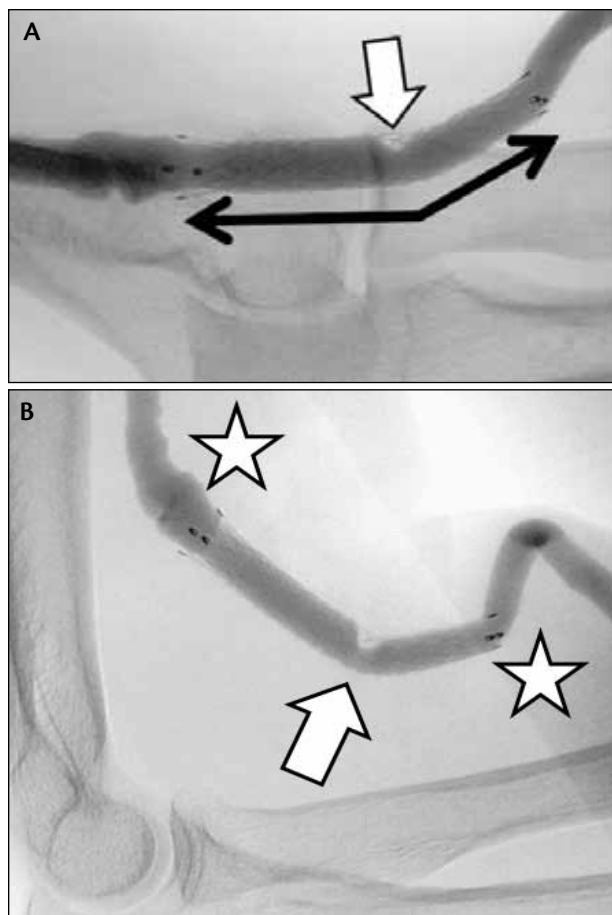


Figure 3. A stent graft placed across the elbow may have unusual forces that deform the implant. Angiography of a stent graft (double-headed arrow) at 6 months showing that it crosses the elbow and has noncritical narrowing within its mid-segment (arrow) (A). Lateral angiography of the stent graft during 90° flexion of the elbow (B). The forces at the ends of the stent graft (stars) are unpredictable for any given case, although there has been no edge stenosis in this case. The mid-stent graft narrowing may be due to neointimal tissue, organized thrombus, or material defect at the site of device deformity during flexion (arrow).

bleeding, and absence of flow (thrombosis). Quantitative indicators of AVG dysfunction include reduced urea clearance, increased intra-access pressure measurements, or reduced AVG flow, as determined by any one of a number of techniques. In our center, I see patients who have been referred for a variety of clinical and/or quantitative abnormalities that suggest underlying stenosis.

ANGIOGRAPHIC FINDINGS AND TECHNIQUE

Once a clinical indicator of AVG dysfunction has been detected, the National Kidney Foundation Kidney

Disease Outcome Quality Initiative guideline also requires luminal diameter reduction of at least 50% before intervention can be considered. Besides the somewhat arbitrary use of 50% diameter reduction, I, like most experienced interventionists, rarely perform quantitative diameter measurements. On occasion, when measurements are performed, I compare the diameter of the stenosis to a reference segment of AVG that is not cannulated for hemodialysis (repeated cannulation can cause dilation of the graft lumen due to disruption of the graft material). At least two different angiographic projections are recommended for assessment of the degree of stenosis and treatment planning.

I start my angiographic study of the AVG with direct catheterization through the wall of the graft in a segment that does not have excessive tortuosity. I place a 4- or 5-F catheter (usually, a micropuncture system) into the graft and connect it to a power injector for contrast administration during imaging. I always try to place the catheter so that it is directed toward the venous outflow of the AVG. This can easily be determined before puncture by compressing the mid-graft manually to the point of complete occlusion, then palpating on both sides of compression. On the arterial side, a strong pulse will be noted, whereas on the venous side, there will be no pulse because upstream flow has been temporarily occluded.

A puncture is then made in the direction from pulse to pulseless, from the arterial to venous direction of blood flow within the AVG. In the best of circumstances, the puncture is made in direct line with the venous anastomosis so that the diagnostic catheter can be converted to a vascular sheath for subsequent intervention (Figure 1). However, because most forearm AVGs are created in a loop configuration, I may make the initial puncture at the arterial side of the graft and later decide if I will intervene around the apex of the graft (Figure 2) or make a second puncture just beyond the apex to allow direct in-line access to a venous anastomotic stenosis.

Complete angiographic evaluation includes imaging from the inflow artery through the AVG to the right atrium. I evaluate the arterial side of the circuit using brief extrinsic compression of the graft beyond the tip of the catheter so that contrast will fill the arterial side of the graft and reflux across the arterial anastomosis into the inflow artery. For clotted grafts, I perform crossed-catheter percutaneous pharmacomechanical thrombolysis with 2 mg of tissue plasminogen activator and clot aspiration. Early in the procedure, I usually dilate the region of the venous anastomosis, even though the lack of blood flow precludes angiographic visualization of a stenosis. The presence of a waist on the angioplasty balloon during inflation indicates the presence of the

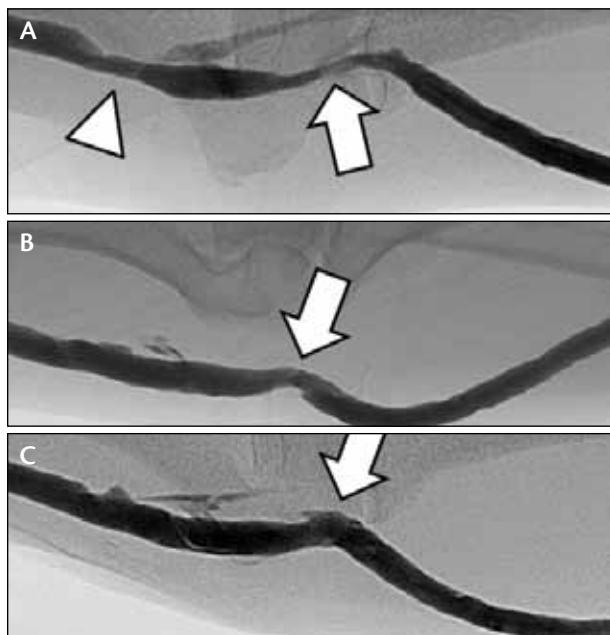


Figure 4. My typical approach to a forearm AVG venous anastomotic stenosis at the antecubital fossa using only angioplasty. Venous anastomotic stenosis (arrow) and a venous outflow stenosis (arrowhead) in a patient with a 7-mm AVG (A). Unsuccessful angioplasty to 9 mm (arrow), with a residual 40% to 50% stenosis at the venous anastomosis despite full balloon expansion (not shown) (B). Balloon dilation of the venous anastomotic stenosis using a 10-mm angioplasty balloon, with an angiographically successful result (C).

stenosis. Once flow has been established, the underlying AVG venous anastomotic stenosis that caused thrombosis is usually still detectable, and completion angioplasty is performed to optimize the final dilation.

ANATOMIC CONSIDERATIONS

I find that there are two types of AVG venous anastomotic stenoses in our patients. One is located in the antecubital fossa and is usually associated with a forearm loop graft. The other type is associated with upper arm AVGs and is found in the mid or high upper arm, with the graft anastomosed to the brachial or axillary vein. I treat antecubital and upper arm venous anastomotic stenoses differently.

Treatment for Antecubital AVG Venous Anastomotic Stenosis

Forearm loop grafts are anastomosed in the antecubital fossa to any of the potential veins found during surgery. Antecubital venous anatomy is variable,⁴ but in many cases, I find that the venous anastomosis is on

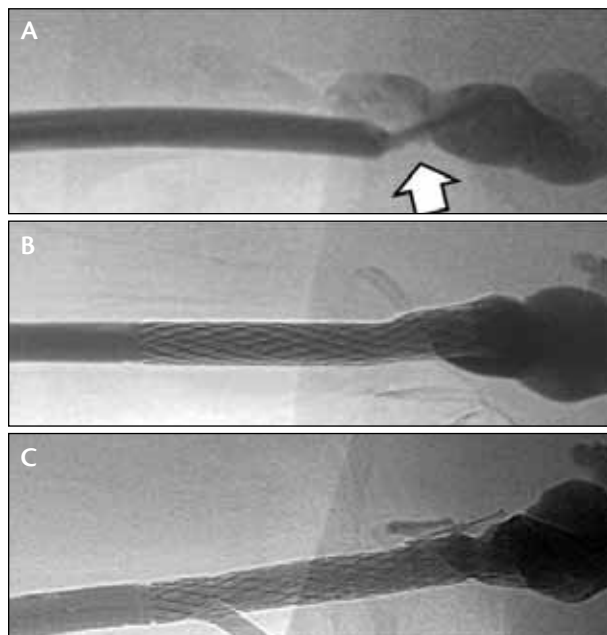


Figure 5. My typical approach to an upper arm AVG venous anastomotic stenosis, which is to primarily place a Flair stent graft at the angioplasty site to gain long-term patency. Short venous anastomotic stenosis in an upper arm, 6-mm-diameter AVG (arrow) (A). Technical success after angioplasty and placement of a 7-mm-diameter flared Flair stent graft (B). With no interval intervention at the venous anastomosis, follow-up angiography at 21 months showed preserved patency of the Flair stent graft (C).

a short segment of vein that bifurcates to supply the cephalic and basilic venous systems (Figure 2). Although this offers the advantage of providing excellent venous outflow through two different venous systems, it is important to realize that interventions should not be carried beyond the anastomotic stenosis to avoid damaging venous segments that may be used at a later time to create an upper arm arteriovenous fistula. This is particularly true when considering the use of stents or stent grafts, which may make subsequent creation of an upper arm arteriovenous fistula problematic.

Once a stent or stent graft has been placed across the elbow, the forces upon the implant and at the ends of the implant are unknown (Figure 3) and may lead to loss of the device's structural integrity and/or device-related stenosis. Finally, our data have shown inferior patency rates for stent grafts that are placed across the elbow.⁵ In the past, I was more liberal with the use of stents and stent grafts at an AVG antecubital venous anastomotic stenosis. Today, I strongly favor referral for early surgical revision when angioplasty fails to achieve an acceptable result.

Treatment for Upper Arm AVG Venous Anastomatic Stenosis

By the time a patient arrives with a stenosed upper arm AVG, I know that this may be the last arteriovenous access in the extremity because arteriovenous fistula and forearm loop graft options have usually been exhausted. A patient with an upper arm AVG is headed toward “end-stage AV access,” and durable salvage of the AVG is crucial. If anatomically suitable, I place a Flair stent graft (Bard Peripheral Vascular, Inc., Tempe, AZ) after angioplasty. The published Flair clinical trial data have shown that the use of this stent graft after angioplasty doubled the 6-month rate of primary circuit patency compared to angioplasty alone.⁶ A substantial 84% of AVGs treated with the Flair stent graft were in the upper arm, so these clinical trial data are particularly relevant for upper arm AVG stenoses.

INTERVENTIONAL TECHNIQUE

After performing complete AVG angiography and confirming a suitable venous anastomatic stenosis for treatment, I proceed with angioplasty. I do not use heparin or antiplatelet therapy because flow through an AVG is typically so fast that intraprocedural thrombosis is extremely rare. Use of prophylactic antibiotics is variable, although I usually administer a gram of intravenous cefazolin within 30 minutes of intervention if I anticipate the use of a stent graft. I select an angioplasty balloon with a diameter that is 1 mm larger than the graft diameter. It may sound like I make a lot of measurements, but it is actually quite easy to determine the graft size based on its anatomic appearance (or the operative note, if available).

There are only two graft sizes that I see in my practice: 6-mm straight grafts and 4- to 7-mm reverse-tapered grafts (4 mm at the arterial anastomosis and 7 mm thereafter). These two AVG configurations are easily differentiated by ultrasound or angiography because the 4- or 7-mm tapered graft is noticeably smaller in diameter at the arterial anastomosis. Because I use a balloon that is 1 mm larger than the graft at the venous end, I select either a 7- or 8-mm-diameter balloon for the initial dilation. I do not use balloons that are shorter than 4 cm in length, having found that 2-cm-long balloons tend to slip out of the stenosis during inflation.

In our practice, I routinely use ultra-high-pressure (UHP) balloons, although in many practices, it may be more economical to use conventional (lower pressure) angioplasty balloons unless the stenosis is resistant and a UHP balloon is required. To decide which strategy is better, you have got to do the math (cost accounting), looking at how often you need a UHP, and considering

the price of conventional versus UHP balloons.

If angioplasty fails to achieve a technically successful result in the antecubital fossa, I try to avoid using stents and stent grafts by selecting a larger-diameter balloon (Figure 4). I have not found that prolonged inflation matters if there is substantial elastic recoil—it wastes time, and the stenosis seems to recoil anyway. My routine is to inflate the angioplasty balloon to full profile twice for approximately 30 seconds. This is pure voodoo, but it seems to work as well as any other method of balloon inflation.

My approach for upper arm AVG venous anastomatic stenosis is very different. Regardless of the angiographic result of angioplasty, I try to place a Flair stent graft across the treatment site if it meets the reasonable anatomic considerations previously described (Figure 5). If insertion through a sheath is preferred, a 9-F sheath is required. When possible, I go “sheathless” to minimize the puncture size. This is especially applicable after declotting with the crossed-catheter technique, in which injection of the arterial side sheath can be used for angiography while the venous sheath is exchanged for the Flair delivery system over a guidewire (“sheathless”). After deployment of the Flair device, I exchange the stent graft delivery system for a 7-F sheath, through

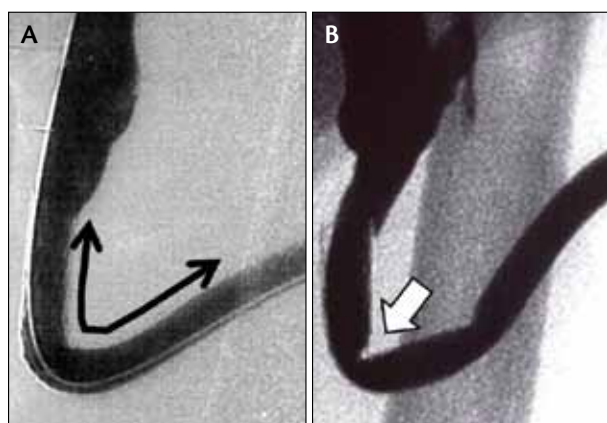


Figure 6. Placement of a stent graft at a site where it must assume a configuration of $> 90^\circ$ flexion. As part of the initial clinical trial of the Flair stent graft, the device (double-headed arrow) was placed at a site where it would be deformed by an angle of $> 90^\circ$ (A). Despite this excessive angulation, the stent graft showed no early signs of deformity. Six-month control angiography as part of the clinical trial shows that the stent graft developed a mid-body kink (arrow) due to chronic deformity (B). Although the degree of narrowing at the kink was $< 50\%$ and the AVG was fully functional, the Flair stent graft should not be used at a venous anastomosis with 90° angulation or greater. Reprinted with permission from Dr. Hervé Rousseau.

which I perform completion angioplasty. Regardless of whether I use a sheath, I close the puncture site with a purse-string suture method and remove the suture before the patient is discharged home. There are many different purse-string techniques, and they all have their champions.

The Flair device is a permanent implant that requires training in order to consistently perform safe and accurate placement. Bard Peripheral Vascular, Inc. has developed a very realistic simulator for Flair training, and they offer periodic training courses. It is not only about technical placement of the Flair, but also about judgment—selection of an appropriate device size and configuration, suitable positioning of the Flair, and appropriate case selection.

PROHIBITIONS TO STENTS AND STENT GRAFTS

I no longer use bare-metal stents to treat AVG venous anastomotic stenoses in any situation. Two decades of clinical data have taught me that patency after stent placement is no better than patency after successful angioplasty—and possibly worse. In-stent stenosis is a vexing problem. When angioplasty is unsuccessful or results in vessel rupture, I will typically use a stent graft.

Only the Flair device has been approved by the US Food and Drug Administration (FDA) for use in AVGs; however, there are some contraindications to its use. Placement in the antecubital fossa was a contraindication in the human clinical trial, so there are no Flair data for this application. A fixed angulation of 90° or greater at the venous anastomosis is a contraindication. An extreme degree of angulation, which is seen on occasion, can kink the Flair device (Figure 6), as was noted in the earliest clinical implants. Use of the Flair device within the AVG's cannulation segments (eg, to treat cannulation pseudoaneurysms) has not been studied.

Although the Flair device was tested in anastomotic stenoses up to 7 cm in length, longer stenoses require the use of two or more Flair stent grafts, which makes the cost of the procedure prohibitively expensive. Some interventionists have used longer stent grafts that are not yet FDA approved for use in AVGs, such as Fluency (Bard Peripheral Vascular, Inc.) and Viabahn (Gore & Associates, Flagstaff, AZ). A recent clinical trial using the Viabahn device for AVG venous anastomotic stenoses has recently been completed, but the results have not yet been released.

It may seem that this substantial list of contraindications often precludes the use of a stent graft. However,

I do not often encounter many of them in upper arm AVGs, and this is exactly the situation in which a stent graft has the greatest merit.

SUMMARY

AVG venous anastomotic stenosis is the most common cause of AVG failure and occurs predominately within the first year after AVG creation. There are two types of anatomic situations: forearm AVGs with a venous anastomotic stenosis at the antecubital fossa and upper arm AVGs in which the stenosis is located at the mid or high upper arm. In my practice, optimal angioplasty of forearm AVG stenosis is the rule, whereas stent graft placement after angioplasty has become my predominant method to treat upper arm AVG venous anastomotic stenosis.

The Flair stent graft is currently the only device that is FDA approved for use in AVG venous anastomotic stenosis after angioplasty, and randomized, prospective clinical trial data support better patency than with angioplasty alone. However, safe and accurate Flair device placement requires judgment and technical skill that can be acquired through simulator training. The Viabahn stent graft trial has been completed, but the results are pending. ■

Bart L. Dolmatch, MD, is Professor of Radiology and Director of Vascular and Interventional Radiology at the University of Texas Southwestern Medical Center in Dallas, Texas. He has disclosed that he is a consultant, royalty recipient, and speaker for Bard Peripheral Vascular, Inc. He has also disclosed that he is on the Board of Directors for the Vascular Access Society of the Americas, Codirector of Controversies in Dialysis Access, a consultant to Merit Medical Systems, Inc., a medical advisory board member and stockholder in Vital Access, Inc., a medical advisory board member of Cyto graft Tissue Engineering, and a medical advisory board member of the Endovascular Forum/IC Sciences. Dr. Dolmatch may be reached at duster54@sbcglobal.net.

1. Dixon BS, Beck GJ, Vazquez MA, et al. Effect of dipyridamole plus aspirin on hemodialysis graft patency. *N Engl J Med*. 2009;360:2191-2201.
2. US Renal Data System. 2010 annual data report: Atlas of chronic kidney disease and end-stage renal disease in the United States. Bethesda, MD: National Institute of Diabetes and Digestive and Kidney Diseases. Available at: <http://www.usrds.org>. Accessed March 15, 2012.
3. National Kidney Foundation. KDOQI clinical practice guidelines and clinical practice recommendations for 2006 updates: hemodialysis adequacy, peritoneal dialysis adequacy and vascular access. *Am J Kidney Dis*. 2006;48(suppl 1):S1-S322.
4. Yamada K, Yamada K, Katsuda I, Hida T. Cubital fossa venipuncture sites based on anatomical variations and relationships of cutaneous veins and nerves. *Clin Anat*. 2008;21:307-313.
5. Dolmatch BL, Duch JM, Winder R, et al. Salvage of angioplasty failures and complications in hemodialysis arteriovenous access using the fluency plus stent graft: technical and 180-day patency results. *J Vasc Interv Radiol*. 2012;23:479-487.
6. Haskal ZJ, Trerotola S, Dolmatch B, et al. Stent graft versus balloon angioplasty for failing dialysis access grafts. *N Engl J Med*. 2010;362:494-503.