

Endovascular TODAY

SPONSORED BY  SURMODICS

DEFEAT COLD FEET #POUNCEIT

The **Pounce™ LP Thrombectomy System** rapidly removes acute-to-chronic thrombi or emboli in tibial arteries



Suyue Zhang, MD



Amanjit S. Baadh, MD



Gary Ansel, MD




2-4mm




3.5-6mm



5.5-10mm



- 03** Meeting the Challenge of Infrapopliteal Organized Thromboemboli With the Pounce™ Thrombectomy Platform
By Gary Ansel, MD, and Cyrus Rezvanifar, PhD, MBA
- 08** The Pounce™ LP System: An Essential Tool for BTK Revascularization
A conversation with Dr. Suyue Zhang.
- 10** Case Report: Prompt Resolution of Acute Popliteal and Infrapopliteal Arterial Occlusions With the Pounce™ LP Thrombectomy System
By Suyue Zhang, MD
- 11** Case Report: Removal of Below-the-Knee Embolic Arterial Occlusion With Two Passes of the Pounce™ LP Thrombectomy System
By Suyue Zhang, MD
- 12** Peripheral Arterial Thrombus Removal Above or Below the Knee Using the Pounce™ Thrombectomy Platform
A conversation with Dr. Amanjit S. Baadh.
- 13** Case Report: Use of the Pounce™ and Pounce™ LP Thrombectomy Systems to Remove Lower Extremity Arterial Thrombus Following Attempted Aspiration Thrombectomy and Thrombolysis
By Amanjit S. Baadh, MD
- 14** Overview of the Pounce™ Thrombectomy Platform



Intended Use

The Pounce™ Thrombectomy System is intended for the non-surgical removal of thrombi and emboli from the peripheral arterial vasculature.

Contraindications

The device is contraindicated for use in patients who cannot receive recommended intravenous anticoagulant therapy.

Caution: Federal (US) law restricts these device(s) to sale by or on the order of a physician. Please refer to Instructions for Use for indications, contraindications, warnings, and precautions.

Meeting the Challenge of Infrapopliteal Organized Thromboemboli With the Pounce™ Thrombectomy Platform

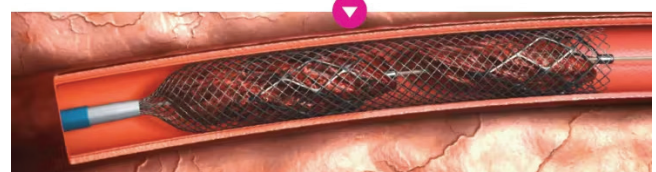By Gary Ansel, MD, and Cyrus Rezvanifar, PhD, MBA

Since the introduction of the Fogarty catheter in the early 1960s, open surgical embolectomy has been a frontline treatment for acute limb ischemia (ALI) of embolic origin, particularly in patients with previously normal vessels lacking collateral circulation.¹ The characteristic severity of embolic ALI often requires prompt revascularization,² and the mechanical properties of spontaneous emboli—typically cardiogenic, fibrin-rich, and highly organized³—may challenge prompt restoration of flow using percutaneous options such as thrombolysis⁴ or aspiration thrombectomy.^{1,5,6}


The Pounce™ Thrombectomy Platform (Surmodics, Inc.), inspired by the Fogarty catheter's mode of action (Figure 1), provides a percutaneous option with demonstrated effectiveness against acute or chronic emboli or thrombi (Figure 2).⁷ The Pounce™ Platform includes three different-sized, fully mechanical, non-aspiration-based systems with a combined vessel diameter range of 2 to 10 mm (page 14). In this article, we highlight the performance of the Pounce™ Thrombectomy System and Pounce™ LP (Low-Profile) Thrombectomy System for percutaneous extraction of arterial thromboemboli.



The basket wire is delivered distal to the location of the thrombus, deploying two nitinol self-expanding baskets.



The baskets capture the clot and are retracted into a nitinol collection funnel.



With the clot entrained, the system is retracted into a minimum 7 Fr guide sheath and removed from the body.

Figure 1. Pounce™ Platform mode of action.

extremity emboli tend to lodge at arterial bifurcations, where the vessel lumen is narrowed.⁸ Secondary thrombus may form both proximal and distal to the emboli, worsening the occlusion and introducing risk of propagation of the secondary clot.⁸ Figure 4 provides an example of a thromboembolic occlusion of the tibioperoneal trunk (TPT) resulting in complete blockage of distal flow in a patient with new-onset atrial fibrillation (AF). Use of the Pounce™ Thrombectomy System succeeded in restoring three-vessel runoff to the foot with three device passes. Note the mixed-morphology occlusive debris extracted using the device.

Bilateral lower extremity embolization. In acute embolic ischemia of the lower extremity, bilateral embolization has been reported in 15% of cases.⁹ Figure 5 illustrates a case of bilateral lower extremity embolization in a patient with as-

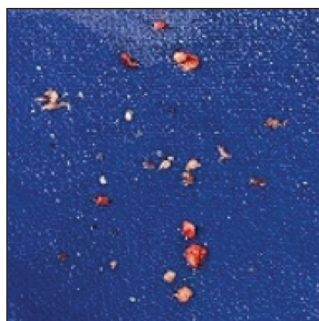

Figure 2. Arterial emboli removed with the Pounce™ Thrombectomy Platform.



See case

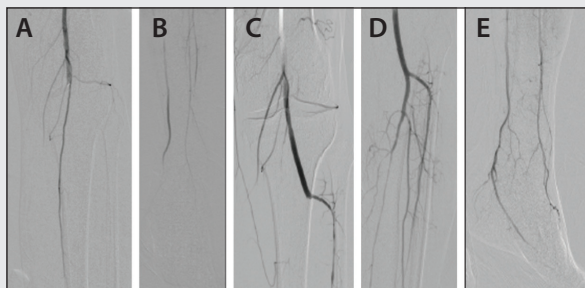
EMBOLIC PRESENTATIONS

Thromboembolic occlusion of the popliteal artery. Figure 3 provides an example of a popliteal embolic occlusion in a patient with no known history of peripheral artery disease. Note successful removal of embolus with two passes of the Pounce™ Thrombectomy System after attempted aspiration thrombectomy.

Thromboembolic occlusion of the tibioperoneal trunk. Lower



Figure 3. Removal of popliteal embolus using the Pounce™ Thrombectomy System following attempted aspiration thrombectomy.

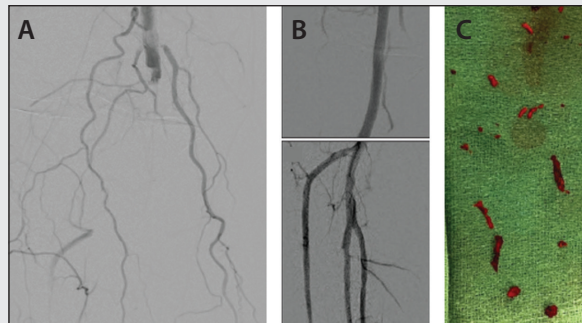


A man in his mid-70s presented to the clinic with a 2-day history of left calf pain and numbness in his foot. His history included smoking and hypertension but no known peripheral artery disease and no medication. Angiography showed embolus in the popliteal artery (A) with distal reconstitution (B). Aspiration thrombectomy failed to open flow to left foot. Two passes of the Pounce™ Thrombectomy System were performed through the TPT. Final angiography showed patent popliteal (C), anterior tibial (AT), and posterior tibial (PT) segments (D) with reconstitution into the foot (E).



See case

Figure 4. Removal of multivessel BTK thromboembolic arterial occlusion with three passes of the Pounce™ Thrombectomy System.



A man in his mid-70s presented with pain and paresthesia of his right foot. Symptoms started 1 day prior to arrival at the hospital. Diagnosis of new-onset AF was made. Initial angiography showed 100% thromboembolic occlusion of popliteal, TPT, peroneal, PT, and AT arteries (A). Pounce™ System baskets were deployed in mid-AT, with funnel in proximal AT, and first pass was made. The system was externalized and cleaned, and a second pass was made in the proximal PT, with funnel in proximal popliteal artery. After removal and cleaning, a third pass was made in the peroneal artery. Popliteal, TPT, and tibial arteries were patent after Pounce™ System passes (B). Clot removed with Pounce™ System (C).



See case

yet undiagnosed paroxysmal AF. Note restoration of right lower extremity (RLE) flow with three passes of the Pounce™ Thrombectomy System and restoration of left lower extremity flow with one pass.

Retrieval of infrapopliteal embolization following catheter-directed thrombolysis (CDT) and aspiration. As illustrated in Figure 6, ALI from embolic occlusions is typically associated with sudden and severe onset with a normal contralateral pulse exam.¹⁰ In this case, the patient's ankle-brachial index (ABI) was severely decreased to 0.35 (R) while the contralateral exam was normal at 1.0 (L). Overnight CDT and aspiration thrombectomy successfully cleared the soft thrombotic debris but were unsuccessful in removing above- and below-the-knee embolic components. The Pounce™ Platform succeeded in removing emboli in the superficial femoral artery (SFA), PT artery, and peroneal artery with one pass per vessel.

Removal of thrombus from dorsalis pedis (DP) artery. The Pounce™ LP System, indicated for peripheral arterial vessels 2 to 4 mm in diameter, is well sized for non-surgical removal of thrombi and emboli from distal and pedal vessels.¹¹ Figure 7 provides an

“Secondary thrombus may form both proximal and distal to the emboli, worsening the occlusion...”

“...the mechanical properties of spontaneous emboli—typically cardiogenic, fibrin-rich, and highly organized³—may challenge prompt restoration of flow...”

example of removal of a significant thrombotic occlusion in the DP artery with two passes of the Pounce™ LP System.

DISCUSSION

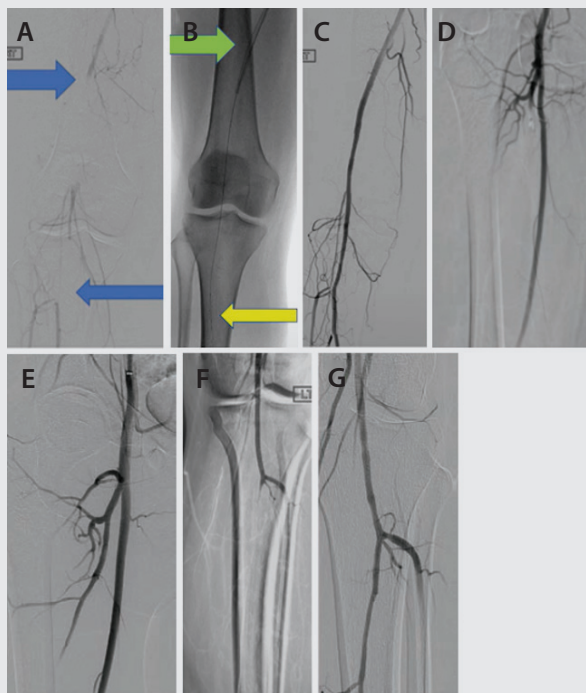
While open surgical embolectomy remains a dependable approach for achieving prompt revascularization, it is associated with significant morbidity and mortality in the frail



See video presentations of cases performed with the Pounce™ Thrombectomy Platform.



Figure 5. Removal of bilateral embolization using the Pounce™ Thrombectomy System.



A woman in her mid-40s who presented with increasing right calf pain of 4 weeks duration had ABI 0.5 (R) and 1.1 (L) on examination. RLE thrombectomy: Two-segment popliteal artery occlusion (A). Pounce™ System deployed with basket wire distal to popliteal occlusions and funnel catheter proximal to occlusions (B). Popliteal flow restored with three passes of the Pounce™ System (C). Filling defect in the right profunda femoris artery (D). Flow restored with one Pounce™ System pass (E). Left lower extremity thrombectomy: TPT occlusion (F). Flow restored with one Pounce™ System pass (G).



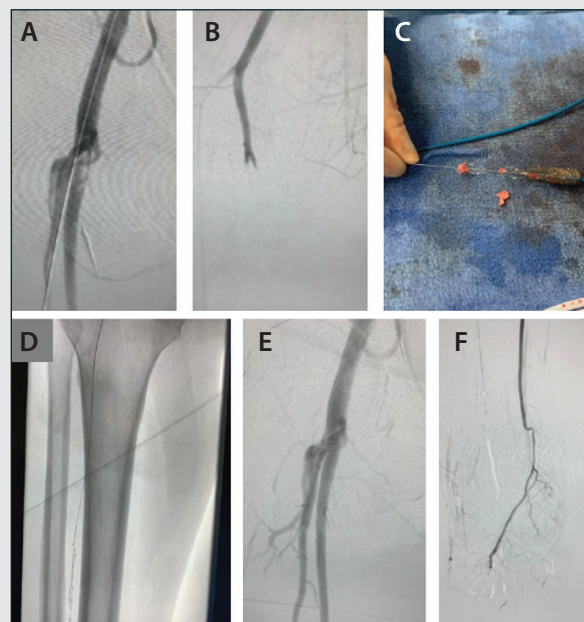
[See case](#)

“The Pounce™ Thrombectomy Platform [was] inspired by the Fogarty catheter’s mode of action...”

ALI population.¹² For removal of below-the-knee emboli, open embolectomy may require infrageniculate exposure under general anesthesia, and the blind nature of standard open surgical thromboembolectomy may make catheter introduction and entry into the branches of small arteries particularly challenging.¹³

The Pounce™ Thrombectomy Platform was originally conceived as a percutaneous alternative to open

Figure 6. Removal of multisite arterial emboli with the Pounce™ Thrombectomy System.



A woman in her mid-40s experienced sudden RLE coldness and numbness and fell to the ground while walking. On examination, ABI was 0.35 (R) and 1.0 (L). Initial imaging showed embolus at the distal common femoral artery (CFA), occluding the profunda and SFA (A). Large embolic burden was also present in the proximal and mid SFA with a secondary occlusive embolus at the tibial trifurcation (B). Overnight CDT resulted in minor improvement in the SFA and profunda artery, with continued occlusion at the trifurcation. Following unsuccessful continuation of overnight CDT, aspiration thrombectomy restored flow in the profunda artery but failed to remove embolus in SFA. The physician was in-serviced on the Pounce™ Thrombectomy System for the first time. The Pounce™ System baskets were deployed in the mid-SFA, the funnel in the distal CFA, and the system captured and removed the thrombus (C), restoring patency to the SFA and profunda artery (D). Subsequent single passes were made in the PT (E) and peroneal arteries, restoring runoff to the foot (F).

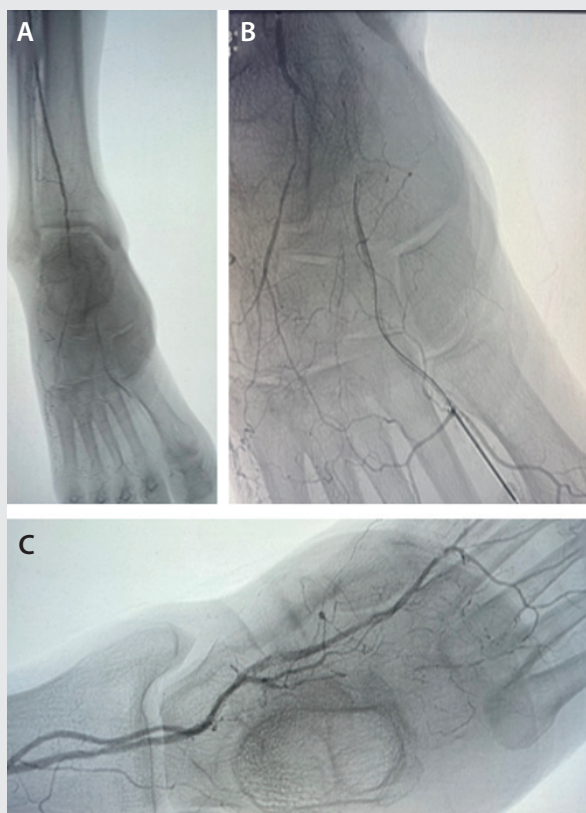


[See case](#)

thromboembolectomy. From the start, the platform’s design specifications called for use of wall-apposed, clot-engagement baskets effective at removing organized thrombi and emboli without aspiration and its associated blood loss, all without the need for capital equipment. The device had to be atraumatic to the vessel wall and capture clot into a proximal enveloping funnel with low risk of distal embolization while removing the clot-burdened system through a conventional access sheath.



Figure 7. Removal of DP thrombus with the Pounce™ LP Thrombectomy System.*



A woman in her late 60s presented to the clinic with right first toe gangrene and severe below-the-ankle disease. Initial angiography showed significant occlusion of the right proximal DP artery (A, B). Plain balloon angioplasty produced an unsatisfactory result. The Pounce™ LP System was introduced, with baskets deployed in the distal DP artery and the funnel deployed in the AT artery. Two passes were made with the Pounce™ LP System, achieving restoration of flow in the pedal loop (C) with palpable pulse after thrombus removal.

Device length had to be sufficient for the baskets to reach below-the-knee arteries within indicated diameter ranges from contralateral access. The wire component was developed with .035 PTA balloon catheter compatibility, which could aid with organized clot disruption for more efficient removal. Finally, the platform had to be simple to use and readily deployable. These attributes are all realized in the Pounce™ Platform. The safety, efficacy, and speed of the Pounce™ Thrombectomy Platform is supported by data from the multicenter, all-comers Pounce™ Platform PROWL registry.

Real-world limb ischemia population. An interim analysis of the PROWL registry presented in November 2025 evaluated Pounce™ Platform performance in 160 patients with

“The safety, efficacy, and speed of the Pounce™ Thrombectomy Platform is supported by data from the multicenter, all-comers Pounce™ Platform PROWL registry.”

thromboembolic limb ischemia in native infrainguinal vessels.⁷ Nearly half of acute patients in this population had immediately threatened limbs (> Rutherford IIa), while over 40% presented with > 2 weeks of symptoms, a reflection of the heterogeneous clinical presentations seen in real-world treatment of peripheral ischemic events.¹⁴ Approximately half of the patients had diabetes, roughly one-quarter exhibited renal insufficiency, and the majority had a history of underlying peripheral artery disease. In this vulnerable population, the Pounce™ Platform was well tolerated, with only one patient experiencing a device-related adverse event.[†] There were no reports of device-related distal embolization.[‡] There were no device-related deaths.

Efficacy and speed. Over 90% of patients experienced final core lab-adjudicated postprocedural TIPI (thrombolysis in peripheral ischemia) 2 to 3 blood flow restoration. Device technical success, defined as restoration of blood flow to the target lesion(s) with < 50% residual obstruction without the need of other therapies, was achieved in over 80% of cases. Average Pounce™ Platform use time in the study was under 25 minutes with a median of two passes per patient.

CONCLUSION

The Pounce™ Thrombectomy Platform represents an attractive percutaneous alternative to open embolectomy for embolic as well as thrombotic limb ischemia, even in infrapopliteal vessels. The platform's safety, efficacy, and speed for non-surgical removal of thrombi and emboli from the peripheral arterial vasculature of real-world, vulnerable limb ischemia patients are supported by a strong body of evidence from the PROWL registry. In a health care landscape inundated with novel devices, the simple and readily deployable Pounce™ Platform represents a groundbreaking solution for prompt flow restoration in limb ischemia. ■

**Presented by Dr. Lucas Ferrer Cardona at an industry-sponsored session at the 2025 Vascular Annual Meeting (VAM) of the Society for Vascular Surgery.*

†Flow-limiting dissection followed by clinically driven target lesion revascularization.

‡Distal embolization requiring surgical procedure or obstructing one of the major downstream vessels > 70% at the end of the procedure.

1. Björck M, Earnshaw JJ, Acosta S, et al. Editor's choice—European Society for Vascular Surgery (ESVS) 2020 clinical practice guidelines on the management of acute limb ischaemia. *Eur J Vasc Endovasc Surg*. 2020;59:173-218. doi: 10.1016/j.ejvs.2019.09.006
2. Olinic DM, Stanek A, Tătaru DA, et al. Acute limb ischemia: an update on diagnosis and management. *J Clin Med*. 2019;8:1215. doi: 10.3390/jcm8081215
3. Jolugbo P, Ariëns RA. Thrombus composition and efficacy of thrombolysis and thrombectomy in acute ischemic stroke. *Stroke*. 2021;52:1131-1142. doi: 10.1161/STROKEAHA.120.032810
4. de Athayde Soares R, Matielo MF, Neto FC, et al. Analysis of the results of endovascular and open surgical treatment of acute limb ischemia. *J Vasc Surg*. 2019;69:843-849. doi: 10.1016/j.jvs.2018.07.056
5. Lopez R, Yamashita TS, Neisen M, et al. Single-center experience with Indigo aspiration thrombectomy for acute lower limb ischemia. *J Vasc Surg*. 2020;72:226-232. doi: 10.1016/j.jvs.2019.10.079
6. Rossi M, Tipaldi MA, Tagliaferro FB, et al. Aspiration thrombectomy with the Indigo System for acute lower limb ischemia: preliminary experience and analysis of parameters affecting the outcome. *Ann Vasc Surg*. 2021;76:426-435. doi: 10.1016/j.avsg.2021.04.016
7. Lyden S, Campbell J, Monteleone P. Real-world clinical outcomes and case insights of the novel Pounce™ Thrombectomy Platform. Presented at: Vascular InterVentional Advances (VIVA) 2025; November 3, 2025; Las Vegas, Nevada.
8. McNally MM, Unvers J. Acute limb ischemia. *Surg Clin North Am*. 2018;98:1081-1096. doi: 10.1016/j.suc.2018.05.002
9. Becquemini JP, Kovarsky S. Arterial emboli of the lower limbs: analysis of risk factors for mortality and amputation. *Ann Vasc Surg*. 1995;9:532-38. doi: 10.1016/S0890-5096(06)60449-4
10. O'Connell JB, Quiñones-Baldrich WJ. Proper evaluation and management of acute embolic versus thrombotic limb ischemia. *Semin Vasc Surg*. 2009;22:10-16. doi: 10.1053/j.semvasc.2008.12.004
11. Chamseddine H, Halabi M, Shepard A, et al. Limb salvage using Pounce LP mechanical thrombectomy system after failed open and percutaneous thromboembolism. *J Vasc Surg Innov Tech*. 2025;11:101935. doi: 10.1016/j.jvsct.2025.101935
12. Kempe K, Starr B, Stafford JM, et al. Results of surgical management of acute thromboembolic lower extremity ischemia. *J Vasc Surg*. 2014;60:702-707. doi: 10.1016/j.jvs.2014.03.273
13. Chahrour MA, Berri N, Jaafar R, et al. Thromboembolism for acute lower limb ischemia: Contemporary outcomes of two surgical methods from a single tertiary center. *Vascular*. 2023;31:489-495. doi: 10.1177/17085381221075478
14. Howard DP, Banerjee A, Fairhead JF, et al. Population-based study of incidence, risk factors, outcome, and prognosis of ischemic peripheral arterial events: implications for prevention. *Circulation*. 2015;132:1805-1815. doi: 10.1161/CIRCULATIONAHA.115.016424

Gary Ansel, MD, inventor of the Pounce Thrombectomy System, is an interventional cardiologist and former system medical chief for the vascular program at OhioHealth and Assistant Clinical Professor of Medicine at the University of Toledo Medical Center. He is a consultant/on advisory board for Cook Medical, Surmodics, Otsuka/Veryan Medical, Reflow Medical, and Akura.

Cyrus Rezvanifar, PhD, MBA is Senior Product Manager at Surmodics.

Caution: Federal (US) law restricts the Pounce™ Thrombectomy System to sale by or on the order of a physician. Please refer to the product's Instructions for Use for indications, contraindications, warnings, and precautions. SURMODICS, POUNCE, and SURMODICS and POUNCE logos are trademarks of Surmodics, Inc. and/or its affiliates. Third-party trademarks are the property of their respective owners.



The Pounce™ LP System: An Essential Tool for BTK Revascularization

A conversation with Dr. Suyue Zhang.

Vascular surgeon **Dr. Suyue Zhang** is a Clinical Assistant Professor in the Department of Surgery at UT Southwestern Medical Center, where he specializes in complex aortic pathologies, dialysis access, and limb salvage. He also sees patients at Texas Health Presbyterian Hospital Dallas, which receives limb salvage transfers from across the Dallas metroplex, and at Parkland Health, where he sees Dallas County patients, many of them low income and uninsured. As a general surgery resident at the University of Illinois Metropolitan Group program, Dr. Zhang received the Robert M. Gasior MD Award for Clinical Excellence and Humanitarianism. We spoke with him about his experience using the Pounce™ Thrombectomy Platform (Surmodics, Inc.) for removal of peripheral embolic and thrombotic arterial occlusions.

How would you describe your limb salvage practice?

About 90% of the limb patients I see have chronic limb-threatening ischemia (CLTI), often with wounds and rest pain. These patients are generally elderly, very sick, with many comorbidities. For our practice, percutaneous treatment is usually a better option than an open solution because of the frailty of our patients, and we've become very facile at endovascular interventions.

For people with CLTI, even a small, organized thrombus from ruptured plaque or a small cardiogenic embolus can completely occlude the small flow channels in their very diseased vessels, converting stable peripheral artery disease into acute limb ischemia. Before the Pounce™ Platform came to market, I didn't know of any other device that was reliably effective for removing these kinds of organized clots, particularly below the knee. It works phenomenally for these cases.

What do you like about the Pounce™ Thrombectomy Platform?

I find that I can get durable results without many device passes.^{1*} That saves me operative time and saves operating

"As a surgeon, I'm very used to the Fogarty embolectomy catheter, and I find that the Pounce™ Platform provides similar tactile feedback."

room costs. I also like the tactile component of this device. As a surgeon, I'm very used to the Fogarty embolectomy catheter, and I find that the Pounce™ Platform provides similar tactile feedback. I can tell when I've crossed a lesion, and I may even be able to tell when I've dislodged an occlusion. That adds another dimension to my technique.

Having a tool such as the Pounce™ Platform also provides a salvage therapy when you're performing recanalization with balloons, stents, or atherectomy. For example, your patient may have one-vessel runoff to the foot, and you run the risk of embolizing into that single vessel when you're treating proximally. It's very helpful to have the Pounce™ Platform on hand for these kinds of situations and may even allow you to be a little more aggressive with your therapies.

"Having a tool such as the Pounce™ Platform also provides a salvage therapy when you're performing recanalization with balloons, stents, or atherectomy."



What have you found to be the shortcomings of other percutaneous thrombectomy devices?

In my experience, aspiration systems have a tough time dislodging embolic occlusions, which tend to be well-organized and rubbery. They can take care of soft, acute thrombus, but if there's something really lodged in there, I have found myself suctioning at the clot without effectively dislodging and removing it. If you're not dislodging organized clot, I've also found that you run the risk of simply pushing the clot downward, since you're pushing the catheter in that direction. When I deploy the Pounce™ Thrombectomy Platform, the baskets mechanically engage the organized clot to dislodge and mobilize clot toward the funnel. Also, I've already crossed the occlusion with the basket wire and low-profile delivery catheter and am drawing back on the clot with the baskets from a distal position, reducing the risk of distal embolization.

There's also the issue of blood loss with extended use of continuous aspiration thrombectomy.² Historically, rheolytic thrombectomy has been fairly effective and could serve as a fall back if aspiration did not succeed, but it is associated with acute kidney injury.³ The Pounce™ Platform can remove clot mechanically without using aspiration or thrombolytics. All of these issues in combination make the Pounce™ Platform a very compelling solution.

Can you tell us more about the case reports you provided and why you selected the Pounce™ Platform for these cases?

In the first case (page 10), we had a fairly young patient, but she was a former smoker with coronary artery disease. It's probable she had a thrombotic event from plaque rupture. She had popliteal and tibial occlusions with some distal reconstitution, which is very common in my practice. I chose the Pounce™ Platform because I have not found other effective endovascular

options in the popliteal and below-the-knee space. I also considered an open cutdown, but I've found that the Pounce™ LP System (indicated for 2-4 mm vessels) allows me to effectively clean clot from tibial vessels and recruit outflow. As it turned out, the anterior tibial vessel was chronically occluded. While we opened it during the procedure, it didn't stay open. However, we were still able to return her to her prior baseline without an open incision.

In the second case (page 11), I knew this patient had an embolic occlusion. I chose the Pounce™ Platform for the same reason as in the first case: it allows me to treat several vessels in a very short time. It's become an essential part of my toolkit. ■

**In a November 2025 interim analysis¹ of 160 patients with native infrainguinal vessel limb ischemia treated with the Pounce™ Platform in the PROWL registry, over 90% of patients experienced final core lab–adjudicated post-procedural TIPI (thromboaspiration in peripheral ischemia) 2-3 blood flow restoration. Average Pounce™ Platform use time in the study was under 25 minutes with a median of two passes per patient.*

1. Lyden S, Campbell J, Monteleone P. Real-world clinical outcomes and case insights of the novel Pounce™ Thrombectomy Platform. Presented at: Vascular Interventional Advances (VIVA) 2025; November 3, 2025; Las Vegas, Nevada.
2. Maldonado TS, Powell A, Wendorff H, et al. Safety and efficacy of mechanical aspiration thrombectomy for patients with acute lower extremity ischemia. *J Vasc Surg.* 2024;79:584-592.e5. doi: 10.1016/j.jvs.2023.10.062
3. Acosta S, Karonen E, Eek F, Butt T. Short-term complications and outcomes in pharmaco-mechanical thrombolysis first and catheter-directed thrombolysis first in patients with acute lower limb ischemia. *Ann Vasc Surg.* 2023;94:253-262. doi: 10.1016/j.avsg.2023.02.018



Suyue Zhang, MD

Vascular Surgeon
UT Southwestern Medical Center
Dallas, Texas
Disclosures: None.

Caution: Federal (US) law restricts the Pounce™ Thrombectomy System to sale by or on the order of a physician. Please refer to the product's Instructions for Use for indications, contraindications, warnings, and precautions. SURMODICS, POUNCE, and SURMODICS and POUNCE logos are trademarks of Surmodics, Inc. and/or its affiliates. Third-party trademarks are the property of their respective owners.



CASE REPORT

Prompt Resolution of Acute Popliteal and Infrapopliteal Arterial Occlusions With the Pounce™ LP Thrombectomy System

By Suyue Zhang, MD

PATIENT PRESENTATION

A woman in her early 40s with coronary artery disease, hyperlipidemia, chronic kidney disease stage 3a, type 2 diabetes mellitus, and a former smoker presented with 1 day of right lower extremity pain.

DIAGNOSTIC FINDINGS

On examination, the right leg was cooler than the left with right foot numbness. Doppler signals revealed a faint monophasic dorsalis pedis (DP) pulse and absent posterior tibial (PT) signal on the right, compared with monophasic DP and multiphasic PT signals on the left, consistent with Rutherford category 2a ischemia. Initial angiography showed occlusion of the popliteal artery, with associated anterior tibial (AT) artery occlusion, and occlusion of the proximal tibioperoneal trunk (TPT), with distal TPT recanalization (Figure 1).

TREATMENT

Contralateral groin access was achieved, a 7 Fr, 65 cm Destination™ Peripheral Guiding Sheath (Terumo Interventional Systems) was advanced, and the lesion was crossed using a

0.018" Glidewire Advantage® Peripheral Guidewire (Terumo Interventional Systems), followed by thrombectomy with the Pounce™ LP (Low-Profile) Thrombectomy System (Surmodics, Inc.). Two passes with the Pounce™ LP System were made in the TPT to the PT artery and four passes were made in the AT artery, with adjunctive plain balloon angioplasty. Final angiography showed restoration of below-the-knee flow (Figure 2).

POSTPROCEDURE OUTCOMES

The patient experienced postoperative resolution of pain and numbness, tolerated the procedure well, and was discharged uneventfully on postoperative day 4. The Pounce™ LP Thrombectomy System removed acute popliteal and infrapopliteal arterial thrombus.

Follow-up diagnostic angiography 3 months later, prompted by a toe ulcer, demonstrated a patent popliteal artery and PT but persistent AT occlusion as evidenced by the initial angiogram AT occlusion. Although the Pounce™ LP System, aided with angioplasty, was able to initially open the AT, patency was limited in the diseased vessel. ■

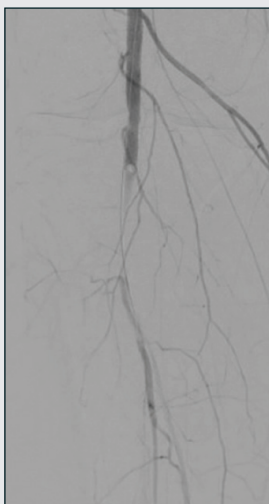

Figure 1. Initial angiography showing popliteal artery occlusion with associated AT occlusion and occlusion of the proximal TPT, with distal TPT recanalization.

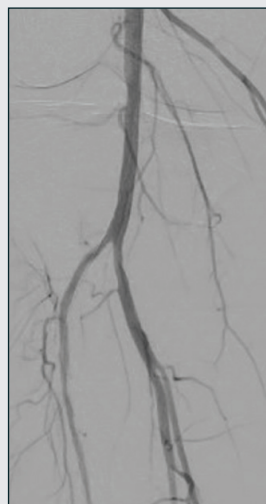

Figure 2. Final angiography showing postprocedure restoration of below-the-knee flow.

Caution: Federal (US) law restricts the Pounce™ Thrombectomy System to sale by or on the order of a physician. Please refer to the product's Instructions for Use for indications, contraindications, warnings, and precautions. SURMODICS, POUNCE, and SURMODICS and POUNCE logos are trademarks of Surmodics, Inc. and/or its affiliates. Third-party trademarks are the property of their respective owners.

CASE REPORT

Removal of Below-the-Knee Embolic Arterial Occlusion With Two Passes of the Pounce™ LP Thrombectomy System

By Suyue Zhang, MD

PATIENT PRESENTATION

A woman in her mid-60s who had initially undergone left lower extremity (LLE) thrombectomy with the Indigo® Aspiration System (Penumbra, Inc.) for embolic disease subsequently developed rest pain in the right lower extremity (RLE). Patient history included hypertension, hyperlipidemia, type 2 diabetes mellitus, atrial fibrillation (previously anticoagulated with warfarin but held due to intracranial hemorrhage), mitral valve stenosis, and prior left pontine cerebrovascular accident with resultant right hemiparesis and respiratory failure requiring tracheostomy and percutaneous endoscopic gastrostomy.

DIAGNOSTICS AND TREATMENT

Angiography of the RLE showed embolic occlusion of the distal popliteal artery at the anterior tibial (AT) takeoff (Figure 1). Contralateral groin access was achieved, and a 7 Fr, 65 cm Destination™ Peripheral Guiding Sheath (Terumo Interventional Systems) was placed. A 018 Glidewire Advantage® Peripheral

Guidewire (Terumo Interventional Systems) was advanced and crossed the lesion, and thrombectomy was performed with the Pounce™ LP (Low-Profile) Thrombectomy System (Surmodics, Inc.). One pass was made in the AT and one pass in the tibioperoneal trunk, achieving successful embolectomy. Completion angiography confirmed three-vessel distal runoff (Figure 2), with intravascular ultrasound showing no residual thrombus.

POSTPROCEDURE OUTCOMES

At 4-month follow-up, the patient was free of rest pain. She remained nonambulatory due to her prior strokes, but ankle-brachial index testing revealed preserved toe pressure of 96 mm Hg on the treated side despite noncompressible arteries. The Pounce™ LP Thrombectomy System succeeded in removing two embolic below-the-knee arterial occlusions with only two total device passes. ■

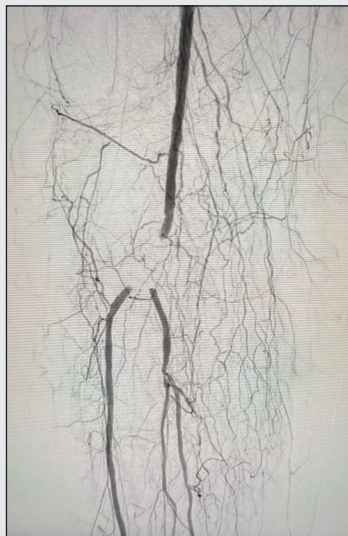


Figure 1. Initial angiography showing embolic occlusion of the RLE distal popliteal artery at the AT takeoff.

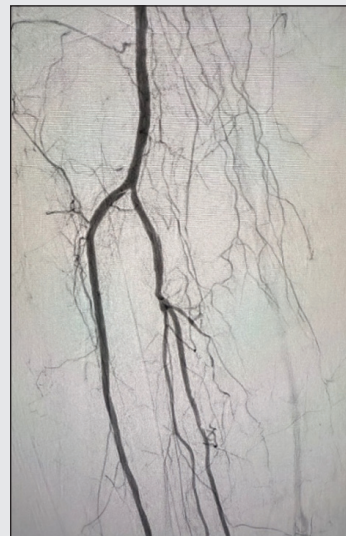

Figure 2. Completion angiography confirming three-vessel distal runoff.

Caution: Federal (US) law restricts the Pounce™ Thrombectomy System to sale by or on the order of a physician. Please refer to the product's Instructions for Use for indications, contraindications, warnings, and precautions. SURMODICS, POUNCE, and SURMODICS and POUNCE logos are trademarks of Surmodics, Inc. and/or its affiliates. Third-party trademarks are the property of their respective owners.



Peripheral Arterial Thrombus Removal Above or Below the Knee Using the Pounce™ Thrombectomy Platform

A conversation with Dr. Amanjit S. Baadh.

Dr. Amanjit S. Baadh is trained in vascular medicine and interventional radiology and practices with Midwest Radiology. He is affiliated with several major medical centers in the Minneapolis/St. Paul metro area. His work focuses on medical management and minimally invasive treatment for peripheral artery disease (PAD), with an emphasis on limb salvage for chronic limb-threatening ischemia (CLTI). A contributor to the field, Dr. Baadh has coauthored several papers in peer-reviewed journals. In 2022, he was recognized as a “Top Doctor Rising Star” by *Mpls.St.Paul Magazine*.

In terms of limb salvage, how would you describe the patient population you treat in your practice?

The patients we see in clinic are typically diabetic, with a fair number of chronic renal failure patients on dialysis. A lot of these folks have had PAD for many years, and they’ve developed a wound. We work closely with podiatry and other specialties to optimize their care. In terms of revascularization, we try to keep people out of the hospital, but some patients we see have rest pain or rapid worsening of their wounds that has brought them into the emergency department. These inpatients tend to be farther along in their disease course.

What has been your traditional approach to peripheral arterial revascularization?

Many CLTI patients we see have chronic plaques and disease that may lead to in situ thrombosis or acute worsening of disease. Our treatment approach depends on patient presentation and the amount of time we feel we have to revascularize. For Rutherford class 1 or 2a patients, we traditionally used thrombolytics as the primary treatment, followed by angioplasty, stenting, or additional clot clearance. We also used aspiration thrombectomy, but these devices were often not amenable to removing organized material.

“The availability of the Pounce™ Platform has changed our approach.”

What role does the Pounce™ Thrombectomy Platform (Surmodics, Inc.) play in your practice?

The availability of the Pounce™ Platform has changed our approach. You really don’t know how old clot will be in any given patient. There have also been times when I thought a clot would be fresh but couldn’t remove it using thrombolytics or aspiration. When I removed the clot using the Pounce™ Platform, it turned out to be organized and rubbery. As we’ve gained experience with the Pounce™ Platform, we’ve increasingly used it as a primary treatment.

Having said that, if there’s a high volume of clot or occlusion of small distal vessels, we may still use lytics or aspiration devices. It’s good to have all these tools available so you can customize your approach. The Pounce™ Platform includes systems with different basket sizes, including the Pounce™ LP System, which is indicated for arterial vessels 2 to 4 mm in diameter. Having multiple sizes available in the Pounce™ Platform is very helpful for complex cases with multiple occluded vessels above and below the knee (see page 13). ■



Amanjit S. Baadh, MD
Interventional Radiologist
Midwest Radiology
Roseville, Minnesota
Disclosures: None.

Caution: Federal (US) law restricts the Pounce™ Thrombectomy System to sale by or on the order of a physician. Please refer to the product’s Instructions for Use for indications, contraindications, warnings, and precautions. SURMODICS, POUNCE, and SURMODICS and POUNCE logos are trademarks of Surmodics, Inc. and/or its affiliates. Third-party trademarks are the property of their respective owners.



CASE REPORT

Use of the Pounce™ and Pounce™ LP Thrombectomy Systems to Remove Lower Extremity Arterial Thrombus Following Attempted Aspiration Thrombectomy and Thrombolysis

By Amanjit S. Baadh, MD

PATIENT PRESENTATION

An active man in his early 50s with no known comorbidities presented to the clinic with left leg claudication of several weeks' duration. The patient had previously been misdiagnosed with shin splints at a primary care facility and been provided with a walking boot. When his symptoms persisted, he received a duplex ultrasound (DUS) examination that showed left popliteal and infrapopliteal thrombosis. He was referred to the emergency department (ED).

DIAGNOSTIC FINDINGS

In the ED, the patient received a CTA examination that confirmed the DUS results, showing occlusion of the left P1 popliteal artery extending into the infrapopliteal vessels with reconstituted flow in the posterior tibial (PT) artery. The patient's motor and sensory function remained intact.

TREATMENT

Following unsuccessful aspiration thrombectomy, the patient was admitted to the intensive care unit for overnight catheter-directed thrombolysis (CDT). At 21.5 hours, the popliteal artery segment remained occluded, with limited flow into the reconstituted PT artery

completely occluding at the ankle level. Peroneal, anterior tibial, and pedal arteries were occluded. Overnight CDT was again attempted, but little change was noted following an additional 22.5 hours of thrombolytic therapy (total of 44 hours of CDT) (Figure 1). As the next step in treatment, a 7 Fr guiding sheath and a crossing catheter were introduced from contralateral femoral access, and angioplasty was performed at nominal pressure using a 5 X 40 mm balloon to disrupt clot in the popliteal vessel. The Pounce™ Thrombectomy System (3.5-6 mm) (Surmodics, Inc.) was then deployed in the popliteal segment, removing clot and achieving flow into the PT artery (Figure 2). The Pounce™ LP (Low-Profile) System (2-4 mm) was then used to remove mixed-morphology clot (Figure 3) from the plantar artery (Figure 4A) and tibial arteries (Figure 4B), restoring flow to the foot (Figure 4C).

POSTPROCEDURE OUTCOMES

The patient was discharged from the hospital with prescribed oral anticoagulation. Use of the Pounce™ System and Pounce™ LP System removed lower extremity arterial thrombus, which restored inline flow in a patient at risk of amputation following unsuccessful CDT and aspiration thrombectomy. ■

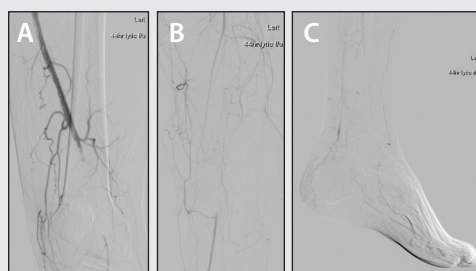


Figure 1. Angiography showing occluded left popliteal (A), tibial (B), and plantar (C) arteries following 44 hours of thrombolytic therapy.

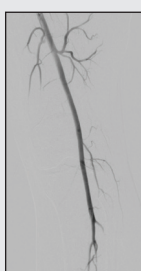


Figure 2. Restoration of left popliteal arterial flow following Pounce™ System thrombectomy.

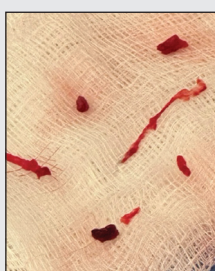

Figure 3. Mixed-morphology clot removed from plantar and tibial arteries using the Pounce™ LP Thrombectomy System.

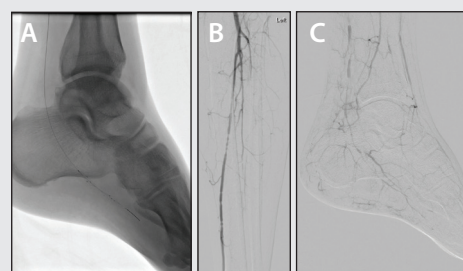


Figure 4. Deployment of Pounce™ LP System baskets in the left plantar artery (A). Restoration of tibial (B), and pedal (C) arterial flow following Pounce™ LP System thrombectomy.

Caution: Federal (US) law restricts the Pounce™ Thrombectomy System to sale by or on the order of a physician. Please refer to the product's Instructions for Use for indications, contraindications, warnings, and precautions. SURMODICS, POUNCE, and SURMODICS and POUNCE logos are trademarks of Surmodics, Inc. and/or its affiliates. Third-party trademarks are the property of their respective owners.



With a combined vessel diameter range of 2–10mm, the **Pounce™ Thrombectomy Platform** provides a standalone solution for rapid removal of peripheral arterial thrombi and emboli throughout the lower and upper extremities.

2–10MM COMBINED VESSEL DIAMETER RANGE



PTS-0407-7F150

2–4mm

- ✓ 7 Fr Compatible
- ✓ 320 cm Basket Wire
- ✓ 150 cm Delivery Catheter



PTS-0607-7F135

3.5–6mm

- ✓ 7 Fr Compatible
- ✓ 300 cm Basket Wire
- ✓ 135 cm Delivery Catheter



PTS-1011-7F135

5.5–10mm

- ✓ 7 Fr Compatible
- ✓ 300 cm Basket Wire
- ✓ 135 cm Delivery Catheter



For more information about the Pounce Platform, scan the QR code or visit pounceplatform.com

Readily Deployable, Simple to Use



Acute or chronic thrombi or emboli



No thrombolytics required—optimizes single-session treatment



Low risk of distal embolization^{1*}



No aspiration used for clot removal—minimizes blood loss

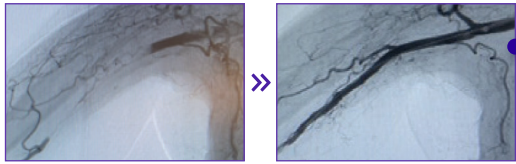


Atraumatic—low risk of flow-limiting dissection^{1†}

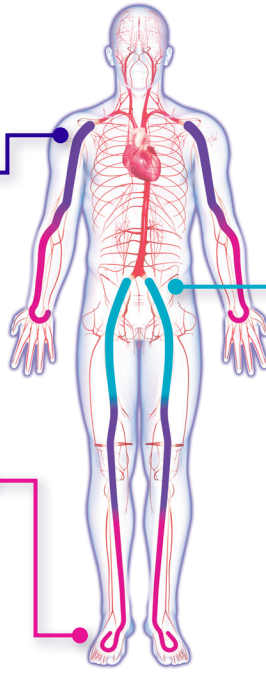
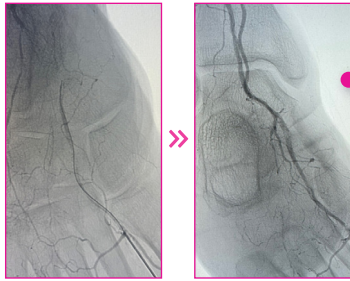
1. Interim results from 160 patients with native infrainguinal vessel limb ischemia. Lyden S, Campbell J, Monteleone P. Real-world clinical outcomes and case insights of the novel Pounce™ Thrombectomy Platform [presentation]. 23rd Annual VIVA Conference; November 3, 2025; Las Vegas, NV.

2. Bacharach MJ, Bacharach T. Successful Removal of 20 cm SFA Thrombus With the Pounce™ Thrombectomy System. Endovascular Today. 2022;21(12 Suppl):S12-13.

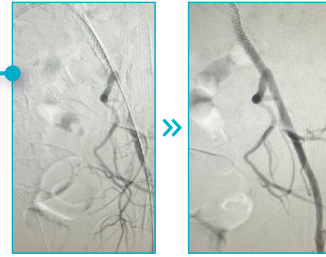
Pounce Thrombectomy **3.5-6mm**



Pounce Thrombectomy **LP 2-4mm**




Pounce Thrombectomy **XL 5.5-10mm**



See more **case reports** using the Pounce Platform in lower and upper extremities




Integrated handle with *slider button* for sheathing and unsheathing funnel



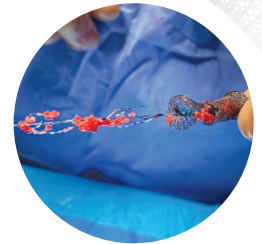
Dual nitinol self-expanding baskets for capturing thrombus

Tapered tip includes a safety coil for atraumatic delivery

Nitinol funnel to capture baskets and entrain clot



Components under fluoroscopy



Clot removed after initial pass of the Pounce System²

PROWL REGISTRY

Real-world data on the **Pounce™ Thrombectomy System** for the non-surgical removal of emboli and thrombi in the peripheral arterial vasculature. NCT05868161

Decide with Data:
Latest PROWL
Registry Results >>



* In an interim analysis of 74 patients with native infrainguinal vessel limb ischemia in the PROWL registry, no device-related distal embolization requiring surgical procedure or obstructing one of the major downstream vessels >70% (at the end of the procedure) was reported.

† One flow-limiting dissection was reported in an interim analysis of 74 patients with native infrainguinal vessel limb ischemia in the PROWL registry. No device-related perforations or major bleeding (requiring transfusion) were reported.



- ✓ 2-4mm
- ✓ 7 Fr Compatible
- ✓ 320 cm Basket Wire
- ✓ 150 cm Delivery Catheter



READY TO DEFEAT COLD FEET? JOIN THE HUNT.

Go Up and Over and Reach the *Pedal Loop!*

The **Pounce™ LP (Low-Profile) Thrombectomy System** is designed to reach and rapidly remove organized clot and acute-to-chronic thrombi and emboli in the tibial arteries (2-4mm).

Organized BTK Arterial Clot?

#POUNCEIT

Contact **Customer Care at 888-626-8501** or scan the QR code to try the power of the Pounce LP System.



qrco.de/DefeatColdFeet

Caution: Federal (US) law restricts this device to sale by or on the order of a physician. Please refer to Instructions for Use for indications, contraindications, warnings, and precautions.

SURMODICS, POUNCE and the SURMODICS and POUNCE logos are trademarks of Surmodics, Inc. and/or its affiliates.
©2026 Surmodics, Inc. All rights reserved. SRDX-PTS-1345 A 05/26