

The Shifting Paradigm in Carotid Revascularization: TCAR in Real-World Practice

BY MARC SCHERMERHORN, MD, AND PATRIC LIANG, MD

The treatment of carotid artery stenosis has seen considerable change and evolution in recent years but is now primed for a clearer pathway into the endovascular world with the introduction of transcrotid artery revascularization (TCAR).

Initial concerns regarding transfemoral carotid artery stenting (TF-CAS) stemmed from peer-reviewed literature that pointed to evidence of higher rates of perioperative strokes and a significantly higher incidence of iatrogenic embolic shed after carotid stenting compared to the gold standard of carotid endarterectomy (CEA) (Table 1).^{1,2}

MOTIVATION AND RATIONALE FOR TCAR

TCAR with flow reversal was developed to mitigate the maneuvers at highest risk for causing stroke during TF-CAS, such as manipulation of a diseased aortic arch to cannulate the common carotid artery and crossing of the carotid lesion prior to deployment of an embolic protection device.

TCAR addresses these concerns by:

- Avoiding the aortic arch entirely via direct common carotid access through a small cutdown incision just above the clavicle
- Providing cerebral protection at the onset of the procedure prior to crossing the carotid lesion via the ENROUTE® Transcarotid Neuroprotection System

These neuroprotective effects from flow reversal have led to a decrease in perioperative cerebral embolic rates on diffusion-weighted imaging, approaching rates closer to those found with CEA.³

REAL-WORLD EVIDENCE OF TCAR SAFETY

Confirmation that TCAR with flow reversal is a safe carotid revascularization technique was demonstrated in recent studies using data from the Society for Vascular Surgery Vascular Quality Initiative (VQI) TCAR Surveillance Project (TSP). The VQI-TSP is an ongoing col-

TABLE 1. PEER-REVIEWED LITERATURE SHOWING POTENTIAL SAFETY CONCERNS FOR CAS VERSUS CEA

Data Source	Endpoint	Results
CREST trial ¹	30-day stroke after transfemoral stenting vs CEA	~Twofold increase for stroke rate in transfemoral stenting vs CEA (4.1% vs 2.3%; $P = .01$)
32-study meta-analysis ²	Iatrogenic embolic shed	On diffusion-weighted imaging, transfemoral stenting was associated with higher rates of iatrogenic embolic shed as compared to CEA (37% vs 10%; $P < .01$)

Abbreviations: CAS, carotid artery stenting; CEA, carotid endarterectomy.

TABLE 2. VQI-TSP INTERIM DATA FROM 1,182 TCAR PROCEDURES FROM JANUARY 2016 TO MARCH 2018

Endpoint	TCAR	CEA	P Value
In-hospital rates of stroke/death	1.6%	1.4%	$P = .33$
Operating time (min)	78	111	$P < .001$
Cranial nerve injury	0.6%	1.8%	$P < .001$

Abbreviations: CEA, carotid endarterectomy; TCAR, transcrotid artery revascularization; VQI-TSP, Vascular Quality Initiative TCAR Surveillance Project.

ENROUTE® TRANSCAROTID NEUROPROTECTION SYSTEM

Sponsored by Silk Road Medical

TABLE 3. VQI-TSP INTERIM DATA UPDATED TO INCLUDE 2,545 TCAR PROCEDURES⁵

Endpoint	Observation	Results
In-hospital rates of stroke/death	No significant difference between TCAR and CEA	(OR, 1.1; 95% CI, 0.8–1.5; $P = .60$)
In-hospital adverse neurologic events and TIA/stroke/death	Transfemoral carotid artery stenting associated with significantly higher odds compared to TCAR	(OR, 2.1; 95% CI, 1.1–4.1, $P = .03$)

Abbreviations: CEA, carotid endarterectomy; CI, confidence interval; OR, odds ratio; TCAR, transcatheter carotid artery revascularization; TIA, transient ischemic attack; VQI-TSP, Vascular Quality Initiative TCAR Surveillance Project.

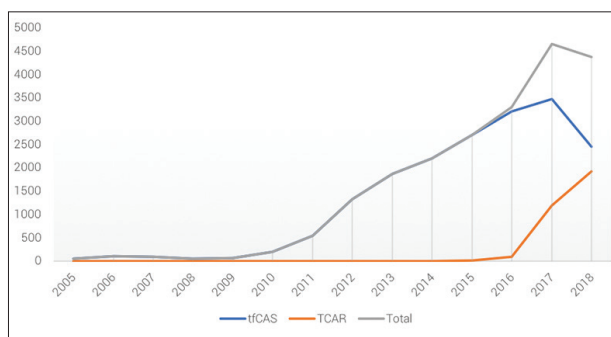


Figure 1. Trend in TCAR and TF-CAS utilization in the VQI.

laborative effort between the Society for Vascular Surgery, FDA, and the Centers for Medicare & Medicaid Services, designed to evaluate outcomes after TCAR in centers participating in the VQI. This large quality improvement data set allows for comparison of real-world outcomes of TCAR, transfemoral stenting, and CEA.

Using VQI-TSP interim data from 1,182 TCAR procedures from January 2016 to March 2018, TCAR was found to have similar outcomes to CEA (Table 2).

Even though TCAR is currently restricted to patients at high medical or anatomic risk, resulting in a sicker cohort, the similarity in stroke/death between the two techniques remained after multivariable adjustment of baseline comorbidities (odds ratio, 1.3; 95% confidence interval, 0.8–2.2; $P = .28$).⁴

Since the publication of these data, these findings have been confirmed using updated data of 2,545 TCAR procedures in the VQI-TSP. In a separate analysis, TCAR was found to be safer than TF-CAS, with TF-CAS associated with double the odds of in-hospital adverse neurologic events and transient ischemic attack, stroke, or death compared to TCAR (Table 3).⁵

SUMMARY

Considering this evidence, TCAR will undoubtedly become a tool that vascular surgeons should have in

their armamentarium to treat carotid disease. In fact, we have already seen an exponential increase in utilization of TCAR in the VQI and a downtrend in TF-CAS in 2018 (Figure 1). If further long-term data continue to support the benefits of TCAR over transfemoral stenting and the equivalence between TCAR and CEA, it is possible that the indication for TCAR will soon be expanded to serve as an option for normal-risk patients and become the predominant modality for interventional management of carotid disease. ■

1. Brott TG, Hobson RW 2nd, Howard G, et al. Stenting versus endarterectomy for treatment of carotid-artery stenosis [published errata appear in N Engl J Med. 2010;363:198 and 2010;363:498]. N Engl J Med. 2010;363:11–23.
2. Schnaudigel S, Gröschel K, Pilgram SM, Kastrup A. New brain lesions after carotid stenting versus carotid endarterectomy: a systematic review of the literature. Stroke. 2008;39:1911–1919.
3. Pinter L, Ribo M, Loh C, et al. Safety and feasibility of a novel transcervical access neuroprotection system for carotid artery stenting in the PROOF Study. J Vasc Surg. 2011;54:1317–1323.
4. Schermerhorn ML, Dakour-Arifi H, Kashyap VS, et al. VESSOS. In-hospital outcomes of transcatheter artery revascularization and carotid endarterectomy in the Society of Vascular Surgery Vascular Quality Initiative. J Vasc Surg. 2018;67:e50–e51.
5. Malas MB, Dakour-Arifi H, Wang GJ, et al. Transcatheter artery revascularization versus transfemoral carotid artery stenting in the Society for Vascular Surgery Vascular Quality Initiative. J Vasc Surg. 2019;69:92–103.e2.



Marc Schermerhorn, MD

George H.A. Clowes Jr. Professor of Surgery
Harvard Medical School
Chief, Vascular and Endovascular Surgery Department
Beth Israel Deaconess Medical Center
Boston, Massachusetts



Patric Liang, MD

Vascular Surgery Resident
Beth Israel Deaconess Medical Center
Fellow
T32 Harvard-Longwood Vascular Surgery Research Training Program
Boston, Massachusetts

Adopting TCAR Out of Vascular Surgery Fellowship

I graduated from a fellowship in vascular surgery and endovascular therapy at Baylor College of Medicine in Houston, Texas, in June 2018 and immediately started working as a vascular surgeon at Mercy Clinic in Springfield, MO. Since my arrival at Mercy, despite offering all four modalities of therapy (medical, CEA, TF-CAS, and TCAR), I have adopted TCAR as the primary modality for surgical treatment of patients with carotid artery occlusive disease. The rationale for this choice is that TCAR combines minimally invasive direct common carotid access with flow reversal during carotid artery angioplasty and stenting as a method of neuroprotection during intervention. In comparison with TF-CAS, TCAR eliminates aortic arch manipulation and unprotected lesion crossing, which are both responsible for a substantial percentage of periprocedural neurologic events during carotid stenting.¹

Although I graduated from fellowship having performed only four TCAR procedures, I had high exposure to both CEA and TF-CAS, allowing me to be comfortable with some key steps of TCAR (eg, neck cutdown, carotid clamping and stenting). I also attended the TCAR hands-on course in Chicago, Illinois, sponsored by Silk Road Medical. After my graduation from vascular surgery fellowship, I was fortunate to join a group of vascular surgeons at Mercy Clinic who have performed many TCAR procedures. Since my arrival at Mercy Clinic in July 2018, I have performed a total of 32 TCAR procedures with 100% technical success,

no perioperative ischemic strokes, a mean fluoroscopy time of 4.3 ± 3.7 min, a mean reverse flow time of 8.5 ± 10.2 min, mean contrast use of 17.6 ± 8.4 mL, and a mean procedure time of 49.2 ± 20.7 min.

In Southwest Missouri, we try to fulfill an acutely growing need for vascular care due to the aging population of this region and the increasing prevalence of chronic diseases such as diabetes and obesity, which affect the cardiovascular system. Our vascular outpatient clinic receives an average of 10 to 15 referrals per day, and many of these are for carotid artery occlusive disease. I choose TCAR as my primary approach to carotid revascularizations for these patients because it allows me to reduce surgical wait times for those requiring carotid surgery at our institution, offering equivalent outcomes to CEA.

Adopting TCAR has allowed me to provide surgical care for more patients per day, without compromising surgical outcomes. ■

1. Ansel GM, Hopkins LN, Jaff MR, et al. Safety and effectiveness of the INVATEC MO.MA proximal cerebral protection device during carotid artery stenting: results from the ARMOUR pivotal trial. *Catheter Cardiovasc Interv.* 2010;76:1-8.



Bernardino C. Branco Rocha, MD
Vascular Surgeon
Mercy Clinic
Springfield, Missouri

The authors of this article have received writing honoraria from Silk Road Medical.