

Considerations for the Near Future of Drug Delivery Devices Below the Knee

A global panel of limb salvage experts weighs in on the promise and pitfalls facing adoption of drug-based options.

**WITH MARIANNE BRODMANN, MD; ANTONIO MICARI, MD, PhD;
JIHAD A. MUSTAPHA, MD, FACC, FSCAI; AND RAMON L. VARCOE, MBBS, MS, FRACS, PhD**



Marianne Brodmann, MD
Substitute Head of the Clinical Division
of Angiology
Department of Internal Medicine
Medical University of Graz
Graz, Austria
marianne.brodmann@medunigraz.at
Disclosures: None.



Jihad A. Mustapha, MD, FACC, FSCAI
Advanced Cardiac & Vascular
Amputation Prevention Centers
Grand Rapids, Michigan
jmustapha@acvcenters.com
*Disclosures: Consultant to Bard, Boston
Scientific Corporation, Philips, and
Terumo Interventional Systems.*



Antonio Micari, MD, PhD
Interventional Cardiologist
Maria Cecilia Hospital
GVM Care and Research
Cotignola, Ravenna, Italy
micariantonio@gmail.com
*Disclosures: Consultant to Medtronic,
Boston Scientific Corporation, Terumo
Interventional Systems, InspireMD; advisory
board for Medtronic.*



**Ramon L. Varcoe, MBBS, MS,
FRACS, PhD**
Department of Surgery
The Vascular Institute
Prince of Wales Hospital
University of New South Wales
Sydney, Australia
r.varcoe@unsw.edu.au
*Disclosures: Consultant to Medtronic and
Abbott Vascular.*

How do your expectations for both short- and long-term outcomes for drug delivery devices below the knee (BTK) differ versus those in the superficial femoral artery (SFA), if at all?

Prof. Brodmann: For some time now, drug delivery has become standard of care for SFA/popliteal artery treatment; however, for BTK disease, we are still fighting for evidence. It is true that some drug-coated balloons (DCBs)

are available and approved for use in BTK arteries, but the usage in every day practice is reduced to a minor subset of patients, mainly those with a high rate of restenosis.

Dr. Varcoe: Treatment of peripheral artery disease (PAD) BTK is usually reserved for patients with critical limb ischemia (CLI), whereas most isolated SFA lesions are treated because of claudication. These two conditions are associated with very different treatment goals. In most cases, the goal of treating BTK lesions is to achieve ulcer healing and limb salvage, which is usually accomplished over the short to mid term. However, when treating the SFA, the goal is long-term symptom relief with associated ongoing improvements in quality of life.

The purpose of adding antiproliferative drug to angioplasty balloons and stents is to improve the patency of the intervention and reduce the need for target lesion revascularization (TLR). Although those two things are closely linked in the SFA, it is unusual for BTK patency loss to result in recurrent ulceration and the need for TLR. Therefore, patency itself may have little impact on limb salvage outcomes from long-segment BTK disease. In saying that, even though durability is less important BTK, if there were two options with one more durable than the other, it is that option that will be chosen every time.

Dr. Micari: First, we need to understand and learn how to use the drug delivery devices in the BTK setting. Elution itself is not straightforward due to calcification, sizing, and deliverability of the device. Only after understanding these issues will we obtain results similar to those found in the SFA.

Dr. Mustapha: Some of the pitfalls in the early trials of the SFA led to improved approaches to drug delivery to the SFA and popliteal artery, including the need for vessel preparation, appropriate balloon-to-vessel ratio sizing, adherence to the time transition of the DCB to the target lesion in a timely fashion, immediate balloon inflation, and maintaining balloon inflation for at least 2 minutes. Also, physicians and industry were misdirected by some of the preclinical work, as decisions were made under the belief that infrainguinal arteries are similar to the coronary arteries.

How would you describe your expectations for the performance of a DCB BTK versus standard percutaneous transluminal angioplasty (PTA)? How long do you expect the treatment benefit for a DCB versus standard PTA to last?

Dr. Varcoe: For a DCB to be useful, it should safely improve patency rates and reduce the need for TLR

compared with PTA alone. Ultimately, I would like to see a reduction in major amputation rates for DCB, as that is the most important endpoint for the treatment of CLI. To date, there is no convincing evidence that any DCB can achieve that goal^{1,2}; however, if future efficacy were to be demonstrated, I would want to see that benefit last at least 12 months for its use to be justified.

Dr. Mustapha: The science has not yet answered this question completely. We have had multiple failed DCB BTK trials, but that should not lead us to the conclusion that DCBs do not work in the BTK arteries. Again, the misleading comparison of anatomic similarities between coronary arteries and tibial arteries played a major role in the failure of the BTK trials. We now know that tibial arteries are significantly different from the coronary arteries in their anatomic and pathologic disease variation. With this knowledge, our approach is changing.

In ongoing trials, we now ensure that the DCB is used in the tibials only after the target tibial lesion is well prepared to receive the drug first to its endothelial lining, then crossing the subendothelial layer followed with the barrier of the internal elastic tissue, then into the media and possibly the adventitia. This might sound like a simple process, but in reality, most tibial arteries that require therapy tend to be heavily diseased with unwanted intimal and medial calcification, neointimal hyperplasia, and thickening of the elastic lamina, both internally and externally. A good example is shown in Figure 1, where the drug and its excipient have to travel across tremendous barriers to reach the source where neointimal hyperplasia must be inhibited.

Current DCBs must be appropriately sized in the tibial arteries to maximize the highest rate of drug transfer from the balloon surface to the tibial endothelial wall to then make the journey to the media and beyond. I believe that if we do it correctly, the result of DCBs in BTK arteries would result in sufficient neointimal inhibition by the antiproliferative mechanism. At the same time, I also believe that we need more of a mechanical component added to the drug/excipient component so we can create an equal ground for all operators and all excipients to consistently reach the media and beyond at the end of the procedure.

In my experience, BTK PTA has been very poor. PTA is the most commonly used treatment modality in the BTK arteries, yet the data over the last 30 years, including the latest large meta-analysis, show extremely high recoil and restenosis rate post-PTA.³ Hence, I hesitate to use PTA alone during tibial interventions, and my hope is to see DCBs approved and available in the

United States, given that 3 decades of data have shown that PTA alone is associated with extremely high restenosis rates.⁴⁻⁶

Prof. Brodmann: My expectations are, for sure, a lower rate of restenosis, as impaired flow is a main contributor to CLI. Longer primary patency would result in fewer reinterventions, which would be a huge benefit in this CLI patient cohort. If we were able to achieve sustained patency up to 12 months, this would be very beneficial.

Dr. Micari: Most reocclusions related to standard PTA occur in the first 3 months after the procedure. I expect that DCBs will provide longer patency, and even in the case of loss of patency, we will appreciate focal restenosis or reocclusion and not full-length reocclusions.

Which factors will most affect your decision to choose a drug delivery device rather than standard PTA?

Dr. Mustapha: Data will affect my decision. Although much of the successful DCB data have been single-center studies or series, at least DCBs showed significant benefit over PTA alone.

Dr. Micari: To change standard practice, we need to have evidence-based data. Different trials are being run to determine the superiority of DCB versus PTA. After compiling the results, we should offer our patients the best treatment based on the data.

Prof. Brodmann: If there were evidence that a DCB works BTK, I would be happy to apply the same protocol as I do for the SFA/popliteal artery: adequate vessel preparation, which is even more relevant BTK than above the knee, and then application of a DCB.

Dr. Varcoe: Thus far, the only drug delivery devices that are shown to be effective BTK are drug-eluting stents (DESs).⁷⁻⁹ These are coronary devices that currently have lengths up to 48 mm. Therefore, they are only of practical use in short- to moderate-length lesions and seem to be well matched to arteries found in the mid to proximal calf.

Are there cases in which the potential for adverse events due to distal particulate embolization will preclude you from selecting a DCB?

Dr. Varcoe: No, but I am unlikely to choose a DCB for crural PAD in the absence of evidence that it is more effective than PTA.

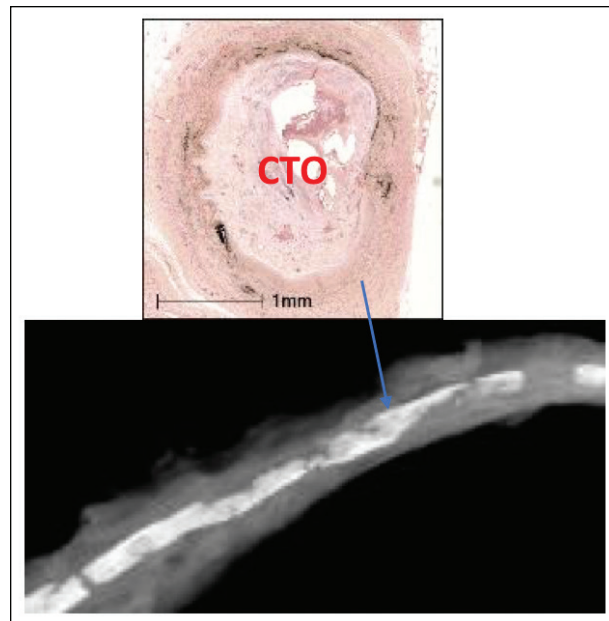


Figure 1. Cross-sectional area of a calcified tibial vessel with intimal calcium, which obstructs drug migration and thereby inhibits new intimal hyperplasia. CTO, chronic total occlusion.

Dr. Mustapha: Yes, I would not recommend use of DCB in cases where circumferential intimal and medial calcification are not modifiable when concentric neo-intimal hyperplasia does not respond to high-pressure balloon angioplasty (Figure 2).

Prof. Brodmann: Yes, if I know that the DCB I have in my hands is not the newest and safest technology with regard to the drug formulation or coating technique, I would not use it.

What percentage of your BTK cases do you estimate will require vessel preparation of some kind before drug delivery? What distinguishes these cases?

Prof. Brodmann: In my opinion, we should focus more on adequate vessel preparation in any patient we are treating with a DCB, independent from the anatomic area.

Dr. Micari: Vessel preparation BTK is crucial. I do not think we can use a DCB without vessel preparation. It is still unknown as to what type of device is best, and we probably we need to tailor our vessel prep for different situations. However, I use DCBs only after appropriate preparation of the vessel and I try to size 1:1.1 vessel/DCB ratio to be confident that I am touching the vessel wall to best elute the paclitaxel.

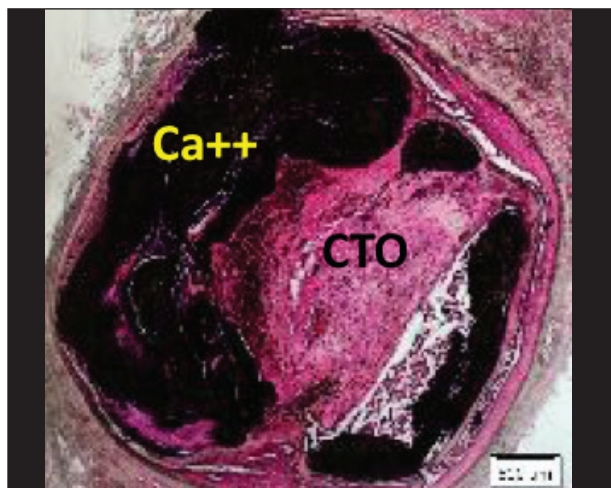


Figure 2. An example of where circumferential intimal and medial calcification is not modifiable when concentric neointimal hyperplasia does not respond to high-pressure balloon angioplasty.

Dr. Mustapha: All tibial cases require vessel preparation prior to DCB delivery. The distinguishing factor is the element of the presence of concentric disease combined with elastocalcinosis and intimal and medial calcification.

Dr. Varcoe: Most lesions will require predilatation with simple PTA prior to the application of a drug delivery device, whether that device is a DCB, DES, or an adventitial delivery system. However, the question of which lesions would benefit from the use of specialty balloons and atherectomy is more contentious. Some evidence suggests that specialty balloons may result in less flow-limiting dissection and thus reduce the need for the use of a permanent metallic implant.¹⁰ The same may also be true of atherectomy; however, the evidence to support these technologies in BTK vessels is sparse.^{11,12}

How might the post-2017 reimbursement situation for DCBs in the United States affect their uptake even once approved by the US Food and Drug Administration?

Dr. Mustapha: This is a tough question. I can't deny the disappointment with the seemingly rash decision to not reimburse DCBs, which is resulting in diminishing use. Let's not discuss our personal opinions or feelings about the Centers for Medicare & Medicaid Services (CMS) decision, but rather let's discuss the science that for the first time showed excellent long-term results for some of the sickest patients we treat. None of us can guarantee

how much DCBs will be used without reimbursement in hospital and nonhospital settings. Like many others, I cannot understand why CMS would take away a scientifically proven, effective treatment from patients who need it. In all the DCB trials, one common theme was noted—less repeated endovascular procedures when DCBs were utilized. This can translate into many different patient-centric benefits that were stripped away from the patients, with the most important on my list being quality of life and work productivity.

Dr. Micari: It is difficult to say. To be sure, economic issues should not affect the best treatment for patients, but it is the real world, and I regret to say that reimbursement is necessary to help device penetration in the market.

Although similar in size, we have learned of substantial distinctions between the coronary arteries—where DESs are approved for use—and the BTK vessels. What role do you believe these devices currently play (ie, which vessels and nature of disease)?

Prof. Brodmann: There are only limited data on this specific point. So far, we have promising data with regard to short DESs in BTK disease, but on the other hand, we all know how extensively BTK arteries are diseased—we are talking about 3- X 30-cm-long, heavily diseased, thin arteries (2–4 mm in diameter). So, a general DES approach as applied in coronary disease is, in my opinion, not useful and/or possible. There are perhaps some situations in which a short DES might make sense.

Dr. Micari: At the moment, DESs have a very small role and are only used in selected short and calcified lesions. Routine use is not likely.

Dr. Varcoe: The use of coronary DESs in BTK arteries has been approved in Australia for close to 10 years. I am liberal in my application of these devices and have seen excellent results, similar to the body of evidence from randomized trials. I choose to use them in short- to medium-length lesions (< 10 cm) and try to avoid them in arteries < 2.75 mm. I also use them to improve run-off after treating the SFA, when I encounter a discreet, proximal tibial lesion. That practice is not supported by evidence but follows the surgical principles of bypass patency relying on good inflow and outflow. In my view, it is a sound extension of that same principle for SFA revascularization.

Dr. Mustapha: Coronary-based DES platforms are best in the proximal tibial arteries. Many trials have

shown the benefits. The issue is that current coronary balloon-expandable DESs are not effective beyond the proximal tibial arteries. They tend to crush and fracture with severe hyperplastic restenosis.

What do we most need to learn in a trial setting about the performance and expectations of DESs BTK before we know if these devices are ready for prime time?

Dr. Mustapha: To start with balloon-expandable DESs, we have had multiple trials, and the conclusion was clear about their positive impact in proximal tibial arteries. Beyond the proximal tibials, we must shift into self-expanding and long DESs to address the multifactorial causes that lead to the failure of balloon-expandable DESs. The type of stent we need for BTK arterial disease is very complex; we need self-expanding stents with strong radial force plus long-term drug emission, the ability to conform to the tapering aspect of the tibial arteries, and fracture resistance.

Dr. Varcoe: We have long-term data for DESs to attest to their safety BTK. We also have level 1 evidence to attest to their efficacy.^{7,9} They have been shown to reduce restenosis, clinically driven TLR, contribute to sustained improvement in Rutherford class, and avoid major amputation compared to conventional endovascular therapy.⁷⁻⁹ We have small data sets that suggest that DESs perform poorly at bifurcations around the ankle and foot.^{13,14} These devices are great for a certain subset of lesions, but they are not suitable for long chronic total occlusions, which are more frequently encountered in CLI.

Dr. Micari: First, we need to see if DESs can be effective in the real CLI disease anatomy. A 40-mm stent cannot be a solution for 40-cm occlusion!

Prof. Brodmann: We have to identify specific lesions and patients in which and in whom a DES makes sense, as BTK disease is so extensive.

Based on the current understanding of the differences between the coronaries and tibials, what anatomy-/disease-specific enhancements would you like to see in both stent and delivery design and capabilities?

Dr. Varcoe: I would like to see longer self-expanding stents to manage long-segment disease. Deliverability doesn't seem to be an issue, and the rapid exchange system is fine if the lesion is adequately prepared. We've had some really encouraging results with bioresorbable scaffolds used BTK, and I think they are particularly well suit-

ed to this vascular territory.¹⁵ However, I would like to see future drug-eluting bioresorbable vascular scaffolds with thinner struts, more rapid resorption profiles, and longer lengths and be more easily visualized on fluoroscopy.

Dr. Mustapha: In terms of stents, I stand by my previous statement of the need for a stent that is self-expanding with strong radial force, long-term drug emission, the ability to conform to the tapering aspect of the tibial arteries, and fracture resistance. This type of stent could treat the entire spectrum of tibial disease from proximal to distal.

Imagining a setting in which DCBs, DESs, and adventitial delivery devices are all available, what is your prediction for how they might be algorithmically selected, weighing durability, cost, and future revascularization needs?

Dr. Varcoe: This is a difficult question considering that there is so much we've yet to understand about adventitial delivery devices—not only whether they are effective, but also if they are safe, the technique to best facilitate treatment of the entire treated segment without geographic miss, the best pharmaceutical agent to use, and toxicity concerns.

If in the future we have results that show that DCBs and adventitial delivery systems work effectively to preserve an open artery after intervention, then you might consider them interchangeable as methods to treat long-segment disease without the need for a metallic implant. My algorithm would be to use a DCB/adventitial delivery system for long-segment disease and areas poorly suited to stents (bifurcations, small arteries, those within 10 cm of the ankle/foot). I would reserve DESs for shorter, proximal calf artery lesions and as bailout for recoil/dissection after DCB/adventitial delivery system use.

Prof. Brodmann: My algorithm would be adequate vessel preparation in all patients, with much more atherectomy than we do now, followed by a DCB and only spot stenting if mechanically needed. Spot stenting could be done with bare-metal stent designs.

Dr. Mustapha: When you mention eventual drug delivery, I can see the variation in the consistency of delivering the proper drug to the proper location precisely each time. At present, we don't have that and therefore this would be my last choice. Balloon-expandable DESs fit well and also have data to support their benefit in the proximal tibial arteries. DCBs are my primary choice at this point, with proper balloon-to-vessel sizing after the adequate vessel preparation has been done.

Dr. Micari: I think that even determining an algorithm is difficult—DCBs, DESs, and adventitial devices should be used in a complementary manner. First, I would use the no-stent techniques, but I would consider stenting in the same artery where needed as bailout or provisional use. Primary stenting should be preferred in proximal, calcified, and relatively short lesions.

Do you expect paclitaxel to continue to be the primary drug used, or does this setting open the door for others such as the limus family?

Dr. Mustapha: Personally, I don't believe paclitaxel is the problem and is not the cause of the failed BTK tibial trials. Limus DCBs will fail as well if not properly used. We are missing a major point in the concept of DCB BTK therapy, which is the extensive obstacles coming from the tibial arterial wall and lumen for any drug we choose to use. We must focus on methods of building paths into the vessel walls, so when the drug arrives to the target area, it will transmit itself as designed with its excipient to the control center of proliferation so it can be immediately effective in preventing proliferation. Until then, we continue to do our best with aggressive vessel preparation and proper sizing of balloon-to-vessel ratio of at least 1:1.1.

Dr. Micari: I expect to see different drugs, as well as limus drugs, coming out. If satisfactory results are achieved from the current DCB trials, more investments will be allocated in the field and more molecules will be studied and targeted in the tibials.

Prof. Brodmann: My assumption is that drugs other than paclitaxel for BTK disease will be recognized and used in the future.

Dr. Varcoe: No, DES data suggest that paclitaxel is less effective than rapamycin analogues BTK.^{16,17} The jury is still out on DCB drug coatings, but now that rapamycin drugs are being evaluated in trials of DCBs above the knee, it opens the door to a BTK-specific rapamycin analogue-coated balloon. ■

1. Zeller T, Beschoner U, Pilger E, et al. Paclitaxel-coated balloon in infrapopliteal arteries: 12-month results from the BIOLUX P-II randomized trial (BIOTRONIK'S first in man study of the Passeo-18 LUX drug releasing PTA balloon catheter vs. the uncoated Passeo-18 PTA balloon catheter in subjects requiring revascularization of infrapopliteal arteries). *JACC Cardiovasc Interv.* 2015;8:1614-1622.
2. Zeller T, Baumgartner I, Scheinert D, et al. Drug-eluting balloon versus standard balloon angioplasty for infrapopliteal arterial revascularization in critical limb ischemia: 12-month results from the IN.PACT DEEP randomized trial. *J Am Coll Cardiol.* 2014;64:1568-1576.
3. Mustapha JA, Finton SM, Diaz-Sandoval LJ, et al. Percutaneous transluminal angioplasty in patients with infrapopliteal arterial disease: systematic review and meta-analysis. *Circ Cardiovasc Interv.* 2016;9:e003468.
4. Razavi MK, Mustapha JA, Miller LE. Contemporary systematic review and meta-analysis of early outcomes with percutaneous treatment for infrapopliteal atherosclerotic disease. *J Vasc Interv Radiol.* 2014;25:1489-1496.

5. Romiti M, Albers M, Brochado-Neto FC, et al. Meta-analysis of infrapopliteal angioplasty for chronic critical limb ischemia. *J Vasc Surg.* 2008;47:975-981.
6. Bosiers M, Peeters P, D'Archembeau O, et al. AMS INSIGHT—absorbable metal stent implantation for treatment of below-the-knee critical limb ischemia: 6-month analysis [published erratum appears in *Cardiovasc Intervent Radiol.* 2009;32:422-423]. *Cardiovasc Intervent Radiol.* 2009;32:424-435.
7. Fusaro M, Cassese S, Ndrepepa G, et al. Drug-eluting stents for revascularization of infrapopliteal arteries: updated meta-analysis of randomized trials. *JACC Cardiovasc Interv.* 2013;6:1284-1293.
8. Katsanos K, Spiliopoulos S, Diamantopoulos A, et al. Systematic review of infrapopliteal drug-eluting stents: a meta-analysis of randomized controlled trials. *Cardiovasc Intervent Radiol.* 2013;36:645-658.
9. Antoniou GA, Chalmers N, Kanesslingham K, et al. Meta-analysis of outcomes of endovascular treatment of infrapopliteal occlusive disease with drug-eluting stents. *J Endovasc Ther.* 2013;20:131-144.
10. Ward C, Mena-Hurtado C. Novel use of pillows and grooves: the Chocolate PTA balloon catheter. *Endovasc Today.* 2014;13:24-28.
11. Rastan A, McKinsey JF, Garcia LA, et al. One-year outcomes following directional atherectomy of infrapopliteal artery lesions: subgroup results of the prospective, multicenter DEFINITIVE LE trial. *J Endovasc Ther.* 2015;22:839-846.
12. Shammam NW, Lam R, Mustapha J, et al. Comparison of orbital atherectomy plus balloon angioplasty vs. balloon angioplasty alone in patients with critical limb ischemia: results of the CALCIUM 360 randomized pilot trial. *J Endovasc Ther.* 2012;19:480-488.
13. Werner M, Scheinert S, Bausback Y, et al. Bifurcation stenting after failed angioplasty of infrapopliteal arteries in critical limb ischemia: techniques and short-term follow-up. *Catheter Cardiovasc Interv.* 2013;82:E522-E528.
14. Katsanos K, Diamantopoulos A, Spiliopoulos S, et al. Below-the-ankle angioplasty and stenting for limb salvage: anatomical considerations and long-term outcomes. *Cardiovasc Intervent Radiol.* 2013;36:926-935.
15. Varcoe RL, Schouten O, Thomas SD, Lennox AF. Experience with the Absorb everolimus-eluting bioresorbable vascular scaffold in arteries below the knee. *JACC Cardiovasc Interv.* 2016;9:1721-1728.
16. Spreen MI, Martens JM, Knippenberg B, et al. Long-term follow-up of the PADI trial: percutaneous transluminal angioplasty versus drug-eluting stents for infrapopliteal lesions in critical limb ischemia. *J Am Heart Assoc.* 2017;6:e004877.
17. Bosiers M, Callaert J, Keirse K, et al. One-year outcomes of the paclitaxel-eluting, self-expanding Stentys stent system in the treatment of infrapopliteal lesions in patients with critical limb ischemia. *J Endovasc Ther.* 2017;24:311-316.