

# Utility of Noncontrast-Enhanced MRA in Patients With Critical Limb Ischemia

A review of classic and new techniques for diagnosis and procedural planning, with a focus on the quiescent-interval single-shot technique.

BY JOS C. VAN DEN BERG, MD, PhD

**A**dditional, second-level imaging in patients with peripheral artery disease is used to confirm findings of other noninvasive tests (eg, duplex ultrasound) or to complement an inconclusive examination. It may also be necessary in the planning of endovascular procedures to assist in determining the feasibility of a direct antegrade approach and to evaluate the iliac axis in case of a contralateral, crossover approach. Typically, CTA and MRA are used, and although the reliability of both imaging modalities is well established, both techniques have several disadvantages that are especially important to be aware of in patients with critical limb ischemia (CLI), as they are often affected by chronic renal impairment and diabetes.

The main disadvantage of CTA, in addition to the radiation exposure, is the use of potentially nephrotoxic iodinated contrast media. Moreover, the value of peripheral CTA in the infrapopliteal segment is limited because of vessel wall calcifications that are present in most patients with diabetic arteriopathy. MRA with gadolinium-based contrast has been associated with nephrogenic systemic fibrosis (NSF), especially in patients with preexisting renal disease, a condition often encountered in patients with CLI. As a precaution, the US Food and Drug Administration has applied a black box warning on gadolinium-based contrast agents.<sup>1,2</sup> The risk of NSF can be reduced by using stable macrocyclic contrast and low-contrast dose; however, current guidelines indicate that these types of contrast agents should be used with caution in patients with renal insufficiency.<sup>3</sup> This article discusses the utility of noncontrast-enhanced MRA (NCE-MRA) in patients with CLI.

## TECHNIQUE OF NONCONTRAST-ENHANCED MRA

Contrast in MRI depends principally on static tissue parameters: longitudinal relaxation time T1, transverse relaxation time T2, and proton density. In addition, the magnetic resonance (MR) signal is sensitive to flow and movement, which frequently leads to artifacts in MRI. However, MRA sequences use flow-induced signal variations to depict blood vessels or obtain quantitative information about blood flow in terms of velocity and direction. Unenhanced MRA comprises MR techniques that rely solely on flow effects. Unlike contrast-enhanced MRA (CE-MRA) and digital subtraction angiography (DSA), which depict the vessel lumen filled with contrast agent, just the movement of blood is seen in the unenhanced MRA. There has been a resurgence of interest in NCE-MRA techniques, in part because of the previously mentioned safety concerns (ie, NSF). An additional advantage of NCE-MRA is a reduction in costs related to the use of gadolinium-based contrast (costs of contrast medium, injector kit, and blood samples to determine the estimated glomerular filtration rate) and increased patient comfort.<sup>4</sup>

### Classic NCE-MRA Techniques

NCE-MRA differs from DSA and other angiographic techniques in that blood vessels are depicted noninvasively with no need for contrast agent injection. Unenhanced MR techniques allow the acquisition of three-dimensional (3D) data sets or stacks of two-dimensional (2D) images ("source images") that cover all vessels in a selected volume of interest. Starting from source images, the postprocessing algorithm (maximum intensity projection [MIP] algorithm) can reconstruct a projec-

tional angiographic display of the vessel and enables the generation of angiogram-like images from any desired view angle<sup>5,6</sup> without the need for additional measurements or invasive procedures. Another advantage of MRA versus DSA is the fact that extravascular tissue is shown with the vessels with MRA, thereby permitting the correlation of blood flow abnormalities with associated soft tissue pathologies (eg, external compression).

Typically, MRA techniques are designed so that flowing blood produces a hyperintense signal over a background signal from largely suppressed stationary tissue ("bright blood" angiography). An alternative is to suppress the signal from the flowing blood so that it appears hypointense compared to the stationary background ("black blood" angiography).

Bright blood MRA can be performed with either a time-of-flight (TOF) or phase-contrast (PC) approach.<sup>2</sup> TOF-MRA is based on amplitude effects: blood flowing into or out of a chosen slice has a different longitudinal magnetization compared to stationary spins, depending on the duration of stay (TOF) in the slice. PC-MRA is based on phase effects: blood flowing along the direction of a magnetic field gradient is subject to changes of its transverse magnetization compared to stationary spins.

Because unenhanced MRA is based on complex flow phenomena, physiologic conditions of flow in the vascular territory of interest are a critical factor for the applicability of the method. Brain vessels, where flow is nearly laminar, provide advantageous conditions for unenhanced MRA. In fact, in clinical routine, unenhanced MRA is a robust and versatile method for noninvasive imaging of brain vessels (circle of Willis, sagittal sinus) and a suitable technique for depicting extracranial carotid arteries and short segments of peripheral vessels (eg, lower leg).<sup>7</sup> Unenhanced MRA performs well in high-velocity arterial flow, where acceptable vessel/background contrasts can be achieved in moderate acquisition times. On the other hand, unenhanced MRA is limited in areas of turbulent or very slow flow, where some signal loss is possible, which may lead to a misdiagnosis of the pathologic condition (eg, stenosis, aneurysm) in severe cases. In addition, anatomic coverage is very limited, leading to long examination times if evaluation of the entire arterial tree from the abdomen to the feet is needed.

Another major limitation of TOF- and PC-MRA is their high sensitivity to motion artifacts, which can either be caused by patient movements related to the need for relatively long acquisition times (typically  $\geq 1$  hour) or due to physiologic reasons in areas of very pulsatile flow (eg, carotids, aorta, and peripheral arteries) or in regions affected by breathing and heart actions (eg, thoracic and abdominal aorta). For these reasons, the use of TOF- and

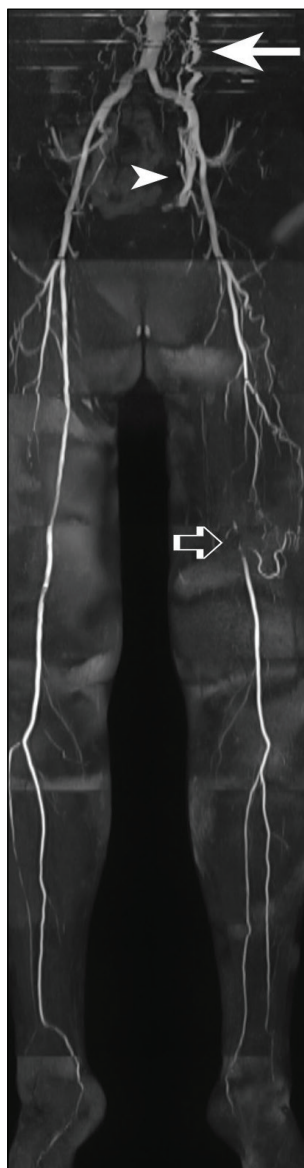
PC-based NCE-MRA to evaluate the peripheral arteries has been abandoned, and CE-MRA was routinely used until the risk of NSF was identified. Because a complete CE-MRA study requires a relatively large amount of contrast agent, the interest in the development of new NCE-MRA techniques has increased.

### Newer NCE-MRA Techniques

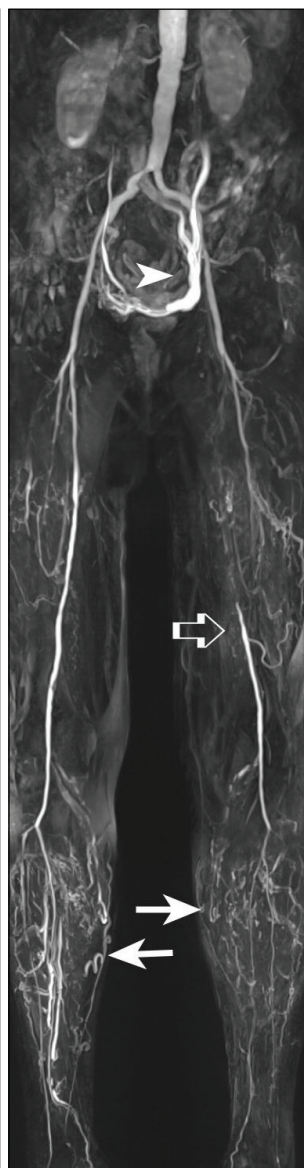
New NCE-MRA techniques are based on subtractive approaches that allow visualization of a large field of view and offer suppression of venous signal. All techniques use electrocardiographic gating combined with subtractive 3D turbo spin echo imaging or 3D balanced steady-state free precession (bSSFP) imaging. All these techniques are based on the difference between the signal of blood during systole and diastole. Both arteries and veins appear bright in diastole, while veins are only visible in systole. By subtracting the data sets obtained in systole and diastole, an arterial image can be obtained.

Although these techniques offer the advantage of 3D image acquisition (as compared to the 2D images obtained with TOF and PC sequences), there are several limitations related to the susceptibility to artifacts caused by patient motion, problems with pulse wave timing, and abnormal flow patterns.<sup>8</sup> The quiescent-interval single-shot (QISS) technique was developed to overcome these limitations.<sup>9</sup> Other techniques such as flow-sensitive dephasing SSFP have been recently developed and also show promise. The QISS technique is discussed herein, because it has been extensively studied with published clinical data.

**QISS technique.** The QISS MRA technique was introduced in 2010 and is a 2D electrocardiographic-triggered, single-shot, bSSFP acquisition.<sup>9</sup> The technique uses an initial saturation pulse to suppress the background signal and one pulse applied inferior to the slice to suppress the venous signal. The quiescent interval before the readout allows the inflow of unsaturated arterial spins into the imaging plane. Although a detailed description of the QISS technique is outside the scope of this article, briefly, stacks of axial slices are acquired throughout the region of interest and are subsequently processed to MIP images. The axial images are then automatically combined into a 3D-MIP projection (Figure 1). Due to its design, the flow sensitivity of MRA with the QISS technique is negligible compared with other noncontrast techniques. The QISS technique has minimal sensitivity to patient motion, is relatively insensitive to cardiac rhythm disturbances, and enables a simple workflow, without the need for highly technically skilled technologists. Because the technique is based on axial slices, there is a minimal risk of excluding regions of the vascular



**Figure 1.** NCE-MRA performed with the QISS technique in a patient with left-sided CLI; in the abdominal segment, multiple artifacts can be seen related to respiratory movement of the patient (arrow). Note the visualization of an insufficient left ovarian vein (arrowhead); this venous structure is visible because flow direction is cranio-caudad. Occlusion of the left SFA is seen with distal filling through collateral (open arrow).



**Figure 2.** CE-MRA of the same patient in Figure 1 showing filling of the left ovarian vein (arrowhead). Note retrograde filling of the distal SFA to a point more proximal to the collateral as compared to Figure 1 (open arrow; the QISS technique only shows antegrade flow). Note also the presence of venous contamination at the calf level bilaterally (arrows), rendering evaluation of the infrapopliteal segment difficult.

anatomy, which is a known problem with coronal slab-based imaging techniques. The acquisition of images and their processing is largely automated, which may lead to greater staff efficiency. However, there are several potential pitfalls. With highly irregular heart rhythms, image quality can degrade. The QISS technique relies on adequate and uniform fat suppression, which is more difficult to achieve at the level of the feet and groin, and therefore, the image may be compromised in these areas. The QISS technique is more sensitive as compared with other sequences to magnetic susceptibility artifacts caused by metallic implants (eg, hip and knee prostheses, stents, and surgical clips) and bowel gas. QISS uses magnetic venous saturation and is therefore not able to depict reversed arterial flow, especially when this occurs over a long segment, which is important in cases where flow to the distal arterial system occurs through collaterals (Figure 2). An advantage of using venous saturation is that it makes the technique less vulnerable for the occurrence of venous contamination in the image, which is a common problem seen in CE-MRA (especially in patients with CLI). In case of poor image quality (eg, patient motion), QISS NCE-MRA offers the option to repeat acquisition of certain arterial segments.<sup>10</sup>

The QISS technique has been validated in several studies using both 1.5T and 3T MRI scanners. A study evaluating 26 patients with type 2 diabetes compared two NCE-MRA techniques (a flow-sensitive dephasing SSFP technique and the QISS technique) with standard CE-MRA on a 1.5T MRI scanner.<sup>11</sup> The QISS technique was found to be slightly more susceptible to soft tissue signal contamination. QISS (like the flow-sensitive dephasing technique) had a high negative predictive value for detecting significant stenosis and is therefore a reliable screening tool for excluding infringuinal significant arterial disease. QISS was found to be less time-consuming. Another study comparing CE-MRA using the QISS technique showed high sensitivity (87% and 89.7% for two reviewers) and specificity (94.6% and 96.5%).<sup>12</sup>

The technique also proved to be valuable in patients with symptomatic peripheral artery disease and diabetes, with a near-perfect agreement of the NCE-MRA technique in patients where DSA was performed.<sup>13</sup> Similar results were seen in a study of 21 patients on a 3T system that allowed acquisition of images with a slice thickness of 1.5 mm.<sup>4</sup> A sensitivity of 93.1% and a specificity of 93.2% were seen when comparing QISS with CE-MRA, with a positive predictive value of 96.5% and a negative predictive value of 87.1%. Notably, the QISS technique showed less venous contamination. As in other studies,<sup>4</sup> the image quality in the distal aorta, pelvis, and femoral arteries was of lesser quality, with similar quality in the

distal segments (popliteal and calf). The good quality of the imaging of the distal arterial tree is of utmost importance in patients with diabetes and CLI, who typically are affected by more distal disease. A study evaluating the performance of the QISS technique on the calf level showed a sensitivity of 89%, a specificity of 91%, and a diagnostic accuracy of 90% when compared to CE-MRA.<sup>3</sup> In a small group of patients with CLI, sensitivity of MRA using the QISS technique was 92% and 81% for one reader and 95% and 97% for the second reader.<sup>14</sup>

Two recent comparisons of QISS NCE-MRA and CTA (with DSA as reference standard) demonstrated good intermodality agreement and interobserver agreement.<sup>10,15</sup> The overall duration of both CT and MR examinations was similar (around 25 min). Sensitivity, specificity, and accuracy of MRA using the QISS technique were not statistically different from CTA. The studies emphasized a major advantage of QISS over CTA with regard to the evaluation of vessel segments with heavy calcification (QISS demonstrated a higher sensitivity in detecting significant stenosis in these segments). Furthermore, in a significant number of cases, opacification of distal vessel segments was suboptimal with CTA (due to inadequate bolus timing). The QISS technique was less reliable in the evaluation of vessel segments in the presence of certain types of stents. The authors foresee improvements of the QISS technique with newly developed sequences, leading to better performance in patients with metallic implants.

## CONCLUSION

New NCE-MRA techniques appear to be valid alternatives to CE-MRA and CTA and can be used routinely in patients with CLI for both diagnostic purposes as well as planning of endovascular procedures. These new NCE-MRA techniques, when combined with CO<sub>2</sub> angiography and/or ultrasound guidance, will lead the way to “no-contrast” peripheral interventions. This will be an important step forward toward optimizing the management of patients with renal impairment and CLI. ■

9. Edelman RR, Sheehan JJ, Dunkle E, et al. Quiescent-interval single-shot unenhanced magnetic resonance angiography of peripheral vascular disease: technical considerations and clinical feasibility. *Magn Reson Med*. 2010;63:951-958.
10. Wu G, Yang J, Zhang T, et al. The diagnostic value of non-contrast enhanced quiescent interval single shot (QISS) magnetic resonance angiography at 3T for lower extremity peripheral arterial disease, in comparison to CT angiography. *J Cardiovasc Magn Reson*. 2016;18:71.
11. Zhang N, Zou L, Huang Y, et al. Non-contrast enhanced MR angiography (NCE-MRA) of the calf: a direct comparison between flow-sensitive dephasing (FSD) prepared steady-state free precession (SSFP) and quiescent-interval single-shot (QISS) in patients with diabetes. *PLoS One*. 2015;10:e0128786.
12. Hodnett PA, Koktzoglou I, Davarpanah AH, et al. Evaluation of peripheral arterial disease with nonenhanced quiescent-interval single-shot MR angiography. *Radiology*. 2011;260:282-293.
13. Hodnett PA, Ward EV, Davarpanah AH, et al. Peripheral arterial disease in a symptomatic diabetic population: prospective comparison of rapid unenhanced MR angiography (MRA) with contrast-enhanced MRA. *AJR Am J Roentgenol*. 2011;197:1466-1473.
14. Altaia MA, Jaskolka JD, Tan K, et al. Non-contrast-enhanced MR angiography in critical limb ischemia: performance of quiescent-interval single-shot (QISS) and TSE-based subtraction techniques. *Eur Radiol*. 2017;27:1218-1226.
15. Varga-Szemes A, Wichmann JL, Schoepf UJ, et al. Accuracy of noncontrast quiescent-interval single-shot lower extremity MR angiography versus CT angiography for diagnosis of peripheral artery disease: comparison with digital subtraction angiography [published online January 12, 2017]. *JACC Cardiovasc Imaging*.

## Jos C. van den Berg, MD, PhD

Service of Interventional Radiology

Centro Vascolare Ticino

Ospedale Regionale di Lugano

Lugano, Switzerland

Universitätsinstitut für Diagnostische,  
Interventionelle und Pädiatrische Radiologie  
Inselspital

Bern, Switzerland

jos.vandenbergh@eoc.ch

Disclosures: None.

1. Sadowski EA, Bennett LK, Chan MR, et al. Nephrogenic systemic fibrosis: risk factors and incidence estimation. *Radiology*. 2007;243:148-157.
2. Wheaton AJ, Miyazaki M. Non-contrast enhanced MR angiography: physical principles. *J Magn Reson Imaging*. 2012;36:286-304.
3. Knobloch G, Lauff MT, Hirsch S, et al. Nonenhanced magnetic resonance angiography (MRA) of the calf arteries at 3 Tesla: intraindividual comparison of 3D flow-dependent subtractive MRA and 2D flow-independent non-subtractive MRA. *Eur Radiol*. 2016;26:4585-4594.
4. Thierfelder KM, Meimarakis G, Nikolaou K, et al. Non-contrast-enhanced MR angiography at 3 Tesla in patients with advanced peripheral arterial occlusive disease. *PLoS One*. 2014;9:e91078.
5. Leiner T, Ho KY, Nelemans PJ, et al. Three-dimensional contrast-enhanced moving-bed infusion-tracking (MoBI-track) peripheral MR angiography with flexible choice of imaging parameters for each field of view. *J Magn Reson Imaging*. 2000;11:368-377.
6. Kaufman JA, McCarter D, Geller SC, Waltman AC. Two-dimensional time-of-flight MR angiography of the lower extremities: artifacts and pitfalls. *AJR Am J Roentgenol*. 1998;171:129-135.
7. Lell M, Fellner C, Baum U, et al. Evaluation of carotid artery stenosis with multislice CT and MR imaging: influence of imaging modality and postprocessing. *AJNR Am J Neuroradiol*. 2007;28:104-110.
8. Lim RP, Hecht EM, Xu J, et al. 3D nongadolinium-enhanced ECG-gated MRA of the distal lower extremities: preliminary clinical experience. *J Magn Reson Imaging*. 2008;28:181-189.