

CO₂ Angiography in Diabetic Critical Limb Ischemia Patients

One center's approach to using CO₂ angiography to evaluate its feasibility, calculate the amount of iodinated contrast medium, and evaluate renal function.

BY MARCO MANZI, MD, AND LUIS MARIANO PALENA, MD

The use of digital subtraction angiography with iodinated contrast is a common invasive imaging technique for diagnostic and interventional vascular procedures. However, this approach is associated with an increased risk of contrast-induced acute kidney injury (CI-AKI) among diabetic patients with baseline chronic kidney disease (CKD).^{1,2} The reported incidence of CI-AKI is 5.1% in patients with baseline CKD who undergo peripheral interventions.³ Because of its lack of nephrotoxicity and potential for allergic reactions, carbon dioxide (CO₂) has been used as a contrast medium for evaluating patients with renal dysfunction.⁴⁻⁸ To decrease procedure-related complications such as CI-AKI and allergic reactions, we have focused on the potential benefits of CO₂ as a contrast agent during invasive diagnostic procedures in the lower limbs.^{2-5,9,10}

OUR CENTER'S APPROACH TO CO₂ ANGIOGRAPHY

After our initial experience,¹¹ we extended the use of CO₂ angiography not only to patients with stage 3 or greater CKD (estimated glomerular filtration rate [eGFR] ≤ 60 mL/min/1.73 m²) at high risk for CI-AKI, but also to patients with normal renal function. The rationale is to evaluate the extensive feasibility of the CO₂ angiographic study, calculate the potential average reduction of the iodinated contrast medium (ICM) amount, and evaluate the potential reduction of CI-AKI and new CKD among the total number of treated diabetic patients with CLI. We routinely use the latest version of the Angiodroid automated CO₂ injector (Angiodroid Srl) (Figure 1).

All patients are pretreated with aspirin (75–160 mg) and ticlopidine (500 mg) or clopidogrel (300 mg). An

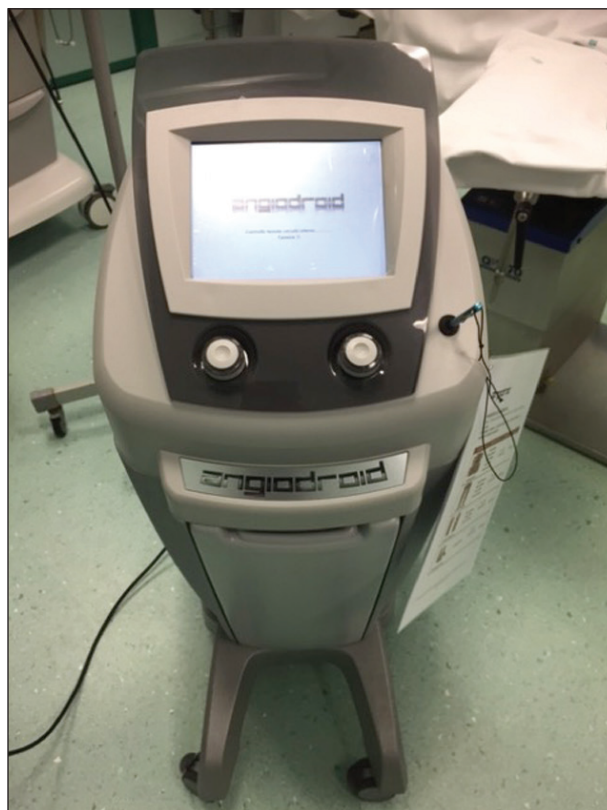

Figure 1. The Angiodroid automated digital CO₂ injector.

infusion of 0.9% normal saline solution at 1 mL/kg/min begins 1 hour before the procedure and continues until 6 hours after the procedure. Intravenous sedatives or analgesics are withheld to avoid masking a patient's reaction to the injection of CO₂.

After local anesthesia, antegrade access is achieved via the common femoral artery (CFA) under ultra-

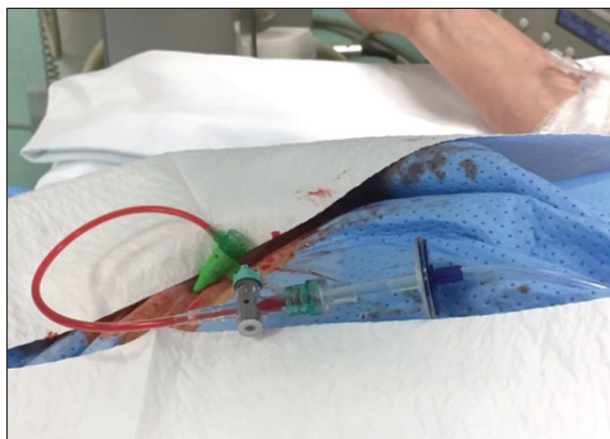


Figure 2. The CO₂ line connected with sheath sidearm.

sound guidance (9-MHz linear probe [Logiq E9, GE Healthcare]), and a 6-F, 11-cm end-hole introducer sheath (Radifocus, Terumo Interventional Systems) is advanced. Patients are anticoagulated with a 5,000-U bolus of intravenous unfractionated heparin. Diagnostic angiography through the CFA sheath, as later described, is performed in all patients; balloon angioplasty is then carried out during the same session. It was possible to perform 70% of procedures with CO₂ only, and the average amount of ICM was 38 mL in the other 30% of cases.

Angiograms are captured using the Integris Allura 12 digital subtraction angiography system (Philips Healthcare). For CO₂ angiography, the automatic, digital Angiodroid injection system is connected to the sidearm of the sheath (Figure 2). Initially, 10 mL of CO₂ is injected to fill the tubing with gas and eliminate air. In many cases, a repeated small injection may provide good imaging in the CFA and proximal superficial femoral artery (SFA) and through the P1 catheter in proximal below-the-knee (BTK) arteries as well. Then, by appropriately manipulating the stopcocks, the sheath is back-bled through its sidearm, and the CO₂ is injected, creating a blood-CO₂ interface without any air in the system.

We currently use a standard protocol for injection from the groin, which can provide good quality imaging up to the foot in most patients. The injected volume is 30 mL with a pressure of 130 mm Hg (17 kPa). To avoid gas fragmentation and trapping, the catheter is purged prior to each injection, and delivery is in a continuous, controlled fashion. When long BTK vessel occlusions are suspected, a 4-F Berenstein type 2 catheter (Cordis Corporation) is advanced to the P1 level, and the same amount of CO₂ is injected at the same pressure as previously described.

TABLE 1. CATEGORIES OF DIAGNOSTIC ACCURACY FOR CO₂ ANGIOGRAPHY

CATEGORY	DEFINITION
Excellent	All images are sufficiently high quality to establish the diagnosis and set up the revascularization procedure without the need for further imaging studies
Good	All images are adequate to establish the diagnosis and to guide treatment; however, complementary images with ICM are needed prior to the intervention
Poor	All images are insufficient or require the use of intravenous sedation/analgesia or the need to completely repeat the angiographic acquisition with ICM
Unacceptable	Images cannot be obtained and the procedure has to be cancelled due to uncontrollable pain or movement in the patients
Abbreviations: ICM, iodinated contrast medium.	

To prevent movement artifacts when the patient is experiencing pain during the injection of large portions of occluded and calcified arteries, we inject 10 mL of lidocaine 2% directly in the P1 positioned catheter. We also avoid elevating the patient's foot in the Trendelenburg position in order to prevent these imaging artifacts.

All angiograms are captured and analyzed in five predefined segments: (1) proximal femoral (including the CFA, proximal to the mid-SFA, and profunda), (2) distal femoral (from mid-SFA to P1 segment of the popliteal), (3) infragenicular (from the P2 segment of the popliteal to the proximal third of the tibial arteries), (4) distal tibial (from mid-calf to ankle), and (5) pedal (below the ankle [BTA]). The pedal territory is studied in two distinct projections (lateral and anteroposterior).

In order to ensure the accuracy of CO₂ angiography, Philips' proprietary postprocessing software can be utilized to render the high-quality images that are acquired. These images are then independently assessed by two experienced operators who are blinded to the ICM images and are not involved in the

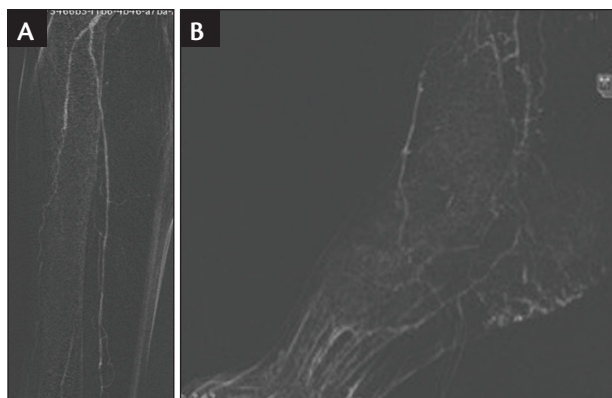


Figure 3. BTK (A) and BTA (B) CO₂ angiograms before angioplasty.

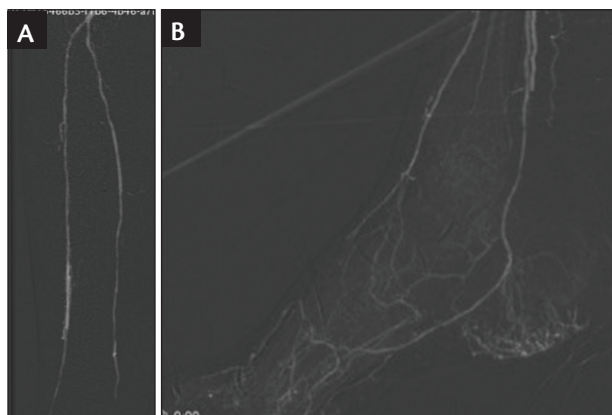


Figure 4. BTK (A) and BTA (B) CO₂ angiograms after angioplasty.

angioplasty procedure. Diagnostic accuracy is scored according to four predefined categories, as shown in Table 1.

RESULTS

Since October 2016, 412 diabetic patients have been studied, and we will prospectively compile cases through December 2017. Preliminary analysis demonstrates a large decrease in the average amount of ICM per patient (38 mL vs 54 mL) and a “good” level of accuracy in most of our patients. So far, in our patient cohort, the incidence of poor diagnostic accuracy with CO₂ angiography was low (17%) (Figures 3 and 4). In general, image degradation was caused by motion artifact that was introduced as a reaction to the pain caused by the injection, resulting in the need for repeat angiography in the specific arterial segment. In these instances when the patient is experiencing pain, treatment with intra-arterial lidocaine resulted in complete resolution of the patient’s symptoms and lack of further motion during repeat sequences. It is obviously too early for a definitive evaluation on the reduction of worsening renal function,

but we expect to reduce the very low eGFR modification from baseline (44.7 ± 13.3 mL/min/1.73 m²) to 47.0 ± 0.8 mL/min/1.73 m² at 24 hours postintervention ($P > .05$), as described in our first experience.¹¹

CONCLUSION

Antegrade arterial access and CO₂ angiography performed from the ipsilateral CFA with an automatic CO₂ injector is a safe and efficient technique to guide endovascular interventions, such as balloon angioplasty, and it provides good diagnostic accuracy even in patients with complex anatomy and comorbidities. CO₂ angiography represents a viable option to significantly reduce (or eliminate) the use of iodinated contrast in diabetic CLI patients in order to preserve renal function. ■

- Manke C, Marcus C, Page A, et al. Pain in femoral arteriography. A double-blind, randomized, clinical study comparing safety and efficacy of the iso-osmolar iodixanol 270 mg/ml and the low-osmolar iomeprol 300 mg/ml in 9 European centers. *Acta Radiol.* 2003;44:590-596.
- Madhusudhan KS, Sharma S, Srivastava DN, et al. Comparison of intra-arterial digital subtraction angiography using carbon dioxide by “home made” delivery system and conventional iodinated contrast media in the evaluation of peripheral arterial occlusive disease of the lower limbs. *J Med Imaging Radiat Oncol.* 2009;53:40-49.
- Fujihara M, Kawasaki D, Shintani Y, et al. Endovascular therapy by CO₂ angiography to prevent contrast-induced nephropathy in patients with chronic kidney disease: a prospective multicenter trial of CO₂ angiography registry. *Catheter Cardiovasc Interv.* 2015;85:870-877.
- Hawkins IF, Cho KJ, Caridi JG. Carbon dioxide angiography to reduce the risk of contrast-induced nephropathy. *Radiol Clin North Am.* 2009;47:813-825.
- Nadolski GJ, Stavropoulos SW. Contrast alternatives for iodinated contrast allergy and renal dysfunction: options and limitations. *J Vasc Surg.* 2013;57:593-598.
- Back MR, Caridi JG, Hawkins IF, et al. Angiography with carbon dioxide. *Surg Clin North Am.* 1998;78:575-591.
- Caridi JG, Hawkins IF Jr. CO₂ digital subtraction angiography: potential complications and their prevention. *J Vasc Interv Radiol.* 1997;8:383-391.
- Hawkins IF Jr, Mladinich CR, Storm B, et al. Short-term effects of selective renal arterial carbon dioxide administration on the dog kidney. *J Vasc Interv Radiol.* 1994;5:149-154.
- De Almeida Mendes C, de Arruda Martins A, Passos Teivelis M, et al. Carbon dioxide is a cost-effective contrast medium to guide revascularization of TASC A and TASC B femoropopliteal occlusive disease. *Ann Vasc Surg.* 2014;28:1473-1478.
- Kawasaki D, Fujii K, Fukunaga M, et al. Safety and efficacy of endovascular therapy with a simple homemade carbon dioxide delivery system in patients with iliofemoral artery diseases. *Circ J.* 2012;76:1722-1728.
- Palena LM, Diaz-Sandoval LJ, Candeo A, et al. Automated carbon dioxide angiography for the evaluation and endovascular treatment of diabetic patients with critical limb ischemia. *J Endovasc Ther.* 2016;23:40-48.

Marco Manzi, MD

Director of the Interventional Radiology Unit
Foot & Ankle Clinic
Policlinico Abano Terme
Abano Terme, Italy
marco.manzi@casacura.it
Disclosures: None.

Luis Mariano Palena, MD

Interventional Radiologist
Policlinico Abano Terme
Abano Terme, Italy
Disclosures: None.