

Sponsored by Spectranetics Corporation

Diverse Applications for Turbo-Power Excimer Laser Atherectomy

Leading experts in the field present case reports and discuss the utility of excimer laser atherectomy in the SFA and popliteal arteries.

Peripheral vascular disease is a common affliction that affects millions of patients worldwide. Endovascular therapy is becoming an attractive initial strategy adopted by clinicians throughout the spectrum of specialties (vascular surgery, interventional radiology, and interventional cardiology). There are various modalities to treat stenotic or occlusive atherosclerotic disease in the superficial femoral artery. Percutaneous transluminal angioplasty was previously a standard of care; however, results are suboptimal in longer lesions. Atherectomy in peripheral artery disease has gained interest due to its perceived benefits over simple percutaneous transluminal angioplasty without creating barotrauma and overstretching the vessels, and it should yield higher patency rates. The atheroablative laser technology that is currently available is the CVX-300 excimer laser (Spectranetics Corporation). Excimer laser uses flexible fiber-optic catheters that produce photoablation of atherosclerotic disease by using an ultraviolet light at 308 nm to penetrate atheroma, dissolve the molecules (producing thermal energy), and create kinetic energy that breaks chemical bonds at the molecular level and vaporizes intracellular water without damaging the surrounding tissue, thus minimizing restenosis.

The Turbo-Power ELA catheter was introduced by Spectranetics in November 2015 under FDA 510(k) clearance for use in in-stent restenosis. Turbo-Power is a laser atherectomy catheter designed for the treatment of de novo or restenotic lesions in native infrainguinal arteries. This new laser catheter carries rotational capabilities allowing the photomechanical effect created by the laser to impact a larger cross-sectional area within the vessel, which offers more precise directional control. Turbo-Power is compatible with a 7-F delivery system and up to 0.018-inch wires and has fluence (power) between 30 and 60 mJ/mm² and frequency (repetition) rate between 25 and 80 Hz.

First-in-Man Application of Turbo-Power Excimer Laser Atherectomy for Treatment of Complex Femoropopliteal ISR

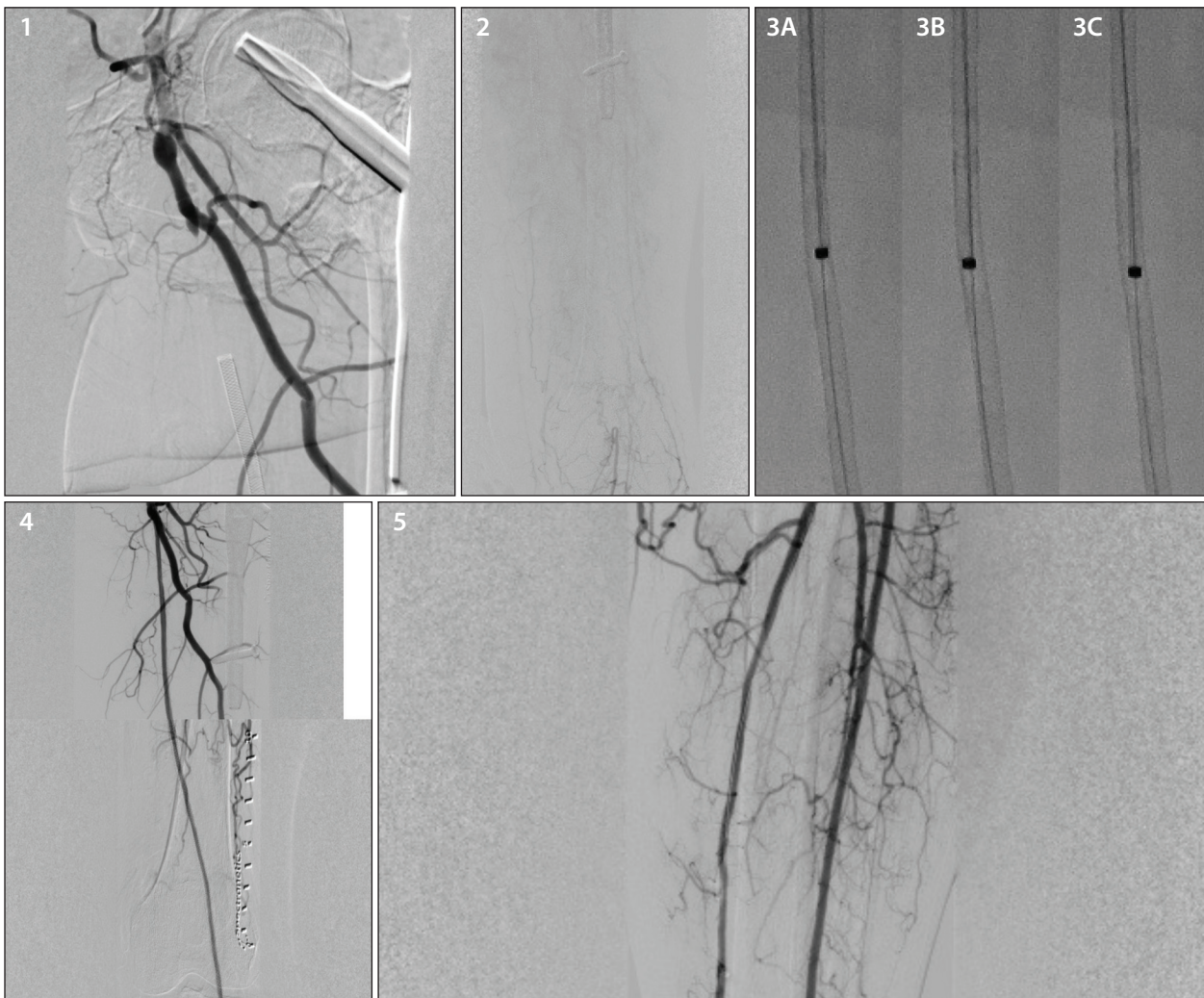
By Amjad AlMahameed, MD, MPH; Pradeep K. Nair, MD, FACC, FSCAI; and Craig Walker, MD

A 62-year-old woman with known advanced atherosclerotic vascular disease presented with true ischemic rest pain (Rutherford class 4). She had undergone stenting of the entire left superficial femoral artery (SFA) and proximal popliteal (femoropopliteal) arteries. She noted disabling recurrent claudication 2 months before her initial outpatient visit. Her exam showed absent pulses in the left leg. Noninvasive evaluation confirmed a marked reduction in resting ankle-brachial index (0.4), and arterial duplex ultrasonography revealed total occlusion of the femoropopliteal arteries and monophasic, low-velocity waveforms in the tibial vessels.

Her past medical history included stable coronary artery disease, coronary artery bypass grafting and stenting, compensated ischemic cardiomyopathy (left ventricular ejection

fraction, 35%), moderate bilateral carotid and left subclavian artery stenosis, dyslipidemia, hypertension, and prior cigarette smoking. Medications included atorvastatin, cilostazol, prasugrel, aspirin, and nebivolol.

Selective arteriography of the left lower extremity revealed total occlusion (in-stent restenosis [ISR]) of the entire left SFA and the proximal popliteal artery (Figures 1 and 2), as well as minimal flow into the tibial arteries via antegrade collaterals without discrete runoff to the foot. It was decided that intervention should be performed to revascularize the leg and relieve the symptoms. Because the occlusion was ISR, planned intervention included laser atherectomy, followed by balloon angioplasty.



PROCEDURAL DESCRIPTION

Retrograde percutaneous access was achieved via the right common femoral artery. A 7-F Pinnacle Destination sheath (Terumo Interventional Systems) was placed into the distal contralateral external iliac artery. Weight-based intravenous unfractionated heparin was administered and titrated to maintain therapeutic activated clotting time. The patient received aspirin and prasugrel before the procedure. Selective left leg arteriography was performed and illustrated occlusion of the entire SFA and reconstitution at the P2 segment (Figures 1 and 2).

The totally occluded left femoropopliteal segment (Figure 1) was crossed with a combination of a Glidewire (Terumo Interventional Systems) and a 4-F straight Glidecath (Terumo Interventional Systems), which was then exchanged for a 300-cm, 0.018-inch V-18 guidewire (Boston Scientific Corporation). Subsequently, the 2.3-mm OTW Turbo-Power excimer laser atherectomy (ELA) catheter (Spectranetics Corporation) was advanced (Figure 3), and two passes were performed. The first pass used a fluence of

40 mJ/mm² and frequency of 40 Hz, and the second pass used a fluence of 60 mJ/mm² and frequency of 60 Hz. The Turbo-Power excimer catheter easily traversed this long occlusion. Notably, the rotating catheter tip navigates away from stent struts and realigns to the central lumen. For example, Figure 3A shows the catheter tip in proximity to the lateral aspect of the stent wall, almost in contact with the struts. The ongoing rotation, however, redirected the catheter tip medially (as seen in Figure 3B) and allowed for subsequent directional control toward the central lumen (Figure 3C). These still frame images were isolated from a 4-second continuous loop recording.

This was followed by balloon dilatation with a 4- X 200-mm ultra-noncompliant Dorado catheter (Bard Peripheral Vascular, Inc.) at 20 atm. Subsequent angiography showed patency of the treated segment, and diffuse severe disease, and poor flow in the anterior tibial artery. Because there was true ischemic rest pain, the anterior tibial artery was then crossed and dilated with a 2.5- X 300-mm VascuTrak balloon (Bard Peripheral Vascular, Inc.) at 8 atm.

Sponsored by Spectranetics Corporation

RESULTS

Final angiography showed an excellent angiographic result with patency of the femoropopliteal segment (Figure 4). The tibial (Figure 5) and pedal vessels were widely patent with two-vessel runoff to the foot.

DISCUSSION

This case represents the first-in-man application of the Turbo-Power ELA catheter for the treatment of ISR and illustrates the technical and anatomical challenges associated with ISR lesions and the complex patient substrate affected by this process. The high-risk characteristics of this lesion include total chronic occlusion of the stents, which involved a very long segment (the entire SFA and

part of the popliteal artery), as well as the small-diameter femoropopliteal vessels and the diffusely and severely diseased outflow (tibial) vessels that required recanalization to establish adequate flow to the foot.

Although ISR material can be hardened, effective debulking was achieved utilizing Turbo-Power ELA followed by balloon angioplasty and yielded excellent results and relief of symptoms. Since the system became available, we have routinely applied Turbo-Power directly to totally occluded stents, allowing the device to vaporize at the tip and create its own pilot channel. Employing additional passes and boosting the power can achieve further debulking to maximize luminal gain as needed.

Personalizing PAD Intervention With Laser Atherectomy

By Vinayak Subramanian, BS, and George L. Adams, MD, MHS

Atherectomy has emerged as a valuable modality for interventionists to treat the complex lesions often involved in peripheral artery disease (PAD). The use of atherectomy to prep the vessels followed by adjunctive therapy with percutaneous transluminal angioplasty or stenting may improve the patency of the vessels and procedural success rates. Laser atherectomy is particularly useful in the treatment of homogenous and thrombotic plaque morphologies, which are common in restenotic lesions often encountered in the PAD population. Laser atherectomy is unlike other atherectomy modalities, which use mechanical interaction between the device and lesion to modify plaque, in that it utilizes a photoablative mechanism instead. This allows it to be used in in-stent restenosis (ISR) lesions. The following case illustrates the utility of laser atherectomy to personalize care for patients in order to optimize procedural success.

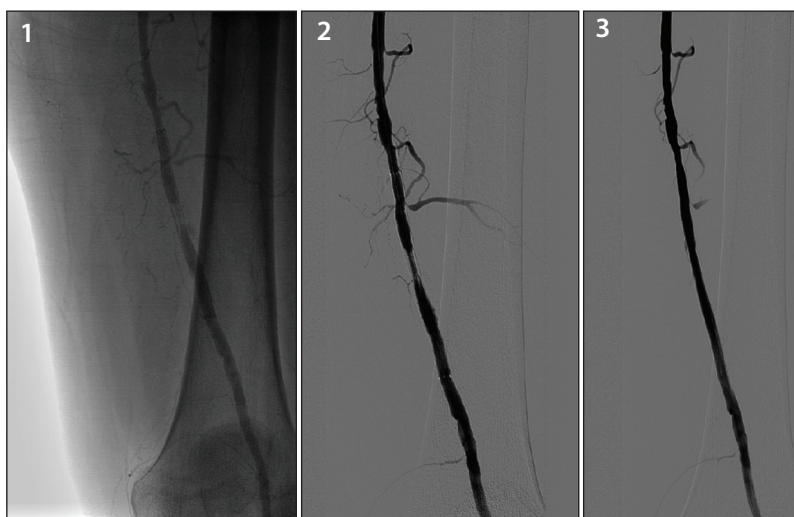
thrombotic component, a 2.3-mm Turbo-Power laser atherectomy device (Spectranetics Corporation) was used to photochemically ablate the lesion. After atherectomy, the stenosis was effectively modified and reduced to approximately 50% (Figure 2). Adjunctive antirestenotic therapy resulted in < 20% residual stenosis (Figure 3).

CONCLUSION

Laser atherectomy is an important tool in the interventionist's tool box for treating PAD. This case illustrates the utility of laser atherectomy in restenotic lesions composed of homogenous/thrombotic plaque. Laser atherectomy allows the operator to personalize therapy, reducing embolic complications and prepping the lesion prior to treatment with angioplasty and/or stenting. To this end, laser atherectomy is a valuable tool to optimize technical success.

PROCEDURAL DESCRIPTION

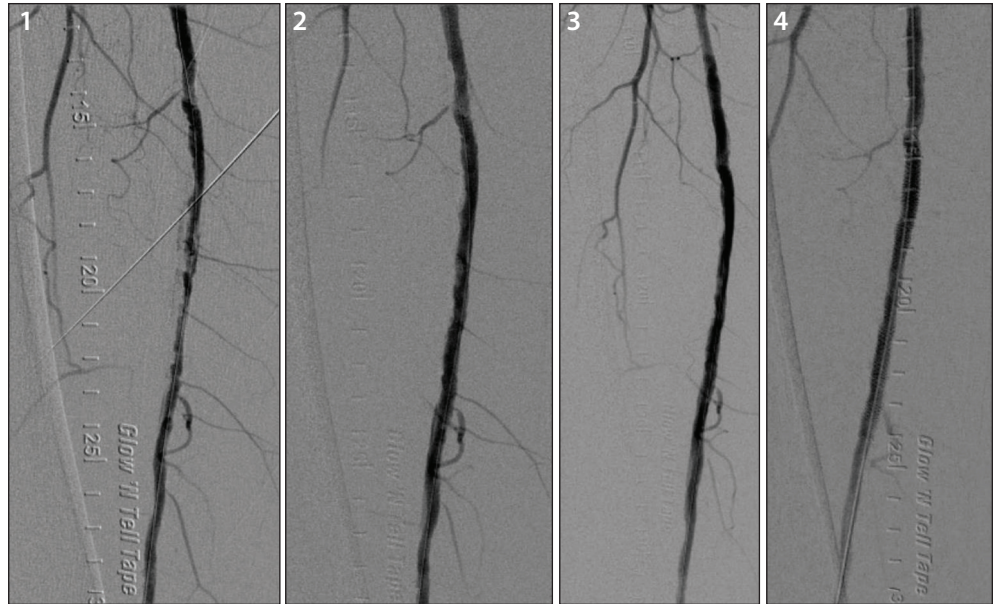
A 65-year-old man with a past medical history of coronary artery disease, hypertension, and dyslipidemia underwent stenting of his left superficial femoral artery 3 years ago before presenting to our institution. He presented to the clinic with claudication of his left leg after walking < 200 yards. His ankle-brachial index was 0.72, and duplex ultrasound of the left leg showed a > 70% ISR lesion in the distal SFA. Diagnostic angiography confirmed this finding (Figure 1). After successfully crossing the lesion and recognizing that ISR lesions may have a



Turbo-Power Excimer Laser Atherectomy for Treatment of a De Novo Lesion in the SFA

By Sachin Kumar Amruthlal Jain, MD, and Prakash Krishnan, MD, FACC, FSCAI

A 70-year-old woman was initially evaluated for bilateral claudication (Rutherford class 2, category 3, Fontaine IIB). The patient complained of worse pain in the right calf. Her Doppler exam revealed a resting ankle-brachial index of 0.70 in her right leg. Her medical history was notable for insulin-dependent diabetes mellitus, hypertension, hyperlipidemia, and prior cigarette smoking. Medications included metformin, metoprolol, losartan, atorvastatin, and insulin. Angiography revealed peripheral artery disease with critical stenosis of the midsegment of the right superficial femoral artery (SFA), as well as moderate stenosis of the tibioperoneal trunk and the anterior tibial artery.



PROCEDURAL DESCRIPTION

The patient underwent endovascular intervention using the left common femoral artery (CFA) access with a micropuncture technique, and a 5-F sheath was placed. A Tempo Flush catheter (Cordis/Cardinal Health) was placed in the distal abdominal aorta, and abdominal angiography was done. A 0.035-inch Wholey guidewire (Medtronic) was used to cross over and placed in the right CFA. Selective right extremity angiography was performed. The 5-F sheath was exchanged for a 7-F Pinnacle Destination sheath (Terumo Interventional Systems) and advanced to the level of the right CFA. A 300-mg oral loading dose and 5,000 units of heparin was given; activated clotting time was checked and found to be therapeutic.

The lesion (Figure 1) in the right SFA was crossed with a 0.014-inch SpartaCore guidewire (Abbott Vascular). A 2.3-mm Turbo-Power excimer laser catheter (Spectranetics Corporation) was used, and two passes were made across the lesion. The first pass was made at a fluence of 45 mJ/mm² and a repetition rate of 25 Hz. The catheter was then pulled back and rotated 180°,

and a second pass was made at 45 mJ/mm² and 45 Hz (Figure 2). The dilation with balloon angioplasty (6- X 20-mm Armada PTA catheter [Abbott Vascular]) was performed subsequent to excimer laser atherectomy (Figure 3). Due to a residual stenosis, a 6- X 80-mm Zilver PTX drug-eluting stent (Cook Medical) was placed at the site of the right SFA (Figure 4). Postdilatation was performed with a 6- X 20-mm Dorado balloon (Bard Peripheral Vascular, Inc.).

RESULTS

There were no complications during the procedure, and final angiography revealed a widely patent right SFA with brisk flow and no residual stenosis. There was excellent distal flow and no evidence of embolization.

DISCUSSION

The use of the Turbo-Power excimer laser device provides an excellent treatment option for de novo lesions in the SFA. In this case, use of laser atherectomy provided an optimal interventional result with no change in distal postintervention runoff.

Laser is very useful in crossing chronic total occlusions or long stenotic lesions. The Turbo-Power catheter is designed to treat at the tip with vaporizing technology for maximal luminal gain. The device debulks the lesion in a single step and offers remote automatic rotation for precise directional control.

Sponsored by Spectranetics Corporation

Laser Atherectomy for Chronic Total Occlusion

By Fadi Saab, MD, and J.A. Mustapha, MD

Peripheral vascular disease is a common disease that impacts millions of patients worldwide. Endovascular therapy is becoming an attractive initial strategy adopted by clinicians throughout the spectrum of specialties (vascular surgery, interventional radiology, and interventional cardiology). Laser atherectomy is a time-honored tool that has been utilized effectively in multiple infrainguinal vascular beds. The unique mechanism of action in laser atherectomy allows the operator to achieve multiple short- and long-term goals. The goals include plaque debulking in relatively large vascular conduits (superficial femoral artery [SFA] and popliteal artery) and extend to plaque modification in relatively smaller vascular beds in the tibial plantar circulation. The following case study demonstrates the application of this new device in a patient with a chronic total occlusion (CTO).

A 57-year-old man presented with complaints of life-limiting claudication that affected his ability to work (Rutherford class 3). The patient was unable to ambulate more than 25 feet secondary to significant discomfort in his left calf. He was an active smoker with more than a 30 pack-year history of smoking. His medical his-

tory included multiple risk factors, including hypertension, type 2 diabetes, and hyperlipidemia.

Cardiovascular exam had relatively normal results. Pulses were intact in the upper extremities. Groin pulses were palpable bilaterally with presence of a loud right groin bruit. Pedal and popliteal pulses were not palpable. Doppler examination revealed bilateral monophasic pedal pulses. Ankle-brachial index (ABI) revealed a severely diminished left ABI at 0.5. The pulse volume recording suggested a diminished waveform in the calf region. These findings supported the possibility of severe infrainguinal femoropopliteal disease.

The patient agreed to stop smoking with the aid of pharmacologic therapy. He was already on appropriate medical therapy with aspirin and statin and had historically not tolerated additional therapy with cilostazol. A diagnostic angiogram was performed, which identified disease involving the left SFA (Figure 1).

PROCEDURAL DESCRIPTION

The decision to treat with an endovascular approach was pursued. After obtaining ultrasound-guided access in an antegrade fashion of the left common femoral artery (CFA), angiography was performed. The distal SFA was occluded with reconstitution in the popliteal artery. CTO crossing and treatment of the lesion was approached in the following stepwise fashion:

1. Extravascular ultrasound (EVUS) assisted crossing of the 100% occluded left SFA/popliteal artery. This technique relies on visual feedback from the equipment within the vessel using an ultrasound probe. The EVUS technique guided the 0.035-inch support catheter to navigate the CTO. Once crossed into the reconstitution, intravascular position of the catheter tip was confirmed via angiography (Figure 2A). The hypo-echogenic appearance was suggestive of an atherothrombotic plaque under ultrasound (Figure 2B).

2. After crossing the CTO, an Emboshield Nav6 embolic protection device (EPD) (Abbott Vascular) was deployed.

3. Ultrasound-guided atherectomy was performed using 2.3 Turbo-Power laser atherectomy (Spectranetics Corporation), utilizing the rotating function of the catheter while advancing the device. Slow advance-

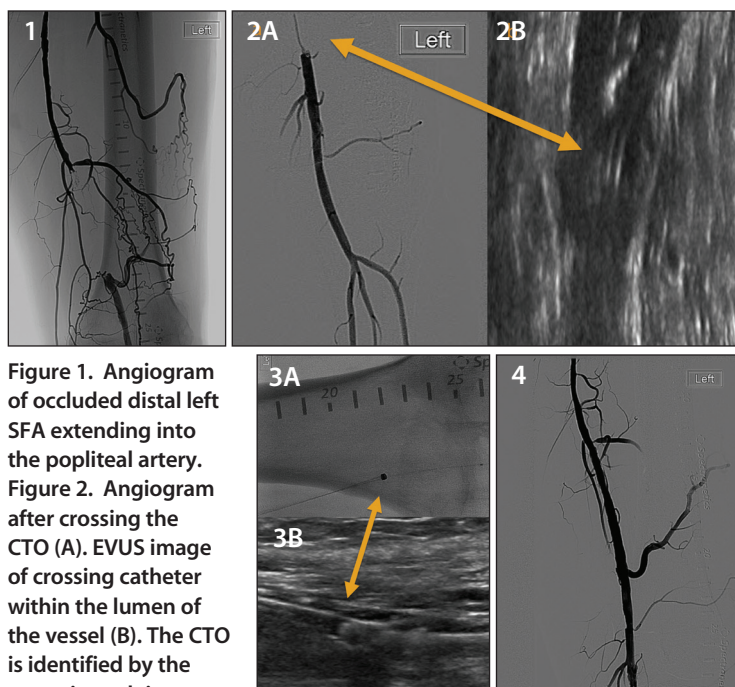


Figure 1. Angiogram of occluded distal left SFA extending into the popliteal artery. **Figure 2.** Angiogram after crossing the CTO (A). EVUS image of crossing catheter within the lumen of the vessel (B). The CTO is identified by the arrow in each image.

Figure 3. Turbo-Power laser atherectomy performed under fluoroscopy (A) and EVUS (B).

Figure 4. Final angiogram after Turbo-Power laser atherectomy and angioplasty with a drug-coated balloon.

ment is essential to capitalize on the effect of laser atherectomy. The eccentric beam created can affect a larger area than its traditional coaxial predecessor. In addition, the rotational capabilities allow the catheter to travel the length of the vessel in an easier fashion. Figure 3 shows the catheter activated under ultrasound and fluoroscopic guidance.

4. After debulking and plaque modification, an angiogram showed a brisk flow with no immediate complication. The EPD was retrieved, and the case proceeded to final therapy.

5. Using a 6-mm AngioSculpt balloon (Spectranetics Corporation), the vessel was treated with low atmospheric balloon angioplasty (5 atm) followed with a 7-mm In.Pact Admiral (Medtronic) drug-coated balloon inflated for 3 minutes. Final angiogram showed brisk flow with no immediate complications (Figure 4).

RESULTS

The patient was discharged home the next day. On 30-day follow-up, he reported complete resolution of his claudication symptoms (Rutherford class 0). His left ABI normalized at 0.97, with arterial duplex evaluation showing vessel patency. The patient was maintained on dual antiplatelet therapy and aggressive lipid-lowering therapy.

The current body of evidence suggests that laser atherectomy in patients with de novo lesions or in-stent restenosis may have better outcomes in contrast to balloon angioplasty alone. Ongoing trials and registries, such as the Peripheral Registry of Endovascular Clinical Outcomes (PRIME registry), continue to explore treatment algorithms in peripheral vascular disease and critical limb ischemia. ■

Amjad AlMahameed, MD, MPH

Interventional Cardiologist
Cardiovascular Institute of the South
Houma, Louisiana
drmjameed@gmail.com
Disclosures: None.

Pradeep K. Nair, MD, FACC, FSCAI

Interventional Cardiologist
Cardiovascular Institute of the South
Houma, Louisiana
Disclosures: None.

Craig Walker, MD

Interventional Cardiologist
Founder, President, and Medical Director
Cardiovascular Institute of the South
Houma, Louisiana
Clinical Professor of Medicine, LSU School of Medicine and Tulane University School of Medicine
New Orleans, Louisiana
drcrwalker@gmail.com
Disclosures: Consultant/medical/scientific boards for Abbott Vascular, Boston Scientific Corporation, Cardiva, Cook Medical, Bard Peripheral Vascular, Lake Regional Medical, Medtronic, Spectranetics Corporation; PVD training for Abbott Vascular, Bard Peripheral Vascular, Boston Scientific Corporation, Spectranetics Corporation, TriReme Medical; stockholder in CardioProlific, Cardiva, Spectranetics Corporation, Vasamed; and on

the speakers' bureau for Abbott Vascular, Bard Peripheral Vascular, Boehringer Ingelheim, Bristol-Myers-Squibb/Sanofi, Cardiva, Cook Medical, Cordis Corporation, DSI/Lilly, Gore & Associates, ACHL/Merck, and Spectranetics Corporation.

Vinayak Subramanian, BS

Department of Biomedical Engineering
North Carolina State University
Raleigh, North Carolina
Disclosures: None.

George L. Adams, MD, MHS

Rex Hospital
University of North Carolina Health System
Raleigh, North Carolina
george.adams@unchealth.unc.edu
Disclosures: Consultant for Spectranetics Corporation.

Sachin Kumar Amruthlal Jain, MD

Endovascular Interventional Cardiology Fellow
Mount Sinai Heart
New York, New York
doctorsachin@gmail.com
Disclosures: None.

Prakash Krishnan, MD, FACC, FSCAI

Assistant Professor of Medicine—Cardiology and Radiology
Icahn School of Medicine
Director of Endovascular Interventions

Mount Sinai Hospital
New York, New York
prakash.krishnan@mountsinai.org
Disclosures: Speaker and teacher for Abbott Vascular, Bard Peripheral Vascular, Inc., and Medtronic, Inc.

Fadi Saab, MD

Interventional Cardiologist
Metro Health Hospital
Wyoming, Michigan
Clinical Assistant Professor of Medicine
Michigan State University CHM and COM
East Lansing, Michigan
Disclosures: Consultant for Spectranetics Corporation, Abbott Vascular, and Medtronic, Inc.

J.A. Mustapha, MD

Director, Cardiovascular Catheterization Laboratories
Metro Health Hospital
Wyoming, Michigan
Clinical Assistant Professor of Medicine
Michigan State University CHM and COM
East Lansing, Michigan
jihad.mustapha@metrogr.org
Disclosures: Consultant for Spectranetics Corporation, Abbott Vascular, and Medtronic, Inc.