

# Recanalization and Stenting Using a Distal Access Site

Using low-profile devices for retrograde recanalization and treatment of superficial femoral and popliteal artery occlusions from a distal access site.

**BY JOS C. VAN DEN BERG, MD, PhD**

**T**he use of access sites other than the common femoral artery has become well accepted in modern endovascular treatment of occlusions of the superficial femoral and popliteal arteries. Alternative sites include direct superficial femoral access (proximal and distal), popliteal artery puncture (either with the patient in a prone or supine position), and access to all below-the-knee and below-the-ankle vessels. Use of distal access is mostly restricted to cases in which antegrade crossing of an occlusive lesion is not possible. When popliteal access is not possible, tibial access can be achieved using either dedicated pedal access sheaths or what is referred to as a “sheathless” approach.

After retrograde crossing with any of the currently known rendezvous techniques (eg, controlled antegrade and retrograde subintimal tracking [CART], reverse CART), the therapeutic procedure is typically performed using the already-present antegrade sheath (the pedal access sheath does not allow insertion of devices larger than 3 F). However, there are instances when the combined proximal antegrade and distal retrograde approach is not feasible. An example would be a patient whose morbid obesity necessitates a crossover approach from the contralateral side, but the approach would not be feasible due to severe iliac tortuosity or the presence of a contralateral iliac occlusion. In addition, some patients may not be able to undergo the procedure in a supine position (eg, due to cardiac or pulmonary failure), thus hampering common femoral artery access (either ipsilateral or contralateral). Therefore, in selected cases, there is a need to perform the procedure entirely from a single distal access site.

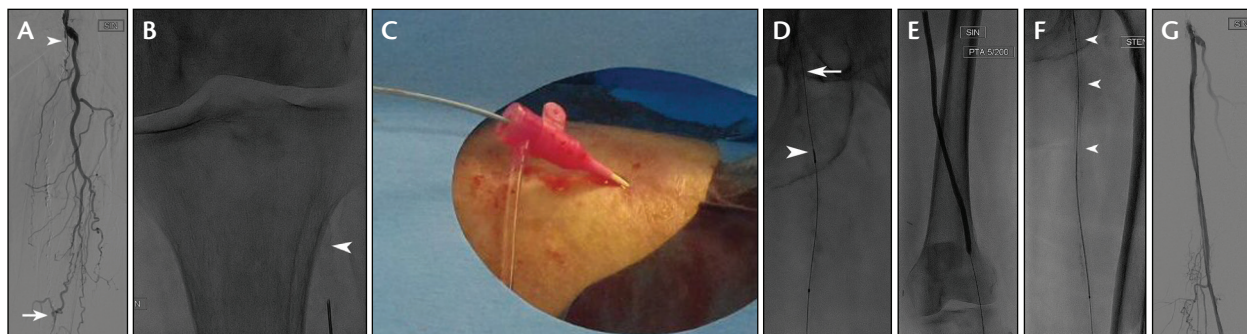
## TECHNICAL CONSIDERATIONS

In a manner analogous to the radial access used in coronary interventions, distal access using 6-F devices has been proposed. However, the use of large-bore access may lead to arterial complications (occlusion or dissection). These complications are known to occur after radial access for percutaneous transluminal coronary angioplasty in < 1% to 33% of cases.<sup>1</sup> In radial access, the occurrence of an occlusion usually remains without any clinical sequelae, but loss of one of the below-the-knee vessels may have devastating consequences in patients with critical limb ischemia (CLI), especially when the access vessel is the only remaining patent artery. Distal access vessel occlusion may also have repercussions on long-term patency in patients with intermittent claudication (the better the runoff score, the better the long-term patency). In addition, there is the risk of turning a patient with claudication into one with CLI. For this reason, the use of 6-F devices with distal access for the treatment of lower limb vascular disease is not to be considered a safe alternative.

## LOW-PROFILE DEVICES

Currently, several 4-F-compatible devices are available for the treatment of the infrainguinal arteries, and these low-profile devices carry a lower risk of causing additional arterial access site problems when introduced from a distal retrograde approach. Therefore, they may be considered a valid alternative.

In Europe, the following devices (which all require 0.018-inch guidewires) are available in 4 F: angioplasty balloons with a diameter of 6 mm and a length of up to



**Figure 1.** Digital subtraction angiography performed during an initial antegrade attempt showing occlusion of the left SFA (arrowhead) and a short patent segment of the popliteal artery (arrow) (A). Fluoroscopic image showing calcification of the distal popliteal artery (arrowhead); needle entry was above the trifurcation (B). A 4-F sheath was positioned from an anterior approach (C). Fluoroscopic image showing the tip of a CXI catheter (arrowhead) and a 0.018-inch guidewire (arrow) after crossing of the CTO of the popliteal artery and SFA (D). Fluoroscopic image showing an inflated 5- X 200-mm PTA balloon (E). Fluoroscopic image showing partial deployment of the distal part of the 6- X 170-mm stent (arrowheads) in the proximal segment of the SFA; the proximal part of the stent in the distal part of the SFA is still constrained (F). Control digital subtraction angiogram showing restoration of flow in the femoropopliteal segment after second stent placement and postdilation (G).

300 mm or a diameter of 8 mm with a length of 40 mm, as well as self-expanding stents with a diameter of 7 mm and a maximum length of 200 mm or a diameter of 8 mm with a length of 80 mm. These devices allow treatment of most popliteal and superficial femoral artery (SFA) disease and even some iliac artery disease (mainly limited to the external iliac artery) from a distal retrograde, 4-F approach.

Several studies have demonstrated the efficacy of 4-F self-expandable stents in the SFA using an antegrade approach. The nonrandomized multicenter 4EVER study prospectively evaluated 120 patients with SFA disease, with an average lesion length of  $7.2 \pm 4.78$  cm.<sup>2</sup> Primary patency at 12 months was 81.4%, and no difference in outcome was seen between calcified and non-calcified lesions (primary patency at 1 year of 80.2% and 82%, respectively). Similar results were seen in a single-center study evaluating 22 patients with TASC D lesions of the SFA (mean stented length, 245 mm; range, 215–315 mm; mean lesion length, 315 mm).<sup>3</sup> At 12 months, a primary patency rate of 77% was observed, with 86% freedom from target lesion revascularization.

The last study that needs to be mentioned in this context is the PEACE registry, which evaluated 118 patients (all-comers) with a lesion length of  $111.5 \pm 71.4$  mm (56.8% of the cases were chronic total occlusions [CTOs]).<sup>4</sup> At 12 months, the overall primary patency rate was 79.5%, and for lesions with a length > 100 mm, it was 78%. Two other articles have shown that retrograde (popliteal) access for the treatment of SFA disease (using 4-F devices) can safely be performed. Long-term patency rates will not be influenced by whether the procedure

was performed in an antegrade or retrograde fashion. The safety of a 3-F distal puncture is well established, and increasing the size of the sheath up to 4 F appears to have a similar safety profile.<sup>5-8</sup>

The advantage of distal access using 4-F-compatible devices is that this approach can be used in patients in whom antegrade access is not feasible (for previously mentioned reasons). In cases when antegrade access is feasible but crossing of the occlusion remains unsuccessful, it may not be possible to perform a combined antegrade-retrograde approach during the same session. This may be due to lack of patient cooperation, inadequate preparation of the distal access site, or logistical problems regarding room availability. When rescheduling the patient for a retrograde attempt, both proximal (common femoral artery) and distal access sites should be prepared. Distal access using a pedal access set (3-F Micropuncture introducer set, Cook Medical) is achieved first. Recanalization is then attempted using a 3-F-compatible support catheter (eg, 2.6-F CXI support catheter, Cook Medical), with a 0.018-inch CTO guidewire.

After successful crossing (intraluminal or subintimal with proximal re-entry), an exchange over the 0.018-inch guidewire is made for a 4-F introducer sheath (using a dilator with a 0.018-inch lumen). The entire procedure can then subsequently be performed using 4-F-compatible devices (combined with either 0.014- or 0.018-inch guidewires), thus obviating the need for an additional antegrade access site. When proximal reentry fails, a combined antegrade-retrograde rendezvous procedure can be performed.

## CASE STUDY

A representative case of retrograde recanalization using a 4-F distal access site is shown in Figure 1. An 87-year-old woman presented with CLI (Rutherford class 5) with an ulcer on the heel of her left foot. CT angiography revealed an occlusion of the left SFA and the P1 segment of the popliteal artery (with a short patent segment) and diffusely diseased P2 and P3 segments. At the tibial level, a relatively low trifurcation was seen with occlusion of the distal posterior tibial artery and patent fibular and anterior tibial arteries. Diagnostic angiography confirmed the findings from CT angiography (Figure 1A).

An attempt at antegrade recanalization through an ipsilateral common femoral approach failed. Due to lack of patient cooperation, retrograde access during the same session was not feasible, and the patient was rescheduled for a second attempt. The distal popliteal artery was punctured under fluoroscopic guidance from an anterior approach (Figure 1B), and a 3-F pedal access sheath was positioned. Retrograde recanalization was achieved using a 0.018-inch Glidewire Advantage guidewire (Terumo Interventional Systems) and a CXI support catheter (Figure 1C). Subintimal passage of the occlusion and proximal reentry were uneventful.

A 4-F Radifocus Introducer II sheath (Terumo Interventional Systems) with a 0.018-inch dilator lumen was subsequently placed (Figure 1D). Predilation was performed using a 5- X 200-mm Passeo percutaneous transluminal angioplasty (PTA) balloon (Biotronik; Figure 1E). Two Pulsar-18 self-expandable stents (6 X 170 mm; Biotronik) were subsequently positioned (Figure 1F) and postdilated with a 5-mm PTA balloon. Control angiography showed complete flow restoration (Figure 1G) and an absence of distal emboli (not shown). Hemostasis was achieved with manual compression.

## POSSIBLE COMPLICATIONS

The disadvantage of single distal access is the lack of an opportunity to treat distal embolic complications; however, this risk is relatively low. Most emboli will remain stuck on the introducer because there is little space to pass alongside the sheath. If there are emboli on the tip of the sheath, they can easily be aspirated through the sheath. The use of filter devices is also not possible. Furthermore, hemostasis after the procedure may be problematic. Internal balloon hemostasis for a distal access site (often used in cases of a combined antegrade-retrograde approach) cannot be used in a single-access procedure. Therefore, one must ascertain that the puncture site is accessible to external com-

The disadvantage of single distal access is the lack of an opportunity to treat distal embolic complications ...

pression. The easiest access sites to compress are those below the ankle and the popliteal area (zones 1 and 4). Compression of zone 2 (roughly, the lower half of the calf) is already more complex and even more difficult in zone 3 (from trifurcation to mid-calf).<sup>9</sup> Punctures performed in zone 3 are also more prone to complications (compartment syndrome).<sup>9</sup>

## CONCLUSION

Retrograde recanalization and treatment of SFA and popliteal artery occlusions with 4-F-compatible devices, performed entirely from a distal (tibial) access site, are feasible and considered a valid technique in patients who are not amenable to antegrade recanalization. ■

1. Rashid M, Kwok CS, Pancholy S, et al. Radial artery occlusion after transradial interventions: a systematic review and meta-analysis. *J Am Heart Assoc.* 2016;5:pii:e002686.
2. Bosiers M, Deloose K, Callaert J, et al. 4-French-compatible endovascular material is safe and effective in the treatment of femoropopliteal occlusive disease: results of the 4-EVER trial. *J Endovasc Ther.* 2013;20:746-756.
3. Lichtenberg M, Stahlhoff W, Boese D. Superficial femoral artery TASC D registry: twelve-month effectiveness analysis of the Pulsar-18 SE nitinol stent in patients with critical limb ischemia. *J Cardiovasc Surg (Torino).* 2013;54:433-439.
4. Lichtenberg M, Kolks O, Hailer B, et al. PEACE I all-comers registry: patency evaluation after implantation of the 4-French Pulsar-18 self-expanding nitinol stent in femoropopliteal lesions. *J Endovasc Ther.* 2014;21:373-380.
5. Hanna EB, Prout DL. Combined radial-pedal access strategy and radial-pedal rendezvous in the revascularization of complex total occlusions of the superficial femoral artery (the "no femoral access" strategy). *J Endovasc Ther.* 2016;23:321-329.
6. Sabri SS, Hendricks N, Stone J, et al. Retrograde pedal access technique for revascularization of infrainguinal arterial occlusive disease. *J Vasc Interv Radiol.* 2015;26:29-38.
7. Bazan HA, Le L, Donovan M, et al. Retrograde pedal access for patients with critical limb ischemia. *J Vasc Surg.* 2014;60:375-381.
8. El-Sayed H, Bennett ME, Loh TM, et al. Retrograde pedal access and endovascular revascularization: a safe and effective technique for high-risk patients with complex tibial vessel disease. *Ann Vasc Surg.* 2016;31:91-98.
9. Mustapha JA, Fox C, Diaz-Sandoval L, et al. Achieving hemostasis after tibiopedal access. *Endovasc Today.* 2014;13:55-61.

**Jos C. van den Berg, MD, PhD**

Head of Service of Interventional Radiology  
Ospedale Regionale di Lugano  
Lugano, Switzerland  
jos.vandenberg@eoc.ch

Disclosures: None.