

# A Team-Based Strategy for Optimal CLI Care

This fast-track, collaborative approach has made our practice the national benchmark in Italy for achieving low major amputation rates.

**BY FRANCESCO LIISTRO, MD; ITALO PORTO, MD, PhD; PAOLO ANGIOLI, MD; KENNETH DUCCI, MD; GIOVANNI FALSINI, MD; SIMONE GROTTI, MD; LUCIA RICCI, MD; GIORGIO VENTORUZZO, MD; FILIPPO TURINI, MD; GUIDO BELLANDI, MD; AND LEONARDO BOLOGNESE, MD**

Critical limb ischemia (CLI) (characterized by rest pain and/or nonhealing ulcers) is a worldwide emergency because it frequently results in major limb amputation, which is a devastating event with profound physical, psychological, and work-related implications.<sup>1</sup> Often, CLI appears along with “diabetic foot,” a chronic affliction of the lower extremities, with a lifetime risk that is estimated at approximately 15% for diabetics.<sup>2,3</sup> It is caused by micro- and/or macrovascular complications of diabetes (sensory neuropathy, atherosclerosis, and motor, autonomic, or proprioceptive alterations) and by the altered response and resistance to infection.<sup>4</sup> The macroangiopathy can also affect the coronary and cerebral anatomy.<sup>5</sup>

The clinical expression ranges from plantar morphostructural abnormalities, to the appearance of superficial and deep ulcers, to the exposure of osteoarticular structures. The ulcers may be complicated by acute (cellulitis, phlegmon, abscesses) and chronic infections (osteomyelitis), which, exacerbated by ischemia, can result in gangrene.<sup>6</sup> More rarely, a complete structural disruption with severe deformities (Charcot neuroarthropathy) may occur, and such a situation is at high risk of ulceration, osteomyelitis, and amputation.<sup>7</sup> Moreover, the financial costs involved in the treatment of CLI are enormous.

## FAST-TRACK TEAM APPROACH

Recently, improved awareness of the need for limb preservation has given rise to the idea of integrated amputation prevention programs in which specialized multidisciplinary

teams cooperate in the medical/surgical management of these patients.<sup>8</sup> In the Arezzo province of Tuscany, Central Italy, we strive to achieve excellence in the management of diabetic foot and CLI. A regional law of 2003 dictating the local guidelines for the management of diabetic foot, coupled with the presence of a high-volume diabetic foot clinic with dedicated personnel and surgical competencies, has sparked the initial development of our integrated approach.

This has been followed by the establishment of a daily collaborative interaction with interventional cardiologists (mainly in charge of the endovascular approach), vascular surgeons (mainly responsible for the open surgical approach, but also involved in endovascular procedures), infectious disease specialists, and orthopedic surgeons (Figure 1). Different from other approaches, no single physician leads the team. A podiatrist and two specially trained nurses are also essential members of the team. Of note, the cardiovascular laboratory interventional team (including nurses and radiology technicians) and the two cath labs are shared between the vascular surgeons and interventional cardiologists, as these specialists often work side by side.

The implementation of a team approach has led to a systematic process for patient screening, evaluation, treatment, and follow-up. The results, as certified in the national evaluation, have made Arezzo the national benchmark. The number of major amputations in Italy ranges between 34 to 43 per million inhabitants, whereas in the Arezzo province (350,000 residents and more than 14,000 diabetics), major amputations occur in between 6 to 12 per million inhabit-

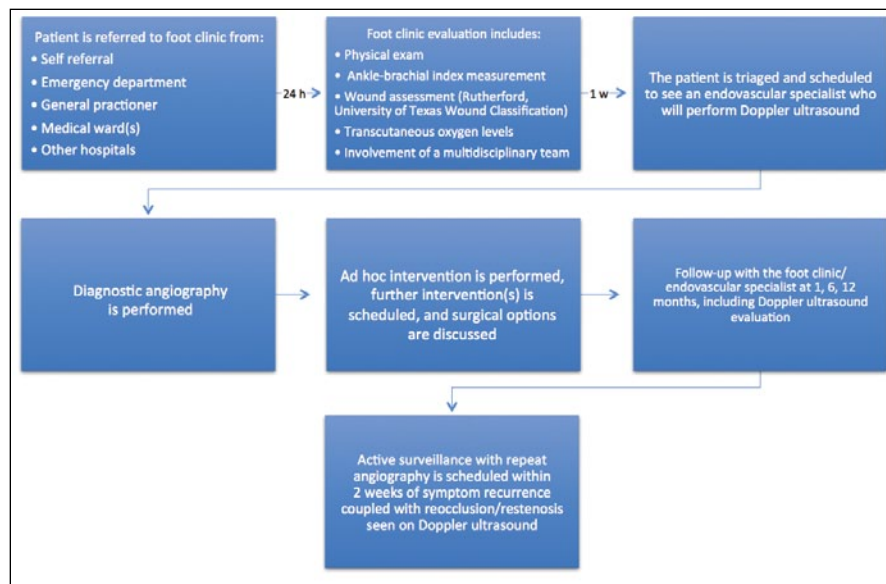


Figure 1. The Arezzo Team Approach patient care algorithm.

ants, meaning that there are no major amputations at all some years, such as in 2009.

The core strategy leading to these results has been the implementation of a fast-track approach centering on a proactive role of the foot specialist and on the direct involvement of the endovascular specialist (either an interventional cardiologist or a vascular surgeon) in the diagnostic phase (Figure 1).

If CLI is suspected during clinical examination by the foot specialist, rapid-access intervention-oriented Doppler ultrasound examination is performed directly by the endovascular specialist who will execute the possible angiography. Our goal has been to achieve these steps within days (maximum of 1 week) from the foot specialist's request.

If a definitive diagnosis of CLI is established and neuropathic gangrene is ruled out, culprit limb angiography and revascularization (with an endovascular-first approach) is attempted within 2 weeks in all cases. Once discharged, all patients are asked to return at specified intervals (at 1 month, then every 6 months) to a dedicated clinic run by the endovascular specialists for follow-up with control Doppler ultrasound. The foot specialist reviews the patients during the same appointment. The dedicated endovascular clinic also forms the backbone of our clinical research activity, which has so far produced several randomized, industry-independent trials published in high-impact journals.<sup>9-11</sup>

Outside this scheduled follow-up scheme, the foot specialist also plays a crucial role in dictating the indication to repeat revascularization, alerting the endovascular specialist regarding the clinical outcome of the ulcer (no healing,

onset of new lesion, decrease/increase in ulcer behavior, or reoccurrence of rest pain), and prompting a Doppler evaluation of the treated or contralateral limb. Clearly, the foot specialist is in a key position to judge whether the clinical scenario depends on the arterial flow or on other components such as infections, antibiotic resistance, or osteomyelitis.

In our experience, this fast-track, team-based approach is linked to a very low incidence of major amputations, which remain confined to patients with an absence of foot and digital arteries, such as those on dialysis treatment.

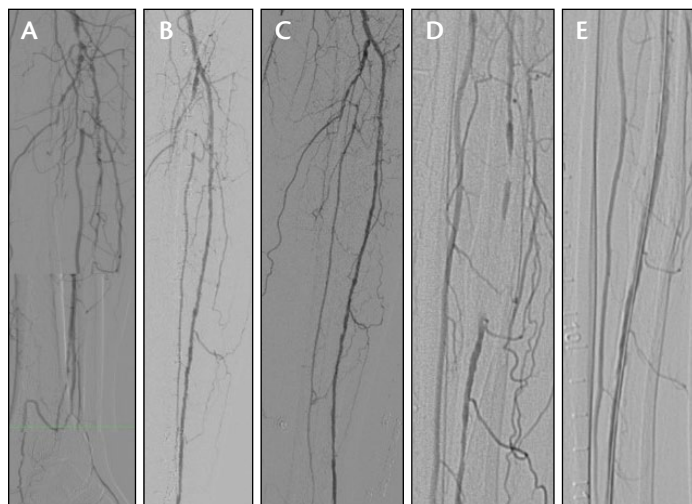
## INTERVENTIONAL APPROACH TO CLI

The complex clinical scenario of CLI in patients with diabetes requires integration between the vascular anatomy, the interventional possibilities, and the comorbidities of the patient in order to select the appropriate revascularization strategy. In our opinion, the professional figure responsible for this integration is the endovascular specialist, who must acquire the skills needed to perform a global ultrasound evaluation of the affected limb(s), as well as a quick evaluation of the intra-abdominal vessels (aortic bifurcation, iliac arteries) and at least a basic evaluation of cardiac function. The subsequent step must be the careful planning of interventional solutions, including the decision of whether the strategy can be completed in one or multiple sessions.

The majority of diabetic patients with CLI will show moderate-to-severe renal functional impairment, and more than 50% will present with inflow and outflow stenosis/occlusion.<sup>1</sup> In most of these cases, a multisession revascularization strategy (first inflow and then outflow treatment soon after) is preferred in order to limit the occurrence of contrast-induced nephropathy. The knowledge of left ventricular function parameters is also mandatory to prevent hemodynamic instability during complex, long interventions and provide an appropriate medical treatment.

## CASE EXAMPLE

A 75-year-old man with long-standing type 2 diabetes mellitus was admitted to our department in November 2011 for bilateral CLI with University of Texas Diabetic Wound Classification ulcers stage IIID on the left foot and IIIC on the right foot, which had occurred in the last month.



**Figure 2.** Distal popliteal artery subocclusion, occlusion of the ATA, and tibioperoneal trunk; collateral filling of the proximal peroneal artery (A). Recanalization of the ATA and angiographic result after angioplasty (B). Persisting optimal angiographic result at 1 year (C). Nonocclusive restenosis of the ATA 30 months after the initial procedure (D). Optimal angiographic result after repeat angioplasty of the ATA (E).

He was evaluated by the foot specialist 4 days before hospital admission. The patient had a previous myocardial infarction, which was treated with percutaneous coronary intervention in the right coronary artery. He also had chronic kidney disease, with a calculated glomerular filtration rate (GFR) of 30 mL/min/1.73 m<sup>2</sup>.

Ultrasound evaluation of both limbs showed massive calcification of all vessels. On the left side, the femoral arteries were patent, but there was a distal popliteal artery subocclusion and occlusion of the anterior tibial artery (ATA) and tibioperoneal trunk, with collateral filling of the proximal peroneal artery, which in turn provided collateral filling of the distal dorsalis pedis and plantar arteries (Figure 2A). On the right side, there was complete proximal occlusion of the superficial femoral artery (SFA) with collateral filling at the level of the Hunter segment, patency of the popliteal artery, and occlusion of the proximal ATA and posterior tibial artery (PTA), with collateral filling of the dorsalis pedis and plantar arteries (Figure 3A, C, and D). Left ventricular function was normal, with an ejection fraction of 55%, and no significant stenoses in the carotid arteries were observed.

According to the patient's GFR and the extent of vascular involvement, the multisession revascularization strategy included immediate left limb revascularization, with right limb revascularization deferred for 1 month (or earlier if the foot lesions worsened). After hydration and N-acetyl-cysteine administration to prevent contrast-induced nephropathy, left limb revasculariza-

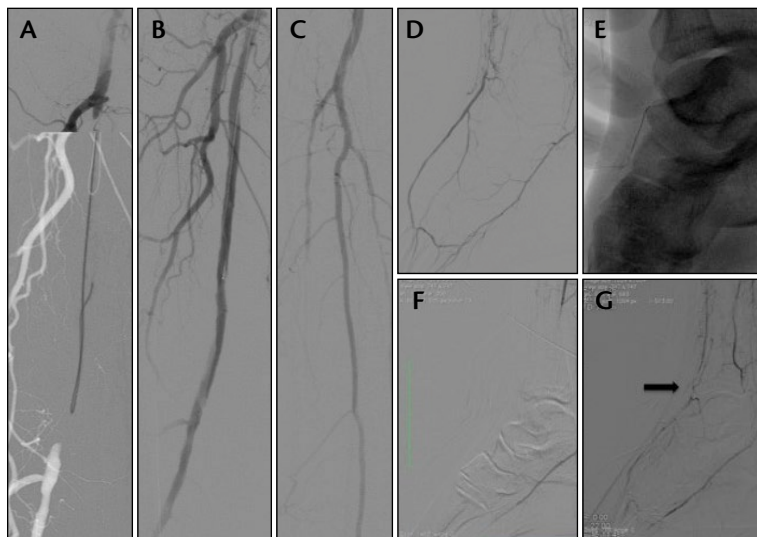tion was performed by an antegrade femoral approach, and according to the angiosome concept, the left ATA was recanalized and treated using multiple Amphirion In.Pact drug-coated balloons (DCBs; Medtronic, Inc. [please note, this device has since been recalled]; sizes: 2.5 X 120 mm, 2.5 X 120 mm, 3 X 80 mm, 3 X 40 mm) (Figure 2B).

The patient was discharged the day after the procedure (his creatinine level was stable at 24 hours) with a recommendation to present to the foot clinic twice a week and to undergo creatinine measurement at 1 week. The foot specialist confirmed the success of the interventional procedure by visualizing the ongoing healing process. A Doppler evaluation of the left ATA was performed 1 month later, showing optimal patency of the vessel with direct flow to the healing foot. Thus, the patient was readmitted for right limb revascularization.

The right SFA was recanalized with an antegrade approach in a subintimal fashion and treated with Pacific In.Pact DCBs (Medtronic, Inc.) (sizes: 5 X 120 mm, 5 X 120 mm) with a good result (Figure 3B). An antegrade attempt to recanalize the right ATA was performed without success due to massive calcification at the dorsalis pedis reentry site. Thus, a retrograde approach via direct puncture of the right dorsalis pedis artery was undertaken, but again without success due to the short artery segment available for puncture (Figure 3E).

The last interventional option remaining was recanalization of the PTA and retrograde recanalization of the ATA via pedal-plantar loop. We managed to reopen the PTA, but no pathway for the plantar loop was found (Figure 3F). We then decided to stop the procedure due to the amount of dye used (70 mL) and planned another attempt with a "plantar-loop surfing" technique (Figure 3G). The patient was discharged the next day and was readmitted only 2 weeks later because no evidence of healing was observed.

At the time of the third interventional procedure, the patient's GFR was stable, and angiography showed reocclusion of the right PTA that was previously reopened, with collateral filling of the right dorsalis pedis artery (Figure 4A). An attempt to reopen the PTA and "surf" through the pedal-plantar loop was successfully performed using the FineCross microcatheter (Terumo Interventional Systems), and the distal cap of the ATA occlusion was crossed with a 0.014-inch Graphix standard guidewire (Boston Scientific Corporation) mounted on a coronary over-the-wire balloon. The occlusion was then dilated via the retrograde wire with a 2.5- X 120-mm Amphirion Deep balloon (Medtronic, Inc.), and an antegrade wire could then be navigated through the ATA for final delivery of Amphirion IN.Pact



**Figure 3.** Ostial occlusion of the right SFA with collateral filling of the Hunter segment; the occlusion was recanalized in a subintimal fashion (A). Optimal angiographic result after DCB use in the SFA (B). Occlusion of the proximal right ATA, and PTA (C). Peroneal artery filling the plantars and the anterior pedis artery (D). Retrograde access to the ATA was attempted but not successful because massive calcification of the distal occlusion cap and the short arterial segment prevented retrograde navigation (E). Recanalization of the PTA but no possibility to “surf” the pedal-plantar loop (F). Good angiographic result after angioplasty of the PTA; retrograde filling of the anterior pedis artery and antegrade filling (subintimal) of the ATA up to the distal occlusion site (G).

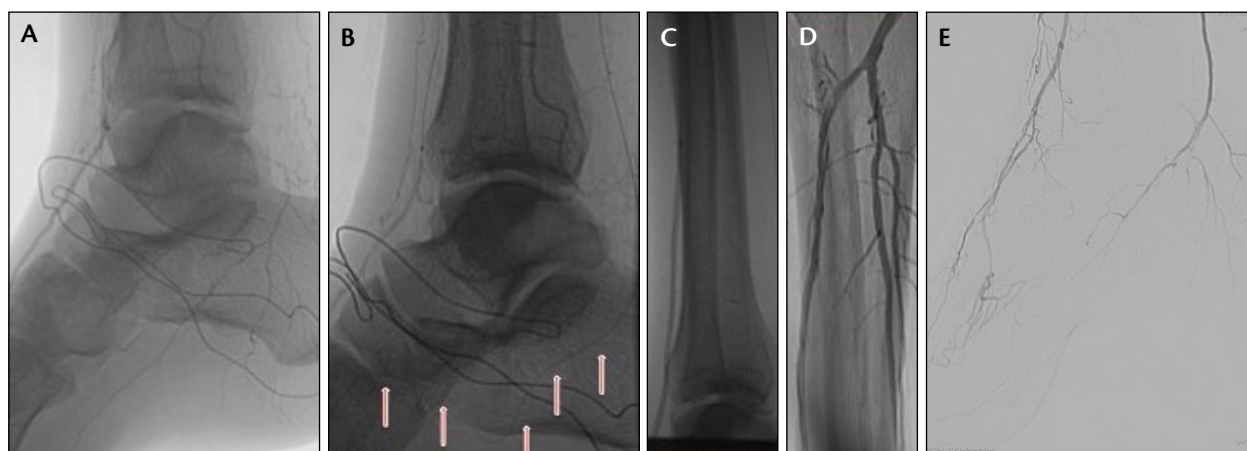
DCBs (sizes: 2.5 X 120 mm, 3 X 120 mm, 3 X 120 mm), which restored direct flow to dorsalis pedis and digital arteries (Figure 4B through E). The patient was discharged the next day with a prespecified foot clinic and Doppler evaluation schedule.

## DISCUSSION

Diabetic patients with CLI represent an extremely high-risk subset and deserve a proven clinical pathway. In the case presented, the extent of vascular involvement (mul-

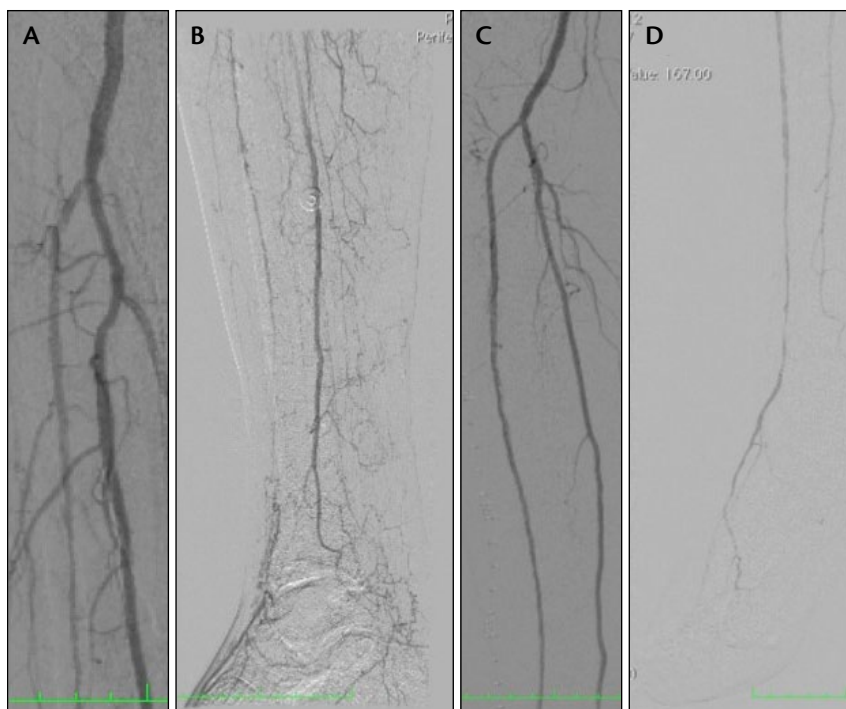
The right and left foot ulcers healed within 3 months, and further Doppler and clinical evaluations showed an optimal interventional and clinical outcome until a year later when a new-onset, first right toe ulcer occurred. Immediate Doppler evaluation and angiography showed focal restenosis in the right SFA, complete reocclusion of the previously treated PTA, and a short reocclusion of the distal ATA. DCB angioplasty was performed again in the SFA and ATA with an optimal angiographic result (Figure 5). His GFR was stable at discharge, and the right toe ulcer healed in 2 months.

Two years after left limb revascularization, a new ulcer appeared on the first and second left toes, and immediate Doppler evaluation showed restenosis at two focal points in the left ATA. Another revascularization procedure was performed within 3 days of diagnosis using DCBs in the left ATA. In the following months, the patient's GFR decreased from 30 mL/min/1.73 m<sup>2</sup> to 20 mL/min/1.73 m<sup>2</sup>, but both feet healed, and amputation was avoided. Overall, the patient underwent eight Doppler evaluations by an endovascular specialist, five hospital admissions for five interventional procedures, and 28 foot clinic visits within 2.5 years.



**Figure 4.** Reocclusion of the right PTA, with collateral filling of the anterior pedis artery (A). Successful “surfing” of the pedal-plantar loop with retrograde crossing of the distal ATA occlusion (B). Dilatation of the ATA with an optimal angiographic result and increased flow to the foot circulation (C–E).





**Figure 5.** Patency of the proximal segment of the right ATA, which occludes distally (A, B). Optimal angiographic result after repeat DCB angioplasty in the ATA (C, D).

tidistrict, multilevel, long occlusions) associated with low GFR represented a real challenge for our entire team, and a dedicated revascularization, foot specialist–driven treatment and clinical program was essential for success. Our goal was both limb salvage and avoidance of complications (especially, contrast-induced nephropathy).

The fast-track strategy adopted in this case (with less than a week interval between diagnosis and treatments) ensured rapid re-establishment of direct flow to the foot and prevented a larger extent of tissue loss. The combination of a wise, although aggressive, interventional strategy together with continued ulceration debridement, healing process evaluation, appropriate medical therapy, and immediate ultrasound evaluation in case of possible CLI recurrence are the keys to success in CLI treatment. ■

*Francesco Liistro, MD, is with the Cardiovascular Department, San Donato Hospital in Arezzo, Italy. He stated that he has no financial interests related to this article. Dr. Liistro may be reached at +39 0575 255617; francescoliiistro@hotmail.com.*

*Italo Porto, MD, PhD, is with the Cardiovascular Department, San Donato Hospital in Arezzo, Italy. He stated that he has no financial interests related to this article.*

*Paolo Angioli, MD, is with the Cardiovascular Department, San Donato Hospital in Arezzo, Italy. He stated that he has no financial interests related to this article.*

*Kenneth Ducci, MD, is with the Cardiovascular Department, San Donato Hospital in Arezzo, Italy. He stated that he has no financial interests related to this article.*

*Giovanni Falsini, MD, is with the Cardiovascular Department, San Donato Hospital in Arezzo, Italy. He stated that he has no financial interests related to this article.*

*Simone Grotti, MD, is with the Cardiovascular Department, San Donato Hospital in Arezzo, Italy, and the Department of Cardiovascular Diseases, University of Siena, Le Scotte Hospital in Siena, Italy. He stated that he has no financial interests related to this article.*

*Lucia Ricci, MD, is with the Diabetes Unit, San Donato Hospital in Arezzo, Italy. She stated that she has no financial interests related to this article.*

*Giorgio Ventrone, MD, is with the Cardiovascular Department, San Donato Hospital in Arezzo, Italy. He*

*stated that he has no financial interests related to this article.*

*Filippo Turini, MD, is with the Cardiovascular Department, San Donato Hospital in Arezzo, Italy. He stated that he has no financial interests related to this article.*

*Guido Bellandi, MD, is with the Cardiovascular Department, San Donato Hospital in Arezzo, Italy. He stated that he has no financial interests related to this article.*

*Leonardo Bolognese, MD, is with the Cardiovascular Department, San Donato Hospital in Arezzo, Italy. He stated that he has no financial interests related to this article.*

1. Clair D, Shah S, Weber J. Current state of diagnosis and management of critical limb ischemia. *Curr Cardiol Rep*. 2012;14:160-170.
2. Gregg EW, Li Y, Wang J, et al. Changes in diabetes-related complications in the United States, 1990–2010. *N Engl J Med*. 2014;370:1514–1523.
3. Pataky Z, Hermann FR, Regat D, Vuagnat H. The prevalence of at-risk foot in patients with diabetes mellitus, patients without diabetes mellitus with neurological disorders, and subjects without known diabetes mellitus or lower limb sensory loss. *J Am Geriatr Soc*. 2008;56:180–181.
4. Fowler MJ. Microvascular and macrovascular complications of diabetes. *Clin Diabetes*. 2008;26:77–82.
5. Liistro F, Angioli P, Grotti S, et al. Impact of critical limb ischemia on long-term cardiac mortality in diabetic patients undergoing percutaneous coronary revascularization. *Diabetes Care*. 2013;36:1495–1500.
6. Jeffcoate WJ, Price P, Harding KG. Wound healing and treatments for people with diabetic foot ulcers. *Diabetes Metab Res Rev*. 2004;20(suppl 1):S78–89.
7. Rogers LC, Frykberg RG, Armstrong DG, et al. The Charcot foot in diabetes. *Diabetes Care*. 2011;34:2123–2129.
8. Alexandrescu V, Hubermont G, Coessens V, et al. Why a multidisciplinary team may represent a key factor for lowering the inferior limb loss rate in diabetic neuro-vascular wounds: application in a departmental institution. *Acta Chir Belg*. 2009;109:694–700.
9. Liistro F, Angioli P, Porto I, et al. Paclitaxel-eluting balloon vs. standard angioplasty to reduce recurrent restenosis in diabetic patients with in-stent restenosis of the superficial femoral and proximal popliteal arteries: the DEBATE-ISR study. *J Endovasc Ther*. 2014;21:1–8.
10. Liistro F, Grotti S, Porto I, et al. Drug-eluting balloon in peripheral intervention for the superficial femoral artery: the DEBATE-SFA randomized trial (drug eluting balloon in peripheral intervention for the superficial femoral artery). *JACC Cardiovasc Interv*. 2013;6:1295–1302.
11. Liistro F, Porto I, Angioli P, et al. Drug-eluting balloon in peripheral intervention for below the knee angioplasty evaluation (DEBATE-BTK): a randomized trial in diabetic patients with critical limb ischemia. *Circulation*. 2013;128:615–621.