

# Assessing Patency After Endovascular Treatment of Patients With CLI

Surveillance strategies and decision making processes.

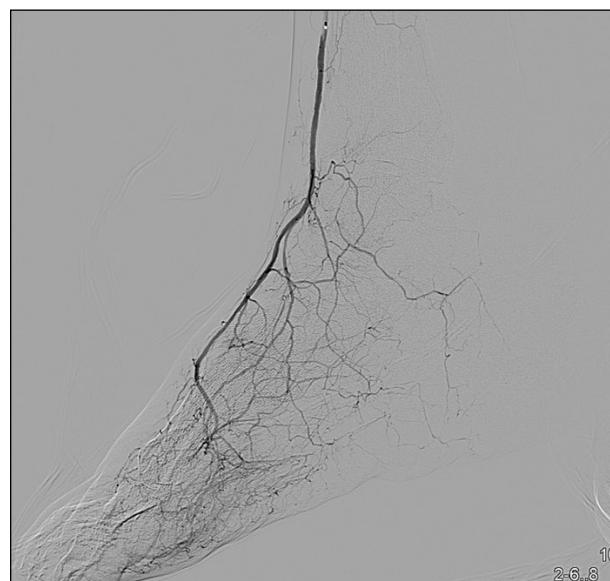
**BY R. KEVIN ROGERS, MD, MSc, RPVI, AND ARASH AGHEL, MD**

**B**y definition, critical limb ischemia (CLI) is the presence of ischemic rest pain or nonhealing wounds for > 2 weeks in the presence of reduced perfusion to the affected limb.<sup>1</sup> The thresholds to define reduced perfusion commonly include an ankle pressure < 50 to 70 mm Hg or a first toe pressure < 30 to 50 mm Hg.<sup>2</sup> Clinically, it can at times be difficult to attribute ischemia as the sole cause of a wound; however, ischemia may still contribute to poor healing. There is a strong association between CLI and amputation and death.<sup>3</sup> Revascularization is often pursued to avoid amputation or to limit the extent of amputation with the goal of improving quality of life.

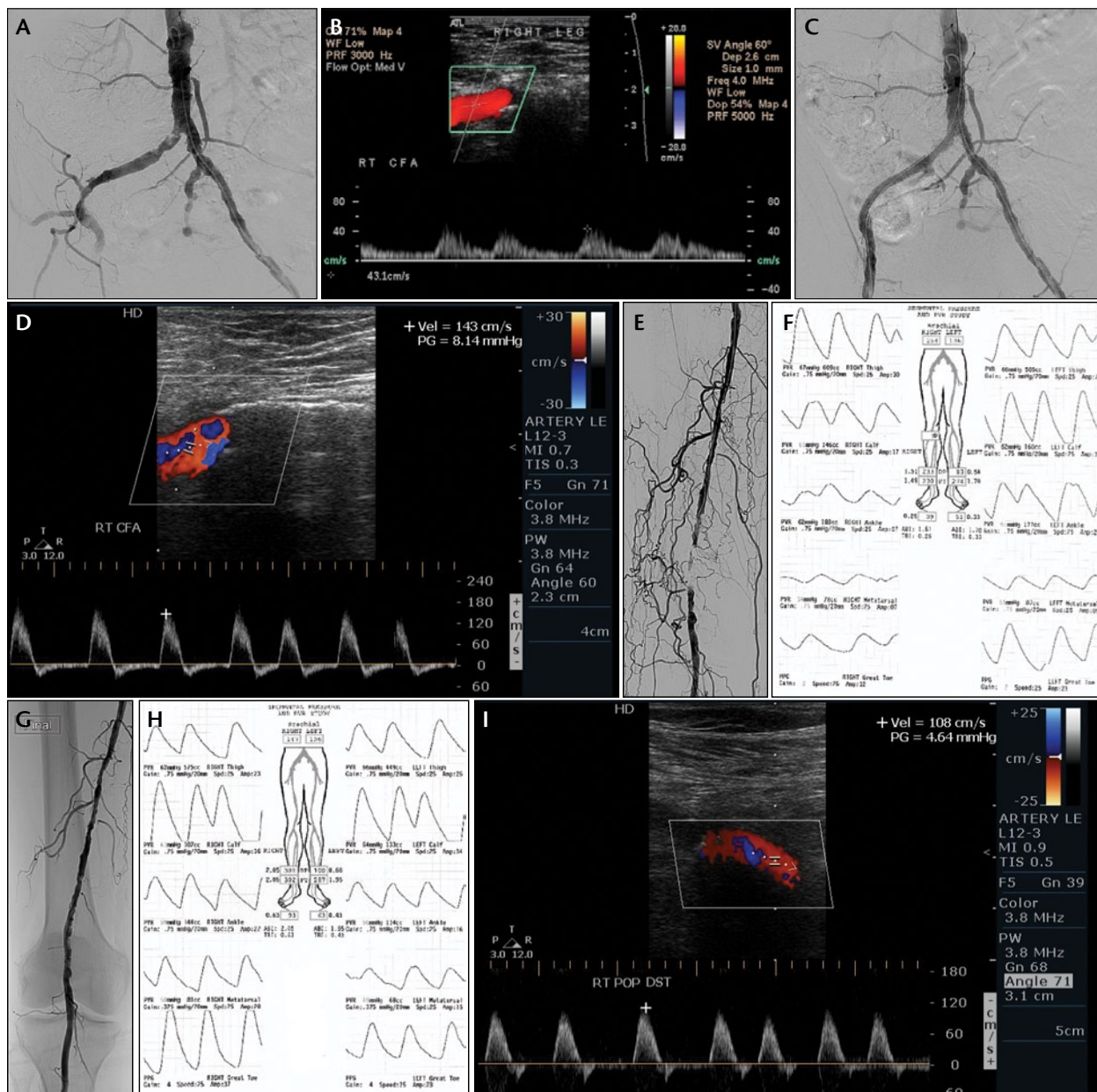
There are no randomized trial data to guide decisions on the optimal surveillance strategies after endovascular treatment in patients with CLI. For surveillance of surgical bypass grafts, a randomized trial has been performed comparing clinical exam, ankle-brachial index measurement and duplex ultrasonography with clinical exam, and ankle-brachial index measurement alone for the surveillance of femoropopliteal or femoral-tibioperoneal vein grafts.<sup>4</sup> Surveillance was performed at the time of enrollment and at 3, 6, 9, 12, and 18 months after revascularization.<sup>4</sup> No differences in amputation, vascular mortality, patency, or health-related quality of life were found. However, this evidence is not generalizable to endovascular interventions for CLI, given the different mode of revascularization and inclusion of claudicants.

The most recent guidelines from the American College of Cardiology Foundation and American Heart

Association (ACCF/AHA) recommend that patients with CLI who have been successfully treated be evaluated by a vascular specialist at least twice a year (Class I, level of evidence C).<sup>5</sup> These guidelines also state that patients with a history of CLI should receive instructions on self-surveillance (Class I, level of evidence C).<sup>5</sup> A Class IIa, level of evidence C recommendation was given that patients with claudication or CLI who had undergone endovascular therapy could be evaluated in a surveillance program with physiologic assessment or imaging.<sup>5</sup> However, it is



**Figure 1. Selective distal anterior tibial angiography.**



**Figure 2.** Catheter-based and noninvasive assessment of a patient with CLI manifested by rest pain and nonhealing first toe ulcer. Aortoiliac angiogram showing severe proximal and distal right common iliac artery stenosis with delayed filling of the external iliac artery compared to the contralateral side (A). Spectral Doppler waveform of the right common femoral artery showing severely blunted biphasic waveform, suggesting more proximal obstructive disease (B). After revascularization of the right common iliac artery, the spectral Doppler waveform in the right common femoral artery is now normal and triphasic with improved velocities (C, D). Arterial duplex ultrasound of the right common femoral artery: spectral Doppler waveform of the right common femoral artery after iliac stenting showing a triphasic waveform with improved velocities (D). In this patient, the common femoral artery spectral Doppler waveform and femoral pulse exam were used to follow for patency of the common iliac intervention. The same patient also had an above-knee popliteal artery occlusion detected by duplex ultrasonography (not shown) that is demonstrated on catheter-based angiography done at the time of intervention (E). Before popliteal revascularization, the right calf pulse volume recording (PVR) was abnormal ( $< 1.5$  times the amplitude of the thigh waveform), and the toe pressure was significantly abnormal (39 mm Hg; toe-brachial index, 0.25). Following popliteal atherectomy (G), the calf PVR and toe pressure improved (93 mm Hg; toe-brachial index, 0.63) (H). Duplex ultrasonography now shows a patent right popliteal artery (I).

difficult to propose rigid, detailed surveillance strategies for patients with CLI given the complexity of this patient population.

The degree of arterial perfusion to heal a wound exceeds the degree of arterial flow necessary to maintain relatively healthy tissue integrity.<sup>2</sup> Thus, patency goals after revascularization are different for patients with non-healing wounds as compared to patients with ischemic rest pain. The clinical indication for revascularization in patients with CLI affects decisions for surveillance strategies. Likewise, there are anatomic and technical differences across aortoiliac, femoropopliteal, tibioperoneal, and pedal interventions that affect patency. Suitable clinical tools to assess for patency across these different levels of disease also differ.<sup>6</sup>

In summary, there is a lack of evidence and detailed guidelines for surveillance following endovascular treatment in patients with CLI. In light of this, strategies for surveillance for patency—as well as decisions for reintervention to maintain patency—can be approached based on the following in patients with CLI: (1) clinical indication and (2) level of disease. This article discusses available clinical modalities for assessing patency and outcomes in patients with CLI who have undergone intervention. Surveillance strategies for revascularization for acute limb ischemia and for bypass grafts are beyond the scope of this article.

## MODALITIES FOR ASSESSING PATENCY

### Physical Exam

The physical exam is critical in assessing patency of aortoiliac revascularization, for evaluation of patency of below-the-knee interventions in patients with noncompressible vessels or previous minor amputation precluding toe pressures, and for evaluating progress of wound healing. Strong femoral pulses are reassuring for patent aortoiliac inflow. Although they are subjective, serial continuous-wave Doppler exams of the pedal pulses by the same provider are useful indicators of patency for tibioperoneal and pedal interventions.

### Cross-Sectional Imaging

Cross-sectional imaging with CT or MR angiography has limitations for surveillance following revascularization in patients with CLI. These limitations include cost, use of contrast, radiation, and little incremental clinical value to duplex ultrasound, hemodynamic assessment, and physical exam in infrainguinal disease.<sup>7</sup> The ACCF/AHA give a Class IIb, level of evidence B recommendation for surveillance with MR angiography in patients who have undergone revascularization.<sup>5</sup> CT angiography is recommended for patients with contraindications to MR imaging.<sup>5</sup>

### Duplex Ultrasonography

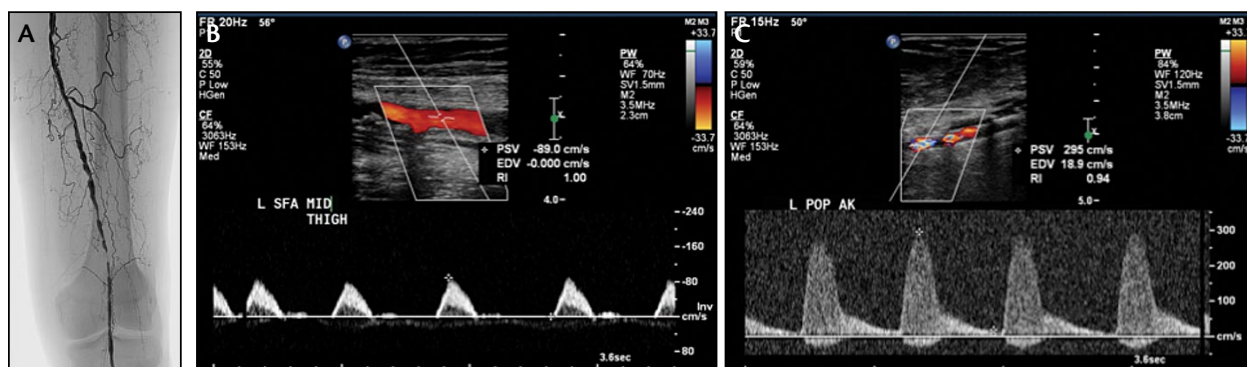
Duplex ultrasonography is an excellent modality to assess patency of femoropopliteal vessels. It is less useful for aortoiliac anatomy due to patient habitus and/or bowel gas.<sup>6,7</sup> Tibioperoneal vessels are difficult to image comprehensively with duplex ultrasound due to the inability of ultrasound waves to penetrate through overlying musculoskeletal structures.

### Hemodynamic Measurements

Physiologic assessment in a vascular diagnostic laboratory includes:

1. Segmental limb pressures, including high thigh, low thigh, calf, ankle, and toe pressures;
2. Pulse-volume recordings at the high thigh, low thigh, calf, ankle, and metatarsal levels;
3. Continuous-wave Doppler tracings at the high thigh, low thigh, calf, dorsalis pedis, and posterior tibial areas;
4. Photoplethysmographic tracings at the first toes.

These assessments are central for the vascular physician to care for patients with CLI and follow for secondary patency. Caution should be used in obtaining pressures in previously stented or bypassed segments.



**Figure 3.** A 90-year-old man with CLI that was manifested by a nonhealing toe ulcer. The patient had undergone multiple popliteal interventions in the setting of severe profunda femoral disease and single-vessel tibioperoneal runoff. Catheter-based angiogram showing critical stenosis in the above-knee popliteal that was originally detected on surveillance duplex ultrasonography (A). Surveillance Duplex ultrasound shows increase in peak systolic velocity consistent with severe stenosis in the above-knee popliteal artery (B, C). A drug-coated stent was placed based on these findings for limb salvage.

The ACCF/AHA give a Class IIa, level of evidence B recommendation of the use of pulse-volume recordings to assess for patency following revascularization in patients with peripheral arterial disease (PAD) and a Class I, level of evidence B statement for continuous wave Doppler waveforms in this setting.<sup>5</sup>

### Catheter-Based Angiography

Catheter-based angiography is the gold standard for anatomic definition of PAD. Although radiation and contrast are required, the doses are typically less as compared to CT angiography. A limitation for catheter-based angiography is access-related complications, although these are infrequent. As such, this modality is often reserved for situations in which intervention is anticipated or there is clinical deterioration, rather than for surveillance in the stable or improving patient. The ACCF/AHA recommends selective or superselective catheter placement to enhance anatomic definition and reduce contrast exposure (Class I, level of evidence C).<sup>5</sup> This technique is particularly important for tibioperoneal and pedal angiography (Figure 1).

### Transcutaneous Oximetry

Although theoretically applicable, serial transcutaneous oximetry measurements are limited by variability due to factors unrelated to patency, such as edema, vasoconstriction, and infection.

## THE IMPACT OF CLINICAL INDICATION FOR REVASCUARIZATION ON SURVEILLANCE

### Rest Pain

Patients with ischemic rest pain require a durable revascularization result for the clinical goal of ongoing relief of rest pain. As such, surveillance would likely be

lifelong in these patients, and reintervention would be indicated if restenosis is found in order to avoid recurrence of symptoms. If an aggressive secondary patency and reintervention strategy is not attractive due to patient or anatomic factors, then revascularization might be deferred.

### Nonhealing Wound

There are often different patency goals for patients with wounds as compared to patients with rest pain. Maintaining patency may only be necessary for a period sufficient for wound healing. Restenosis after wound healing may be clinically insignificant. Several clinical situations exist for patients with nonhealing wounds, each with different surveillance strategies.

If the etiology of a wound is ischemic and the expected outcome of restenosis or reocclusion is tissue loss, then aggressive surveillance and reintervention is indicated.

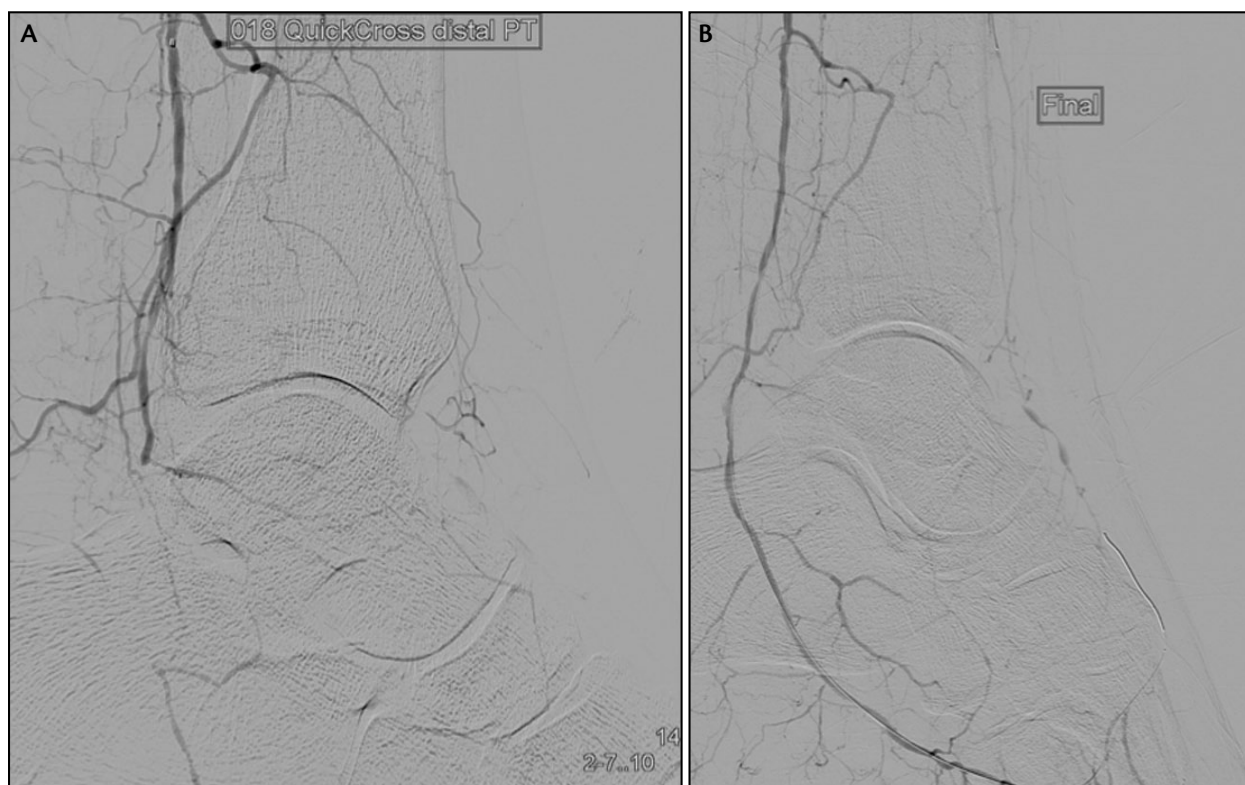
If the etiology of a nonhealing wound is likely non-ischemic in the setting of concomitant obstructive PAD, then close surveillance with testing may only be required until the wound is healed. For example, a hospitalized patient develops a heel pressure wound that does not heal due to severe concomitant PAD. After revascularization, the wound heals. Restenosis is not expected to cause a recurrent wound with proper offloading of the wound and preventive measures.

If revascularization is performed to facilitate healing of a minor amputation, then close surveillance with testing may only be necessary until the surgical site has healed.

### LEVEL OF DISEASE

Patency and the modalities that are useful to monitor patency differ among various anatomic levels of disease.





**Figure 4.** Distal posterior tibial artery occlusion extending into lateral plantar artery (A) treated with angioplasty (B) in a patient with a plantar wound. Surveillance was performed with toe pressures and wound exam.

### Aortoiliac

Aortoiliac disease is rarely the only anatomic segment affected in patients with CLI (Figure 2).<sup>3</sup> Primary patency after aortoiliac angioplasty and stenting is favorable and approached 90% at 1 year in a series of CLI patients.<sup>8</sup> Direct visualization by duplex ultrasonography of the aortoiliac segments is often challenging due to patient body habitus and bowel gas. Instructing patients to fast before duplex ultrasonography can facilitate a thorough exam of these segments. Common femoral pulse palpation is a subjective, albeit important, modality of assessing for patency. Comparison of thigh-brachial or ankle-brachial pressures before and after revascularization is a very useful and noninvasive way to assess for patency. Cross-sectional imaging visualizes aortoiliac segments well but requires contrast and/or radiation. Given the relatively high patency of revascularization at this level, we favor physical exam and physiologic studies for surveillance of aortoiliac revascularization.

### Femoropopliteal

The prevalence of obstructive atherosclerotic disease of the superficial femoral artery is extremely high in patients with PAD.<sup>9</sup> Achieving acceptable patency following endovascular or surgical revascularization is chal-

lenging but improving with newer devices. For example, in a trial comparing drug-coated stents to angioplasty, the primary patency rate for the drug-coated stent arm was 75% at 2 years.<sup>10</sup> Of note, the lesion and patient complexity were likely less than that encountered in a CLI population.

Duplex ultrasonography is an excellent modality to examine revascularized femoropopliteal segments for patency (Figure 3). Physiologic studies at the calf, ankle, and foot can provide additional data. Minimal incremental clinical utility would be expected from CT, MR, or catheter-based angiography.

### Tibioperoneal

The prevalence of tibioperoneal disease in patients with CLI is impressively high.<sup>9</sup> In a series of 450 patients with CLI, 70% of participants had a complete occlusion of a tibioperoneal artery.<sup>9</sup> As such, surveillance strategies for this anatomic segment are particularly germane when managing CLI.

As mentioned previously, duplex ultrasonography cannot comprehensively examine all segments of the tibioperoneal arteries due to overlying musculoskeletal structures. CT angiography lacks the spatial resolution to adequately characterize the tibioperoneal vessels in detail, and dense

calcification can produce artifact.<sup>6</sup> MR angiography is an impractical surveillance tool in this setting due to cost and unrealistic requirements for patients to be motionless for an extended period of time. As such, physiologic assessments and physical exam are the cornerstone of following patients after revascularization of tibioperoneal arteries. Unfortunately, patients with tibioperoneal disease often have noncompressible vessels, rendering the ankle-brachial index useless. Comparing ankle and metatarsal PVRs, toe pressures, and toe photoplethysmographic tracings before and after the procedure can be useful when assessing patency after tibioperoneal revascularization. Catheter-based angiography can be useful to assess for patency, particularly when a patient's clinical status is deteriorating or physiologic assessments are equivocal (Figure 4).

### Pedal

Pedal revascularization is the most challenging of anatomic segments to survey for patency. Such interventions are typically reserved for nonhealing wounds, and following the progress of wound healing can lend insight into patency. Serial toe pressures and continuous wave Doppler assessments as part of a physical exam are helpful. In contrast to other levels of disease, there is a lower threshold to perform catheter-based angiography to monitor for patency following pedal revascularization in the nonimproving or deteriorating patient.

### TIMING OF SURVEILLANCE

There is scant evidence to guide decisions on the timing of surveillance after endovascular treatment for patients with CLI. A Class I, level of evidence C recommendation exists for evaluation of a patient with CLI 2 weeks after revascularization.<sup>5</sup> In the stable patient with a history of CLI, the AHA/ACCF recommends evaluation every 6 months at a minimum (Class I, level of evidence C).<sup>5</sup> In our practice, we see patients with active CLI at 2 weeks and then every 1 to 3 months after revascularization to assess for patency. Factors that favor more frequent monitoring include worsening clinical status, presence of a wound rather than ischemic rest pain, and lower probability of patency. We follow patients with healed wounds and/or resolution ischemic rest pain every 3 to 6 months. Variables favoring more frequent assessment in this setting include expected limb threat were restenosis to occur, lower probability of long-term patency, and complexity of reintervention should occlusion recur.

### DECISIONS FOR REINTERVENTION TO ACHIEVE SECONDARY PATENCY

The decision for reintervention must include considerations for procedural risk and patient preferences and

the expected outcome of restenosis. The following situations favor reintervention in the setting of restenosis:

- Wound has not yet healed.
- Recurrence of ischemic rest pain or wound.
- Expected result of restenosis is recurrent tissue loss or rest pain.

In contrast, examples of situations favoring conservative management of restenosis include the following:

- Healed wound without expected recurrence of wound. For example, a hospitalized patient develops a heel pressure wound that does not heal due to concomitant PAD. After revascularization, the wound heals. Restenosis is not expected to cause a recurrent wound with proper offloading of the wound and preventive measures.
- Healed minor amputation site.
- Excessive clinical risk.

### CONCLUSION

Surveillance for secondary patency after revascularization in patients with CLI is yet another challenging aspect in the management of this disease. The modality of surveillance, the frequency of surveillance, and the decision for reintervention can be approached based on the level of anatomic disease and the original clinical indication for revascularization. ■

*R. Kevin Rogers, MD, MSc, RPVI, is Assistant Professor, Section of Vascular Medicine and Intervention, Department of Cardiology at the University of Colorado in Aurora, Colorado. He has disclosed no financial interests related to this article. Dr. Rogers may be reached at (720) 848-6506; kevin.rogers@ucdenver.edu.*

*Arash Aghel, MD, is with the University of Colorado, Interventional Cardiology and Vascular Medicine in Aurora, Colorado. He has disclosed no financial interests related to this article.*

1. Varu VN, Hogg ME, Kibbe MR. CLI. *J Vasc Surg.* 2010;51:230-241.
2. Arain SA, White CJ. Endovascular therapy for CLI. *Vasc Med.* 2008;13:267-279.
3. Setacci C, de Donato G, Teraa M, et al. Chapter IV: Treatment of critical limb ischaemia. *Eur J Vasc Endovasc Surg.* 2011;42:543-59.
4. Davies AH, Hawdon AJ, Sydes MR, et al. Is duplex surveillance of value after leg vein bypass grafting? Principal results of the Vein Graft Surveillance Randomised Trial (VGST). *Circ.* 2005;112:1985-1991.
5. Anderson JL, Halperin JL, Albert NM, et al. Management of patients with peripheral artery disease (compilation of 2005 and 2011 ACCF/AHA guideline recommendations): a report of the American College of Cardiology Foundation/American Heart Association Task Force on Practice Guidelines. *Circ.* 2013;127:1425-1443.
6. Wennberg PW. Approach to the patient with peripheral arterial disease. *Circ.* 2013;128:2241-2250.
7. Sobieszczak P, Eisenhauer A. Management of patients after endovascular interventions for peripheral artery disease. *Circ.* 2013;128:749-757.
8. Timaran CH, Stevens SL, Freeman MB, Goldman MH. Predictors for adverse outcome after iliac angioplasty and stenting for limb-threatening ischemia. *J Vasc Surg.* 2002;36:507-513.
9. Rueda CA, Nehler MR, Perry DJ, et al. Patterns of artery disease in 450 patients undergoing revascularization for CLI: implications for clinical trial design. *J Vasc Surg.* 2008;47:995-999; discussion 999-1000.
10. Dake MD, Ansel GM, Jaff MR, et al. Sustained safety and effectiveness of paclitaxel-eluting stents for femoropopliteal lesions: 2-year follow-up from the Zilver PTX randomized and single-arm clinical studies. *JACC.* 2013;61:2417-2427.