

Options for Chronic Total Occlusions

A summary of the technologies that may enable treatment of difficult lesions.

BY THOMAS P. DAVIS, MD, AND JAMES TOREY, PA-C

The treatment of chronic total occlusions (CTO) is challenging for the endovascular specialist. Historically, long total occlusions were treated with bypass surgery. Patients with significant comorbidities, however, increasingly need more aggressive percutaneous treatment options. Standard guide-wire techniques have been the most frequently used for crossing total occlusions. Treatment failures occur about 20% to 25% of the time;¹ the most common reason is failure to cross back into the true lumen beyond the distal cap. Crossing technologies were developed to assist in the treatment of difficult lesions and to increase success rates. Patients with critical limb ischemia depend on successful revascularization, thus making these devices potentially limb saving.

Subadventitial wiring of CTOs not only has significant failure rates but also potential problems that can complicate the revascularization procedure that follows. Difficulty entering the lumen at the distal cap can extend the lesion length. This extension may require treatment into so-called nonstent zones or may even interrupt surgical target areas. Limitations may also occur with atherectomy devices, poor angioplasty results, and poor stent expansion.²⁻⁶ Intravascular ultrasound has shown that crossing devices can maintain central lumen crossing in the majority of cases. This has the potential to improve procedural success rates in these difficult long CTOs.⁷ In this article, we describe some of the newer crossing devices and their crossing rate data.

THE CROSSER SYSTEM

The Crosser system (Bard Peripheral Vascular, Inc., Tempe, AZ) is composed of two features: the Generator and the Crosser catheter (Figure 1). The Generator converts AC power into high-frequency current, and piezoelectric crystals within the transducer convert high-



Image courtesy of Bard Peripheral Vascular, Inc.

Figure 1. The Crosser catheter has a nitinol core wire that transmits mechanical vibration to the metal tip of the catheter at 20,000 cycles per second at 20- μ m amplitude.

frequency current into vibrational energy. The Crosser catheter is a nitinol-core wire that transmits mechanical vibration to the metal tip of the catheter at 20,000 cycles per second at 20- μ m amplitude.⁸

The PATRIOT study was conducted and released in 2009. Enrollment was for infrainguinal lesions resistant to wire crossing. Eighty-five patients were enrolled and the results revealed an 84% crossing rate. There were no instances of vessel perforation, and the endpoint of freedom from limb loss, clinical perforation, and repeat revascularization through 30 days was 94.1%.⁸

The CENTRAL study has completed enrollment and is awaiting publication. The study tracks 100 attempted




Figure 2. The Wildcat catheter in passive configuration.

crossings. All successful crossings are analyzed by intravascular ultrasound to assess reference segment extension, collateral loss, presence of dissection or hematoma, and the percent of the crossing that is completely intraluminal. Twelve-month target lesion revascularization data will be tracked in addition to the acute findings.

THE WILDCAT AND KITTYCAT CATHETER

The Wildcat catheter (Avinger, Inc., Redwood City, CA) was originally manufactured as a femoropopliteal hydrophilic-coated support catheter in a 0.035-inch caliber system (Figure 2). It is 6-F compatible and has a rotatable tip that is manually activated by turning the connected device handle. The tip has both passive and active configurations. The active configuration is a more aggressive tip profile that occurs when the deployable spiral wedges are exposed out of the catheter tip by sliding the hand control to advance them.⁹ An 0.014-inch infrapopliteal version of the device is called the Kitty cat, which is 5-F compatible and has an extended length of 140 cm. It has a lower crossing profile of 1.5 mm in comparison with the 2-mm crossing profile of the Wildcat.

The CONNECT study (Chronic Total Occlusion Crossing With the Wildcat Catheter) was a prospective, multicenter, nonrandomized, US investigational device exemption study conducted at 15 centers to support an expanded indication for crossing CTOs for Avinger's commercially available Wildcat catheter. Both the primary safety and efficacy endpoints were achieved, demonstrating a 95.2% safety profile and an 89.3% successful crossing rate. Secondary endpoints of device, lesion, and procedural success were also very high at 89.3%, 89.8%, and 89.3%, respectively.¹⁰

THE OCELOT AND PIXEL CATHETER

The Ocelot catheter (Avinger, Inc.), supported by the Lightbox console, allows physicians to see inside an artery using optical coherence tomography (Figure 3). It is built

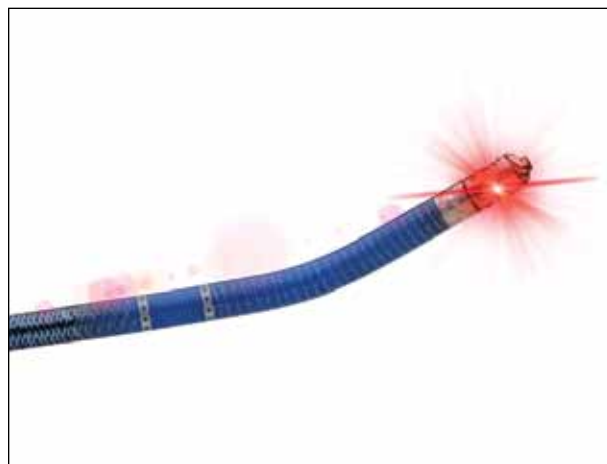


Figure 3. The Ocelot catheter in active configuration, which is a more aggressive tip profile.

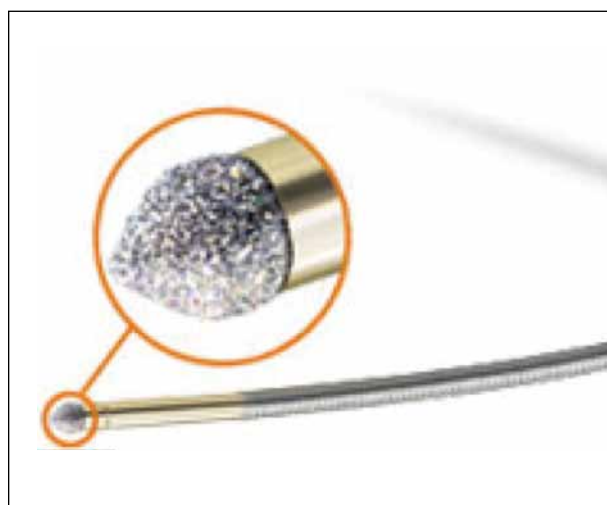


Figure 4. The TruePath CTO device is a low-profile catheter with a rotating diamond-coated shapeable tip.

off the Wildcat and Kitty cat catheters but incorporates tomographic imaging of the vessel wall to allow the practitioner to steer the device away from the media and remain intraluminal.¹¹ Unlike the Wildcat, the Ocelot is 0.014-inch compatible, although it still has an infrapopliteal counterpart, the Pixel catheter.

The CONNECT II trial was a prospective, multicenter, nonrandomized, US investigational device exemption study conducted at 17 centers that evaluated the safety and effectiveness of the Ocelot system in crossing femoropopliteal CTO lesions. It enrolled 122 subjects, including 22 roll-ins from 15 investigational sites in the United States and Europe from February 23, 2012 to June 7, 2012. The Ocelot system successfully crossed the target CTO lesion in 97% (97/100) of primary cohort

TABLE 1. COMPARISONS OF DIFFERENT DEVICES

Device	Study	Crossing Success Rate (%)	Major Adverse Event Rate (%)	Sheath Compatibility (F)	Guidewire Compatibility (Inches)
Crosser	PATRIOT	84	6	6	0.014
Wildcat	CONNECT	89	5	6	0.035
Ocelot	CONNECT II	97	2	6	0.014
TruePath	REOPEN	80	1	5	0.014
Viance	PFAST-CTO	84	3	5	0.014

subjects with an overall major adverse event rate of 2% (2/98), indicating that both the primary safety and efficacy endpoints were statistically met. Both endpoints were assessed through independent angiographic review.¹²

THE TRUEPATH CTO DEVICE

The TruePath CTO device (Boston Scientific Corporation, Natick, MA) is a low-profile (0.018-inch) catheter featuring a rotating diamond-coated shapeable tip that is designed to break through occluded peripheral arteries and facilitate the placement of conventional guidewires for the treatment of peripheral lesions (Figure 4). Once positioned, the distal tip rotates at 13,000 rpm to facilitate drilling through calcified lesions and other fibrous blockages.¹³ It has the longest working length at 165 cm and has an extension wire option, which provides over 300 cm of working length.

The ReOpen study was the validation study for the device, which analyzed 85 lesion attempts in the infringuinal region. Mean length of occlusion was 166 mm, activation time was 8.2 minutes, and average fluoroscopy time was 23.9 minutes. The safety endpoint was achieved in 98.8% of patients. An 80% technical success (crossing the lesion) rate was achieved (68/85 patients), and there was a 70.6% procedural success rate (achievement of technical success plus a residual stenosis of < 50% and improved flow postprocedure).¹⁴

THE VIANCE CROSSING CATHETER

The Viance crossing catheter (Covidien, Mansfield, MA) is a central lumen crossing catheter that employs a 0.037-inch atraumatic distal tip and a 1:1 fast spin torque handle (Figure 5). The spinning motion that is created enables the practitioner to access microchannels and navigate CTOs without added capital costs above the cost of the catheter. The shaft of the device is multi-



Image courtesy of Covidien.

Figure 5. The Viance crossing catheter is a central lumen crossing catheter.

wired to ensure optimal torque. It is 0.014-inch and 5-F compatible and has 150 cm in working length.¹⁵

The PFAST-CTO study examined the safety and efficacy of the Viance catheter. Forty-five patients were included. Initial safety of the study (major adverse event rate) was 3%, while the crossing rate was 84%. The average length of lesion was measured at 19.5 cm, and 42% of these lesions were classified as being either moderately or severely calcified.¹⁶

CONCLUSION

Crossing devices can potentially improve procedural outcomes but also come with difficulties. The added cost of these devices can be significant, and some require capital equipment. With the already high cost of medical care and the concern over reimbursement rates, convincing hospital administrators of the necessity of these devices may be difficult. This cost must be tempered by the potential for higher procedural success rates. Wiring CTOs takes a high skill level, and success rates can vary among operators. Crossing devices

can possibly improve operators' success rates significantly enough that lesions that normally would not be attempted may be within an operator's skill set.

The learning curve that is inherent with these devices must also be factored into consideration. There is certainly a wide variety to these devices, and the addition of imaging is another aspect that must be learned. These devices require a certain degree of practice to achieve a comfortable level of confidence for successful use. This means that they cannot be used on the rare isolated case—the devices must be used often enough to maintain an adequate skill level. The treating interventionist needs to become comfortable with at least one of these devices and use it frequently. ■

Thomas P. Davis, MD, is Director of the Cardiac Catheterization Lab at St. John Hospital and Medical Center in Detroit, Michigan. He has disclosed that he has stock ownership with Avinger and does teaching programs for Covidien.

James Torey, PA-C, is Director of Intravascular Ultrasound at St. John Hospital and Medical Center in Detroit, Michigan. He has disclosed that he has no financial interests related to this article. He may be reached at toreyj01@yahoo.com.

1. Markose G, Miller FN, Bolia A. Subintimal angioplasty of femoropopliteal occlusive disease. *J Vasc Surgery*. 2010;52:1410-1416.
2. Setacci E, Chisci G, de Donato F, et al. Subintimal angioplasty with the aid of a re-entry device for TASC C and D lesions of the SFA. *Eur J Vasc Endovasc Surg*. 2009;39:76-87.
3. Sultan S, Hynes N. Five-year Irish trial of CLI patients with TASC II type C/D lesions undergoing subintimal angioplasty or bypass surgery based on plaque echolucency. *J Endovasc Ther*. 2009;16:270-283.
4. Desgranges P, Boufi M, Lapeyre M, et al. Subintimal angioplasty: feasible and durable. *Eur J Vasc Endovasc Surg*. 2004;28:138-141.
5. Antusevas A, Aleksynas N, Kaupas RS, et al. Comparison of results of subintimal angioplasty and percutaneous transluminal angioplasty in superficial femoral artery occlusions. *Eur J Vasc Endovasc Surg*. 2008;36:101-106.
6. Keeling AN, Khalidi K, Leong S, et al. Subintimal angioplasty: predictors of long-term success. *J Vasc Intervent Radiol*. 2009;20:1013-1022.
7. Boguszewski A, Torey J, Pai R, et al. Intraluminal recanalization of SFA CTOs. *Endovasc Today*. 2010;9:33-38.
8. PATRIOT evaluates FlowCardia's Crosser to mediate CTO recanalization. *Endovasc Today*. Available at http://bmctoday.net/evtoday/2009/10/article.asp?f=eNews102909_07.htm. Accessed April 30, 2013.
9. Pigott JP. Crossing CTOs with the Wildcat catheter. *Endovasc Today*. 2011;1:30-32.
10. Pigott JP, Raja ML, Davis T; Connect Trial Investigators. A multicenter experience evaluating chronic total occlusion crossing with the Wildcat catheter (the CONNECT study). *J Vasc Surg*. 2012;56:1615-1621.
11. FDA clears first forward-looking imaging catheter to treat chronic total occlusions. *Diagnostic and Interventional Cardiology*. Available at <http://www.dicardiology.com/article/fda-clears-first-forward-looking-imaging-catheter-treat-chronic-total-occlusions>. Accessed April 30, 2013.
12. Avinger reports results of clinical study evaluating new imaging catheter designed to help cross CTOs in patients with peripheral artery disease (PAD). *Market Watch*. Available at <http://www.marketwatch.com/story/avinger-reports-results-of-clinical-study-evaluating-new-imaging-catheter-designed-to-help-cross-ctos-in-patients-with-peripheral-artery-disease-pad-2012-10-11>. Accessed April 30, 2013.
13. Boston Scientific launches TruePath CTO crossing device. *Endovasc Today*. Available at <http://bmctoday.net/evtoday/2012/01/article.asp?f=boston-scientific-launches-truepath-cto-crossing-device>. Accessed April 30, 2013.
14. George JC. Revascularization of calcified infrapopliteal chronic total occlusion. *Vascular Disease Management*. 2013;10:E56-E58.
15. Viance crossing catheter. Covidien website. Available at <http://www.ev3.net/peripheral/us/cto-devices/viancesup-sup-crossing-catheter.htm>. Accessed April 30, 2013.
16. Final results presented for Covidien's PFAST-CTOs study. *Endovasc Today*. Available at <http://bmctoday.net/evtoday/2012/10/article.asp?f=final-results-presented-for-covidien-pfast-ctos-study>. Accessed April 30, 2013.