

Exotic Access, Techniques, and Devices for Infrapopliteal CTOs

Recommendations on how to successfully cross chronic total occlusions of the infrapopliteal vasculature.

BY GEORGE L. ADAMS, MD, MHS, FACC; STEVE J. GARDNER, BA;

JON GARDNER, MBA, RCIS, CCVT, CCPT; AND JIHAD A. MUSTAPHA, MD, FACC, FSCAI

Approximately 40 million Americans (13%) are 65 years of age or older.¹ An estimated 11 million Americans over the age of 65 (26.9%) have diabetes, which is the leading cause of kidney disease in the United States.² Advancing age, diabetes, and kidney disease individually and conjunctively predispose people to developing intra-arterial calcium and, ultimately, peripheral arterial disease.³ Intra-arterial calcium is disproportionately distributed below the waist (10% above and 90% below). Below the waist, the majority (75%) of intra-arterial calcium resides in the infrapopliteal vessels (Figure 1).^{4,5}

Typically, patients with critical limb ischemia fall into one or all of these demographic subtypes and anatomically present with infrapopliteal calcific chronic total occlusions (CTOs). Due to the difficulty of treating infrapopliteal CTOs, adequate planning is necessary before attempting recanalization. The purpose of this article is to describe common and uncommon (exotic) access points, techniques, and devices to cross infrapopliteal CTOs.

ARTERIAL ACCESS AND DEVICE CONSIDERATIONS

Successful arterial access is an integral part of a well-planned and well-executed infrapopliteal intervention. Careful consideration should be used when determining the location of the access point(s) (ie, contralateral common femoral artery [CFA], antegrade CFA, ante-

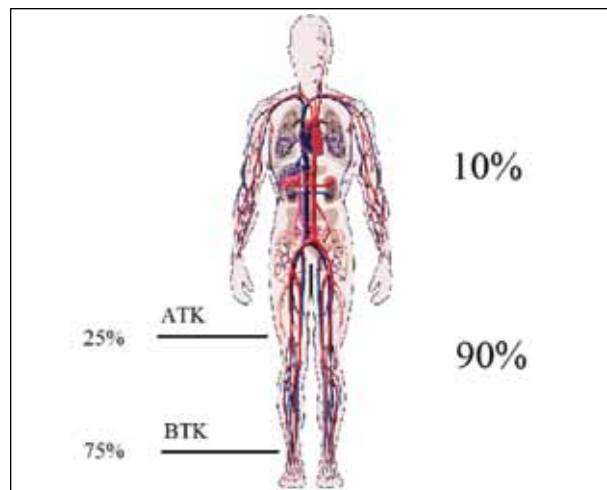


Figure 1. Intra-arterial calcium distribution in the body.

grade popliteal, and/or retrograde tibial). Ultrasound-guided arterial access is a valuable tool for precise access. Although currently underutilized in peripheral interventions, it can be very useful in patients with an absent arterial pulse or after failed palpation-guided puncture.⁶ Complications such as pseudoaneurysm,⁷ arteriovenous fistula, and arterial dissection/hematoma may be significantly reduced as a result.

Exotic access points outside the normal singular contralateral antegrade approach should be used to

facilitate technical success. Factors influencing the choice of approach should include the diameter of the access vessel(s) (CFA, approximately 6 mm; popliteal artery, approximately 4 mm; tibial artery, approximately 2 mm), distance from access site to the lesion, and characteristics of the CTO. An oversized sheath that is incorrectly selected for the requisite diameter may cause arterial trauma, resulting in spasm, dissection, and/or bleeding, essentially halting the intervention before it begins. Keep in mind that leaving an oversized sheath in for a longer period of time can lead to thrombosis.

An access point that is > 150 cm in distance from the target lesion may prevent treatment due to a shorter than necessary shaft length. As a result, the brachial/radial approach as the sole access is inadequate due to the distance from the target lesion. An ability to recall the shaft length of commonly used atherectomy devices, balloons, and stents is thus essential. Additionally, sheath and/or crossing catheter support may be needed when crossing calcific infrapopliteal CTOs. Therefore, selecting an access site that provides the best support may be warranted (ie, contralateral and/or antegrade and/or retrograde approaches). Characteristics of challenging CTOs, such as those that end at a large collateral, are longer than 60 cm, and/or are heavily calcified, may initially require two access points (antegrade and retrograde) in order to optimize a successful outcome, remain intraluminal when crossing, and reduce the length of the procedure.

ANTEGRADE CROSSING TECHNIQUES AND DEVICES

When addressing infrapopliteal calcified CTOs, the antegrade approach has traditionally been considered first. A multitude of CTO wires and catheters have been developed specifically for crossing this challenging diseased segment. CTO wires that are used in the infrapopliteal segment are 0.014 or 0.018 mm in diameter, with loaded tips ranging from 3 to 30 g. Higher levels of calcification present in some occlusions require more body to a wire, which is accomplished through a larger diameter and a greater loaded tip. Additionally, specialized hydrophilic and/or tapered wires may be utilized for crossing through microchannels and drilling through calcific plaque. Multiple wires meet these requisites, and selection is usually guided based on the operator's level of comfort and experience.

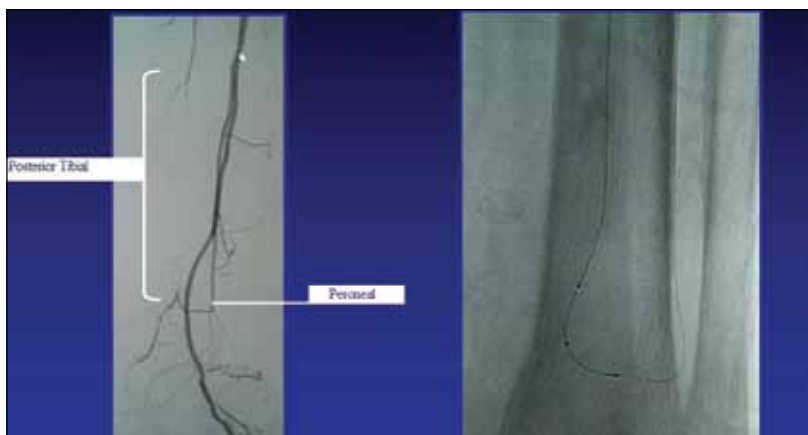

Figure 2. Retrograde approach using a peroneal collateral.

Multiple catheters have been developed to aid in crossing complex CTOs. Crossing catheter characteristics include diameter (0.014–0.035 inches in diameter), coating (hydrophilic or not), length (90–300 cm), and tip angulation. The crossing catheter should cater to the size of the vessel and the characteristics of the lesion being crossed.

When treating occlusions with a wire/crossing catheter approach, the crossing catheter is placed on the proximal cap for support. The CTO wire is then rotated in a 180° fashion conjunctively with a forward tension/tapping motion. Careful attention should be placed on both tactile sensation of the lesion and the visual angiographic cues in order to keep the wire intraluminal. Tactile resistance cues transmitted from the tip of the wire include:

- low resistance (homogenous/heterogenous lesions or entrance into a dissection plane)
- high resistance (heterogenous to calcific lesions)
- a sudden decrease in resistance and increased friction consistent with crossing into a dissection plane or perforation.

Visual angiographic cues include calcium on nonsubtracted angiography, islands of reconstituted vessel on subtracted views, and knowing the natural anatomic course of the tibial vessels. If a subintimal course is suspected from the visual and/or tactile cues, the wire should be pulled back and an alternative path obtained before advancing the crossing catheter.

Three techniques using the wire/crossing catheter are usually employed. The most typical is leading with an angulated CTO wire and following with the support of a crossing catheter. This technique is most frequently employed in a lesion that is heavily calcified. The second technique is bending a 0.014- or 0.018-inch wire on itself (usually a floppy tipped) and extending to the

reconstitution site with the support of a crossing catheter. The lesion morphology with this technique is usually a homogenous/heterogenous lesion and/or restenosis of a previous treated segment. The third technique utilizes a straight segment with a homogenous/heterogenous and/or restenosed region and involves pulling the wire into the crossing catheter and crossing the lesion leading with the crossing catheter tip. The goal with all of these techniques is to stay intraluminal.

RETROGRADE CROSSING TECHNIQUES

A retrograde approach is necessary when an antegrade approach has failed or is not feasible. There are two methods for retrograde access. The first is through a transcollateral vessel, requiring a single access via an antegrade/retrograde approach. The distal peroneal (lifeline of the tibials) provides both a collateral to the anterior tibial via the anterior communicating artery and posterior tibial at the ankle via the posterior communicating artery.

If retrograde access is warranted, this collateral may be used (Figure 2). The technique involves using a reduced-gram 0.014/0.018-inch hydrophilic wire to traverse the collateral. After traversing the collateral, a 0.014- or 0.018-inch crossing catheter is then used to traverse into the occluded artery. The hydrophilic wire is switched for a CTO wire to cross the lesion. Once crossed, the operator may choose to perform percutaneous transluminal angioplasty through the collateral. However, the only balloon currently available in the United States that has a long enough shaft (170 cm) from a contralateral common femoral artery access approach would be the Advance LP balloon dilatation catheter (Cook Medical, Bloomington, IN).

Other than this balloon, atherectomy devices, stents, and other balloons will not reach due to the shorter shaft length. If other treatment modalities are warranted, retrograde wire access must be converted to an antegrade access. To cross from above, a wrapping wire technique may be performed. This technique wraps the antegrade wire around the retrograde wire in a coiling fashion following the retrograde wire path. A second option is using a snare to pull the retrograde wire through the antegrade access. Sometimes, this technique may be difficult because of the increased forces applied to the retrograde wire secondary to tortuosity and the small caliber (2 mm or less) of the distal tibial vessels. To overcome the tension on the transcollateral wire, the use of a support catheter is recommended during the snaring process. These techniques may be utilized through other collaterals below the knee and for collateral access above the knee (ie, profunda collaterals into the superficial femoral artery).

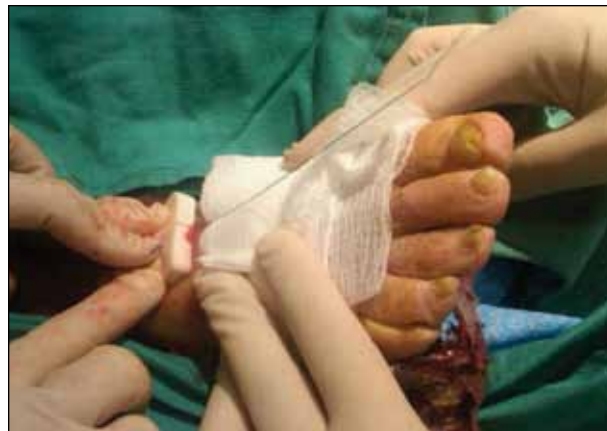

Figure 3. Pedal access using the dorsalis pedis.

The second retrograde approach is dual-access antegrade/retrograde tibiopedal (anterior, posterior, peroneal, and pedal arteries) (Figure 3). As previously mentioned, access may be achieved by ultrasound guidance or angiographic imaging from a catheter placed in a proximal segment. Anatomically, two veins surround each tibial artery, so careful attention should be given to avoid these vessels. To reduce the chance of injury to the distal tibials, typically no larger than a 4-F sheath should be used. Vigorous intra-arterial nitroglycerin should be injected through this 4-F sheath to vasodilate the distal bed and prevent spasm. A 0.014- or 0.018-inch CTO wire is then used to cross the CTO with the aid of a 0.014- or 0.018-inch crossing catheter.

If the retrograde wire traverses into a subintimal plane, a double-balloon technique may be used to regain intraluminal access. This technique extends a 0.014- or 0.018-inch wire from the antegrade access to the proximal aspect of the CTO, as well as extending a 0.014- or 0.018-inch wire from the pedal access to the level of the proximal wire. Utilizing multiple angiographic angulated views, each wire is manipulated such that they are no further than approximately 4 mm apart. A coronary balloon that is 2 to 3 mm in diameter is extended over the pedal wire to the tip, and a coronary or peripheral balloon, which is also 2 to 3 mm, is extended over the antegrade wire. These balloons are abutted, the wires are retracted into the balloons, and in a synergistic fashion, both balloons are inflated to nominal pressure. The hope is that the subintimal plane will be disrupted by the shearing action of the balloons so that the distal wire may be advanced into the true proximal lumen (Figure 4).

After crossing, CTO treatment may be performed with balloon angioplasty from the 4-F pedal access site with a coronary balloon or one of two techniques that may be employed from an antegrade approach.

(Courtesy of Dr. Andrej Schmidt.)




Figure 4. Double-balloon technique.

The first is extending an angled catheter to the level of the popliteal and rotating it in a position such that the catheter abuts the vessel wall. Using the angled retrograde wire, extend it to the level of the catheter and abut it against the same wall. This allows the third dimension to be removed so the wire can be successfully tunneled into the catheter. Once in the catheter, the wire can be pushed out the end of the sheath, and the CTO may be treated from an antegrade approach in a “flossing” fashion. In the flossing technique, the wire is visible from both the antegrade and pedal sheaths. The second technique uses a snare to capture the retrograde wire and pull through the antegrade sheath with the flossing technique as previously described.

ADJUNCTIVE CROSSING DEVICES AND TECHNIQUES

Central lumen crossing in a timely fashion is a major challenge with long, calcified infrapopliteal CTOs. As such, many novel crossing devices have been developed for use in this patient subset to decrease radiation exposure, intra-arterial dye load, and procedure length. These adjunctive devices include: (1) the CVX-300 excimer laser system (Spectranetics Corporation, Colorado Springs, CO), (2) the Crosser device (Bard Peripheral Vascular, Inc., Tempe, AZ), (3) the Kitty cat catheter (Avinger, Inc., Redwood City, CA), (4) the Ocelot catheter (Avinger, Inc.), (5) the TruePath device (Boston Scientific Corporation, Natick, MA), (6) the FrontRunner device (Cordis Corporation, Bridgewater, NJ), and (7) a new CTO device that Covidien (Mansfield, MA) acquired from BridgePoint Medical, Inc. (Plymouth, MN) in January.

The excimer laser may be used for crossing and debulking calcific CTOs with the Biamino technique.^{8,9} This step-by-step sequence involves advancing the guide-

wire into the origin of the CTO followed by the laser catheter over and beyond the tip of the wire into the first few millimeters of the occlusion. The laser catheter is then activated and advanced stepwise up to 5 mm followed by readvancement of the guidewire toward the tip of the laser catheter. This sequence is repeated with the laser catheter sequentially advanced and activated ahead of the supporting guidewire until the total occlusion is crossed.

The Crosser catheter is an ultrasonic energy delivery catheter that disrupts plaque in a CTO, allowing passage of a wire through the occlusion. The catheter is placed on the proximal cap, is activated, and with slight tension, is advanced through the CTO. The RESPECT (Traversing Peripheral Chronic Total Occlusions With the Crosser Device: the Real World Experience of 2,050 CTOs) registry collected data on 2,050 CTOs using the Crosser catheter. The technical success rate was 86.8% in an average CTO length of 220 mm, with a total procedure time of 91 minutes.¹⁰

The Frontrunner catheter is another catheter for penetrating and crossing CTOs. The catheter tip has a small, jaw-like microdissector that opens (maximum 2.3-mm outer diameter) and closes with the repetitive movement of a pistol grip mechanism. With its low profile and accompanying 4.5-F microguide catheter for support, it is placed at the proximal cap and activated. It is then steered through or around the CTO, and a wire is then advanced to the distal lumen. Once across the CTO caps, the support catheter is advanced, and the Frontrunner is exchanged for a wire.

The Kitty cat is a 5-F-accessible CTO crossing device with a spiral-fluted catheter tip. It is advanced to the proximal CTO cap over a wire. The catheter is activated in a counterclockwise passive mode. If resistance is met, the device is switched to active mode, rotating the spiral wedges in a clockwise rotation. After crossing the occlusion, a wire is advanced, and the device is removed.

Along with the current Kitty cat catheter, Avinger, Inc. is conducting a multicenter nonrandomized clinical trial evaluating the safety and efficacy of its new Ocelot crossing catheter. The Ocelot device employs optical coherence tomography to acquire an optical sonographic image to stay in the true lumen while crossing a CTO.

TruePath is a low-profile (0.018 inch) CTO crossing device. This device is advanced to the proximal CTO cap over a catheter. The diamond-coated tip is then activated and rotates through the CTO. Once across, the support catheter is advanced, and the TruePath CTO catheter is exchanged for an interventional wire.

The two new CTO devices from Covidien include an intraluminal crossing system, as well as a subintimal reentry system. However, 510(k) submission is pending. The devices are designed to be simple and intuitive, allowing physicians to treat challenging lesions endovascularly. The devices do not require separate capital equipment. The crossing catheter is low profile (0.035 inches) with a coiled shaft and atraumatic distal tip. The 150-cm catheter travels over a standard 0.014-inch guidewire, and using a torque device, the physician spins the catheter to advance it through the true lumen. The crossing device comes in two different levels of shaft stiffness for treating above- and below-the-knee lesions.

CONCLUSION

Restoring outflow is the goal of infrapopliteal intervention. Outflow influences inflow patency, limb salvage, and mortality.¹¹⁻¹⁴ Technically, endovascular outflow restoration is extremely challenging. The patient population is typically higher risk, older, diabetic, and renally compromised.³ As such, the characteristics of the infrapopliteal blockage are commonly long, occluded, and calcified.

A physician who attempts to treat these lesions must be patient and dedicated. Many times, success is based on the ability to achieve common and/or exotic access, understand CTO crossing techniques, and/or utilizing novel crossing devices. Every physician will have his or her own level of comfort with various techniques and devices. There is no specific recipe for success with infrapopliteal CTOs. Each case brings unique challenges that can be overcome with ingenuity and dedication to restoring adequate distal runoff. Amputation prevention is our ultimate goal and will drive future growth of devices and techniques for use in the infrapopliteal region. ■

George L. Adams, MD, MHS, FACC, is with Rex Hospital in Raleigh, North Carolina, and the University of North Carolina in Chapel Hill, North Carolina. He has disclosed that he is a trainer for Cook Medical. Dr. Adams may be reached at george.adams@rexhealth.com.

Steve J. Gardner, BA, is with North Carolina State University in Raleigh, North Carolina. He has disclosed that he has no financial interests related to this article.

Jon Gardner, MBA, RCIS, CCVT, CCPT, is the Heart & Vascular Administrator at Texas Health Presbyterian Hospitals in Dallas, Texas. He has disclosed that he has no financial interests related to this article.

Jihad A. Mustapha, MD, FACC, FSCAI, is with Metro Health Hospital in Wyoming, Michigan, and Michigan State University in Lansing, Michigan. He has disclosed that he is a trainer for Cordis and is a Research Investigator with Spectranetics and Bard.

1. Department of Health and Human Services. Administration on aging: aging statistics. http://www.aoa.gov/AoARoot/Aging_Statistics/index.aspx. Accessed: April 12, 2012.
2. Centers for Disease Control and Prevention. National diabetes fact sheet: national estimates and general information on diabetes and prediabetes in the United States, 2011. Atlanta, GA: U.S. Department of Health and Human Services, Centers for Disease Control and Prevention, 2011. http://www.cdc.gov/diabetes/pubs/pdf/ndfs_2011.pdf. Accessed: April 11, 2012.
3. Floege J, Ketteler M. Vascular calcification in patients with end-stage renal disease. *Nephrol Dial Transplant*. 2004;19:59-66.
4. Bishop PD, Feiten LE, Ouriel K, et al. Arterial calcification increases in distal arteries in patients with peripheral arterial disease. *Ann Vasc Surg*. 2008;22:799-805.
5. Füssl HS, Schälzky H, Schewe S, et al. Pathogenesis and clinical significance of Mönckeberg medial calcinosis. *Klinische Wochenschrift*. 1985;63:211-216.
6. Wacker F, Wolf KJ, Fobbe F. Percutaneous vascular access guided by color duplex sonography. *Eur Radiol*. 1997;7:1501-1504.
7. Gabriel M, Pawlaczyk K, Waliszewski K, et al. Location of femoral artery puncture site and the risk of post catheterization pseudoaneurysm formation. *Int J Cardiol*. 2007;120:167-171.
8. Biamino G. The excimer laser: science fiction fantasy or practical tool? *J Endovasc Ther*. 2004;11:207-222.
9. Laird JR, Reiser C, Biamino G, Zeller T. Excimer laser assisted angioplasty for the treatment of chronic total occlusions that cause critical limb ischemia such as complex tibial disease can be recanalized successfully as well critical limb ischemia. *J Cardiovasc Surg*. 2004;45:239-245.
10. Patlola R. Traversing peripheral chronic total occlusions with the Crosser device: the real world experience of 2050 CTOs. Presented at: TCT 2010; September 22-25, 2010; Washington, DC.
11. Cambria RP, Faust G, Gusberg R, et al. Percutaneous angioplasty for peripheral arterial occlusive disease. Correlates of clinical success. *Arch Surg*. 1987;122:283-287.
12. Johnston K. Femoral and popliteal arteries (reanalysis of results of balloon angioplasty). *Radiology*. 1992;183:767-771.
13. Bailey CM, Saha S, Magee TR, Galland RB. A 1-year prospective study of management and outcome of patients presenting with critical lower limb ischemia. *Euro J Vasc Endovasc Surg*. 2003;25:131-134.
14. Davies MG, Saad WE, Peden EK, et al. Impact of runoff on superficial femoral artery endoluminal interventions for rest pain and tissue loss. *J Vasc Surg*. 2008;48:619-626.