

# Overview of Vascular Closure

The *Endovascular Today* annual review.

BY ZOLTAN G. TURI, MD

This is the eighth year that I have had the privilege of writing the annual Overview of Vascular Closure in *Endovascular Today*. There were a number of developments in the past year, including new device approvals and changes in existing closure platforms. Vascular closure continues to grow toward the eventual billion-dollar mark, as an ever-expanding range of endovascular procedures drives the need for more efficient closure at the end of procedures. In addition, a changing reimbursement landscape, with slowly increasing adoption of outpatient interventions in the United States, will likely drive vascular closure device (VCD) use (as well as increasing transradial interventions). Although the intellectual property space is narrowing, a number of creative concepts are being explored, some of which will be covered in this edition of our annual overview.

I will review the existing technologies, discuss new devices receiving US Food and Drug Administration (FDA) clearance, and touch on some not-yet-ready for market platforms. I continue to find it useful, for both new readers as well as those familiar with the classification system, to show

the various technologies classified by category (Figures 1 through 7); this time, I have included FDA-approved devices as well as some in various stages of development. This classification system, first introduced in *Endovascular Today*, provides a conceptual framework to allow comparison of VCDs and to anticipate the potential strengths and weaknesses of each device. I will review select items from the past year's medical literature and will expound on fluoroscopy-guided access (see *What Should Fluoroscopic Guidance Really Entail?*).

## ACTIVE CLOSURE: STILL THE DOMINANT TECHNOLOGY

Angio-Seal (St. Jude Medical, St. Paul, MN) (Figure 1A) continues to be the most widely used VCD, although its market share may have eroded somewhat in the past year. It remains the only “belts and suspenders” device, achieving hemostasis with active closure that sandwiches the hole in the artery with a resorbable anchor inside the vessel combined with an extravascular collagen plug. The elements are tethered together by suture. In addition, it provides the coagulation-facilitating effect of the collagen. Primary suc-

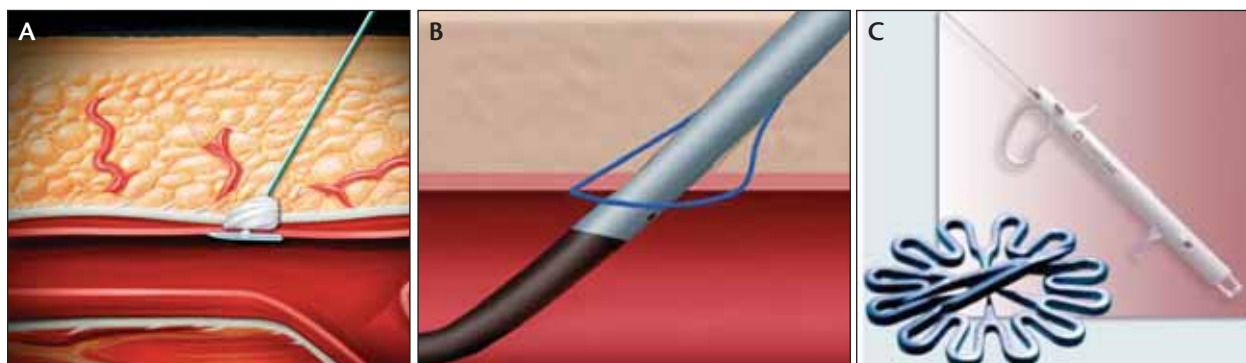
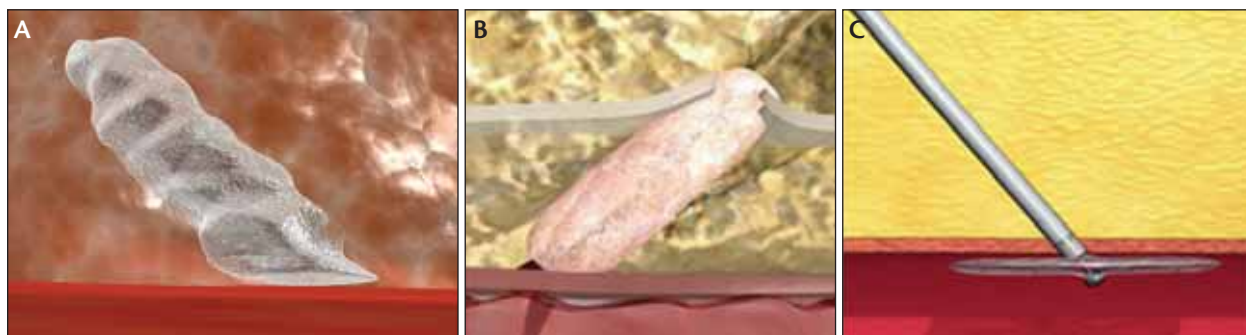


Figure 1. Three active closure devices dominate the vascular closure market overall. Angio-Seal uses suture material to tether a resorbable anchor inside the artery to a collagen plug on the arterial surface (A). Perclose (the ProGlide is shown in this image) (Abbott Vascular, Santa Clara, CA) uses a suturing mechanism to approximate the arterial edges (B), whereas StarClose (Abbott Vascular) fires a nitinol clip into the artery wall (C).



**Figure 2.** Three passive closure devices, with the Mynx (AccessClosure, Mountain View, CA) (A) having had increasing usage in the past year. Both the Mynx and ExoSeal (Cordis Corporation, Bridgewater, NJ; not FDA approved) (B) are sealants delivered through the procedure sheath that expand in the tissue track over the arteriotomy to seal the artery. Neither are tethered to the vessel itself. The Catalyst (Cardiva Medical, Sunnyvale, CA) (C) uses a nitinol disc inside the artery on which tension is placed while hemostasis occurs. During tension, the shaft pulls back to expose hemostasis-facilitating agents. The disc is then collapsed and pulled through the arteriotomy after which additional compression is performed.

cess—the ability of the device to achieve closure without adjunctive compression, single-operator technique, and ease of use—are particularly strong suits of this device, with primary success rates uniquely above 95%. The anchor inside the artery does pose a potential hazard in vessels that are already partly obstructed; embolization of the anchor is quite rare. The collagen inside the tissue track provides some additional benefit in terms of decreasing postprocedure oozing: the suture that extends nearly to the skin surface and the foreign body left behind temporarily in the form of the collagen plug do create a small but important infection risk, an issue common to all VCDs that leave even temporary foreign bodies behind. In the past year, Angio-Seal released its Evolution platform, which improves on the VIP version in several ways, most notably by standardizing the force used to deliver the plug, and in general improves consistency across users.

Perclose and StarClose (Figure 1B and 1C) remain the second most commonly used technologies. They provide active approximation without a thrombosing or sealing agent and mimic the well-established surgical techniques of suturing or stapling blood vessels. Because of the absence of suspenders—no thrombosing or sealing agent—both devices are somewhat more likely to have oozing (usually minor) after interventions in fully anticoagulated patients. Perclose dominates in one very important area: preclosure. With an ever-increasing number of procedures requiring large-sheath technology, including abdominal aortic aneurysm repair, percutaneous aortic valve replacement, and a variety of percutaneous ventricular-assist devices, the ability to achieve access and closure without surgical cut-down has become an important part of the vascular closure device arena. Operators preclose with either the ProStar XL, which provides four suture needles but has a somewhat

challenging platform, or two ProGlides placed at a 40° angle. More recently, a technique has been described using three ProGlides; this presumably grabs more segments of the arterial wall and provides redundancy in case one of the closures fails.<sup>1</sup>

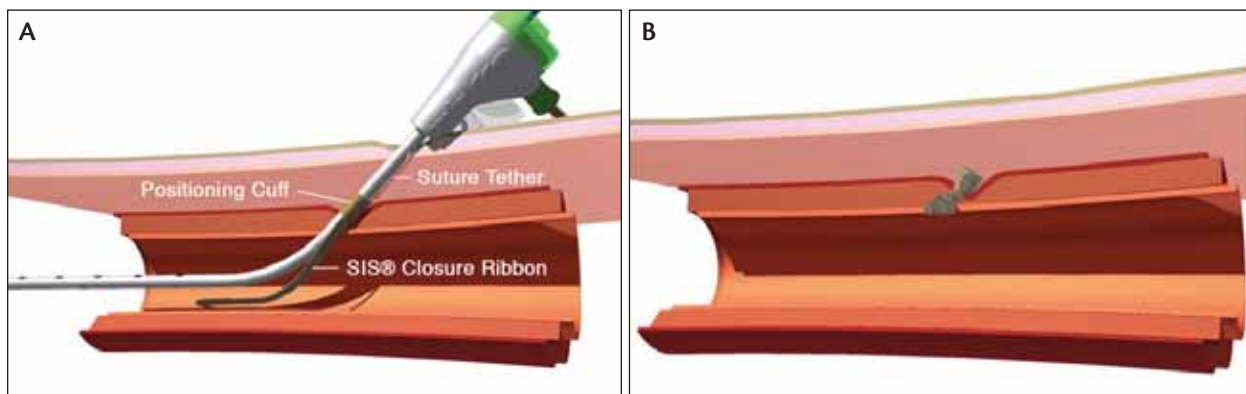
#### PASSIVE APPROXIMATORS: CONTINUED GROWTH OF THE MYNX

The Mynx (Figure 2A) has by all accounts now gained double-digit market share. It has the advantages of an elegant deployment mechanism and generally excellent patient tolerance of its sealant, polyethylene glycol (PEG). A 5-F version (Mynx M5) was released in the past year. The device is deployed through the procedural sheath—a desirable feature that theoretically improves patient tolerance and may decrease infection risk because there are fewer devices transitioning directly across the tissue track. PEG differs from collagen in several ways: it is a synthetic sealant rather than a bioactive thrombosing agent, has a less fibrous consistency than collagen, and resorbs by hydrolysis at an apparently faster rate. However, there remains a need for solid scientific comparison between sealants and thrombosing agents. Several hypotheses about the Mynx remain unproven, and unfortunately, given the volume of cases being done, the evidence base remains lamentably scant. Unanswered questions are (besides the role of sealants versus thrombosing agents in achieving hemostasis) the potential for infection associated with PEG versus collagen and the risk of distal vessel occlusion from inadvertent deployment of the sealant in the artery.

Most importantly, the efficacy and safety of unanchored plugs in percutaneous coronary intervention (PCI) patients remains to be shown; my bias has generally been that active (rather than passive) closure in fully anticoagu-



**Figure 3.** Closure begins with access (CBA). The Arstasis device (Arstasis, San Carlos, CA) was cleared by the FDA in March 2010. A micropuncture hole is created using conventional technique. The deployment device is placed through this small hole, and a needle is deployed that travels in a shallow diagonal across the vessel wall (green arrow) (A). A guidewire is then placed through that needle and the assembly withdrawn. A sheath (white arrow) is then placed conventionally (B). At the end of the procedure, the sheath is withdrawn, and hydrostatic pressure facilitates early closure (typically within 3 minutes for diagnostic, 6 minutes for interventions) (C). This is a hybrid device, primarily passive closure, although other passive closure agents do not have the same potential beneficial effects of hydrostatic pressure. There is no foreign body or sealing/thrombosing agent.

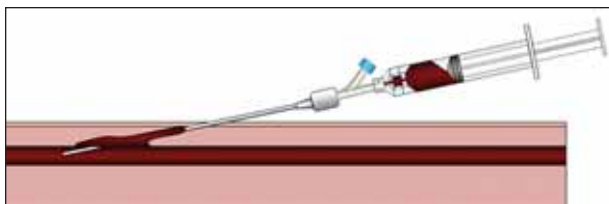


**Figure 4.** The FISH (Femoral Introducer Sheath and Hemostasis) (Morris Innovative, Bloomington, IN) device deploys small intestinal submucosa (SIS) as a resorbable ribbon (A) that forms a plug in the artery wall when the sheath is withdrawn (B). This is a hybrid device, probably best described as active closure with a temporary foreign body. The SIS, depending on configuration, may have some sealant properties.

lated patients is superior, but what I would consider to be a high-level evidence-based comparison study has not been published. Nevertheless, somewhat buttressing my concern is a very recent retrospective look by Azmoon et al<sup>2</sup> at 428 patients treated with Angio-Seal or Mynx after PCI. Although that study showed no difference in major vascular complications between Angio-Seal and the Mynx, it did reveal a 2.5 times higher failure rate for the Mynx. It will be particularly important to see how often retroperitoneal hemorrhage occurs after Mynx deployment in the interventional setting (and after ExoSeal—see page 70—once that device is released) (Figure 2B), compared with Angio-Seal and Perclose/StarClose, especially in the particularly challenging setting of high punctures. In the meantime, novel uses of the Mynx continue to be published, including the use of multiple devices simultaneously for large-hole closure.<sup>3</sup>

The Cardiva Catalyst (Figure 2C) is the other mature technology that has FDA approval and can generally be

categorized as a passive approximator. In order to address some of the limitations of the original Boomerang device in anticoagulated patients, it now incorporates protamine in addition to two other topical agents on the shaft of the device. These are all designed to facilitate coagulation when exposed in the tissue track after tension is placed on the cable holding the nitinol disc in place. The Catalyst has theoretical appeal for some settings where compression can be difficult or ineffective (such as brachial, although this is off-label use). The relative efficacy of this device in the interventional setting needs to be compared to active approximators. There are two factors that suggest an evidence base in the fully anticoagulated setting would be important. First is the generic issue of passive closure in this setting as discussed previously, and second, the unique feature of this device that requires that the disc be collapsed and pulled through the fresh clot formed during initial hemostasis. The disc does compress to an 18-gauge needle size according to the manufacturer, which is



**Figure 5.** Illustration of the ClosSys device (CloSys Corporation, St. Paul, MN) showing the syringe that has withdrawn anticoagulated blood, deheparinized it, and is injecting a small amount back into the tissue track above the arteriotomy site. This is a passive closure mechanism, without thrombosing agent, with no foreign body left behind. It is an investigational device and not FDA approved.

approximately 1.3 mm in diameter. Importantly, no foreign body is left behind.

#### CLOSURE BEGINS WITH ACCESS: FDA CLEARANCE FOR ARSTASIS

This concept, which was also first introduced in this column, now has two devices that are FDA approved: Arstasis One and FISH (Figures 3 and 4). The two devices are quite different with the exception of one central concept: they both begin the closure process when access is first obtained. This is a potential benefit and drawback: the decision to use these devices typically needs to be made before important details are known (location of the puncture site, presence of any vascular disease in the common femoral artery, or size of the common femoral artery) and in many cases, before a decision is made on whether the procedure will include intervention. FDA approval for both devices is limited to diagnostic cases currently, but conversion to ad hoc PCI means that they will of necessity be used in interventions.


The FISH is a closure device using small intestinal submucosa as a ribbon that creates a resorbable plug in the artery wall. Arstasis is unique: it is both an access and closure concept—it creates a pathway for the sheath that traverses the artery at a shallow angle and takes advantage of hydrostatic forces to facilitate closure of the artery when the sheath is withdrawn. One of several appealing features of the Arstasis approach is that it leaves no foreign body behind. My limited anecdotal experience with this technology has been positive in a number of settings about which I previously described theoretical concerns, including use in diseased and calcified blood vessels. However, much more will need to appear in the investigational literature before we have a clear understanding of the potential benefits

and drawbacks of both devices. As with all the other VCDs mentioned, I remain concerned about the possible complications associated with use in the setting of high punctures and anticoagulation/aggressive antiplatelet therapy, and it will be interesting to see how these technologies fare in the real world of suboptimal access.

#### NEW TECHNOLOGIES: NOT FDA CLEARED

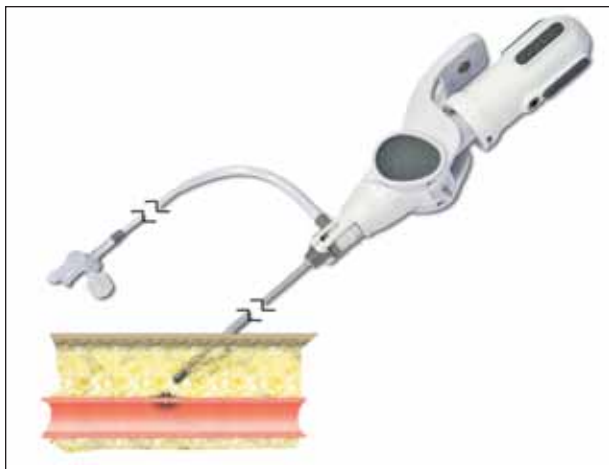
Several new, investigational technologies are worth describing. One interesting outside-the-box concept is CloSys, designed for use in patients who have been anticoagulated with heparin for their procedure (Figure 5). The device is used to withdraw a small amount of blood extracted through a catheter placed inside the procedural sheath and deheparinize it, followed by reinjection of 3 to 4 mL into the tissue track above the arteriotomy site as the sheath is withdrawn. Compression then follows. The concept is to form a seal with coagulable blood in anticoagulated patients, with no foreign body left behind. It is in the early phase of clinical trials. Several questions come to mind that will need to be answered: the effectiveness of the method in the aggressively anticoagulated/antiplatelet agent environment, the duration of compression ultimately required, and the infection risk of a small amount of blood compared with that of the foreign body left behind by most (but not all) VCDs.

A number of companies are working on rapidly deployable mechanical closure, typically, but not exclusively, with active approximation techniques. Two such devices both have bioabsorbable intra- and extra-arterial anchors: BravoSeal (VIMedRx, Atlantic Beach, FL) and FastSeal (Vascular Closure Systems, Palo Alto, CA) (Figure 6). Another VCD in development is the Celt ACD (Figure 7), a stainless steel device with both intra- and extraluminal components that features through the procedural sheath deployment. Vascular Solutions (Minneapolis, MN) is in early testing of MagneSeal, a novel closure device delivered through the procedural sheath that uses magnesium to achieve rapid closure and resorbs in a short time frame.



**Figure 6.** Two rapidly deployable through-the-procedure-sheath bioabsorbable devices, BravoSeal (A) and FastSeal (B). Both serve as active approximators, with no thrombosing agent, and are temporary foreign bodies. Both are investigational.





**Figure 7.** The Celt ACD (previously called AstraPlug) (Vasorum, Dublin, Ireland). A stainless steel plug is delivered through the procedure sheath. This is an active closure system, with no thrombosing agent, and a permanent foreign body left behind. It is an investigational device and not FDA approved.

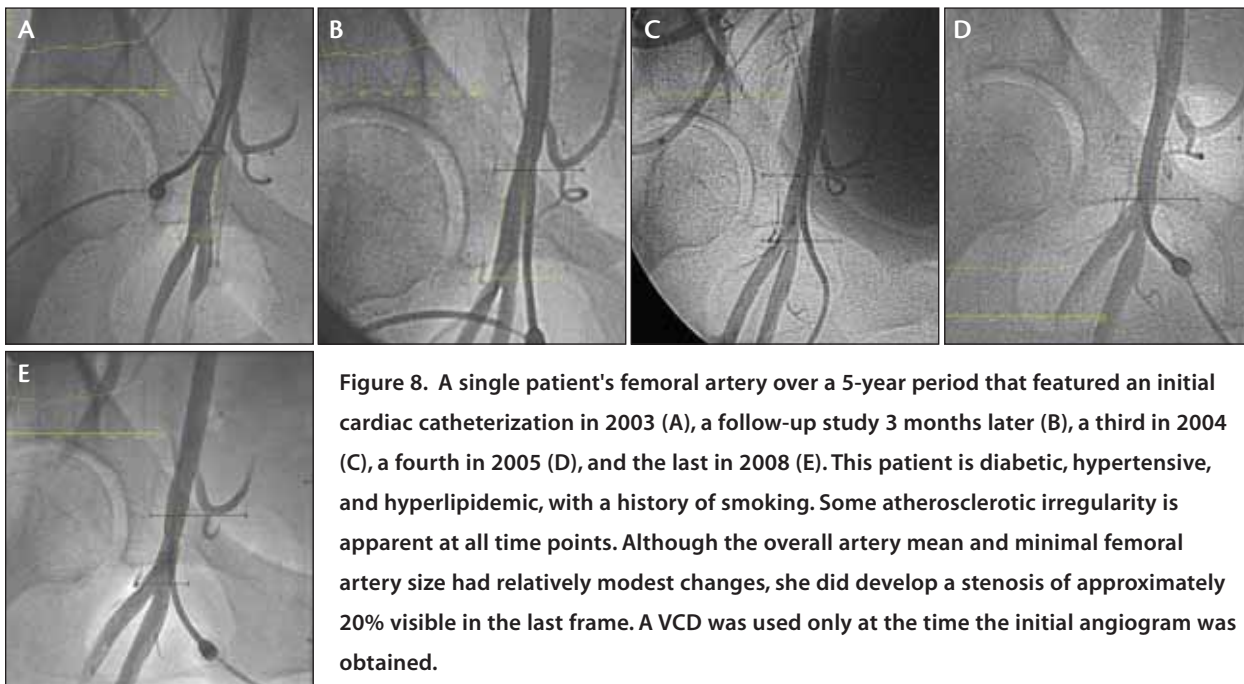
ExoSeal is a passive closure device described last year that shares a number of characteristics with the Mynx, including the use of a biodegradable polymer sealant and deployment through the procedural sheath. It was the subject of a pivotal trial (ECLIPSE) published in the past year, but it is not yet FDA approved. Using the familiar Boomerang/Catalyst platform, Cardiva Medical has developed a new system that releases what is currently being

described as a bioabsorbable hemostatic material into the tissue track. This device has undergone first-in-man testing in New Zealand.

## LARGE-HOLE CLOSURE

The ever-increasing variety of large devices being placed in the arterial tree is mandating renewed focus on large-hole access and closure. A less than optimal puncture, such as through the sidewall of the artery, may not cause significant problems when a 6-F sheath is placed but may result in devastating complications when a 24-F sheath is introduced. By way of example, vascular access site complications during completely percutaneous transfemoral aortic valve implantation occurred in approximately one-third of patients early in the experience, with surgical repair necessary for 10% to 20% overall.<sup>45</sup> When working with sheaths and catheters that are this large, it is essential to know ahead of time vessel size, presence of calcification and atherosclerotic disease, presence of iliac tortuosity and angle of insertion into the aorta, and location of the femoral artery bifurcation. These can all be obtained noninvasively with computed tomography or to some degree with magnetic resonance angiography.

Preclosure with Perclose has already been discussed in this article; a number of other innovations in both access and closure of large holes are worth mentioning. Several novel approaches use contralateral access for contrast injection to allow road mapping of the iliac and common femoral artery. A particularly clever method uses a pigtail catheter placed into the common femoral artery contralaterally, which is



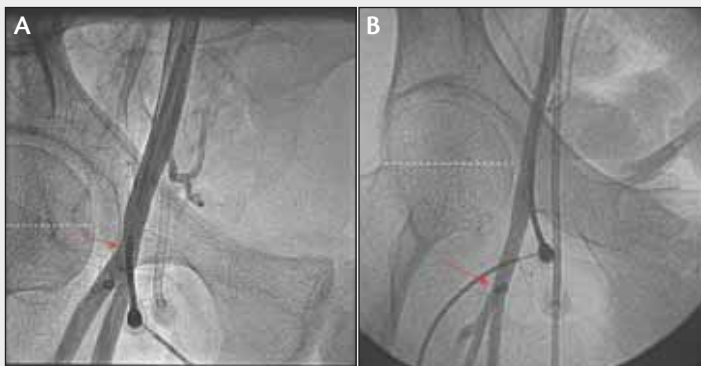**Figure 8.** A single patient's femoral artery over a 5-year period that featured an initial cardiac catheterization in 2003 (A), a follow-up study 3 months later (B), a third in 2004 (C), a fourth in 2005 (D), and the last in 2008 (E). This patient is diabetic, hypertensive, and hyperlipidemic, with a history of smoking. Some atherosclerotic irregularity is apparent at all time points. Although the overall artery mean and minimal femoral artery size had relatively modest changes, she did develop a stenosis of approximately 20% visible in the last frame. A VCD was used only at the time the initial angiogram was obtained.

## What Should Fluoroscopic Guidance Really Entail?

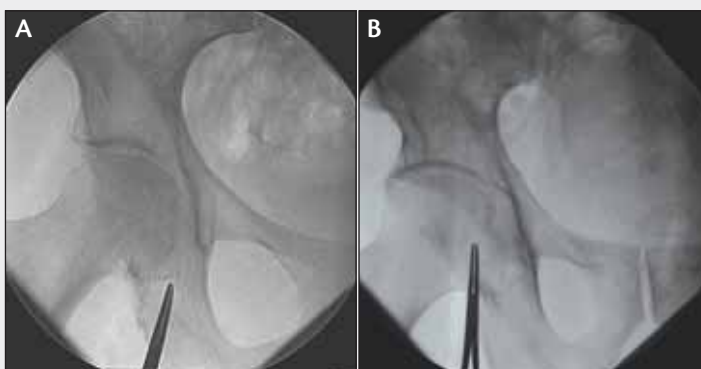A number of articles in the past 2 years have sought to address whether or not fluoroscopic guidance adds to the overall safety of vascular access. The consensus of the literature to date is that it does not. Generally speaking, by identifying the bottom of the femoral head, the frequency of low sticks is reduced, but overall outcomes did not appear to be affected. However, a careful reading of the methodology shows that what is considered fluoroscopic guidance by many operators is in fact an oversimplified version of the technique. The more comprehensive approach has been described in both *Endovascular Today* and *Cardiac Interventions Today* in the past few years. Specifically, what many consider fluoroscopic guidance—identifying the bottom or center of the femoral head with a hemostat—is not adequate to optimize puncture location or reduce complications. The net result is that the actual location of puncture is frequently well over the centerline of the femoral head. The top half of the femoral head should be a “no puncture zone.”

**Rule 1.** Look at any previous angiograms. We have long advocated routine femoral angiography with every femoral access, although it has been difficult to convince many operators. One of the benefits of this practice is that when patients come back for repeat catheterization, an increasingly common event, the location of the femoral bifurcation and the presence of atherosclerotic disease as well as lumen size will be known. Importantly, if the bifurcation is low, as is the case in some 77% of patients, it means that the area for safe puncture is extended all the way down to the bottom of the femoral head, increasing the size of the target zone (Figure 1).

**Rule 2.** Place the hemostat at the bottom of the femoral head or at the target location for arterial entry below the centerline of the femoral head by approximately 1 cm (Figure 2). Only then should you anesthetize the skin and introduce the needle. It is essential to have adequate distance between the skin puncture site and the planned arterial entry site so that the needle does not enter the artery above the centerline of the femoral head. If the needle



**Figure 1.** Usefulness of having a previous femoral angiogram. If the bifurcation (red arrow) is relatively high (A), the target area for puncture will be relatively narrow. If the bifurcation is low (B), the area for safe puncture is extended to the bottom of the femoral head.

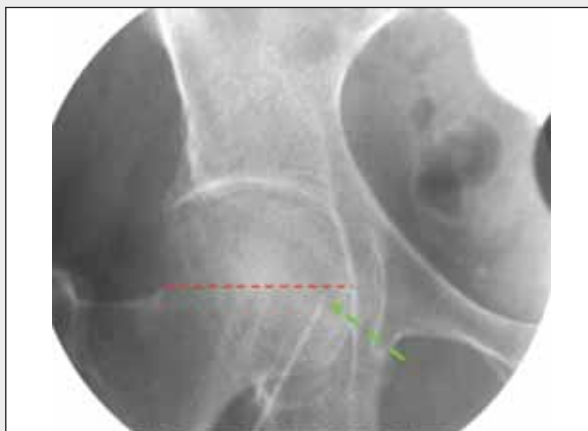

**Figure 2.** Hemostat placed at the bottom of the femoral head (A) or at the target point (B). The latter should be located medially and approximately 1 cm below the centerline. This alone does not constitute fluoroscopy-guided access. It is merely the first step.

enters the skin too high, there is no shame in reanesthetizing the skin more distally and beginning the puncture process again.

**Rule 3.** Use micropuncture. We made what I believe was a compelling case last year in *Endovascular Today* as to why all arterial puncture should be by the micropuncture technique, whether the access is femoral or radial. There is at least one large ongoing randomized trial looking at this issue. In my practice, all puncture, including venous puncture (and including pericardiocentesis), is by a micropuncture approach.

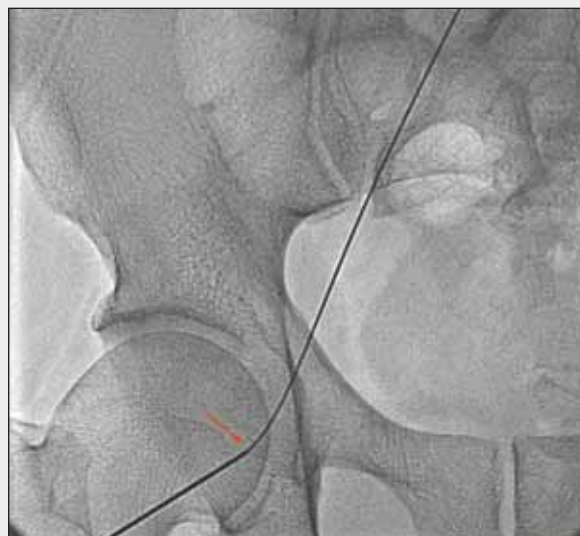**Rule 4.** Perform fluoroscopy before arterial entry (Figure 3). This is the essential step performed by only a small minority



**Figure 3.** Repeat fluoroscopy after the needle has been introduced deep into the tissue track, roughly where the operator thinks the needle is about to enter the vessel. Surprisingly often, even in the hands of experienced operators, the needle tip is well off the optimal target area. Because of differing tissue depths and inherent problems in localizing the femoral artery, it is quite common to be too medial, lateral, low, or high.

of operators. Once the needle has penetrated deep enough so that the operator thinks he or she is about to puncture the artery, it is time to stop, remove your hands from the field, and fluoroscope the needle location. If it is below the centerline of the femoral head and medial, then it is reasonable to proceed. However, most operators first using this technique are surprised at how often the needle is in a dramatically different position.

**Rule 5.** After entering the artery and advancing the wire, look at the needle/wire interface (Figure 4). In fact, we frequently record a single frame of this image. This pinpoints precisely the relationship of the puncture site to the femoral head, much more accurately than a sheath angiogram. If the



**Figure 4.** The wire needle interface (red arrow) shows, with high degree of accuracy if imaged in the anterior-posterior view, the location of needle entry with relationship to the femoral head. This avoids some of the difficulties of localizing puncture entry using sheath angiography caused by vessel and sheath overlap.

puncture is high or low, this is the last chance to avoid placing a sheath into the femoral artery in an unsafe location. In the case of a 6-F sheath, the hole created is approximately 3.5 times the size of the micropuncture needle.

**Rule 6.** Administer anticoagulants only after sheath angiography. The risk of all hemorrhage, and most importantly retroperitoneal hemorrhage, is increased 10- to 20-fold once anticoagulants are given. In particular, if the stick is clearly high, we strongly recommend performing only those parts of the catheterization not requiring anticoagulation and saving the intervention for another day if the procedure is elective.

then used as a target for needle puncture. A means of achieving closure while minimizing risk of major blood loss involves occluding the iliac artery proximally while the sheath is pulled and the artery is closed using whatever technique is planned, such as tying of multiple sutures placed during the preclosure process.<sup>6</sup>

## THE LITERATURE

I have again selected a few articles from the past year that provide unique and important insights into vascular closure. A study by Tiroch and colleagues<sup>7</sup> reviewed femoral angiography performed on 827 patients who had at least two catheterizations between 2001 and 2008 that involved repeat access into the same femoral artery when

angiograms were available for both procedures. Using quantitative techniques, the investigators compared artery size. Although the mean time between the initial and last follow-up angiogram was less than 1 year, a number of important observations were made. First, the procedures appeared to have no impact on femoral artery size. Second, the use of VCDs did not appear to affect vessel diameters in follow-up. Interestingly, multivariate analysis revealed a modest decrease in femoral artery size only in women and smokers (current or in the past), whereas vessel size increased in patients who had been on statin therapy. By way of disclosure, we have a similar study in the analysis phase (REPEAT) using somewhat different methodology. An example of the appearance of the

femoral artery during multiple catheterizations is seen in Figure 8. The effect of repeat interventions over longer periods of time on the femoral artery will be important as the plethora of vascular interventions increases in a typical patient's lifetime.

A second important article was by Abu-Fadel and colleagues<sup>8</sup> comparing fluoroscopic-guided and "traditional" femoral arterial access (using landmarks such as the inguinal crease, point of maximal pulsation, and location of the anterior superior iliac crest and symphysis pubis). The study prospectively randomized patients to fluoroscopic or traditional technique and found no difference in outcomes, although suitability for VCD use rather than complications was the basis for the sample size and power calculations. This study, as well as two other similar but less comprehensive investigations, had similar conclusions. The only benefit shown was that the incidence of puncture below the femoral head was lower with fluoroscopy. A nonstatistically significant trend, likely related, was that fewer pseudoaneurysms occurred with fluoroscopic guidance, but the study was not sufficiently powered to address this. Because the techniques outlined in the sidebar in this article were not used, 45% of the punctures were above the centerline of the femoral head, and 67%—fully two-thirds—were at or above the centerline. The technique described in *Endovascular Today* over the past several years has repeatedly urged that fluoroscopy be used to make certain that 100% of punctures are below the centerline of the femoral head. Thus, although this was an elegantly designed and excellently executed study, the potential benefits of fluoroscopic guidance, as it should be used in my opinion, have not been examined.

A number of other articles also deserve brief mention. The ACUTY trial (which looked at patients with acute coronary syndromes undergoing an early invasive management strategy) compared 4,307 patients receiving a VCD with 7,314 who did not and demonstrated reduced bleeding complications in patients where a VCD was used.<sup>9</sup> As with a multiplicity of nonrandomized retrospective analyses of this type, selection bias may have favored VCD use in a more favorable population. A study by Bangalore et al<sup>10</sup> confirmed previous reports that the occurrence of a failed VCD deployment is associated with significantly higher rates of vascular complications. Finally, renal dysfunction, a risk factor for virtually every other aspect of vascular medicine, is also associated with higher complication rates after VCD use, in particular a higher infection rate, occurring in approximately 1.7% of the patients in the study by Aziz et al.<sup>11</sup> This is at least sixfold higher than previous reports; because VCD-related infection carries an approximately 5% mortality rate, it is one of the most dreaded complications associated with closure devices.

## THE CRYSTAL BALL

After a period of relative stability in the VCD world, a number of new technologies will become available in the next 1 to 2 years, some of them rather creative if not revolutionary. The mandate to access and seal femoral arteries after large-hole closure will only increase and represents a variety of technical and clinical challenges. I expect radial artery access for more conventional sheath sizes to grow dramatically in the United States in the next few years (it is already the majority approach in some parts of the world) for reasons discussed in this article last year. A debate regarding femoral versus radial access, part of a series I have the privilege of writing in *Cardiac Interventions Today*, will appear in the next several months, and a debate regarding fluoroscopic, ultrasound-guided, and traditional access will follow later in the year. The use of topical hemostatic agents deserves more discussion, and I plan to include that in this space next year. ■

*The images in Figure 8 and Figures 1 through 4 in the sidebar were prepared with the expert assistance of Brian McEniry, Dr. Turi's research associate and supervisor of the Cooper Angiographic Core Laboratory.*

*Zoltan G. Turi, MD, is Director of the Section of Vascular Medicine at Cooper University Hospital and Professor of Medicine at Robert Wood Johnson Medical School in Camden, New Jersey. He has disclosed that he receives research grant support from Abbott Vascular and St. Jude Medical, and has performed consultation for Arstasis, Cook Medical, Johnson and Johnson, and St. Jude Medical. Dr. Turi may be reached at (856) 342-3488; turi-zoltan@cooperhealth.edu.*

1. Kahlert P, Eggebrecht H, Eibel R, et al. A modified "preclosure" technique after percutaneous aortic valve replacement. *Catheter Cardiovasc Interv*. 2008;72:877-884.
2. Azmoon S, Pucillo AL, Aronow WS, et al. Vascular complications after percutaneous coronary intervention following hemostasis with the Mynx vascular closure device versus the AngioSeal vascular closure device. *J Invasive Cardiol*. 2010;22:175-178.
3. Korngold EC, Ingleissis I, Garasic JM. A novel technique for 14 French arteriotomy closure after percutaneous aortic valvuloplasty using two Mynx closure devices. *J Interv Cardiol*. 2009;22:179-183.
4. Ducrocq G, Francis F, Serfaty JM, et al. Vascular complications of transfemoral aortic valve implantation with the Edwards SAPIEN prosthesis: incidence and impact on outcome. *EuroIntervention*. 2010;5:666-672.
5. Kahlert P, Al Rashid F, Weber M, et al. Vascular access site complications after percutaneous transfemoral aortic valve implantation. *Herz*. 2009;34:398-408.
6. Sharp AS, Michew I, Maisano F, et al. A new technique for vascular access management in transcatheter aortic valve implantation. *Catheter Cardiovasc Interv*. 2010;75:784-793.
7. Tiroch KA, Matheny ME, Resnic FS. Quantitative impact of cardiovascular risk factors and vascular closure devices on the femoral artery after repeat cardiac catheterization. *Am Heart J*. 2010;159:125-130.
8. Abu-Fadel MS, Sparling JM, Zacharias SJ, et al. Fluoroscopy vs. traditional guided femoral arterial access and the use of closure devices: a randomized controlled trial. *Catheter Cardiovasc Interv*. 2009;74:533-539.
9. Sanborn TA, Ebrahimi R, Manoukian SV, et al. Impact of femoral vascular closure devices and antithrombotic therapy on access site bleeding in acute coronary syndromes: The Acute Catheterization and Urgent Intervention Triage Strategy (ACUTY) trial. *Circ Cardiovasc Interv*. 2010;3:57-62.
10. Bangalore S, Arora N, Resnic FS. Vascular closure device failure: frequency and implications: a propensity-matched analysis. *Circ Cardiovasc Interv*. 2009;2:549-556.
11. Aziz EF, Pulimi S, Coleman C, et al. Increased vascular access complications in patients with renal dysfunction undergoing percutaneous coronary procedures using arteriotomy closure devices. *J Invasive Cardiol*. 2010;22:8-13.