

Getting Access to the Lesion

A practical approach to guidewire, catheter, and sheath selection for peripheral and visceral vascular disease.

BY PARAG J. PATEL, MD, AND RAHUL S. PATEL, MD

Endovascular treatment of peripheral vascular disease has evolved tremendously during the past 20 years. The number of endovascular devices—including balloons, stents, and stent grafts, as well as adjunctive devices for debulking and true lumen re-entry—has exploded as industry has invested significant resources in their design and development. Additionally, when compared to earlier generations, these newer devices are made with lower profiles, different delivery shaft lengths, as well as varying guidewire platforms and delivery systems. The increase in device options has facilitated the growth of endovascular therapies. However, anatomic constraints remain the one constant in treating these lesions. In other words, if you cannot get to the lesion, you cannot treat the lesion. There has been an equally phenomenal growth in guidewires, catheters, and sheaths that permit access to lesions that were previously not possible to treat. Herein, we review some of the devices and techniques that we find helpful in reaching the lesions we are targeting for treatment.

As with all endovascular treatments, the first step to a successful intervention is appropriate preprocedure imaging (eg, ultrasound, computed tomographic angiography [CTA], or magnetic resonance angiography [MRA]). This will help in selecting the appropriate access site and tools needed to perform the intervention.

VISCERAL INTERVENTION

Endovascular treatment of visceral artery lesions is attractive because many of these patients are older and have significant comorbidities. Its main advantages over surgical options are shorter hospital stay and decreased morbidity and mortality rates. Abdominal visceral vas-

cular intervention typically refers to the mesenteric and renal vascular beds. Preprocedure planning with CTA is essential. Key factors include the angle of origin of the mesenteric or renal vessels in relation to the aortic axis, the presence of calcification and/or thrombus, as well as identifying important collaterals in proximity to the targeted lesion.

Details of arterial access are beyond the scope of this review; however, the Seldinger technique is used to achieve common femoral artery (CFA) and, less commonly, brachial artery access. A floppy tip or J-wire is typically used for arterial access, as these are relatively atraumatic. For the purpose of further discussion, CFA access will be presumed unless otherwise noted. Vascular access is then secured with a standard 5-F, 10-cm vascular sheath such as the Pinnacle sheaths (Terumo Interventional Systems, Somerset, NJ). This is typically sufficient for diagnostic angiography work. If an intervention is planned, initial placement of a 6-F sheath may be preferred. In the setting of tortuous iliac arteries, consideration should be made for use of 25-cm vascular sheaths. The distal sheath tip can be positioned above the aortic bifurcation thereby diminishing the influence of iliac tortuosity on the catheter, which allows improved catheter torqueability.

Aortography is typically performed with one of a variety of flush catheters. The authors prefer a 5-F pigtail or Omni Flush catheter (AngioDynamics, Queensbury, NY) because these optimally direct the contrast bolus laterally into the mesenteric or renal arteries rather than craniocaudally. Accordingly, the catheters are positioned with the distal tip slightly above the origin of the vessel of interest. Selective catheterization of the mesenteric or renal arteries can often be accomplished with a cobra-shaped catheter. However, in the setting of

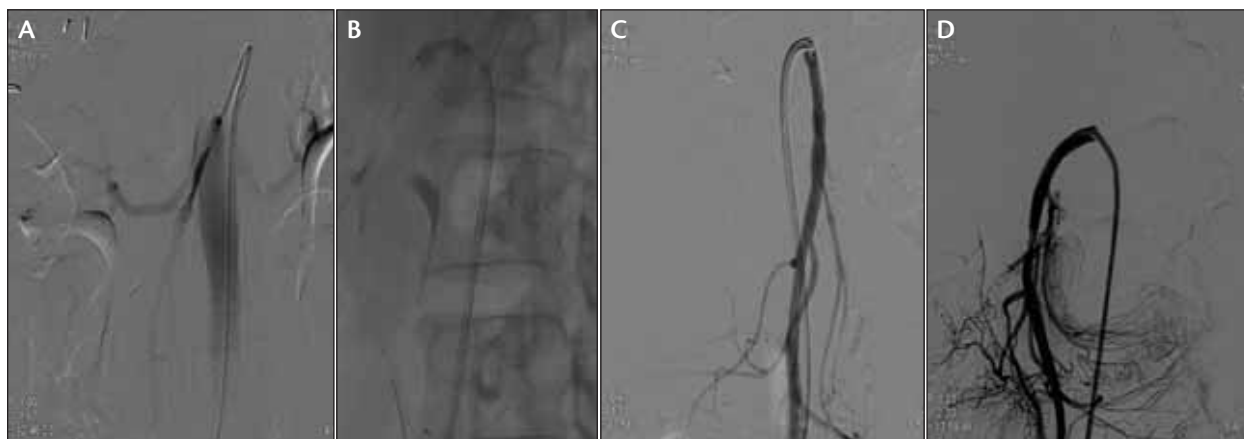

Figure 1. Patient with chronic mesenteric ischemia and high-grade superior mesenteric artery (SMA) and celiac artery stenoses. Selective catheterization was performed with a reverse-curve catheter through a long guide catheter (A). Initial 4-mm PTA was performed over an 0.018-inch wire (B). Despite predilation, the balloon-expandable stent would not advance across the stenosis. Two 0.014-inch buddy wires were placed alongside each other to facilitate delivery of the balloon-expandable stent (C). Angiogram after successful stenting of the SMA origin shows a widely patent SMA with markedly improved filling of distal jejuna and colic branches (D).

significant ostial stenoses, a cobra catheter may not afford sufficient purchase for subsequent angiography and/or intervention. Difficulty engaging the targeted artery may also be secondary to the presence of atherosclerotic aortic disease, iliac tortuosity, and abdominal aortic aneurysm. In many of these cases, a reverse-curve catheter is preferred. We often use a Sos Selective (AngioDynamics) or Simmons catheter (Figure 1A). The vessel is then selected primarily with either a small- (0.014 or 0.018 inch) or large- (0.035 inch) platform guidewire.

Our choice for 0.018-inch wires is the V-18 Control wire (Boston Scientific Corporation, Natick, MA), and for 0.014-inch wires, we prefer the Grand Slam (Abbott Vascular, Santa Clara, CA) or balanced middleweight wires. The TAD wires (Covidien, Mansfield, MA) are another good option, which are 0.035 inch but taper to 0.018 inch distally. This taper affords a small flexible distal tip with the support of a large platform wire. This selection offers a range of support and torqueability to aid in device delivery; however, care must be taken when advancing any of these wires, as distal vessel perforation is possible. At this point, the base catheter can often be withdrawn into the vessel as it follows the path of the guidewire. For lesions that are distal to the ostium of the main renal or mesenteric artery, this may be a sufficient catheter purchase to allow for diagnostic or initial planning angiography.

Planned interventions in the visceral arterial vasculature benefit from placement of either a guide sheath or guide catheter at the orifice of the targeted vessel. This

will ease delivery of devices to the targeted lesion as well as provide a means for intraprocedural angiography without necessitating a catheter exchange. There are several options of guide catheters and sheaths. For renal arterial interventions, we prefer 6-F RDC (renal double curve) guide catheters or a flexible 6-F guide sheath such as the Ansel or Raabe sheaths (Cook Medical, Bloomington, IN). There are a number of techniques to deliver the guide catheter or sheath. The decision may be based on the desired guidewire platform for ultimate device delivery. Most visceral vascular interventions are performed on smaller vessels with shorter lesions. The majority of balloons and stents designed to treat these lesions are on a 0.014- or 0.018-inch platform (Figure 1B).

When using a guide sheath, guidewire access may be obtained in conjunction with the desired diagnostic catheter. The catheter and initial base sheath need to be exchanged for the longer guide sheath. Although this is feasible, it is reliant on maintaining guidewire access across the lesion during catheter withdrawal and sheath exchange. This may be tenuous because sufficient guidewire purchase is necessary to facilitate advancement of the guide sheath to the targeted vessel. This is generally performed over a 0.035-inch guidewire, although some guide sheaths, such as the Ansel sheath, come with a 0.018-inch dilator. Alternatively, the base catheter can be exchanged for a guide catheter, eliminating the need to replace the base sheath. Another option would be to exchange for the guide sheath in advance of selecting the target vessel. Position the guide

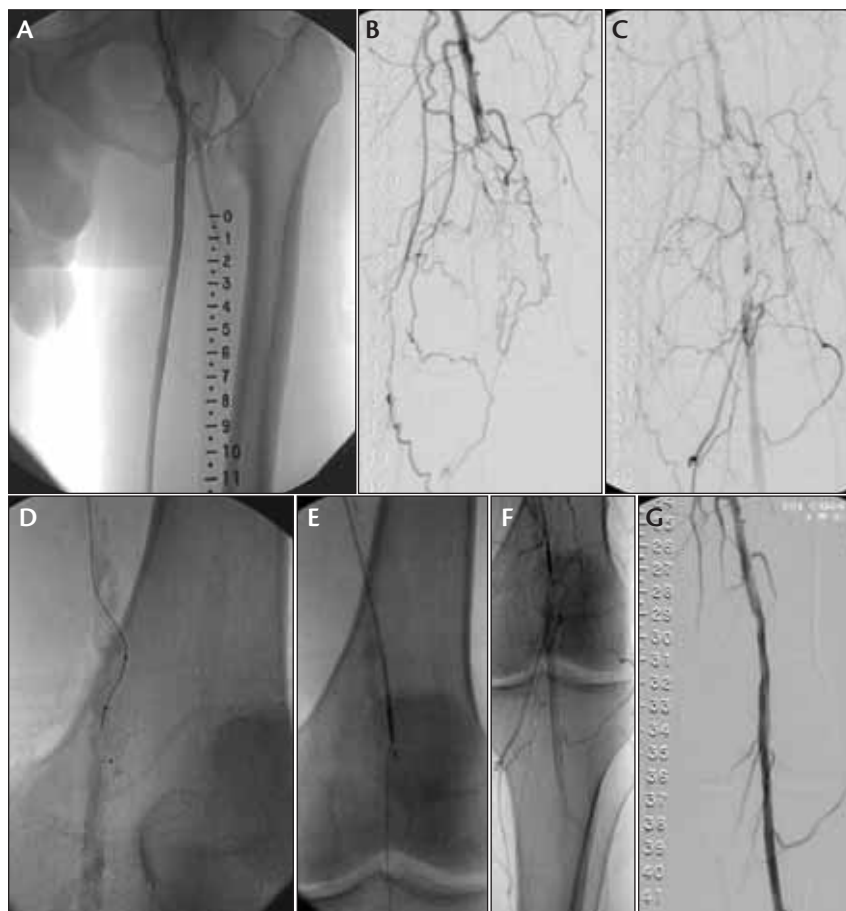


Figure 2. Patient with critical limb ischemia and occluded superficial femoral artery (SFA). Antegrade access was obtained (A), and angiography revealed a distal SFA occlusion with reconstitution of the popliteal artery (B, C). Recanalization was performed with a Quick-Cross catheter (Spectranetics Corporation, Colorado Springs, CO) in conjunction with a hydrophilic guidewire (D). A subintimal course was taken around the heavily calcified lesion, but distal re-entry was not successful. An Outback LTD re-entry device (Cordis Corporation, Bridgewater, NJ) was used with a 0.014-inch Grand Slam wire to obtain distal re-entry (E, F). Angiogram after placement of 6-mm Viabahn endograft (W. L. Gore & Associates, Flagstaff, AZ) (G).

sheath in the mid or distal aorta. Through the guide sheath, select the target vessel with the choice of a small or large platform wire and selective catheter. At this point, the guide sheath can be telescoped over the diagnostic catheter and guidewire to the target vessel ostium. The catheter is then removed, and the appropriate device is delivered. A similar technique can be used with guide catheters (Figure 1A). The guide catheters are typically packaged with a small-caliber introducer that will allow introduction over a 0.014- or 0.018-inch wire. The guide catheter can also be advanced over a smaller diagnostic catheter in a similar method as described previously in this article.

In severely stenotic ostial visceral lesions, initial angioplasty of the lesion is recommended to facilitate stent placement. During deflation of the balloon angioplasty catheter, the guide catheter or sheath may be advanced over the balloon catheter, which acts as a short introducer. These lesions may be refractory to angioplasty, which may not permit this maneuver to be accomplished and ultimately may not allow stent delivery. In these cases, additional guidewire support may be necessary. When additional support is needed, we have used the buddy wire technique (Figure 1C). This technique uses two 0.014-inch wires positioned alongside each other through the guide catheter, into the target vessel, and across the lesion. The devices are delivered over one of these wires, while the other wire is left stationary alongside the device catheter. This is particularly useful in tortuous anatomy and aids in stabilizing the guide catheter while adding support to the balloon catheter and/or stent.

INFRAINGUINAL INTERVENTION

Most infrainguinal interventions are performed from a contralateral CFA access using an up-and-over technique. Getting up and over can

be achieved in various ways. If aortic angiograms are performed before getting over the aortic bifurcation, an Omni Flush catheter is often used. The reverse curve of the catheter is opened up by advancing a Bentson wire (Cook Medical) a few centimeters beyond the catheter tip above the bifurcation. Both the catheter and wire are then pulled down and seated over the bifurcation. The catheter and wire are advanced over into the ipsilateral CFA. Using this method, most up-and-over accesses can be achieved. Another method sometimes used is a combination of a cobra-shaped Glidecath and an angled Glidewire (Terumo Interventional Systems). This method is usually successful but can be difficult in patients with steep bifurcations.¹

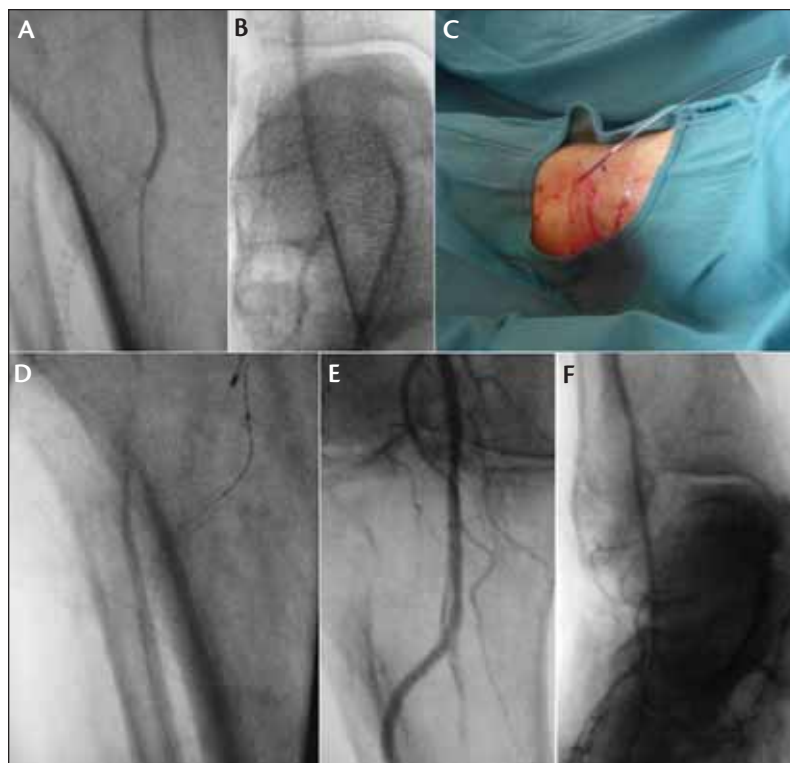


Figure 3. Patient with critical limb ischemia with previously placed anterior tibial stent, which is occluded. Attempted recanalization from an antegrade approach failed (A). The dorsalis pedis artery is accessed with a 22-gauge needle under fluoroscopic guidance (B). An 0.014-inch wire and Amphirion Deep balloon (Medtronic, Inc., Minneapolis, MN) was passed, and the occluded stent was crossed (C, D). Angiogram after angioplasty shows the stent is patent, and hemostasis at the puncture site was achieved with gentle manual compression (E, F).

Once a catheter is placed up and over and imaging of the extremity is performed, a guide sheath is placed into the CFA. This is delivered over a stiff wire (eg, Amplatz super stiff [Boston Scientific Corporation], Wholey wire [Covidien], or stiff angled Glidewire). Typically, the size of the guide sheath is 6 F to accommodate delivery of most balloons and stents. A larger sheath size may be needed if covered stents (eg, Viabahn) are to be placed. There are numerous sheaths that can be used, such as the Balkin (Cook Medical), Destination (Terumo Interventional Systems), or long Arrow-Flex sheaths (Arrow International, Reading, PA), all of which come in several different French sizes. Sometimes, due to a steep bifurcation, delivery of the crossover sheath can be difficult. This can be overcome by using an extra stiff guidewire or telescoping the sheath over the dilator or selective catheter and over the bifurcation.

Due to the stent systems for infrainguinal interventions, the wires used are typically 0.035 inch in size. If

the diseased segments are crossed easily, stenting, angioplasty, and imaging can then be performed with the operator's preferred 0.035-inch working guidewire. We typically use a 0.035-inch Wholey or Storq (Cordis Corporation) wire.

The long-segment occlusions and subintimal recanalizations are truly where knowledge of different wires and catheters becomes helpful. In our institutions, initial attempts at subintimal recanalizations are performed using either a hydrophilic Glidewire or an LLT wire and a 4- or 5-F-long catheter such as a VERT curve or angled Glidecath. Having the up-and-over guide sheath is helpful in this situation because intraprocedural imaging can be performed to mark the re-entry point, and the sheath gives added support and pushability. The crossing profile of the 4- or 5-F catheter may sometimes not allow for passage of the catheter. In these cases, we use a Quick-Cross catheter. This catheter has a lower crossing profile but at the expense of reduced catheter stiffness or support.

The most difficult part of any subintimal recanalization is re-entry back into the true lumen in an appropriate place. In our institutions, this is first attempted

using a combination of various catheters and wires. The devices that seem to perform the best for us include straight or angled Glidewires used in conjunction with a curved catheter such as a VERT, MPA, or RIM catheter.

If this is unsuccessful, a re-entry device can be used (Figure 2). There are currently two re-entry devices on the market in the United States: Outback LTD and Pioneer (Medtronic, Inc.). The Outback LTD is a 6-F system, and the Pioneer is a 7-F system with integrated intravascular ultrasound for targeting. Both are based on a 0.014-inch system. In our experience, the wire that works best with both of these systems is the Grand Slam wire. Some of the other 0.014-inch wires can get bound up within the system or even sheared off by the needle. When steep bifurcations are present, the device may not be able to go up and over due to the inherent stiffness within the device. Once the 0.014-inch wire is in the true lumen, the re-entry device is removed and exchanged for a catheter, and the wire is then exchanged for a 0.035-inch wire. Angioplasty and stenting are then performed as needed.

Alternative access should be considered when re-entry cannot be performed or the operator is unable to go up and over (eg, previous aortoiliac stenting or endovascular aortic aneurysm repair). If there is enough patent proximal SFA, an antegrade approach can be helpful (Figure 2A). This allows for greater pushability and, in our experience, easier re-entry. Working from an antegrade access can be a bit cumbersome because the back end of the wires lay on the patient's abdomen or head. Additionally, there is concern for a higher risk of groin complications.² Antegrade access can be achieved with direct ultrasound guidance or by palpation and fluoroscopy to ensure that access is into the CFA.

Another helpful but often underutilized access is the transpopliteal approach. It is beneficial to have a catheter in the CFA so imaging can be performed while recanalizing a chronic occlusion. It is important to have enough space at the proximal SFA/CFA to re-enter, as an inappropriate re-entry site can lead to stenting over the origin of the profunda artery. Usually, the popliteal access sheath can be pulled and manual pressure used to achieve hemostasis.³

INTRAPOPLITEAL INTERVENTIONS

Infrapopliteal interventions can be somewhat problematic in that up-and-over access may not always work due to the limited working length of catheters and devices. For example, we commonly use the Amphirion Deep balloons among others; however, the longest working length is 150 cm, which may be too short to reach the distal tibial vessels in a tall patient. Depending on the area of disease (proximal vs distal) in the tibial bed, either a contralateral retrograde access or an antegrade access is chosen.

We typically use a long 4-F Flexor tibial sheath (Cook Medical) when performing infrapopliteal intervention from a contralateral access. The advantage is its long length (90–100 cm) and ability to easily pass through the 6-F crossover sheath. This allows treatment of a femoropopliteal lesion before the infrapopliteal intervention. Most of the balloons and stents used for tibial intervention will pass through a 4-F sheath.

For antegrade access, we typically use a 4-F long sheath such that the tip of the sheath lies in the distal popliteal artery. This gives the best imaging and greatest pushability. The sheath can be placed further into a specific tibial vessel, but the vessel must be large enough to accommodate a 4-F sheath without being occlusive.

For most tibial interventions, we use a 0.014-inch wire. We have found for crossing tibial occlusions, a 0.014-inch guidewire with a hydrophilic tip works best (eg, PT Graphix or PT2 wire [Boston Scientific Corporation]).

This is also done with a catheter for support, such as a Quick-Cross catheter or the Amphirion Deep balloon itself. If we are unable to cross a tibial occlusion with these wires, we have found some of the coronary chronic total occlusion guidewires, such as the Miracle Bros or Confianza (Abbott Vascular), work well.

In complex popliteal and infrapopliteal occlusions, an antegrade recanalization attempt can fail in up to 20% of cases.⁴ In these cases, we will use a retrograde (transpedal) approach. This is done with a 22-gauge needle to access the vessel and a 0.014-inch wire and a low-profile 0.014-inch catheter or even the Amphirion Deep balloon (Figure 3). A sheath can be placed into the pedal vessel if it is big enough, but typically this step is not necessary. Once the occlusion is crossed, the 0.014-inch wire is captured from above, and the necessary interventions are performed from the antegrade access. Hemostasis at the pedal access site is obtained by either gently inflating the balloon over the entry site or with light manual compression.

CONCLUSION

The growth of endovascular intervention coincides with the expansion of available devices. Many of the previous anatomic restrictions that limited safe treatment or delivery of devices can be overcome with knowledge of the various catheters, guidewires, and sheaths available. Although this review offers our approach, there are several additional methods to accomplish these same results. Additionally, further development of devices will only bring newer and better tools and techniques for the interventionist's disposal. ■

Parag J. Patel, MD, is Assistant Professor, Department of Radiology, Vascular & Interventional Radiology, Medical College of Wisconsin in Milwaukee, Wisconsin. He has disclosed that he holds no financial interest in any product or manufacturer mentioned herein. Dr. Patel may be reached at (414) 805-3125; papatel@mcw.edu.

Rahul S. Patel, MD, is Assistant Professor, Department of Radiology, Vascular & Interventional Radiology, University of Maryland in Baltimore, Maryland. He has disclosed that he holds no financial interest in any product or manufacturer mentioned herein. Dr. Patel may be reached at (410) 328-3631; rpatel@umm.edu.

1. Bachman DM, Casarella WJ, Sos TA. Percutaneous iliofemoral angioplasty via the contralateral femoral artery. *Radiology*. 1979;130:617-621.

2. Nice C, Timmons G, Bartholemew P, et al. Retrograde vs antegrade puncture for infringuinal angioplasty. *Cardiovasc Intervent Radiol*. 2003;26:370-374.

3. Saha S, Gibson M, Magee TR, et al. Early results of retrograde transpopliteal angioplasty of iliofemoral lesions. *Cardiovasc Intervent Radiol*. 2001;24:378-382.

4. Montero-Baker M, Schmidt A, Bräunlich S, et al. Retrograde approach for complex popliteal and tibioperoneal occlusions. *J Endovasc Ther*. 2008;15:594-604.