

CASE REPORT

Bland Hepatic Embolization for Metastatic Rectal Neuroendocrine Tumors

BY VENU VADLAMUDI, MD

A 41-year-old woman with a history of rectal neuroendocrine tumors underwent primary resection several years ago. She presented to the interventional oncology clinic following referral from her medical oncologist due to bulk symptoms from newly diagnosed hepatic metastatic tumors (biopsy-proven grade I neuroendocrine tumors; Figure 1). Due to the size of the tumors, the decision was made to proceed with bland embolization for devascularization/debulking of the largest tumors.

PROCEDURE

A left radial approach was used with a 5-F sheath. Using a 5-F X 110-cm radial catheter, a celiac arteriogram was performed; it showed standard anatomy but hypertrophied hepatic branches, especially the right hepatic branches (Figure 2). Through the radial catheter, bland embolization of the right hepatic arterial supply to the largest tumors was performed utilizing 100- μ m Embozene™ Microspheres (Boston Scientific Corporation). During embolization of the segment 7-8 supply, there was intratumoral hemorrhage from a branch near the dome, which was embolized through a 2.4-F X 150-cm microcatheter utilizing 4:1 n-BCA glue. Final angiography demonstrated good pruning of the distal tumoral supply with preservation of the main arterial branches for potential future liver-directed therapy (Figure 3).

The patient was discharged home the same day with methylprednisolone. She reported initial abdominal discomfort for a

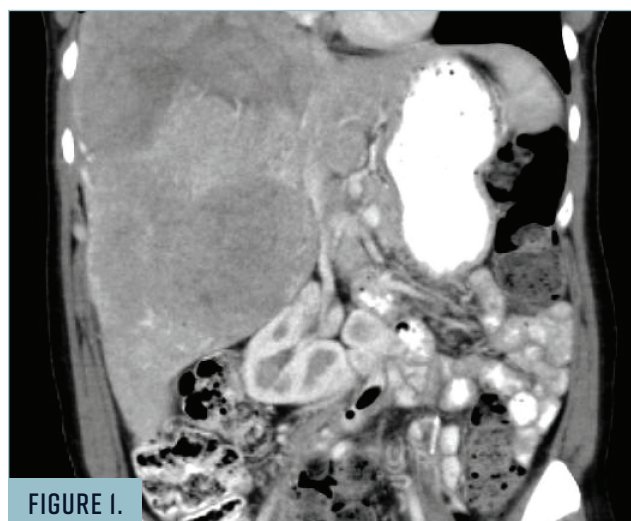


FIGURE 1.

Preoperative CT abdomen demonstrated large vascular tumors throughout the right lobe of the liver. Note the mass effect on the medially/inferiorly displaced right kidney.

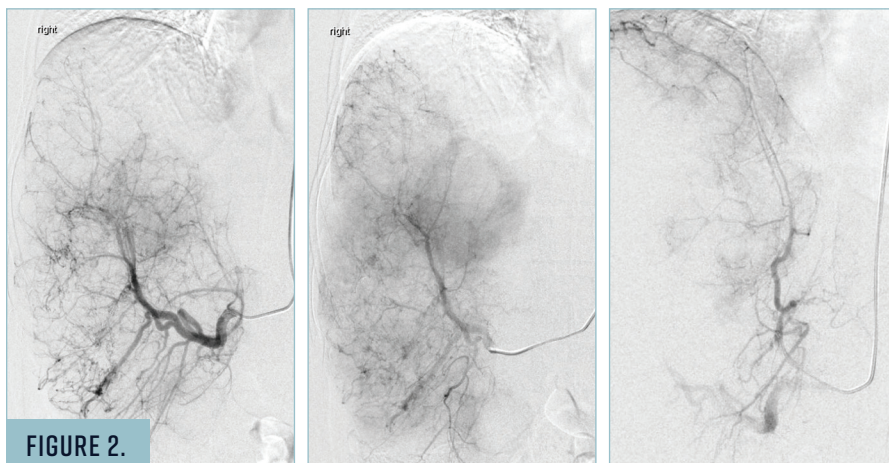


FIGURE 2.

Hepatic angiograms (segments 4-6 and segments 7-8) confirm supply to multiple hypervascular neuroendocrine metastases.

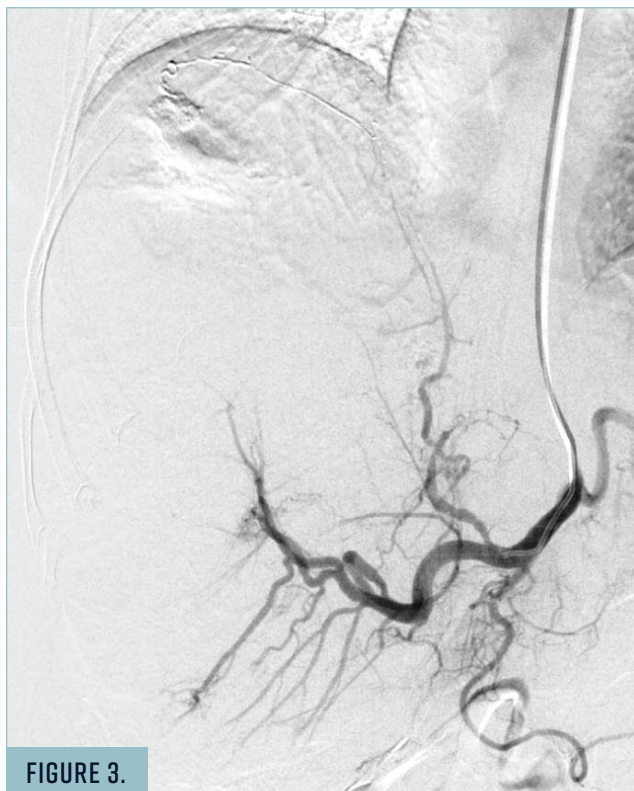

FIGURE 3.

Final celiac angiogram demonstrated good pruning of the distal tumoral supply with preservation of major arterial branches. Note the glue cast in the distal segment 7-8 branch.

few days, which slowly improved. She was seen at 6 weeks, and an MRI of the abdomen demonstrated good devascularization of the largest right hepatic tumors and an approximate 15% decrease in overall volume compared to preoperative imaging (Figure 4). She reported improvement in her original bulk symptoms.

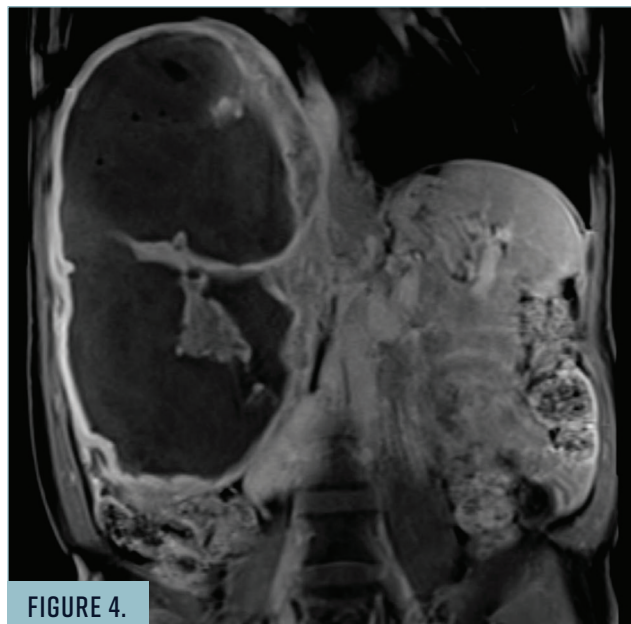


FIGURE 4.

Follow-up MRI at 6 weeks demonstrated good devascularization of the large right hepatic tumors.

CONCLUSION

Embozene™ Microspheres allow for calibrated bland embolization of distal vasculature while preserving larger proximal branches. ■

venu vadlamudi, MD

Inova Alexandria Hospital
Alexandria, Virginia
Disclosures: None.