

Sponsored by Medtronic

The MVP™ Micro Vascular Plug: A New Paradigm in Peripheral Embolization

BY RIPAL T. GANDHI, MD, FSVM; BRIAN E. SCHIRF, MD; AND JONATHAN IGLESIAS, MD

Coils and plugs have emerged as the most commonly employed mechanical embolic devices. Various coils are used in daily practice for an array of clinical applications. Although effective, the main disadvantage of coils relates to the number of coils and time needed to achieve adequate vascular occlusion. Additional limitations of traditional pushable coils include lack of controlled deployment, occlusion of nontarget vessels secondary to coil migration, incomplete occlusion, and recanalization.

More recently, vascular plugs have been shown to be a viable alternative to conventional coil embolization. Advances in technology have led to the widespread availability of plugs in a variety of lengths and sizes and have helped overcome the access and time limitations of conventional coils. The Amplatzer Vascular Plug 4 (St. Jude Medical, Inc.) is available in 4- to 8-mm diameters and allows for the occlusion of arteries from 2.6- to 6.2-mm. Although it is an effective embolic device, its primary shortcoming is that it still requires a 4- or 5-F catheter (0.038-inch inner-diameter lumen) for delivery and does not result in immediate occlusion. This precludes its utilization in a significant number

of embolization procedures in which smaller-caliber vessels necessitate a microcatheter or if a more rapid occlusion is desired.

The newly developed, CE Mark- and US Food and Drug Administration-cleared state-of-the-art MVP™ micro vascular plug system (Medtronic) addresses the drawbacks of its predecessors. The MVP™ plug, composed of nitinol and covered by a polytetrafluoroethylene (PTFE) membrane at the proximal end and approximately two-thirds of its length, is designed for rapid vascular occlusion (Figure 1). Passing through standard microcatheters, the MVP™ plug can navigate through tortuous vessels as small as 1.5 to 3 mm in diameter, providing super-selective access and embolization. The MVP™ plug is a detachable and resheathable device, which allows for controlled, precise deployment with stability. Finally, the device allows for angiography to be performed through the microcatheter with the MVP™ plug in place before deployment, which enables additional safety and unparalleled accuracy.

TECHNICAL DETAILS AND CLINICAL BENEFITS

The MVP™ plug is currently available in two sizes: (1) The MVP-3 plug has an unconstrained diameter of 5.3 mm for target vessels in a 1.5- to 3-mm-diameter range; (2) the MVP-5 plug has an unconstrained diameter of 6.5 mm for target vessels in a 3- to 5-mm-diameter range. The MVP-3 and MVP-5 plugs are designed for delivery via 0.021-inch and 0.027-inch inner-diameter microcatheters, respectively (Table 1).

The length of the unconstrained MVP™ plug is 12 mm, which may increase up to about 15 mm when deployed in the vessels in target diameter range; therefore, a landing zone length of ≥ 15 mm is recommended to accommodate the device without inadvertently occluding unintended vessels. The manufacturer advises against placing the device at the curve of a vessel; however, we have landed the device in such a location in several cases with stability of the device and no complications.

The MVP™ plug boasts an array of established clinical




Figure 1. The MVP™ plug, composed of nitinol and covered by a PTFE membrane at the proximal portion, is designed for immediate vascular occlusion. Reprinted with permission from Medtronic.

TABLE 1

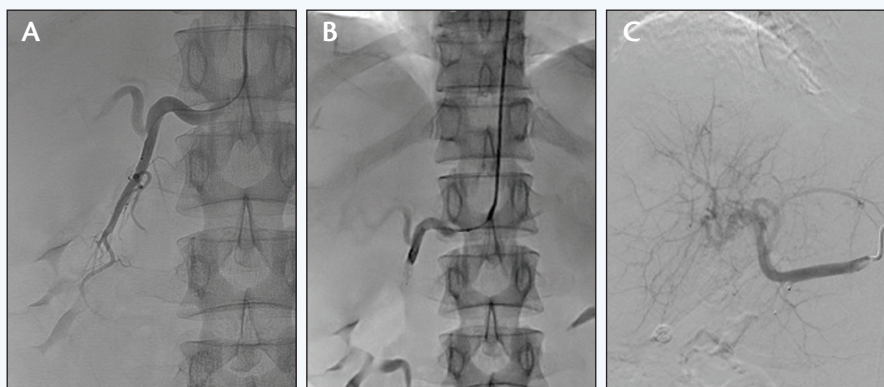
Catalog Number	Target Vessel Diameter (mm)	Unconstrained Length (mm)	Maximum Constrained Length (mm)	Unconstrained Device Diameter (mm)	Recommended Microcatheter ID (inches)	Detachment Method
MVP-3 or MVP-3US	1.5–3.0	12	15	5.3	0.021	Electrolytic
MVP-5 or MVP-5US	3.0–5.0	12	15	6.5	0.027	Electrolytic
MVP-3Q	1.5–3.0	12	15	5.3	0.021	Mechanical
MVP-5Q	3.0–5.0	12	15	6.5	0.027	Mechanical

TABLE 2

	Hydrogel Detachable Microcoils	Hydrogel Pushable Microcoils	Fibered Platinum Microcoils	MVP™ Micro Vascular Plug (MVP-5)
Number of devices to occlude the GDA	2.9	5.5	11.5	1
Associated list cost/device	\$1,100	\$800	\$150	\$1,750
Total device cost to occlude	\$3,190	\$4,400	\$1,725	\$1,750
Time to occlude	25 min	32 min	20 min	Immediate

CASE 1

(Courtesy of Ratul Patel, MD)



A patient with hepatocellular carcinoma presented for a pre-Y-90 mapping procedure. Selective angiography of the GDA (A) via a radial approach showed a typical GDA. After advancement of an MVP™ plug, predeployment angiography (B) via the microcatheter showed the MVP™ plug to be slightly distal to the GDA origin. Placement of the MVP™ plug at the origin of the GDA was desired, so the device was slightly retracted and deployed with a subsequent angiogram (C) showing complete occlusion with a single device.

is compatible with any 0.021- or 0.027-inch microcatheter (≤ 155 cm) currently available on the market. This feature allows for unparalleled navigability, allowing the MVP™ system to be delivered to distal targets, even in the face of challenging tortuous anatomy. We have tracked the MVP™ plug across 360° turns in arteries with ease.

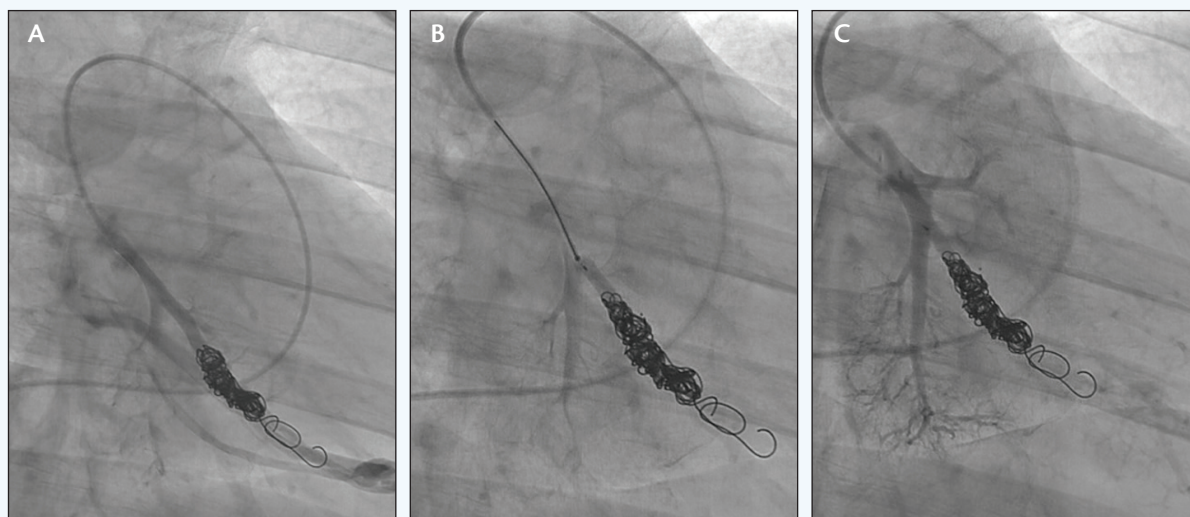
Microcatheter delivery also allows for pre-detachment angiography to ascertain efficacy and location. The value of the ability to inject contrast through the microcatheter with the

cally relevant device features. The MVP™ plug holds the advantage of being a single all-inclusive device capable of vascular embolization, differentiating it from coils and other plugs, which require multiple devices and/or time to achieve vessel occlusion. The MVP™ system

MVP™ plug in place cannot be overstated, because this is not feasible with coils. This unique feature allows for the operator to have greater confidence in placement and allows manipulation, if necessary, before final deployment.

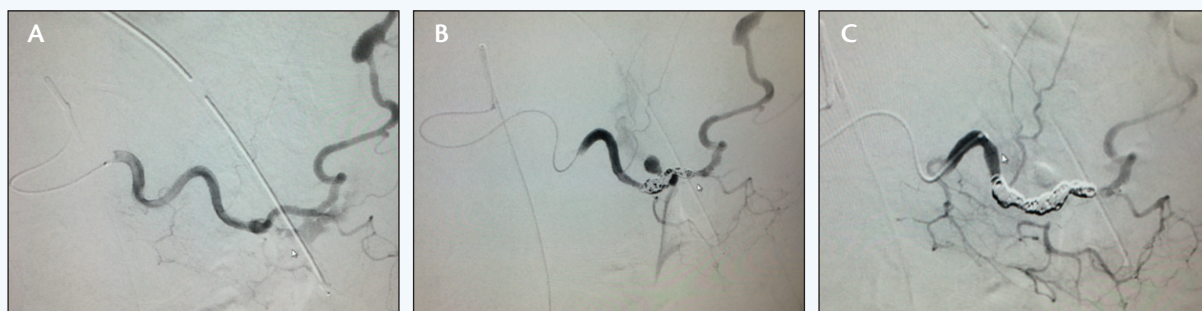Sponsored by Medtronic

CASE 2



A patient with a history of Osler-Weber-Rendu syndrome underwent previous coil embolization of a left lower lobe pulmonary AVM 5 years before presenting. A recent CTA (not shown) and subsequent angiogram (A) showed persistent flow to the previously embolized AVM due to recanalization. An MVP™ plug was placed at the origin of the pulmonary artery branch supplying the AVM, and angiography was performed via the microcatheter (B) before detachment. The final angiogram (C) showed complete occlusion of the AVM with a single device and preservation of flow to the adjacent pulmonary artery branches.

CASE 3



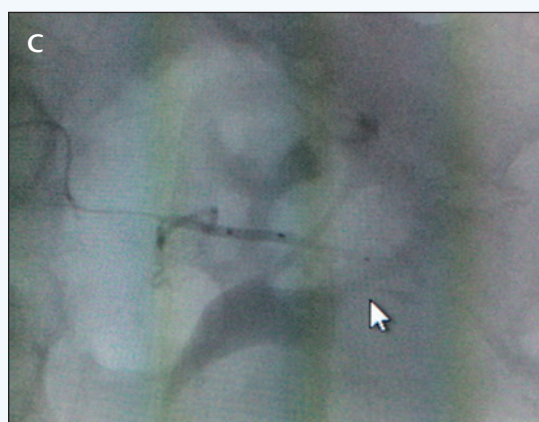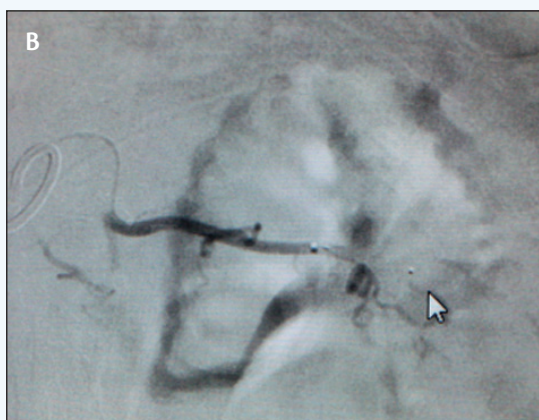
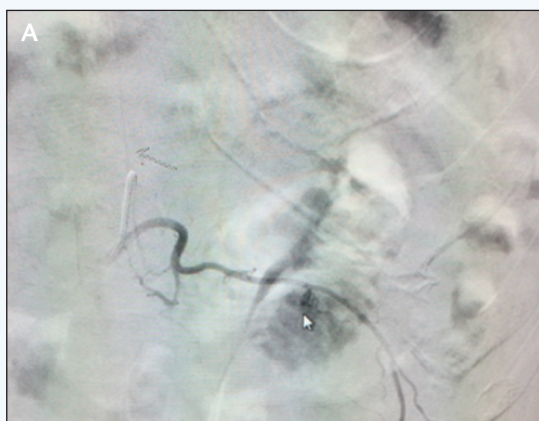A patient with gastric lymphoma presented with erosion into the splenic artery, massive hematemesis, and hypotension. Selective angiography of the splenic artery (A) showed extravasation (arrow) into the stomach (B). After deployment of a distal 5-mm MVP™ plug (arrow) and four Nester® coils (Cook Medical), there was continued in-flow to the pseudoaneurysm (C). After a proximal 5-mm MVP™ plug (arrow) was deployed, the pseudoaneurysm was isolated with no further contrast extravasation but with preserved collateral flow to the spleen.

The device's unique resheathability features allow it to be completely resheathed and redeployed without disruption, serving to ensure optimal and precise arterial occlusion. The ability to reliably place, reposition, and perform angiography before deployment provides vast benefits in difficult cases, especially when encountering precarious anatomy or high-flow vascular beds.

CLINICAL DATA

The device has been proven to be extremely efficacious, as it provides consistent, immediate, and stable target vessel occlusion from a single implant. The ability to produce immediate results is critical; other devices may require 20 minutes or longer to achieve complete occlusion. The MVP™ delivery system has been shown

CASE 4



A patient with left renal mass undergoing cryoablation developed an enlarging retroperitoneal hemorrhage after ablation needle removal. A selective left L1 lumbar arteriogram (A) showed a pseudoaneurysm, marked by the arrowhead and an arrow marking a spinal artery. A single 3-mm MVP™ plug was deployed (B) across the neck of the pseudoaneurysm, and there was no further hemorrhage or pseudoaneurysm perfusion on a follow-up arteriogram (C).

to reliably produce stable results. A clinical study by Pellerin et al demonstrated immediate occlusion in all treated vessels with no displacement or migration of the plug after successful implantation.¹ The MVP™ plug was resheathed, relocated, and redeployed in 30% of cases in this study without any issue.

Migration is a concern after coil embolization. This complication is minimized with the MVP™ plug, given the oversizing recommended by the manufacturer as well as the greater surface area of the device in contact with the vessel wall. Vascular recanalization after coiling is a well-known problem (Case 2). Although there is no systematically collected prospective data with regard to recanalization rates with the MVP™ plug, we hypothesize that vascular recanalization would be virtually eliminated given the circumferential PTFE covering of the device.

COST-EFFECTIVENESS

There are no studies specifically evaluating the cost-effectiveness of the MVP™ plug compared to pushable and detachable coils. Its value in an assortment of clinical applications as a stand-alone embolic device underlies its potential cost-saving benefits. According to the COSY trial, an average of 3.4 0.018-inch Interlock™ coils (Boston Scientific Corporation) were required for gastroduodenal artery (GDA) embolization during a Y-90 mapping procedure.² At a sales price of \$750, this would result in a \$2,550 total device cost for the embolization. A single MVP™ plug is listed at \$1,750, resulting in cost savings of \$800.

A prospective comparison of hydrogen-coated microcoils and fibered platinum microcoils for GDA embolization was evaluated by Maleux et al.³ Per Table 2 (please note the MVP™ device was not evaluated in this study but is included for comparison), the MVP™ device would result in significant savings over both pushable and detachable hydrogel microcoils. The MVP™ plug's cost is comparable to fibered platinum microcoils, although only a single MVP™ device is required with immediate occlusion.

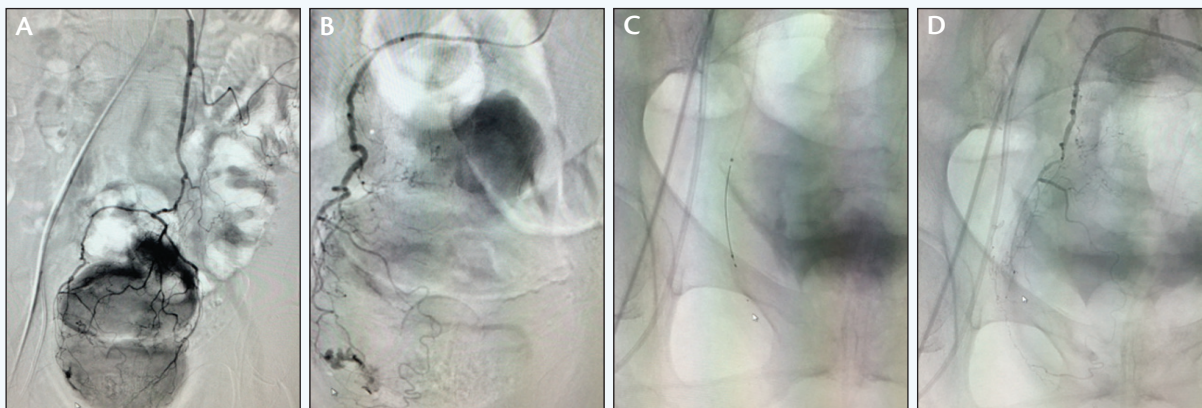
In addition to potential cost effectiveness with regards to device cost, additional savings may be realized via reduced procedure times, contrast utilization, complications, and need for reinterventions.

CLINICAL APPLICATIONS

The MVP™ plug may be used for a multitude of diverse clinical applications involving embolization of the peripheral vasculature (both arterial and venous). Selected clinical cases presented here include the following:

Sponsored by Medtronic

CASE 5



A patient presented with recurrent rectal hemorrhage with hypotension. An inferior mesenteric arteriogram showed active contrast extravasation (A). A selective microcatheter arteriogram showed sites of hemorrhage (B). A single 3-mm MVP™ plug was deployed (C) with immediate cessation of hemorrhage on a follow-up arteriogram (D).

- GDA embolization during a yttrium-90 (Y-90) radioembolization mapping procedure (Case 1).
- Recanalized pulmonary arteriovenous malformation (AVM) that was previously treated with pushable coils (Case 2).
- Splenic artery hemorrhage secondary to tumoral erosion (Case 3).
- Lumbar artery pseudoaneurysm after cryoablation (Case 4).
- Lower gastrointestinal hemorrhage (Case 5).

Another potential application of the MVP™ plug would be temporary vessel occlusion. For example, in a patient with previous extensive gastric/duodenal surgery, permanent embolization of the GDA may put the patient at risk for ischemic complications. In such a case, an interventionist may place an MVP™ plug in the GDA (leaving it on the delivery catheter undeployed) while performing radioembolization via a second access microcatheter. The MVP™ plug may then be resheathed and removed at the completion of the case. A similar strategy may be utilized in vascular malformations and other complex vascular cases in which only temporary occlusion of a critical vessel during the procedure is desired.

CONCLUSION

The MVP™ plug represents a new paradigm in embolotherapy with its unique ability to achieve safe, effective,

and immediate permanent vascular occlusion through a single device. The distinctive features of the device add a level of precision and efficiency currently unattainable with other devices. Dramatic decreases in occlusion time, achievable only with the MVP™ plug, leading to shorter procedure times make this an excellent tool, especially in critically ill patients.

The development of larger devices is currently underway and is poised to expand the clinical utility of the device. ■

Ripal T. Gandhi, MD, FSVM, is with Miami Cardiac and Vascular Institute in Miami, Florida. He has disclosed that he is a consultant to Medtronic. Dr. Gandhi may be reached at gandhi@baptisthealth.net.

Brian E. Schirf, MD, is with Riverside Radiology and Interventional Associates, Inc., in Columbus, Ohio. He has disclosed that he is a consultant to Medtronic and Cook Medical. Dr. Schirf may be reached at bschirf@riversiderad.com.

Jonathan Iglesias, MD, is with Miami Cardiac and Vascular Institute in Miami, Florida. He has disclosed that he has no financial interests related to this article.

1. Pellerin O, Maleux G, Dean C, et al. Microvascular plug: a new embolic material for hepatic arterial skeletonization. *Cardiovasc Intervent Radiol*. 2014;37:1597-1601.

2. Fischman AM, Ward TJ, Patel RS, et al. Prospective, randomized study of coil embolization versus Surefire infusion system during yttrium-90 radioembolization with resin microspheres. *J Vasc Interv Radiol*. 2014;25:1709-1716.

3. Maleux G, Deroose C, Fieuws S, et al. Prospective comparison of hydrogel-coated microcoils versus fibered platinum microcoils in the prophylactic embolization of the gastroduodenal artery before yttrium-90 radioembolization. *J Vasc Interv Radiol*. 2013;24:797-803.

Indications, contraindications, warnings, and instructions for use can be found in the product labeling supplied with each device.

CAUTION: Federal (U.S.A.) law restricts this device to sale by or on the order of a physician.