

Does Material Matter?

Absolute Ethanol

The history behind absolute ethanol as an intravascular embolic agent, its mechanism of action, and applications of its use.

BY WAYNE F. YAKES, MD, FSIR, FCIRSE

Embolotherapy is a burgeoning field developed by the subspecialties of interventional radiology and interventional neuroradiology and is rapidly being embraced by neurosurgeons, neurologists, vascular surgeons, and cardiologists who began performing minimally invasive catheter-directed procedures in recent years. The vast array of embolic agents that can be superselectively delivered with multiple catheter systems and direct puncture needles has blossomed due to the innovative ideas of numerous investigators and has led to improved quality and lower costs of care, quicker patient recuperation times, and the better outcomes that our patients deserve. This article describes the current uses of absolute ethanol as an embolic agent.

HISTORY

Particulate agents, coils, and detachable balloons dominated the early years of embolotherapy. Prof. Plinio Rossi was the first to develop selective catheter arteriography of the brachiocephalic arteries. In the late 1960s, Prof. Rossi had a scientific exhibit at Karolinska University Hospital in Stockholm, Sweden (P. Rossi, oral communication, September 1994; later collaborated by T. H. Newton, oral communication, October 1997) where he described his pioneering selective catheter technique to Prof. Hans Newton. Previously, only a technique using direct carotid injections with 18-gauge needles was employed. This method of selective catheterization along the carotid artery distribution gave rise to the concept of selective catheter delivery of contrast and embolic agents in other arterial anatomies as well.

In the late 1960s, Prof. Fedor A. Serbinenko pioneered catheter systems to navigate the internal carotid artery to the level of the cavernous carotid artery to deliver his

hand-made detachable balloons to treat carotid-cavernous fistulas, either resulting from trauma or aneurysm rupture.¹ By the early 1970s, Prof. Charles Kerber began working with isobutyl cyanoacrylate (IBCA).² When he finished his neuroradiology fellowship under Prof. Newton, he then became a staff neuroradiologist at the University of Oregon Health Sciences Center in Portland, Oregon (as an aside, Prof. Kerber performed the first carotid angioplasty).³

Prof. Kerber took the next step and developed microcatheter systems to navigate the cerebral vasculature (a calibrated-leak balloon catheter system) and many other pioneering developments.⁴ Because the lumen size of the calibrated-leak balloon system was small (no wire system was developed for it yet), only liquid agents were able to be injected through this catheter system. Prof. Kerber then integrated his work with IBCA, making embolization of cerebral arteriovenous malformations (AVMs) possible. Prof. Charles Dotter broke into Prof. Kerber's desk to use the IBCA to close pelvic vasculature trauma while Prof. Kerber was on vacation (C. Kerber, oral communication, July 1998).

Because the concept of selective catheterization in arterial systems was firmly in place, investigators aggressively pursued transcatheter delivery of many embolic agents. Dr. Brian Elman first developed preoperative transcatheter embolization of renal cell carcinomas with absolute ethanol.⁵ Absolute ethanol proved to be a superior embolic agent to particle and coil renal artery embolization due to the absence of any postembolization infarction syndrome. Other indications for the use of absolute ethanol soon came to light (see the *Current Indications for the Use of Ethanol as an Embolic Agent* sidebar).⁶

(Continued on page 75)

(*Absolute Ethanol, continued from page 71*)

CARDIOPULMONARY COLLAPSE ISSUES

Before the etiology of postethanol injection-cardiopulmonary (CP) collapse was elucidated, it was a rare but dire complication. A bolus of ethanol reaches the pulmonary vascular bed, and pulmonary artery spasm can then occur. If the spasm becomes severe enough, it can lead to pulmonary hypertension and right heart failure, which causes decreased left heart filling and

resultant systemic hypotension. Severe systemic hypotension causes decreased coronary artery perfusion. If severe enough, this can lead to cardiac arrhythmias such as electromechanical dissociation and asystole.

Prof. Young Soo Do and coinvestigators⁷ published an AVM treatment series showing that if the operator does not exceed 0.14 mL of ethanol/kg of body weight during a 10-minute period, CP collapse will not occur. I did a prospective in-house study of > 200 consecutive

CURRENT INDICATIONS FOR THE USE OF ETHANOL AS AN EMBOLIC AGENT

1. Curative treatment of AVMs has been published by many authors. Long-term cures are documented in these high-flow lesions (Figure 1).⁸⁻²³

2. Curative treatment of low-flow venous and lymphatic malformations has been published by many authors. MRI utilizing T2-weighted sequences with fat suppression and STIR imaging document permanent ablation of these low-flow lesions at long-term follow-up (Figure 2).^{12,14}

3. Preoperative embolization of renal cell carcinoma was one of the first indications for the use of ethanol as an embolic agent. However, because the nerves that cause the ischemic pain of infarction syndrome are destroyed with ethanol embolization, no infarction syndrome occurs and is tolerated well by patients. If a patient is a poor operative candidate, then primary treatment of, and occlusion with, cellular destruction of large renal cell cancers causing significant hematuria and transfusion requirements is possible with this endovascular technique alone.⁵

4. Hemorrhaging renal angiomyolipomas can be nonsurgically managed by superselective ethanol embolization of the tumor and preservation of the normal-functioning renal parenchyma (Figure 3).

5. Vascular tumors and their metastases can be infarcted and treated palliatively by superselective ethanol embolization in selected cases. In patients with metastatic renal cell carcinoma of the spine, relief of spinal block has been reported with this nonoperative, minimally invasive technique. Superselective ethanol embolization of inoperable and recurrent meningiomas has been a useful nonoperative adjunct to treat these vexing tumors (Figure 4).

6. Varicocele endovascular embolization with coils and ethanol is routinely successful to curatively manage this problem. Care must be taken not to have ethanol flow during embolization into the pampiniform plexus of the testicle. This can cause severe pain and an inflammatory reaction. Simple techniques such as placing a few small fibered coils in the refluxing varix immediately proximal to the inguinal canal and externally to manually compress the inguinal canal during the ethanol injection will prevent this potential complication. Frequently, varicoceles have multiple large and small collateral venous pathways that may be extremely challenging to access endovascularly. However, just as contrast injections flow into and opacify these multiple collateral channels, liquid ethanol can also fill these collateral channels and thrombose them completely, thus preventing recurrences (Figure 5). In patients who have

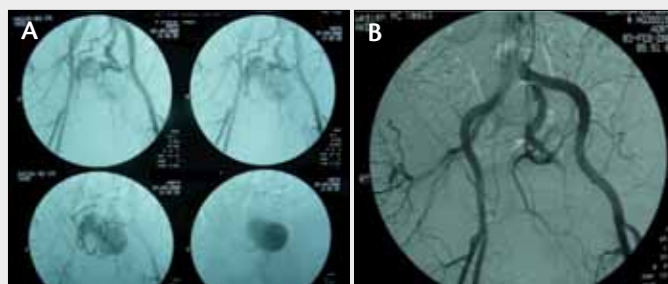


Figure 1. A 52-year-old man presented with increasing left pelvic pain symptoms (A). Oblique pelvis arteriography showed a large left pelvic AVM with giant venous aneurysm. There was atypical venous outflow toward the peripudendal venous plexus instead of the left internal iliac vein. Arterialized pulsations from the giant venous aneurysm accounted for the left pelvic pain. Oblique pelvis arteriography showed resolution of the left pelvic AVM at 9-year arteriographic follow-up (B). The patient has remained pain-free.

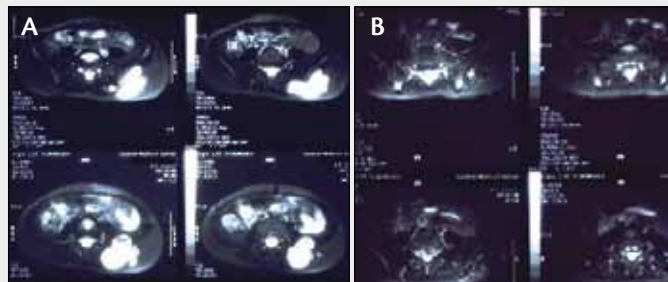


Figure 2. A 4-year-old girl presented with a massive left paraspinal venous malformation causing a severe pain (A). Magnetic resonance imaging (MRI) with T2-weighted sequences with fat suppression showed the massive extent of the painful lesion. At 3-year follow-up, an MRI with T2-weighted sequences with fat suppression demonstrates near-total obliteration of the massive venous malformation (B). The patient was pain-free.

varicocele recurrence after surgery and endovascular treatment by other methods, ethanol injections in these collateral channels is also curative.

7. Pelvic congestion syndrome is a challenging condition to manage clinically. Chronic pelvic pain is the main presenting symptom. Catheterization of the distal refluxing gonadal vein varices (the female

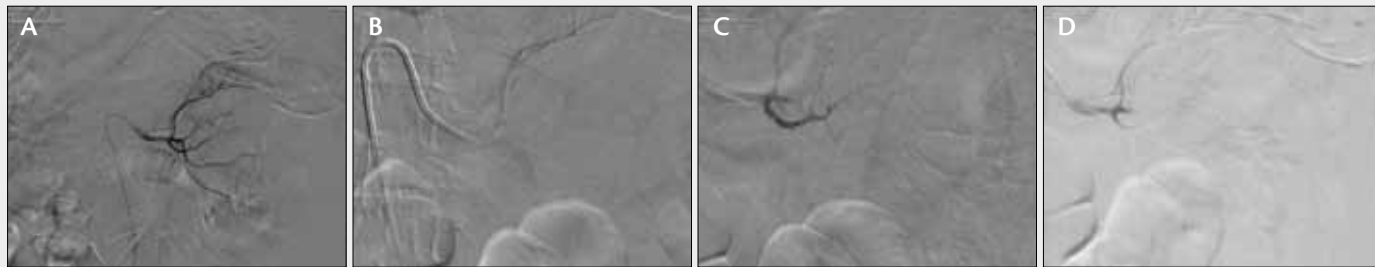


Figure 3. A 22-year-old man presented with a hemorrhaging left renal angiomyolipoma, and we proceeded with selective left renal ethanol embolization (A). We then performed elective microcatheterization of the renal upper pole (B) and lower pole branches (C). Digital subtraction angiography (DSA) showed draping renal artery branches around the lesion. Left renal DSA after ethanol embolization showed thrombosis without antegrade arterial flow (D). The hematuria ceased, and the patient was spared from surgical nephrectomy. No infarction syndrome occurred.

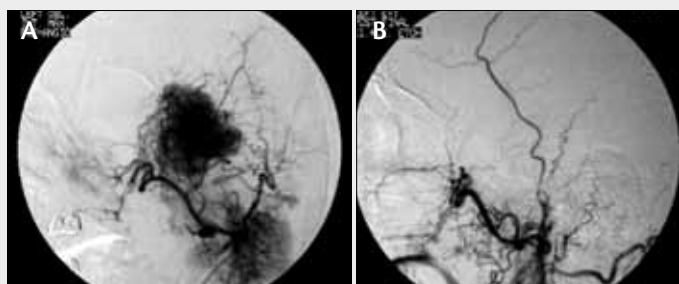


Figure 4. An 80-year-old man presented with a large left middle cranial fossa hypervascular meningioma (A). Surgical removal was obviated due to the patient's age and multiple comorbidities. Progressive speech problems and right upper and lower extremity weakness were the presenting symptoms. Care must be taken when embolizing with ethanol in the middle meningeal artery so that the microcatheter is positioned way distal to the foramen spinosum and so that no reflux of ethanol occurs at the level of the foramen spinosum. Important branches of the vasa nervorum from the middle meningeal artery to the seventh cranial nerve must be spared to prevent nerve damage. Ethanol embolization was then performed to treat the tumor in a minimally invasive fashion. Left external carotid DSA after total tumor devascularization with selective ethanol embolization of the left middle meningeal artery and left deep temporal artery vascular supply to the tumor (B).

version of varicocele) is difficult. But just as contrast can penetrate deep into the pelvic venous varices, ethanol does penetrate deeply to thrombose these dilated, refluxing abnormal venous structures. Despite successfully thrombosing these extensive venous channels, the pain can still persist for months. This suggests that the chronic venous engorgement pressuring against the pelvic nerves causes inflammation of the nerves, which may take awhile to abate—one more reason that this type of venous vascular lesion is so vexing to treat.

8. Benign cystic structures of the liver (and elsewhere) have many reported successes of their shrinkage by direct puncture aspiration of the cyst fluid and distillation of ethanol. It is important to drain the cyst of all fluid so that when the ethanol is injected to sclerose the wall of the cyst, it will not act as a diluent to decrease the efficacy of the ethanol.

9. Absolute ethanol infiltration in the nerve plexus (ie, the celiac plexus block) can permanently ablate nerve structures bathed in it. Many authors have reported success with this technique.

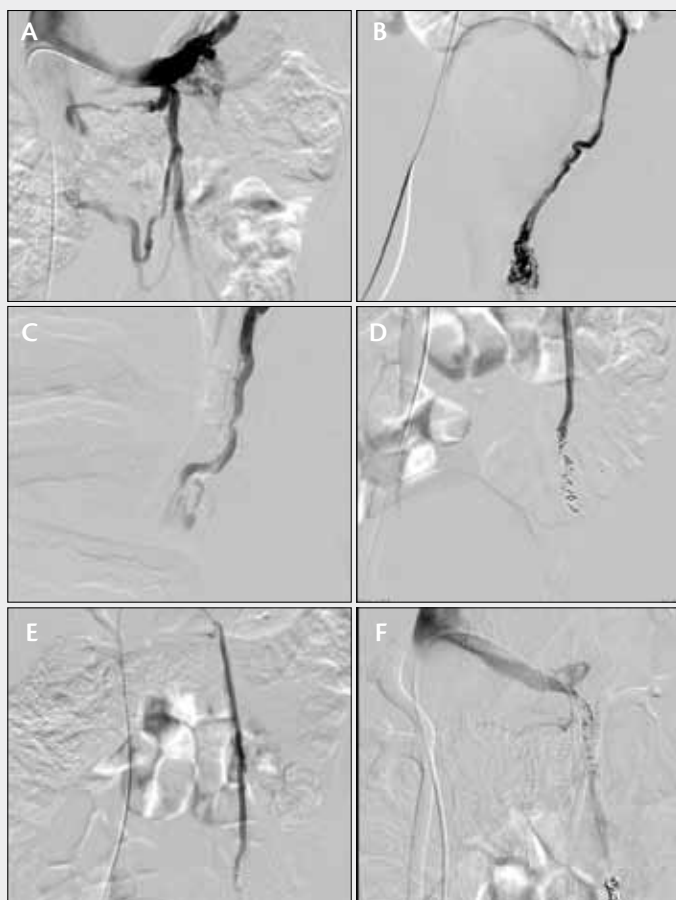


Figure 5. A left varicocele in a 7-year-old boy. Left renal vein DSA showed contrast reflux down the left gonadal vein (A). Selective left gonadal vein DSA showed contrast in the left testicular vein plexus causing the patient's symptoms (B). Selective left gonadal vein DSA with digital compression at the inguinal canal preventing contrast from flowing into the testicular vein plexus (C). This prevents ethanol injection into the pampiniform plexus. Left gonadal vein DSA postethanol and coil embolization in the distal gonadal vein (D). Left gonadal vein DSA showed collateral vein channels that can cause lesion recurrence (E). Left renal vein DSA showed varicocele closure after distal vein ethanol and fibered coil embolization, the mid-left gonadal vein ethanol embolization to occlude collateral channels, and proximal vein coil and ethanol embolization (F).

procedures in conjunction with my anesthesiologists. When treating high-flow lesions (AVMs/arteriovenous fistulas [congenital and acquired]), as well as low-flow lesions (venous malformations, lymphatic malformations, mixed lesions), with endovascular ethanol in doses of 0.1 mL/kg ideal body weight every 10 minutes, pulmonary pressures never increased to any significant degree, and CP collapse was obviated. Therefore, if one stays within these parameters for any intravascular ethanol procedure, CP collapse should not occur.

If a patient has pulmonary hypertension (whatever the etiology), they should have an arterial line placed and Swan-Ganz catheter monitoring of pulmonary pressures during the ethanol procedure. Small ethanol amounts can worsen their pulmonary hypertension and cause CP collapse.

MECHANISM OF ACTION

Absolute ethanol is a liquid embolic agent that penetrates to the capillary bed levels. Because of the distal penetration to the capillary bed level, tissues are totally devitalized, and infarcted collateral flow cannot occur. Therefore, great care and vigilance must be maintained to prevent unwarranted, nontarget embolization of vascular territories with ethanol. When injected into any vascular space (arterial, venous, lymphatic), ethanol denudes the endothelial cell from the vascular wall and precipitates its protoplasm. The denuded vascular wall is then fractured to the level of the internal elastic lamina. Platelet aggregation then occurs on the fractured and denuded vascular wall. Thus, thrombosis occurs beginning at the vascular wall with more and more accumulation until it thromboses centrally in the vascular lumen.

In vascular malformations, the endothelial cell is the reason recurrences are so common with embolic agents other than ethanol. The acute thrombosis that occurs with any embolic agent (polyvinyl alcohol, coils, glues, etc.) produces an ischemic state that is sensed by the intact endothelial cell lining of all vascular surfaces. Reacting to the acute ischemic state caused by the thrombosis, the endothelial cell releases chemotactic cellular factor and angiogenesis factor. Chemotactic cellular factor causes the migration of macrophages that carries off the intravascular debris formed during the embolization procedure. After there is significant debris removal, the endothelial cell then re-endothelializes the “new” lumen, which recanalizes the vascular malformation, leading to recurrences. The angiogenesis factor secreted by the endothelial cell stimulates new vascularity to the thrombosed ischemic area of the vascular malformation. This is called the “neovascular stimulation phenomenon” or “neovascular recruitment phenomenon.”

By using ethanol as an embolic agent, you can destroy the endothelial cell, and these two phenomena of recanalization and neovascular recruitment are noticeably absent.

Thus, there is a permanence of treatment, and cures are now possible.

SUMMARY

Absolute ethanol as an intravascular embolic agent must be respected. Inadvertent nontarget ethanol embolization must be completely obviated or devitalization of tissues with resultant necrosis will invariably occur. Unopacified ethanol as an embolic agent can be challenging to use successfully when one is only used to visualizing embolic agents fluoroscopically. Adhering to an ethanol injection protocol that does not exceed 0.1 mL/kg ideal body weight every 10 minutes will obviate the need for Swan-Ganz catheter monitoring of pulmonary artery pressure and arterial line monitoring of systemic arterial pressures unless the patient suffers from chronic pulmonary artery hypertension. Absolute ethanol has many indications for the treatment of the previously listed pathologic conditions, and investigators will invariably develop more indications for its use in the future. ■

Wayne F. Yakes, MD, FSIR, FCIRSE, is the Founder and Director of the Vascular Malformation Center in Englewood, Colorado. He has disclosed that he has no financial interests related to this article. Dr. Yakes may be reached at wayne.yakes@vascularmalformationcenter.com.

1. Serbinenko FA. Balloon occlusion of cavernous portion of the carotid artery as a method of treating carotid-cavernous fistulae. *Zh Vopr Neurokhir.* 1971;6:3-9.
2. Kerber CW. Intracranial cyanoacrylate. A new catheter therapy for arteriovenous malformation. *Invest Radiol.* 1975;10:536-538.
3. Kerber CW, Cromwell LD, Loehden OL. Catheter dilation of proximal carotid stenosis during distal bifurcation endarterectomy. *AJNR Am J Neuroradiol.* 1980;1:348-349.
4. Kerber CW. A new system for super-selective angiography and occlusive catheter therapy. *Radiology.* 1976;120:547-550.
5. Ellman BA, Parkhill BJ, Curry TS, et al. Ablation of renal tumors with absolute ethanol: a new technique. *Radiology.* 1981;141:619-626.
6. Yakes WF, Pevsner P, Reed M, et al. Serial embolizations of an extremity arteriovenous malformation with alcohol via direct puncture. *AJR Am J Roentgenol.* 1986;146:1038-1040.
7. Shin BS, Do YS, Lee BB, et al. Multistage ethanol sclerotherapy of soft tissue arteriovenous malformations: effect of pulmonary artery pressure. *Radiology.* 2005;253:1072-1077.
8. Yakes WF, Gibson MD, Parker SH, et al. Alcohol embolotherapy of vascular malformations. *Semin Intervent Rad.* 1989;6:146-161.
9. Yakes WF, Luetheke JM, Parker SH, et al. Ethanol embolization of vascular malformations. *Radiographics.* 1990;10:787-796.
10. Yakes WF, Luetheke JM, Merland JJ, et al. Ethanol ablation of arterio-venous fistulae: a primary mode of therapy. *J Vasc Interv Radiol.* 1990;1:89-96.
11. Rak KM, Yakes WF, Ray RL, et al. MR imaging of symptomatic peripheral vascular malformations. *AJR Am J Roentgenol.* 1992;159:107-112.
12. Yakes WF. Extremity venous malformations: diagnosis and management. *Semin Intervent Rad.* 1994;11:332-339.
13. Yakes WF, Rossi P, Odink H. Arteriovenous malformation management: how I do it. *Cardiovasc Interv Radiol.* 1996;19:65-71.
14. Keljo DJ, Yakes WF, Anderson JM, Timmons CF. Recognition and treatment of venous malformations of the rectum. *J Pediatr Gastroenterol Nutr.* 1996;23:442-446.
15. Yakes WF, Krauth L, Ecklund J, et al. Ethanol endovascular management of brain AVMs: initial results. *Neurosurgery.* 1997;40:1145-1154.
16. Yakes WF. AVMs—how I treat them: alcohol. *J Vasc Interv Radiol.* 1999;10:171-175.
17. Yakes WF. Management of high flow vascular malformations of the spine. *J Vasc Interv Radiol.* 2002;13:294-298.
18. Yakes WF. Management of high flow vascular malformations. *J Vasc Interv Radiol.* 2003;14:128-133.
19. Do YS, Yakes WF, Shin SW, et al. Ethanol embolization of AVMs: interim results. *Radiology.* 2005;235:674-682.
20. Yakes WF. Endovascular management of high-flow arteriovenous malformation management. *Zhonghua Kou Qiang Yi Xue Za Zhi.* 2008;6:327-332.
21. Lee BB, Kim HH, Mattassi R, et al. A new approach to the congenital vascular malformation with a new concept: how the pioneer Prof. Stefan Below enlightened us through the Seoul Consensus. *Int J Angiol.* 2003;12:248-251.
22. Yakes WF. Management of intraosseous AVMs. *Endovasc Today.* 2010;9:48-50.
23. Lee BB, Yakes WF, Mattassi R, et al. Consensus statement of the diagnosis and treatment of congenital high flow AVMs. *Int J Angiol.* In press.