

The Time Is Now for Transradial Intervention

A technical guide describing the uses of this technique in interventional radiology and oncology procedures.

BY AARON M. FISCHMAN, MD, AND RAHUL S. PATEL, MD

Use of the radial artery as the primary access vessel into the arterial system for transcatheter diagnosis and intervention is not a new concept. The first series describing diagnostic angiography of the coronary circulation using transradial access (TRA) was published in 1989 by Lucien Campeau at the Montreal Heart Institute.¹ Campeau suggested percutaneous radial access as a safer alternative to percutaneous and “cutdown” brachial or axillary access. His series of 100 patients demonstrated an 88% technical success rate and a 6% asymptomatic radial artery occlusion rate, which was a significant improvement over brachial/axillary upper arm access.¹ Shortly thereafter, in 1992, Kiemeneij performed the first successful transradial (TR) coronary angioplasty procedure and then, in 1993, the first TR coronary stent placement via the radial artery.² Since then, the utilization of this technique has significantly grown worldwide.

Despite this growth, TRA is estimated to account for only 10% of percutaneous coronary interventions (PCI) worldwide.³ There are some areas in Canada and Europe that perform close to 95% of PCIs via the TR approach.³ In the United States, TRA is estimated to have grown from 1.3% in all PCI procedures in 2007 to slightly more than 10% in 2011.³ Its usage, however, is largely absent in the interventional radiology and vascular surgery communities. The brachial artery continues to be the most common upper extremity artery used for noncoronary interventions. Reasons for underutilization of TRA outside of the cardiac catheterization lab may include a lack of appropriate training, equip-

ment limitations such as inappropriate catheter length and shape, and the initial learning curve.

This article intends to describe the technique of TRA for noncoronary interventions, particularly hepatic embolization, and the issues surrounding its usage.

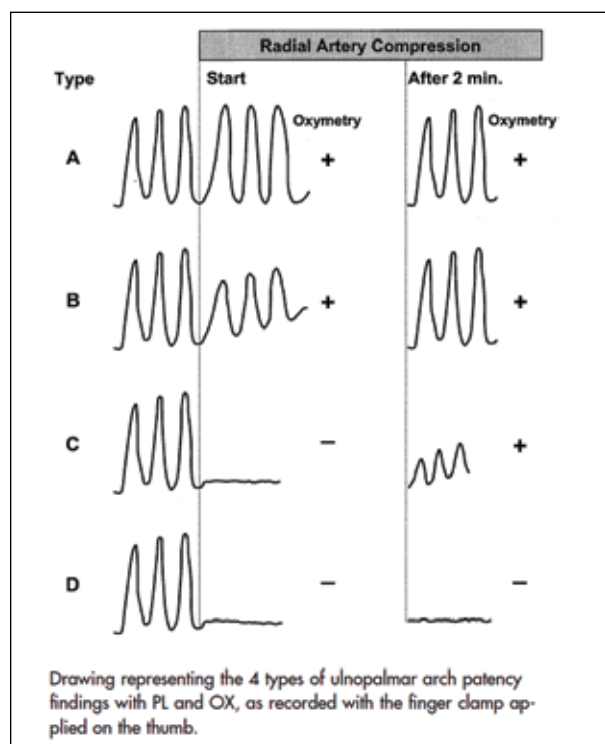


Figure 1. The Barbeau test. Reprinted with permission from the American Heart Association.⁴

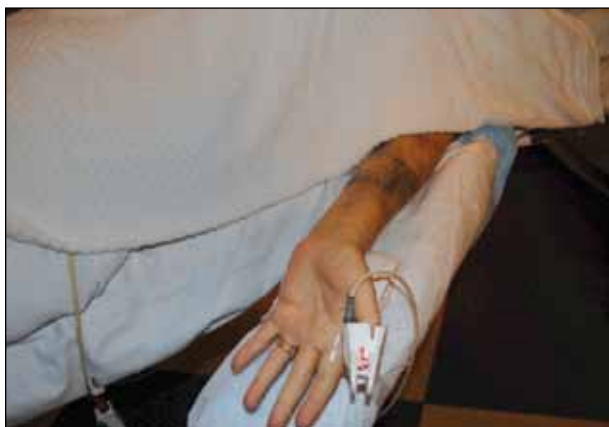

Figure 2. Arm positioned at an acute angle to the table for easier vessel access with ultrasound. Note the towel roll used to support the wrist.

ADVANTAGES OF THE TRANSRADIAL APPROACH

There are several obvious advantages of TRA over transfemoral access (TFA). First, the radial artery is more superficial than the femoral artery, and there are no surrounding structures that are susceptible to injury. In addition, inadvertent injury to the artery itself, such as dissection or thrombosis, is significantly less detrimental to the patient because of the dual blood supply to the hand.¹ The radial artery is also readily compressible, which has decreased the incidence of postprocedural bleeding complications during PCI and, in some studies, decreased cardiac mortality.⁵⁻⁷ Hemostasis can be achieved without the introduction of a foreign body, such as a vascular closure device, which is common practice in many interventional suites.

Patient comfort issues are also of paramount importance, especially in today's climate where patients have

many options in terms of choosing where they will be treated. After TRA, patients are able to ambulate immediately, sit up in bed, and are discharged home faster. In a randomized trial, Cooper et al demonstrated a strong patient preference, improved quality-of-life metrics, and decreased hospital costs for TRA over TFA during cardiac catheterization.⁸ The specific advantages of immediate ambulation and decreased incidence of back pain are of particular importance during hepatic embolization, especially in a patient population that is frequently nauseated and vomiting.

PATIENT SELECTION

As is the case with every procedure, patient selection is key. Although not every patient is ideally suited for TRA, many operators believe that close to 90% of patients can undergo TRA for PCI using a "radial first" approach. It still remains to be seen if this high percentage translates to the noncoronary space. It has become clear that the TR technique is associated with a steeper learning curve. When initially learning this technique, higher rates of femoral crossover are seen, particularly in patients with smaller-caliber radial arteries, anatomic variants, and aortic disease and tortuosity.³

In our practice, TRA is preferred in obese patients because of the inherent difficulty in locating the common femoral artery, as well as the difficulty in detecting and controlling postprocedure hemorrhage. In 2007, the TROP registry demonstrated that TRA significantly reduced vascular complications in obese patients.⁹ Patients who are deemed high risk for bleeding complications, such as those with thrombocytopenia, coagulation disorders, liver dysfunction, and those on anticoagulants, are also well suited for TRA. Advanced patient age is also considered a risk factor for bleeding complications.³ These patients often benefit from the

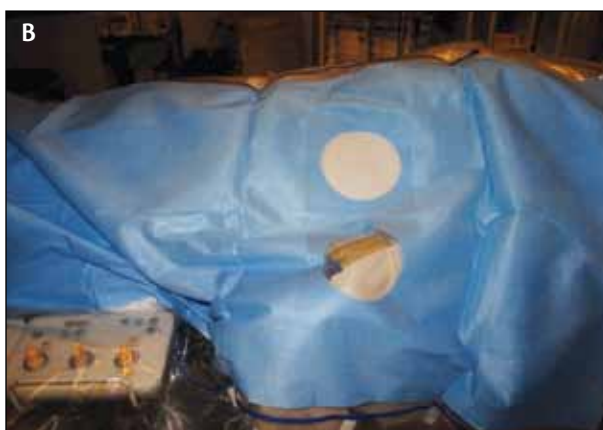
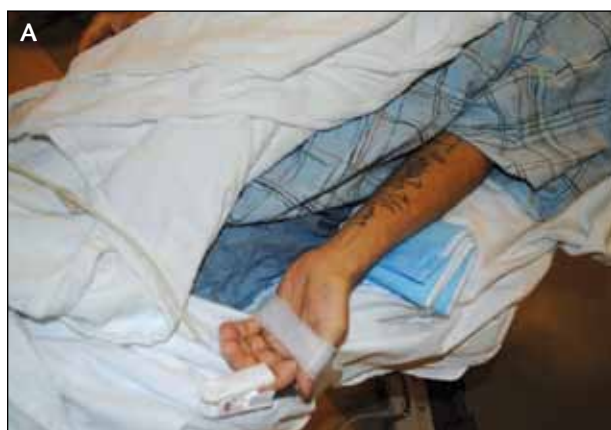
Figure 3. Arm positioned more parallel to the procedure table (A). The arm in parallel position to the table allows for more comfortable wire and catheter exchange; standard femoral drapes are used (B).

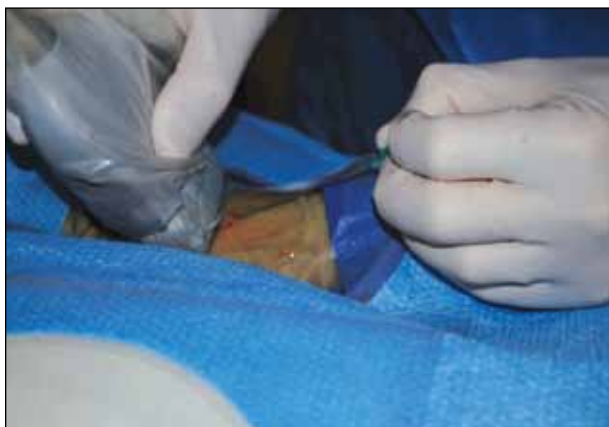

Figure 4. Ultrasound-guided access to the radial artery with a 21-gauge micropuncture needle.

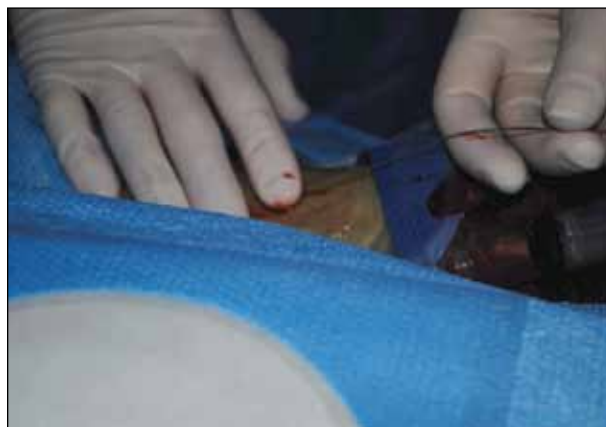


Figure 5. A 0.018-inch wire is used to cannulate the radial artery. Note the finger pressure over the access site as the sheath is placed over the wire.

TR approach; however, anatomic issues such as vascular tortuosity and atherosclerosis sometimes make these cases more technically challenging. Female sex has also been shown to be a risk factor for increased bleeding during PCI. In 2007, Pristipino et al demonstrated a significantly decreased risk of major and minor bleeding in women with TRA as compared to TFA.¹⁰ It should be noted, however, that women tend to have smaller radial arteries, which can present a technical challenge for TRA.

All patients being considered for TR catheterization undergo a modified Allen's test with a pulse oximeter, also known as the Barbeau test.⁴ A pulse oximeter is placed on the patient's thumb, the radial pulse is identified, and the waveform is analyzed. The radial artery is then compressed, and the pulse oximeter waveform is again analyzed for up to 2 minutes and graded. The four types of ulnopalmar patency include (A) no damping of the pulse tracing immediately after compression, (B) damping of pulse tracing, (C) loss of pulse tracing followed by recovery within 2 minutes, and (D) loss of pulse tracing without recovery within 2 minutes (Figure 1).⁴ Barbeau et al demonstrated that this technique is more sensitive than the Allen's test in determining suitable candidates for TRA by direct comparison in 1,010 patients.⁴ It was also shown that only 1.5% of patients were not suitable

for TRA (Barbeau type D). It is important to note that the Barbeau D waveform is the only true contraindication to TRA, as Barbeau types A through C confirm patency of the ulnopalmar arch. Other relative contraindications for TRA include small radial artery (< 3 mm) and patients with a dialysis fistula or those nearing dialysis who may depend on the radial artery for access.

HEPATIC EMBOLIZATION

Setup and Access

For interventional procedures below the diaphragm, the left radial artery accessed is preferred. There is a slightly shorter distance to the target vessel from the left wrist, which can be crucial given the current limitations of catheter lengths (discussed subsequently in detail). In addition, the guiding catheter or sheath is not positioned across the great vessels during the procedure, theoretically limiting the risk of cerebral emboli or thrombus formation.

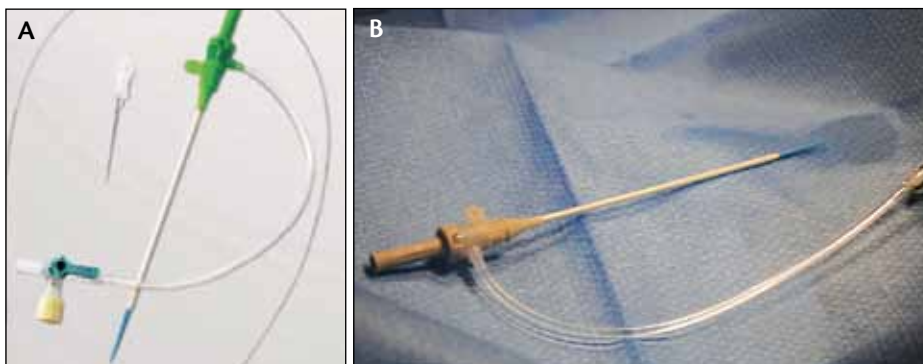


Figure 6. Hydrophilic access sheath for use in the radial artery (Glidesheath, Terumo Interventional Systems, Somerset, NJ).

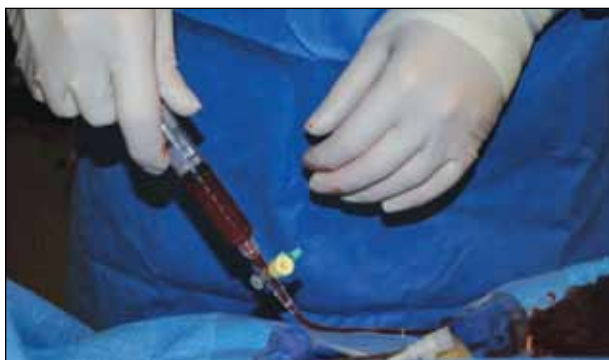

Figure 7. A medication cocktail is injected intra-arterially immediately after sheath placement. Nitrates, heparins, and calcium channel blockers are used. Note the use of hemodilution with blood during injection to decrease the pain associated with calcium channel blockers.

The arm can be positioned in several ways. One option is to position the arm at 75° to 90°, almost perpendicular to the table (Figure 2). This allows for easier access to the vessel but makes catheter exchanges somewhat awkward and cumbersome. We prefer to position the arm at the patient's side in a similar position to the patient's groin. This allows for catheters/wires to be positioned over the patient's draped body similar to TFA (Figure 3). Arm positioning boards can also be used, and there are several options available on the market today. The wrist should be slightly hyperextended, and a towel roll is used to support the wrist (Figure 2). Prone positioning has also been described, allowing the left radial artery to be accessed and positioned in a similar fashion as the right common femoral artery.¹¹ This technique can be used in patients with chronic back pain, who are unable to lie supine.

The pulse oximeter is always placed on the thumb or forefinger of the wrist being accessed. A small amount of lidocaine is administered locally for anesthesia. Our lab uses ultrasound-guided access and the Seldinger technique with a 21-gauge echogenic-tip needle (Figure 4). Other labs use the "angiocath technique." A small IV catheter is advanced through both walls of the radial artery under direct palpation and slowly pulled back until blood flow is seen. A 0.018-inch wire is advanced into the radial artery (Figure 5). If there is any resistance, the wire is pulled back and readjusted. If the wire cannot be advanced,

fluoroscopy and direct visualization with contrast is performed.

A specialized radial access sheath with a hydrophilic coating is then used. The dilators on these sheaths are tapered to 0.018 inch to allow for immediate sheath placement without an incision or wire exchange. The most common hydrophilic sheath used in our lab is the 10-cm-length Glidesheath (Terumo Interventional Systems, Somerset, NJ) (Figure 6). Other commonly used hydrophilic radial sheaths include Radialsource (Cordis Corporation, Bridgewater, NJ) and Adelante (Oscor Inc., Palm Harbor, FL). Rathore et al showed that the use of hydrophilic sheaths decreases the incidence of radial artery spasm and pain during TRA.¹² The majority of diagnostic and interventional procedures can be performed with 5- to 6-F sheaths; however, safe radial access can be performed with sheaths ranging in size from 4 to 7 F.

After sheath placement, a medication "cocktail" is administered intra-arterially directly through the access sheath. Nitrates, calcium channel blockers, and heparin are typically used to prevent arterial spasm and reduce vascular tone. Although there are numerous recommendations, there is no consensus on the ideal mixture. Our lab uses 3,000 units of heparin, 200 µg of nitroglycerin, and 2.5 mg of verapamil. It is important to note that verapamil causes a significant burning sensation upon injection, so continual hemodilution and slow injection is recommended (Figure 7).

Catheter Selection

In most cases, a 100-cm Cobra-shaped or JR 4 catheter and a standard 0.035-inch access wire are used to navigate the subclavian region and engage the descending aorta. The catheter is then "hubbed" in the sheath, and small aliquots of contrast are used as the catheter is pulled back to engage the superior mesenteric artery

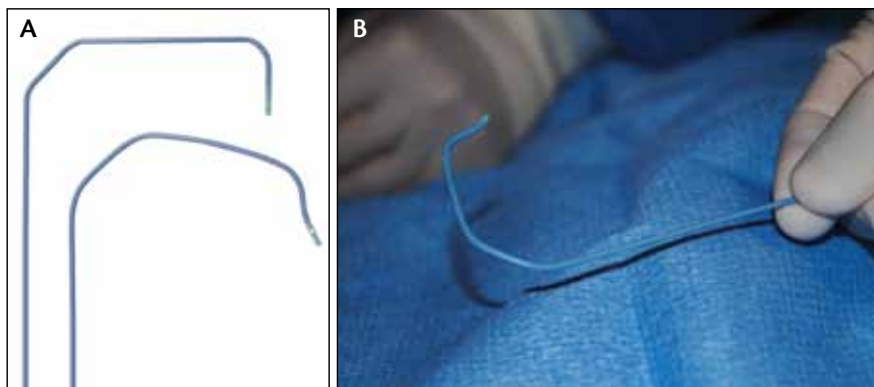


Figure 8. Jacky and TIG Optitorque catheters (Terumo Interventional Systems) (A) and the Sarah radial Optitorque catheter (Terumo Interventional Systems) (B).

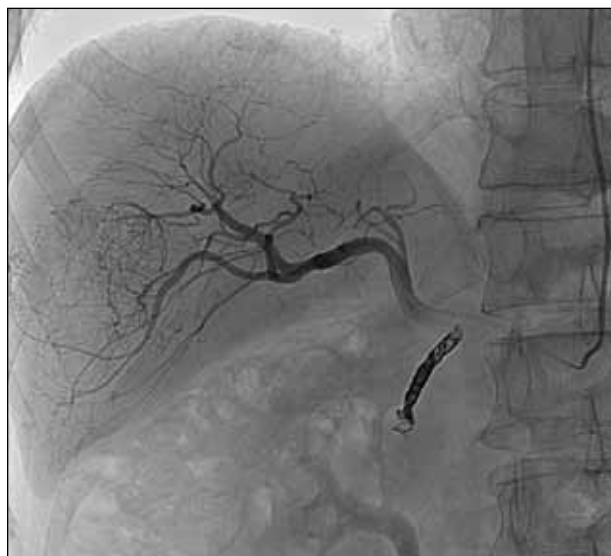

Figure 9. A 56-year-old man with hepatocellular carcinoma in the right hepatic lobe. Right hepatic artery angiography via left radial artery access before yttrium-90 infusion demonstrates marked tumor hypervascularity. Note the coils in the gastroduodenal artery from previous embolization.

and celiac artery. Other catheters that are commonly used for hepatic embolization include the Jacky Radial and Sarah Radial Optitorque catheters (Terumo Interventional Systems) (Figures 8 and 9). In addition to the unique shape of these catheters, they are available in 110-cm lengths, which make them very useful in taller patients where 100 cm is not adequate. One of the major limitations of TRA for hepatic embolization is the limited availability of unique shapes and lengths for engaging the mesenteric vessels. Efforts are currently underway to design new catheters for this purpose. For hepatic embolization procedures, standard-length microcatheters (130 and 150 cm) are then used to

select the appropriate hepatic artery for treatment purposes.

In our practice, TRA is most commonly used in transarterial chemoembolization (TACE) and transarterial radioembolization (TARE) in both the macroaggregated albumin mapping procedures and delivery of yttrium-90. TACE using TRA was first described in Japan in 2003.¹³ Shiozawa et al retrospectively compared 150 TACE patients who underwent TFA and 177 patients who underwent TRA. Of the 70 patients who received both approaches, 92.9% preferred TRA. Although unpublished, our data using the TRA approach currently suggest the same trend.

Imaging evaluation and intervention planning now include a complete vascular evaluation with CT angiography or magnetic resonance angiography of the hepatic vasculature. The angle of the access artery (celiac or superior mesenteric) to the aorta as well as the vascular tortuosity (iliac or aortic arch) is taken into account when planning TRA or TFA. Difficult access cases can be triaged to one technique based on the perceived difficulty of vascular access. For complex mesenteric and renal interventions, 5- and 6-F guide catheters are used for balloon angioplasty, intravascular ultrasound, and stent placement. The Launcher coronary guide catheter (Medtronic, Inc., Minneapolis, MN) and the Vista Brite Tip guiding catheter (Cordis Corporation) are most commonly used.

RADIAL ARTERY HEMOSTASIS

Nonocclusive “patent” hemostasis is a key technique in minimizing radial artery thrombosis postprocedure. The PROPHET study in 2008 demonstrated that this technique is superior to occlusive pressure in maintaining radial artery patency.¹⁴ This is typically performed using a wrist band device. There are several devices on the market today, which are listed in Table 1. The most common device used in our lab is the TR Band

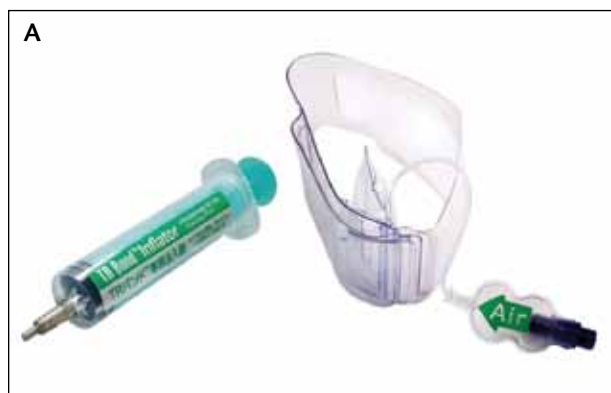

Figure 10. The TR Band (A) and the “patent” hemostasis technique (TR Band) (B).

(Terumo Interventional Systems) (Figure 10). A distal radial artery pulse should palpate during the hemostasis period, which ranges from 30 to 120 minutes, depending on the complexity of the procedure performed. After a typical TACE or TARE procedure utilizing a 5-F access sheath, the band is slowly deflated over 15 minutes after 100 minutes of patent hemostasis. If bleeding or “oozing” is seen from the puncture site during the removal process, the band is reinflated for 20 minutes, and the process is repeated. Once the band is successfully removed, the patient is observed for 30 minutes before discharge.

COMPLICATIONS

The most common, albeit rare, complication seen in our practice is a local hematoma with mild pain at the access site. This is often self-limited and can be treated with NSAIDs if necessary. Despite proper patient hemostasis technique, radial artery thrombosis will occur in a minority of cases, which are almost always asymptomatic.¹⁵ Factors associated with a decreased rate of radial artery occlusion include increased heparin dose, smaller sheath size, and use of a hydrophilic sheath.¹⁴ Other rare complications include radial artery pseudoaneurysm, perforation, radial arteritis, perforation, severe spasm, and dissection. Digital ischemia is exceedingly rare and is often described in the literature in patients who do not have a patent ulnopalmar arch.¹⁶

One concern when performing TRA instead of TFA is the theoretical risk of cerebral embolization related to arch manipulation. In addition, catheter placement from the left radial artery will lie across the left vertebral artery during hepatic embolization. Several studies have concluded that silent brain infarcts occur at rates as high as 15% to 22% after cardiac catheterization using TFA.¹⁷⁻¹⁹ Hamon et al performed diffusion-weighted magnetic resonance imaging on 41 consecutive patients after right-sided TRA and identified two procedure-related ischemic lesions (4.9%), both of which were asymptomatic.²⁰ This study concluded that TRA has a lower incidence of cerebral embolization compared to TFA when intervening on the coronary circulation based on previous studies published in the coronary literature. Anecdotally, the incidence of cerebral embolization when using the left radial approach for interventions below the diaphragm is extremely low. However, there is no published literature on this to date. In our single-center experience of more than 175 transradial hepatic interventions, there were no complications related to cerebral infarction (manuscript in preparation).

TABLE 1. RADIAL COMPRESSION DEVICES APPROVED IN THE UNITED STATES

Device Name	Company
Bengal Band	AccessClosure, Inc. (Mountain View, CA)
Hemoband	Hemoband Corporation (Portland, OR)
Air-Band	Maquet Cardiovascular LLC (Wayne, NJ)
Finale	Merit Medical Systems, Inc. (South Jordan, UT)
RadStat	Merit Medical Systems, Inc.
RadiStop	St. Jude Medical, Inc. (St. Paul, MN)
TR Band	Terumo Interventional Systems
R-Band	Vascular Solutions, Inc. (Minneapolis, MN)

PATIENT PREFERENCE AND COST EFFECTIVENESS

As more interventions move from the hospital setting into outpatient offices, improved patient comfort and faster discharge times are increasingly important. This is currently the trend in interventional oncology across the country. In our practice, transarterial radioembolization is performed solely on an outpatient basis, and TACE is performed with a 23-hour observation admission and trending toward a completely outpatient procedure. Procedure cost is also an extremely important issue as we move forward into the next phase of health care reform. Many studies have demonstrated decreased costs associated with TRA as compared to TFA.^{7,21,22} In hepatic embolization, TR procedure costs will generally be lower because of decreased utilization of closure devices and also from decreased readmission for bleeding complications. More work is being done in this area to prove this concept.

In our practice, patient preference overwhelmingly favors TRA over TFA for hepatic embolization procedures, mainly due to earlier ambulation and discharge times. We must pay attention to patient satisfaction as we build comprehensive interventional oncology practices. I believe TRA should be learned by busy operators so that we can offer this technique to our patients.

RADIAL ACCESS IN 2013: WHERE ARE WE HEADED?

Even inability to successfully access the radial artery does not preclude a patient from distal arm access. Many operators have used the ulnar artery as an alternative to the radial artery, especially if radial artery spasm or severe tortuosity is encountered or if the ulnar artery is dominant. Recently, de Andrade et al described their experience with transulnar access in a prospective registry of 410 patients, with a low access site complication rate of 3.9%.²³

Other potential applications for TRA in the future include renal artery denervation, uterine artery embolization, and carotid, iliac, and infrainguinal interventions. Several studies have already described some of these techniques.²⁴⁻²⁶ Cerebral angiography has been performed and described from the radial artery for more than a decade,^{27,28} including a large series of more than 1,000 patients in Korea in 2010.²⁹ More recently, complex cerebral interventions, including aneurysm coiling, have been performed using TRA.³⁰ Widespread adoption in the United States is currently limited by equipment available to successfully perform these cases.

CONCLUSION

Transradial intervention has broad applications for interventional radiology. In particular, hepatic embolization procedures are well suited for this approach. The time is now to learn this technique in order to offer comprehensive, cost efficient, and safe care for our patients. ■

Aaron M. Fischman, MD, is Assistant Professor of Radiology and Surgery, Division of Interventional Radiology, Icahn School of Medicine at Mount Sinai in New York, New York. He has disclosed that he is a consultant to Terumo Interventional Systems. Dr. Fischman may be reached at (212) 241-7409; aaron.fischman@mountsinai.org.

Rahul S. Patel, MD, is Assistant Professor of Radiology and Surgery, Division of Interventional Radiology, Icahn School of Medicine at Mount Sinai in New York, New York. He has disclosed that he is a consultant to Arstasis and Sirtex Medical Ltd.

- Campeau L. Percutaneous radial artery approach for coronary angiography. *Cathet Cardiovasc Diagn.* 1989;16:3-7.
- Kiemeneij F, Laarman GJ. Percutaneous transradial artery approach for coronary stent implantation. *Cathet Cardiovasc Diagn.* 1993;30:173-178.
- Frangos C, Nobel S. How to transform you into a radialist: literature review. *Cardiovasc Medicine.* 2011;14:277-282.
- Bertrand OF, Belisle P, Joyal D, et al. Comparison of transradial and femoral approaches for percutaneous coronary interventions: a systematic review and hierarchical Bayesian meta-analysis. *American Heart J.* 2012;163:632-648.
- Romagnoli E, Biondi-Zoccai G, Sciahbasi A, et al. Radial versus femoral randomized investigation in ST-segment elevation acute coronary syndrome: the RIFLE-STEACS (Radial Versus Femoral Randomized Investiga-

- tion in ST-Elevation Acute Coronary Syndrome) study. *J Am Coll Cardiol.* 2012;60:2481-2489.
- Mehta SR, Jolly SS, Cairns J, et al. Effects of radial versus femoral artery access in patients with acute coronary syndromes with or without ST-segment elevation. *J Am Coll Cardiol.* 2012;60:2490-2499.
- Cooper CJ, El-Shiekh RA, Cohen DJ, et al. Effect of transradial access on quality of life and cost of cardiac catheterization: a randomized comparison. *Am Heart J.* 1999;138(3 Pt 1):7.
- Benamer H, Louvard Y, Sanmartin M, et al. A multicentre comparison of transradial and transfemoral approaches for coronary angiography and PTCA in obese patients: the TROP registry. *EuroIntervention.* 2007;3:327-332.
- Pristipino C, Pelliccia F, Granatelli A, et al. Comparison of access-related bleeding complications in women versus men undergoing percutaneous coronary catheterization using the Radial Versus Femoral Artery. *Am J Cardiol.* 2007;99:16-21.
- Barbeau GR, Arseneault F, Dugas L, et al. Evaluation of the ulnopalmar arterial arches with pulse oximetry and plethysmography: comparison with the Allen's test in 1010 patients. *Am Heart J.* 2004;147:489-493.
- Kwon SW, Cha JJ, Rhee JH. Prone position coronary angiography due to intractable back pain: another merit of transradial approach compared to transfemoral approach. *J Invasive Cardiol.* 2012;24:605-607.
- Rathore S, Stables RH, Pauriah M, et al. Impact of length and hydrophilic coating of the introducer sheath on radial artery spasm during transradial coronary intervention: a randomized study. *JACC: Cardiovasc Interv.* 2010;3:475-483.
- Shiozawa S, Tsuchiya A, Endo S, et al. Transradial approach for transcatheter arterial chemoembolization in patients with hepatocellular carcinoma: comparison with conventional transfemoral approach. *J Clin Gastroenterol.* 2003;37:412-417.
- Pancholy S, Coppola J, Patel T, Roke-Thomas M. Prevention of radial artery occlusion-patient hemostasis evaluation trial (PROPHET study): a randomized comparison of traditional versus patency documented hemostasis after transradial catheterization. *Cathet Cardiovasc Interv.* 2008;72:335-340.
- Pancholy SB, Patel TM. Effect of duration of hemostatic compression on radial artery occlusion after transradial access. *Cathet Cardiovasc Interv.* 2012;79:78-81.
- de Bucourt M, Teichgraber U. Digital ischemia and consecutive amputation after emergency transradial cardiac catheter examination. *Cardiovasc Interv Radiol.* 2012;35:1242-1244.
- Omran H, Schmidt H, Hackenbroch M, et al. Silent and apparent cerebral embolism after retrograde catheterisation of the aortic valve in valvular stenosis: a prospective, randomised study. *Lancet.* 2003;361:1241-1246.
- Büsing KA, Schulte-Sasse C, Flüchter S, et al. Cerebral infarction: incidence and risk factors after diagnostic and interventional cardiac catheterization—prospective evaluation at diffusion-weighted MR imaging. *Radiology.* 2005;235:177-183.
- Lund C, Nes RB, Ugelstad TP, et al. Cerebral emboli during left heart catheterization may cause acute brain injury. *Eur Heart J.* 2005;26:1269-1275.
- Hamon M, Gomes S, Clergeau MR, et al. Risk of acute brain injury related to cerebral microembolism during cardiac catheterization performed by right upper limb arterial access. *Stroke.* 2007;38:2176-2179.
- Corvoisier PL, Gellen B, Lesault PF, et al. Ambulatory transradial percutaneous coronary intervention: a safe, effective and cost-saving strategy. *Catheter Cardiovasc Interv.* 2013;81:15-23.
- Mitchell MD, Hong JA, Lee BY, et al. Systematic review and cost-benefit analysis of radial artery access for coronary angiography and intervention. *Circ Cardiovasc Qual Outcomes.* 2012;5:454-462.
- de Andrade PB, Tebet MA, Nogueira EF, et al. Transulnar approach as an alternative access site for coronary invasive procedures after transradial approach failure. *Am Heart J.* 2012;164:462-467.
- Mendiz OA, Sampaioles AH, Londero HF, et al. Initial experience with transradial access for carotid artery stenting. *Vasc Endovasc Surg.* 2011;45:499-503.
- Cortese B, Peretti E, Troisi N, et al. Transradial percutaneous iliac intervention, a feasible alternative to the transfemoral route. *Cardiovasc Revasc Med.* 2012;13:331-334.
- Trani C, Tommasino A, Burzotta F. Pushing the limits forward: transradial superficial femoral artery stenting. *Cathet Cardiovasc Interv.* 2010;76:1065-1071.
- Levy EI, Boulos AS, Fessler RD, et al. Transradial cerebral angiography: an alternative route. *Neurosurgery.* 2002;51:335-332.
- Nohara AM, Kallmes DF. Transradial cerebral angiography: technique and outcomes. *AJNR Am J Neuroradiol.* 2003;24:1247-1250.
- Ko JW, Park SM, Kim SD, et al. Is transradial cerebral angiography feasible and safe? A single-center's experience. *J Korean Neurosurg Soc.* 2010;47:332-337.
- Lawson MF, Velat GJ, Fargen KM, et al. Direct radial artery access with the 070 neuron guide catheter for aneurysm coiling: a novel application of the neuron catheter for cerebral interventions. *Neurosurgery.* 2012;71(2 Suppl Operative):E329-E334; discussion E334.