

Endovascular Options for Splenic Artery Aneurysms

There are multiple technical considerations for endoluminal exclusion of splenic artery aneurysms; treatment options are dictated by anatomy and patient characteristics.

**BY HICHAM T. ABADA, MD; PATRIZIO CAPASSO, MD, DSc;
AND JAFAR GOLZARIAN, MD**

The prevalence of splenic artery aneurysms (SAAs) ranges from 0.1% to 2%.^{1,2} Although SAAs are considered rare, they remain the most common (50%–75%) among all visceral aneurysms. A predominance among women is found with a ratio of 4:1.³ The increased use of cross-sectional imaging has shown incidental findings of SAAs in asymptomatic patients. In acute settings, patients who present with ruptured or symptomatic SAAs, are exposed to a life-threatening condition with hemodynamic collapse and high mortality.

Even if there is no clear evidence-based data regarding the cut-off size for treating SAAs, the currently accepted threshold for the treatment of asymptomatic patients is an aneurysmal diameter in excess of 2 cm. Additional factors that may warrant intervention include childbearing women, portal hypertension, cirrhosis, and patients requiring liver transplantation.

Pregnant women with splenic artery (SA) rupture are exposed to a high mortality rate of 70% to 90%. The critical period for pregnant women is in the last trimester, particularly during labor. A distinction is made between true SAAs and pseudoaneurysms. A true aneurysm is often associated with hormonal changes and increased flow, which is the case when physiologic modifications occur during pregnancy. On the other hand, pseudoaneurysms occur with damage to the

Endovascular management of SAAs has gained widespread acceptance because of its high technical success rates.

arterial wall following trauma or with exposure to proteolytic enzymes as observed with pancreatitis.⁴

As previously mentioned, there is an absence of convincing evidence predicting the risk of SAA rupture. Size is not clearly associated with risk of rupture in pseudoaneurysms as demonstrated by Tessier et al, who state that such a risk is present for aneurysms as small as 0.3 cm and as large as 17 cm. Therefore, they recommend the systematic treatment of all visceral pseudoaneurysms.⁵

ENDOVASCULAR OPTIONS

Endovascular management of SAAs has gained widespread acceptance, essentially because of its high technical success rates along with its significant improvements in morbidity and mortality compared to open surgical repair. Technical considerations for endoluminal exclusion of SAAs are multiple. The use of different occlusive agents has been described in published litera-

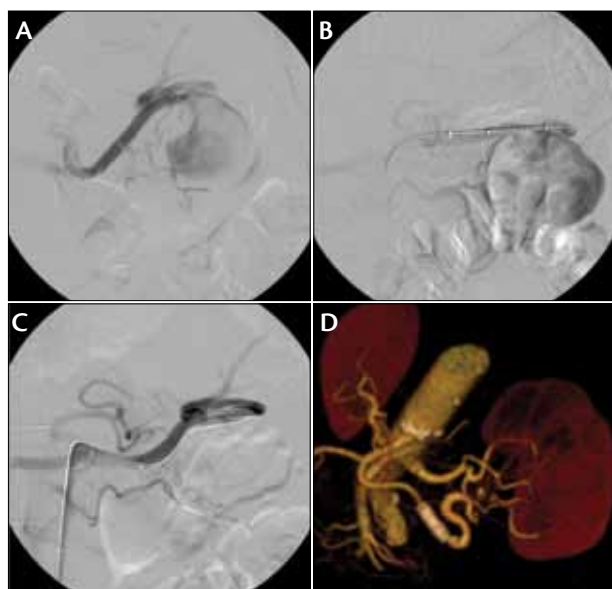


Figure 1. A 58-year-old man with a large SAA. Selective angiography of the SA showing the aneurysmal sac (A). Angiography through the sheath postpositioning of the stent graft and before deployment (B). Stent graft implantation to exclude the aneurysm (C). Computed tomographic angiography with volume-rendering technique at 3 months posttreatment (D).

ture, including coils, bare stents, n-butyl cyanoacrylate (n-BCA), the Amplatzer vascular plug (St. Jude Medical, Inc., St. Paul, MN), and covered stents. Any attempt to treat an SAA should consider the presence of the collateral pathways that can induce backbleeding and also whether the SA needs to maintain patency or not.

Aneurysm Exclusion Via Total Occlusion of the SA Without Parent Artery Flow

Embolization of the SA could be performed when preservation of the native artery is not required. Occlusive agents such as coils, n-BCA, or Onyx (Covidien, Mansfield, MA) may be considered. The goal is to achieve complete occlusion of the vessel beyond the aneurysmal neck first and then proximal to the lesion to avoid backbleeding into the lesions through gastroepiploic, pancreatic, or gastric collaterals. This is the so-called sandwich technique. Dense packing of the coils is often necessary for rapid, complete embolization in a high-flow system. The use of a coaxial system and microcatheters is preferable, especially in the case of very tortuous vessels or when a distal splenic branch is involved.

The Amplatzer vascular plug consists of an expandable nitinol mesh and can be used to proximally

occlude the SA. This device comes with a delivery wire attached to a stainless steel screw that is unlocked to release the plug when its positioning is deemed optimal. This device may allow for faster embolization compared with the deployment of the large number of coils needed to obtain complete stasis in a high-flow system. The use of a guiding catheter can be difficult for catheterization of tortuous vessels and may therefore prevent the use of this device in such anatomy. However, the control of the delivery system and the possibility of recapture provide a lower risk for nontargeted embolization.⁶

SA Exclusion While Maintaining Parent Artery Flow

Covered stents. SAA exclusion with preservation of the parent artery is possible using covered stents (Figure 1). The primary limiting factor of this approach is the tortuosity of the SA, which can prevent the progression of the guiding catheter or the guiding sheath to a suitable level of deployment. However, recent developments in coronary artery stent grafts with low profiles offer new possibilities if the diameter of the SA is adequate. In addition to the preservation of parent vessel patency, exclusion of the SAA with a stent graft has the benefit of decreasing computed tomographic artifacts, which are more prominent with platinum coils or n-BCA with radiopaque agents.

Bare stents, coils, and combined occlusive agents.

Prior to the development of covered stents, one way to preserve the parent artery was to coil the aneurysm itself. Implantation of a bare stent could be performed before or after the coiling procedure to protect the parent vessel and help to maintain its patency. Tulsyan et al used similar techniques to treat visceral aneurysms in which a combination of n-BCA and coils was used before stent placement.⁷ The development of newer stents with high metallic coverage is also being considered for the exclusion of aneurysmal sacs, as will be described later in this article.

Aneurysm coiling. Classic transcatheter coil embolization with dense packing of the aneurysmal sac is another option that is used to maintain native circulation. The use of detachable coils allows a more precise deployment. Ikeda et al used this approach to treat 22 visceral aneurysms, and a high success rate was achieved in SAAs.⁸ However, they also described the risk of coil migration when using a similar technique for the treatment of renal artery aneurysms. This approach is suitable for patients with saccular aneurysms that have a narrow neck in which coil deployment limited

to the sac is feasible, with a low risk of coil dislodgment. These can also be treated using liquid occlusive agents such as n-BCA or Onyx.

Ethyl vinyl alcohol copolymer (Onyx) has now become popular for off-label use in peripheral interventions. This is essentially related to its ability to offer better control of the embolization session, allowing longer injection rates due to its nonadhesive properties.

Percutaneous approach. In cases of difficult vascular access to the SA, whether it is related to its size, location, or vascular anatomy preventing an endovascular approach, one can consider accessing the aneurysmal sac directly through a percutaneous approach. This can be performed either under computed tomographic or ultrasonographic guidance. The aneurysm can then be occluded with coils, thrombin, n-BCA, or Onyx. Complications such as parent vessel thrombosis and distal embolization along with recanalization of the lesion has also been reported.⁹

NEW TECHNOLOGY

A self-expanding bare stent (Cardatis multilayer stent [Cardatis, Isnes, Belgium]) has been approved in Europe in recent years for the treatment of aneurysms

in the central nervous system and peripheral vessels. It is made of phynox, and its design consists of a three-dimensional braided tube made of two interconnected layers. The multilayer configuration along with the three-dimensional geometry confers a decrease in velocity within the aneurysmal sac while maintaining laminar flow in the main artery and surrounding branches. Recently, Balderi et al reported a case of hepatic artery aneurysm treatment using this stent. One can therefore surmise that visceral aneurysms, including SAAs, will be treated with such a device because a wide range of diameters is available, from 5 to 20 mm, and from 30 to 120 mm in length.¹⁰

CONCLUSION

There are multiple endovascular approaches for the treatment of splenic aneurysms. It has become a reliable procedure with high technical success and low periprocedural morbidity. Treatment options are dictated by the anatomic location, the age of the patient, and the physiologic and clinical conditions. ■

Hicham T. Abada, MD, is Associate Professor of Radiology, Section of Vascular & Interventional Radiology, University of Kentucky in Lexington, Kentucky. He has disclosed that he has no financial interests related to this article.

Patrizio Capasso, MD, DSc, is Professor of Radiology and Surgery, and Vice Chair of Research, University of Kentucky in Lexington, Kentucky. He has disclosed that he has no financial interests related to this article.

Jafar Golzarian, MD, is Professor of Radiology and Surgery, and Director of the Division of Interventional Radiology & Vascular Imaging, University of Minnesota in Minneapolis, Minnesota. He has disclosed that he has no financial interests related to this article. Dr. Golzarian maybe reached at (612) 625-5147; golzarian@umn.edu.

1. Stanley JC, Wakefeld TW, Graham LM et al. Clinical importance and management of splanchnic aneurysms. *J Vasc Surg.* 1986;3:836-840.
2. Carr SC, Pearce WH, Vogelzang RL, et al. Current management of visceral artery aneurysms. *Surgery.* 1996;120:627-633.
3. Berceci SA. Hepatic and splenic artery aneurysms. *Semin Vasc Surg.* 2005;18:196-201.
4. Sugg SL, Gerndt SG, Hamilton BJ, et al. Pseudoaneurysms of the intraparenchymal splenic artery after blunt abdominal trauma: a complication of nonoperative therapy and its management. *J Trauma.* 1995;39:593-595.
5. Tessier DJ, Stone WM, Fowl RJ, et al. Clinical features and management of splenic artery pseudoaneurysms: case series and cumulative review of the literature. *J Vasc Surg.* 2003;38:969-974.
6. Zhu X, Tam MD, Pierce G, et al. Utility of the Amplatzer vascular plug in splenic artery embolization: comparison in conventional coil technique. *Cardiovasc Intervent Radiol.* 2011;34:522-531.
7. Tulsyan N, Kashyap VS, Greenberg KR, et al. The endovascular management of visceral artery aneurysms and pseudoaneurysms. *J Vasc Surg.* 2007;45:276-283.
8. Ikeda O, Tamura Y, Nakasone Y, et al. Nonoperative management of unruptured visceral artery aneurysms: treatment by transcatheter coil embolization. *J Vasc Surg.* 2008;47:1212-1219.
9. Pezzullo JA, Dupuy DE, Cronan JJ. Percutaneous injection of thrombin for the treatment of pseudoaneurysms after catheterization: an alternative to sonographically guided compression. *AJR Am J Roentgenol.* 2000;175:1035-1040.
10. Balderi A, Antonietti A, Pedrazzini F, et al. Treatment of hepatic artery aneurysm by endovascular exclusion using the multilayer cardatis stent. *Cardiovasc Intervent Radiol.* 2010;33:1282-1286.