

Managing Aortic Pseudoaneurysm Caused by Metastatic Choriocarcinoma

A case in which a custom-made graft is used to successfully treat an unusual aortic defect.

BY BIBOMBE P. MWIPATAYI, MMED (SURG), FCS (SA), CERT VASC SURG (SA), FRACS;
SHANNON THOMAS, BMEDSc (HONS), MBBS (HONS); SARAH NORTON, MBBS;
AND VIKRAM VIJAYAN, MBChB, MRCS, FRCS

The indications for endovascular aneurysm repair have been extended since first described by Parodi and colleagues.¹ Although initially designed for simple infrarenal aortic aneurysm repair, the development of bifurcated, modular, and custom-made grafts has extended the use of this technology to allow inclusion of different and challenging aortic anatomies and pathologies, including aortoiliac aneurysms, internal iliac aneurysms, as well as emergent ruptured aneurysms and aortoenteric fistulas.²⁻⁵

Aortic pseudoaneurysm resulting from infiltrating metastatic choriocarcinoma is a relatively rare entity, with a reported incidence of three cases in the literature in which these patients were mainly managed surgically.⁶⁻⁸

We report an unusual case of a patient with aortic pseudoaneurysm secondary to metastatic choriocarcinoma, in which the aortic defect was managed with a custom-made aortic graft.

CASE REPORT

A 25-year-old man presented to the emergency department with 4 weeks of lower right back pain. On suspicion of ureteric colic, a computed tomography (CT) scan was performed and showed large enhancing necrotic mass lesions in the retroperitoneum with compression of the inferior vena cava and right-sided hydronephrosis. A testicular lump was palpated. Scrotal ultrasound showed a complex cystic mass measuring 6 mm in diameter within the right testicle and bilateral testicular microlithiasis. CT-guided lymph node biopsy

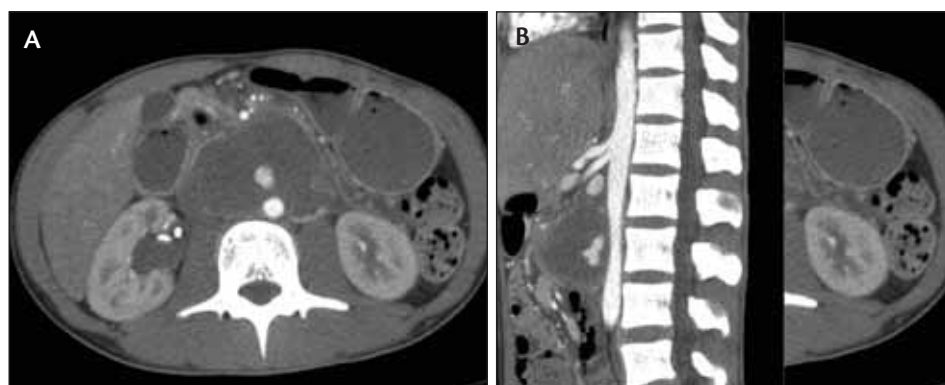


Figure 1. Axial slice (A) and sagittal slice (B) of a preoperative CT angiogram taken of the patient with aortic pseudoaneurysm secondary to choriocarcinoma. Contrast extravasation into the tumor mass from the aorta is demonstrated on arterial phase imaging.

of the retroperitoneal mass in the right iliac fossa was performed where histopathological examination showed choriocarcinoma, with no demonstration in the sample of other germ cell types. Before establishing chemotherapy, the patient was taken to the endovascular suite where a ureteric JJ stent (Boston Scientific Corporation, Natick, MA) was placed in the obstructed ureter. Chemotherapy (cisplatin and etoposide) was started, and the patient was found to be severely neutropenic. Because serial CT scan and ultrasound determined that the lesion was stable, he was kept in the ward until there was an improvement in his blood cells. However, the patient's course was complicated by respiratory failure with chest and abdominal pain.

This prompted a CT scan and ultrasound examination of the chest and abdomen. Cannonball metastases to the lungs were evident. The large retroperitoneal necrotic mass (5.9 X 8.9 cm) in the abdomen was stable in size, but an anterior aortic defect was demonstrated with contrast extravasation into the retroperitoneal tumor mass. The communication measured 6 to 8 mm in diameter and was situated approximately 30 mm below the renal arteries. The inferior mesenteric artery originated 18 mm distal to the communication. The distal aorta and common iliac arteries appeared smooth walled and free from tortuosity. The proximal landing zone aortic diameter was 15.2 mm, and the distal landing zone diameter was 15.6 mm. The external iliac arteries appeared smooth walled, free from any tortuosity, and measured 7 to 8 mm in diameter (Figure 1). An ultrasound performed at the time demonstrated a pseudoaneurysm with a wide neck.

The patient was initially assessed for open surgical repair. He was noted to have responded well to resuscitative measures and was hemodynamically stable. He concurrently had a pancytopenia with profound neutropenia on blood laboratory examination secondary to his chemotherapy. Despite widespread metastases, the patient was given a good prognosis by the oncological medical team. It was therefore believed that the patient should be managed expectantly, and an endovascular graft was planned to manage the aortic injury when the patient was medically fit for intervention.

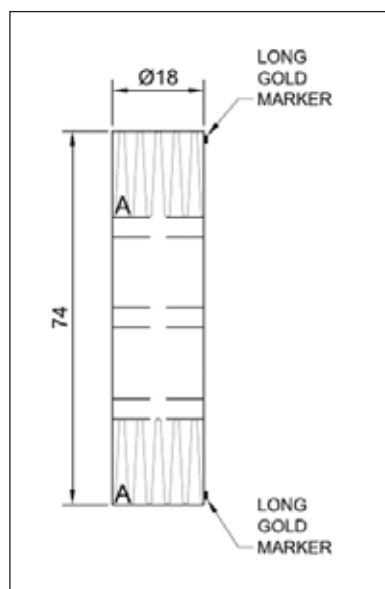


Figure 2. A custom-made tube graft (Cook Medical). This is an 18-mm-diameter tube graft with a length of 74 mm, planned to land immediately below the renal arteries with vessel coverage to the distal aorta.

PROCEDURAL DETAILS

A custom-made graft was developed in conjunction with Cook Medical (Brisbane, Australia) based on the basic Zenith Flex system. This consisted of a stainless steel stent tube graft with fabric made from woven Dacron. The graft was sized to seal in the infrarenal aorta proximally and above the aortic bifurcation distally. No suprarenal fixation or barbs were employed in the device, with the graft to be delivered via an 18-F introducer system that has an outer diameter (OD) of 7.1 mm (21.5 F) (Figure 2).

Although an open approach was considered, due to the availability of a hybrid endovascular suite and the patient's preference, the procedure was performed via percutaneous access with complete exclusion of the false aneurysm (Figure 3). Unfortunately, the right common femoral artery was occluded on the final angiogram, and it was believed

that the vessel had dissected due to the size of the delivery device. Given the patient's young age, the decision was made to repair this dissection via open vein patch angioplasty, where vein was harvested from the left arm.

Postoperatively, the patient recovered well with no complications. He recommenced chemotherapy 1 week postoperatively and was later discharged home. At 4-month follow-up, a CT scan showed that there was no evidence of contrast extravasations and that the stent graft was in satisfactory position. The tumor had decreased in size and vascularity (Figure 4).

DISCUSSION

Choriocarcinoma of testicular origin is one of many subtypes of germ cell tumors that, although being rare (occurring in 1% to 2% of all malignancies affecting males), are the most common malignancy affecting males aged 15 to 35.⁹

Pure choriocarcinoma is the rarest form of testicular tumor, with (in order of frequency) seminoma, embryonic tumor, teratocarcinoma, and teratoma being more common. Choriocarcinoma metastasizes early via hematogenous routes to the brain, lungs, and liver and usually presents via clinical manifestations of metastatic disease. The testicular primary tumor in such cases may

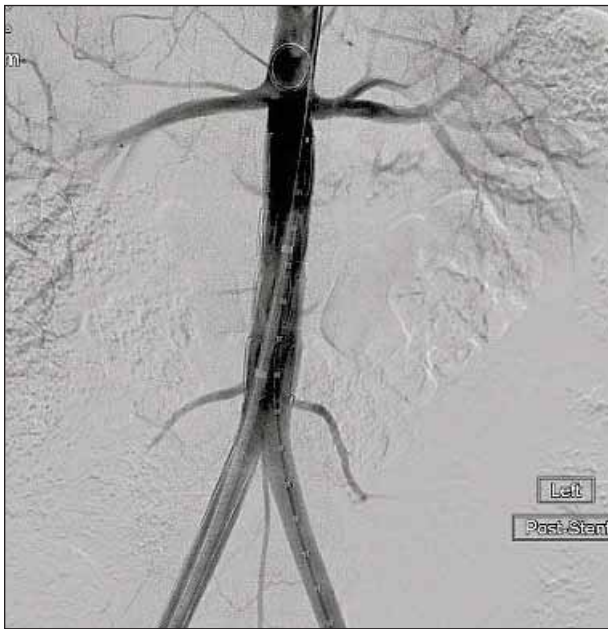


Figure 3. Completion angiogram demonstrating in situ endoluminal graft with no endoleak or contrast extravasation outside the graft in the infrarenal aorta.

be small and “burned-out.” Most germ cell tumors respond well to radiotherapy and cisplatin-based chemotherapy. Surgery for pure choriocarcinoma is limited to radical orchiectomy for tissue diagnosis.¹⁰ Degenerative changes of the vessel wall or secondary erosion by the adjacent tumor into the aorta are believed to represent the mechanism of pseudoaneurysm formation.¹¹

The literature generally reports that malignant tumors cause life-threatening bleeding that may occur via aortoenteric fistula formation.⁶ Pseudoaneurysm formation is a rare presentation of neoplastic invasion of the aorta¹² in relation to aortic injury.

Hansen and colleagues describe endovascular repair of an aortoenteric fistula caused by choriocarcinoma presenting with life-threatening hemorrhage. Although initially technically successful, the patient later died from aortic bleeding secondary to further necrosis and deterioration of the aortic wall.⁶ Open surgical approaches described for aortic invasion

include en bloc resection of the aorta with replacement with Dacron graft.¹³

Treatment options for the aortic defect in our patient included conservative management, open surgery, and endovascular surgery. Conservative management was initially chosen to allow for improvement in the patient’s general medical condition, where it was believed the risk associated with an intervention in a patient with pancytopenia would have outweighed the benefits of aneurysm exclusion. Open surgery was considered for the patient; however, the retroperitoneal tumor was believed to be too extensive with disease noted deep in the pelvis, as well as encasing the pancreas, superior mesenteric artery, and inferior vena cava. Complete margin-free tumor resection would not have been possible, and dissection of the tumor off the aorta would have been difficult and not without risk.

The use of a balloon-expandable stent was also considered, but the angiographic impression that the balloon gives as it inflates with the proximal and distal ends, known as the “dog bone effect,”¹⁴ was considered a problem in this patient, because the uncovered expanding balloon could damage the already friable aorta and create further problems. This could lead to further disruption of the aortic wall and/or a possible complete aortic rupture. Endovascular treatment was deemed challenging.

In making our decision regarding therapy, we noted case reports by Hansen et al⁶ and Yang et al,¹⁵ which demonstrated that a malignant process causing a defect in the aortic wall may not only cause wall degeneration at the site of pseudoaneurysm or aortoenteric fistula but that a larger surrounding segment of the aortic wall may be affected by the degenerative/invasive process. For this reason, simple coiling and injection of the defect was not felt to be a viable methodology to give

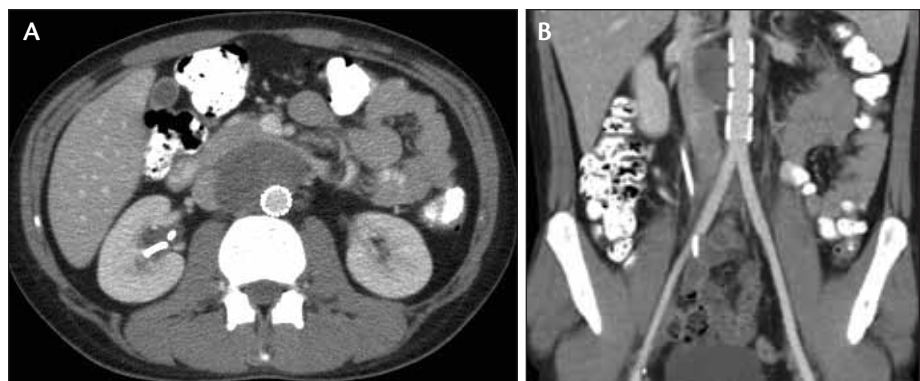


Figure 4. Axial slice (A) and coronal slice (B) of a postoperative CT angiogram. There is complete exclusion of the false aneurysm and satisfactory position of the stent graft with reduction in size and vascularity of the surrounding tumor.

the patient long-term protection from further aortic degeneration (particularly in light of ongoing chemotherapy and expected tumor necrosis). Although a balloon-expandable stent would also allow coverage of a large area of aorta, it was felt that the risk of dog-boning the presumed friable aorta was too great; although the aortic diameter did look normal, it was considered that it was weakened by the tumor. It was important that ballooning should be strictly inside the stent to avoid further damage of the aortic wall. The stent used was depleted of any hooks to avoid any catastrophic complication. Because of the dimensions of the nonaneurysmal aorta, an "off-the-shelf" graft would have been difficult to deploy. Also, it was believed that suprarenal fixation was not necessary and that barbs may have caused further injury to the already friable aorta. For these reasons, a custom-made graft was designed that was essentially a simple Dacron tube stent graft without barbs or suprarenal fixation.

The dissection of the common femoral artery was felt to occur due to the large size of the delivery device and relatively small artery, despite appearing as an acceptable diameter on initial imaging. This problem would have been overcome via design of a smaller delivery device; however, such design may be limited by the use of stainless steel stents.

Finally, completion angiography revealed complete exclusion of the pseudoaneurysm from the circulation with no evidence of endoleak. As per our protocol for monitoring patients after endoluminal repair of abdominal aortic aneurysm, the patient will have clinical and radiological review (CT scan or duplex ultrasound) on an annual basis to look for the presence of endoleak, as well as the development of a new pseudoaneurysm. This will be particularly important because the tumor necroses with chemotherapeutic treatment.

CONCLUSION

Malignancy resulting in aortic pseudoaneurysm is rare and presents a difficult management problem for the surgeon. We have presented a case of successful endoluminal management of an aortic defect resulting from malignant invasion and degeneration of the aortic wall. The use of a custom-made graft allowed for exclusion of the diseased aorta and preservation of distal blood supply with minimal morbidity to the patient. ■

Bibombe P. Mwipatayi, MMed (Surg), FCS (SA), Cert Vasc Surg (SA), FRACS, is an endovascular surgeon with the Department of Vascular Surgery at Royal Perth Hospital, Professor of Surgery at the School of Surgery, and Faculty of Medicine, Dentistry, and Health Sciences at the

University of Western Australia in Perth, Australia. He has disclosed that he holds no financial interest in any product or manufacturer mentioned herein. Dr. Mwipatayi may be reached at +61-8-9224 0228; bibombe@iinet.net.au.

Shannon Thomas, BMedSc (Hons), MBBS (Hons), is a vascular fellow with the Department of Vascular Surgery at Royal Perth Hospital in Perth, Australia. Dr. Thomas has disclosed that he holds no financial interest in any product or manufacturer mentioned herein.

Sarah Norton, MBBS, is a resident with the Department of Vascular Surgery at Royal Perth Hospital in Perth, Australia. Dr. Norton has disclosed that she holds no financial interest in any product or manufacturer mentioned herein.

Vikram Vijayan, MBChB, MRCS, FRCS, is a senior vascular fellow with the Department of Vascular Surgery at Royal Perth Hospital in Perth, Australia. Dr. Vijayan has disclosed that he holds no financial interest in any product or manufacturer mentioned herein.

1. Parodi JC, Palmaz JC, Barone HD. Transfemoral intraluminal graft implantation for abdominal aortic aneurysms. *Ann Vasc Surg.* 1991;5:491-499.
2. Greenberg RK, West K, Plaff K, et al. Beyond the aortic bifurcation: branched endovascular grafts for thoracoabdominal and aortoiliac aneurysms. *J Vasc Surg.* 2006;43:879-886; discussion 886-887.
3. Tielliu IF, Bos WT, Zeebregts CJ, et al. The role of branched endografts in preserving internal iliac arteries. *J Cardiovasc Surg (Torino).* 2009;50:213-218.
4. Verhoeven EL, Tielliu IF, Bos WT, et al. Present and future of branched stent grafts in thoraco-abdominal aortic aneurysm repair: a single-centre experience. *Eur J Vasc Endovasc Surg.* 2009;38:155-161.
5. Veith FJ, Lachat M, Mayer D, et al. Collected world and single center experience with endovascular treatment of ruptured abdominal aortic aneurysms. *Ann Surg.* 2009;250:818-824.
6. Hansen KS, Sholey RC. Aortoenteric fistula in advanced germ cell tumor: a rare lethal complication. *J Urol.* 2002;167:2131.
7. Kelly R, Skinner D, Yellin AE, et al. En bloc aortic resection for bulky metastatic germ cell tumors. *J Urol.* 1995;153:1849-1851.
8. Napolitano L, D'Auliero A, Gargano E, et al. Clinical study of aortic co-involvement in lumbosacral lymph node metastasis of testicular carcinoma. *G Chir.* 2003;24:231-234.
9. Mostofi FK, Sesterhenn IA. Anatomy and pathology of testis cancer. In: Vogelzang N, ed. *Comprehensive Textbook of Genitourinary Oncology.* Baltimore, MD: Williams and Wilkins; 1996: 956-958.
10. Ramón y Cajal S, Piñango L, Barat A, et al. Metastatic pure choriocarcinoma of the testis in an elderly man. *J Urol.* 1987;137:516-519.
11. Smith BL, Munschauer CE, Diamond N, et al. Ruptured internal carotid aneurysm resulting from neurofibromatosis: treatment with intraluminal stent graft. *J Vasc Surg.* 2000;32:824-828.
12. Sueyoshi E, Sakamoto I, Nakashima K, et al. Visceral and peripheral arterial pseudoaneurysms. *AJR Am J Roentgenol.* 2005;185:741-749.
13. Kelly R, Skinner D, Yellin AE, et al. En bloc aortic resection for bulky metastatic germ cell tumors. *J Urol.* 1995;153:1849-1851.
14. Hehrlein C, Devries J, Arab A, et al. Role of the "Dogbone" effect of balloon-expandable stents: quantitative coronary analysis of DUET and NIR stent implantation introducing a novel indexing system. *J Invasive Cardiol.* 2002;14:59-65.
15. Yang DM, Yoon MH, Kim HS, et al. Interrenal pseudoaneurysms complicating renal choriocarcinoma metastases: treatment with coil embolization. *Clin Imaging.* 2000;24:217-220.