

A New CTO Algorithm With the BeBack Crossing Catheter

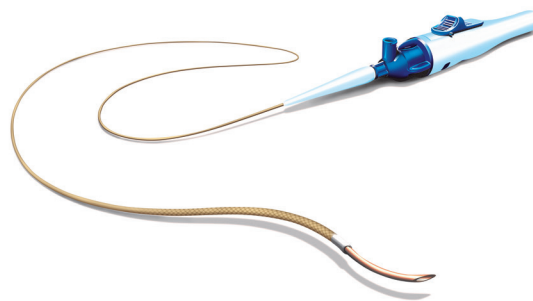
A literature review and conversation with a clinician experienced in the technology highlight the utility of the BeBack catheter for CTO in patients with chronic limb-threatening ischemia.

With Daniel Raskin, MD

Crossing a chronic total occlusion (CTO) lesion is challenging. Although there are a few other re-entry devices on the market currently, the BeBack crossing catheter (Bentley InnoMed GmbH, Hechingen, Germany) is unique in that it can act as a support catheter, has a low profile for crossing possibilities, and provides re-entry options. The BeBack catheter is versatile and can be used in multiple approaches: antegrade, retrograde, and cross-over. The BeBack catheter is available globally, including the United States, where the device is 510(k) cleared.

This article reviews a recent retrospective study that analyzed the use of the BeBack catheter for patients with arterial CTO and chronic limb-threatening ischemia (CLTI). The study found that the BeBack catheter results in high procedural success with a low rate

of complications. Then, one of the study's authors, Dr. Daniel Raskin, talks about the study's results, the role of the BeBack catheter in his CTO treatment algorithm, and advice on using the catheter.



Single-Center, Retrospective Review Evaluates BeBack Catheter for CTO Recanalization in CLTI Patients

In a single-center, retrospective study of CLTI patients undergoing catheterization for CTOs, Cohen et al found that use of the BeBack catheter had high procedural success and a low rate of complications. The study was published online in *Journal of Endovascular Therapy*.¹

The initial evaluation (May 2018-December 2022) included a total of 1,184 patients aged >18 years with peripheral artery disease who underwent limb recanalization or attempted recanalization due to CLTI. After excluding cases that did not use the BeBack catheter, the study analysis was conducted on 72 patients who underwent 78 procedures (77.8% male; mean age, 75.6 years).

The *Journal of Endovascular Therapy* article outlined the technical procedure undergone in the study as follows:

KEY FINDINGS

- High rates of procedural and technical success (92.3%) were demonstrated among 72 patients undergoing 78 procedures with the BeBack catheter.
- Mean ABI improved from 0.59 preprocedure to 0.95 postprocedure.
- A low rate of complications was observed, with 5.1% major amputations and 3.8% mortality at 30 days.

- All patients underwent preprocedural diagnostic CTA and access site was selected. Contralateral femoral access was used in 48.7% of procedures, ipsilateral femoral in 29.5%, and retrograde via anterior tibial artery as primary single access in 21.8%.
- Intravenous heparin was administered to achieve an activated clotting time of 250 to 300 seconds.
- Sheath selection was made based on the access approach.
- Intra-arterial vasodilators were not used.
- Either luminal or subintimal recanalization was attempted with a 3-F support catheter and 0.018-inch guidewire.
- A BeBack catheter was used if conventional methods did not succeed at crossing or reentering the true lumen. The BeBack catheter was used to attempt over-the-wire crossing into the subintimal space or towards the distal part of the occlusion. The needle was deployed and the guidewire advanced into the postocclusion true lumen, and the BeBack catheter was removed.
- Percutaneous transluminal angioplasty (PTA) was routinely performed, and control angiography was used to evaluate vascular patency, with self-expanding stents placed as needed.

Technical success was defined as CTO recanalization via occlusion crossing or subintimal re-entry with the BeBack catheter, as well as arterial patency on completion angiography. Procedural success was defined as arterial recanalization with < 30% residual stenosis and ≥ 0.2 improvement in ankle-brachial index (ABI) after 24 hours.

Most (67/72, 93%) patients underwent one procedure, with four (5.6%) undergoing two procedures and one (1.4%) undergoing three. The majority of patients were classified as Rutherford class 6. During the 78 procedures, the BeBack catheter was used 85 times: in 62.5% of procedures for subintimal dissection and re-entry and in 34.1% of procedures for intraluminal crossing of the CTO. Occluded segments were most often in the femoral artery, followed by the popliteal artery. Median occlusion length was 201 mm (IQR, 284-285 mm), and all lesions were TASC II D.

Procedural and technical success was achieved in 92.3% of cases (72/78 procedures) and was attributed

to the ability of the BeBack catheter to directly cross the occlusion or indirectly cross through subintimal re-entry. Mean ABI improved from 0.59 preprocedure to 0.95 postprocedure.

In the three instances where attempts to advance a catheter were unsuccessful due to calcification, the retractable needle of the 4-F BeBack catheter was used to debulk the lesion and allow the balloon to cross.

Overall, complications were low. Intraprocedural acute thrombosis was noted in five procedures, which were all successfully treated with an aspiration catheter. Intraoperative bleeding was not observed at any point. Postprocedure, access site hematoma was found in four patients, as was pseudoaneurysm. By 30-day follow-up, two patients required reintervention in the treated limb, one underwent above-knee amputation, three underwent below-knee amputation, five required minor amputation, and three were deceased.

The retrospective design, single-center setting, and absence of a control group were observed by Cohen et al as limitations, as they limit the generalizability of the study. A prospective controlled trial that compares the available crossing and re-entry catheters is needed.


CONCLUSION

The BeBack catheter offers several key advantages for endovascular treatment: (1) the 4-F catheter can track over a 0.018-inch guidewire, providing excellent support compared to standard 0.014-inch guidewires; (2) the 4-F catheter can navigate to various sites; and (3) the BeBack catheter has a retractable needle that can be used for debulking and precision/control or retracted to act as a crossing device.

As demonstrated in this single-center experience, the BeBack catheter provides an alternative option for recanalization of occluded segments in patients with CLTI, with high procedural success and low complication rates. During this study, only the 4-F BeBack catheter was available. In addition to the 4-F size, Bentley also provides an even lower profile catheter in size 2.9-F.

1. Cohen I, Raskin D, Barash Y, et al. Performance of BeBack crossing catheter in chronic total occlusion in patients with chronic limb-threatening ischemia: a single-center experience. *J Endovasc Ther*. Published online October 17, 2023. doi: 10.1177/15266028231204264

Incorporating the BeBack Catheter Into Your Daily Practice



Daniel Raskin, MD

Division of Diagnostic Imaging
Sheba Medical Center
Tel HaShomer, Israel
Affiliated to Faculty of Medicine
Tel Aviv University
Tel Aviv, Israel
raskind@gmail.com
Disclosures: None.

How would you describe your approach before you began using the BeBack catheter? What was the role of re-entry devices in your practice at that time?

Before the BeBack catheter, our approach was very much dependent on our guide wires or catheters. We only used re-entry catheters as a bailout approach when stuck subintimally.

What was your impetus for incorporating this device into your armamentarium?

When the BeBack catheter came to market, I was very interested to see how this device could improve my practice. We all know how difficult it can be to recanalize a tough lesion or get stuck at a hard calcification. Our success rate was already good with the specialty catheters, wires, and our own skills, but this does not mean there was no room for improvement. With the BeBack catheter, we hoped we could lower complications like dissections and speed up procedure time when we needed to recanalize a lesion. Because this multipurpose device replaced a support, crossing, and re-entry catheter all in one, it was a no-brainer to include it in our armamentarium.

Can you tell us about your rationale for embarking on this study? Why was this re-entry and crossing device the right choice for these patients?

The application of the BeBack catheter as a go-to re-entry device meant we could decrease the amount of wire and catheter attempts and use only the device. But also, the BeBack catheter has a needle tip that can be used to shatter intraluminal hard calcifications and assist in passing a wire over that occlusion. From the earliest use, we noticed a few benefits: In comparison to similar devices available, the BeBack catheter crosses acute aortic bifurcations without effort. Also, it is conveniently

applied via tibial access, and if done correctly, it could be used in steps when the intraluminal occlusion is long.

How has your algorithm for managing CTO changed as a result of your experience in this study?

Since our first publication in 2022 assessing the technical success of the BeBack catheter,¹ we have used it sooner rather than later in the procedure. This means less chance of uncontrolled dissection, as well as less time invested in the wire and catheter method. We have learned to spot the lesions in which it would be better to apply the device early on.

In what situations do you use BeBack as a crossing catheter, and what features can be useful in these instances?

The BeBack catheter is useful in a variety of situations, depending on the lesion. I can access a lesion from antegrade access, via crossover, and, last but not least, through a pedal access set for a retrograde approach with the 2.9-F variant.

The BeBack catheter has the lowest profile, so I can easily use it as a support catheter to cross the lesion or give support to my wire. This is the only device on the market with an adjustable needle length that can be rotated 360° at the catheter tip. In an occluded vessel, the needle can be steered in a controlled manner through the lesion, with the possibility to stay intraluminal. With this feature, I can choose sharp recanalizations with the slightly straight 3-mm needle but can use my 7- or 11-mm needle length if I need to get back intraluminal from subintimal.

What has been your experience using this catheter in soft plaque and when there's a need to stay intraluminal while crossing?

In this situation, the device gives me the opportunity to be more careful than I could be with only a wire finding its way. With the BeBack catheter, I can choose to stay intraluminal and attempt to not create dissections, which is sometimes tricky in these lesions.

Your single-center experience had a high procedural and technical success rate (92.3%)—how was BeBack a contributor to this success rate?

We are a reference center in our area for endovascular treatment of CLTI patients, and as such, we have gained a lot of experience with advanced endovascular equipment for treatment. During the last year, we conducted

approximately 900 procedures and used the BeBack catheter on 82 occasions. We are stubborn in our dedication to succeed. The benefit of the BeBack catheter is that it is a multipurpose tool, and when the operator learns the best timing for its application, the procedural success rises accordingly.

What are your thoughts on using a re-entry and crossing catheter as a standard device when you encounter difficulty passing a wire?

For us, this is the go-to device not only for re-entry and lesion crossing but also in hard, calcified lesions where the wire is advanced but no other equipment can be advanced.

What is your advice regarding when to involve a BeBack catheter when planning a procedure? How much time do you allow yourself with conventional techniques before using a BeBack crossing catheter?

It is important to keep the BeBack catheter in mind when approaching a potentially difficult lesion or when it seems that the re-entry would not be achieved easily or at a desired location. In order to cross a lesion or return into the lumen, you need the relevant tool. I think the most important factor is time spent in the attempt—at some point, you stop and try something different.

Did the specific catheter choice speed up procedure time?

Saving time during a procedure is indeed very valuable for not only me as a physician but also for the patient. This can reduce radiation exposure, limit contrast, and control the total cost of the procedure.

During tough CTO recanalizations, do you think operators often start with other options like BeBack too late to successfully conclude the case safely? If so, what is the solution to this?

We are very used to our own methods of working. Integration of dedicated devices like this sometimes requires a paradigm shift, which subsequently benefits the overall outcome. We prefer the wire and catheter technique because it suffices most of the time, and no other tool is required. Having said that, I always advise to not linger when it comes to BeBack application. When additional assistance is required, it's a great tool to be used earlier rather than later.

What are the biggest advantages of this kind of catheter?

The biggest advantage is that this is a universal multipurpose device, meaning it is a crossing, re-entry, and debulking device. Moreover, the variability of the needle angulation and adjustable protrusion lengths allows for application of the device as a steering catheter.

How would you describe BeBack to a colleague in a few words?

It truly is a multipurpose game-changer! ■

Acknowledgments: BeBack procedures were conducted with and under the leadership of Boris Khaitovich, MD, Head of Interventional Radiology at Sheba Medical Center.

For further information please contact us at info_us@bentley.global.

1. Raskin D, Silverberg D, Halak M, et al. Technical success of the GoBack™ crossing catheter in chronic total occlusion in patients with chronic limb threatening ischemia. *Cardiovasc Intervent Radiol*. 2022;45:641-645. doi: 10.1007/s00270-021-03033-7



Scan to view the introduction video to the BeBack crossing catheter.