

# Wide-Necked Cerebral Artery Aneurysms: Where Do We Stand?

The evolution and progression of neurointerventional treatments for morphologically challenging aneurysms.

**BY MATTHEW J. MCPHEETERS, MD, MBA; KUNAL VAKHARIA, MD; STEPHAN A. MUNICH, MD; AND ADNAN H. SIDDIQUI, MD, PhD**

Since Guglielmi et al first published data on the use of detachable platinum coils to occlude intracranial aneurysms through an endovascular approach,<sup>1</sup> neurointerventionalists have worked to develop techniques and devices that allow endovascular treatment to become the standard of care for ruptured and unruptured intracranial aneurysms. Despite 2 decades of advancements, the treatment of wide-necked aneurysms still remains a technical challenge.

Most wide-necked aneurysms can be categorized into two general categories: sidewall and bifurcation. Sidewall aneurysms occur at locations where there is no associated branch vessel (eg, cavernous carotid artery) or where the branch vessel is of significantly smaller caliber than the parent vessel (eg, ophthalmic artery, superior hypophyseal artery, posterior communicating artery). Bifurcation aneurysms occur at locations where both branches are of nearly equal size. Proximally, bifurcation aneurysms include the basilar apex and internal carotid artery terminus; distally, they include the anterior communicating artery and middle cerebral artery bifurcation.

Early reviews of aneurysms treated with coil embolization noted two recurring factors limiting the effectiveness of this approach: neck size and dome-to-neck ratio.<sup>2,3</sup> In a morphologic study of 63 aneurysms treated with coil embolization, neck size  $\leq 4$  mm at the time of embolization was the only factor associated with successful embolization (defined as residual  $< 2$  mm

on follow-up angiography).<sup>2</sup> These data were later expanded on in the ATENA study, which was a morphologic study of 694 unruptured aneurysms treated endovascularly, in which the investigators found that a dome-to-neck aspect ratio of  $< 1.5$  was associated with a decreased rate of successful coil embolization.<sup>4</sup>

Neurointerventionalists continue to develop techniques focused on treating wide-necked aneurysms, which vary in effectiveness based on the type and location of the aneurysm. Initial techniques focused on the use of intraluminal devices such as balloons and stents to support intrasaccular embolization of the aneurysm. Although these techniques remain in use, the addition of intraluminal flow-diverting devices created a paradigm shift that has been augmented by several novel devices specifically designed for the endovascular treatment of wide-necked aneurysms. Clip ligation remains an option for morphologically difficult cerebral aneurysms, but the well-trained neurointerventionalist's armamentarium contains numerous tools and techniques for the treatment of a wide variety of wide-necked aneurysms (Table 1).

## INITIAL INNOVATIONS: INTRALUMINAL-SUPPORTED EMBOLIZATION

### Balloon-Assisted Coiling

One of the earliest endovascular solutions for the treatment of wide-necked intracranial aneurysms was balloon-assisted coiling (BAC). This technique was first

TABLE 1. ENDOVASCULAR TECHNIQUES AND DEVICES FOR THE TREATMENT OF WIDE-NECKED ANEURYSMS

	Sidewall Aneurysm Indication	Bifurcation Aneurysm Indication	
		Proximal	Distal
Techniques			
Balloon-assisted coiling	Yes	Yes	Yes
Stent-assisted coiling	Yes	Yes	Yes
Liquid embolic agents	Yes	Yes	Yes
Flow diverters			
Pipeline Flex (Medtronic)	Approved	No	No
Silk (Balt Extrusion)	Approved	No	No
Surpass Streamline (Stryker Neurovascular)	Approved	No	No
p64 (phenox GmbH)	Under investigation	No	No
Novel devices			
PulseRider (Cerenovus)	No	Approved	Under investigation
pCONUS (phenox GmbH)	No	Under investigation	Under investigation
pCANVAS (phenox GmbH)	No	Under investigation	Under investigation
Woven EndoBridge (MicroVention Terumo)	No	Under investigation	Under investigation
eClips (Evasc Neurovascular Enterprises ULC)	No	Under investigation	Under investigation
Honeycomb microporous covered stent	Under investigation	Under investigation	Under investigation
Comaneci (Rapid Medical)	Under investigation	No	No

established by Moret et al, with treatment achieved for 52 aneurysms in 50 patients, resulting in complete angiographic occlusion in 40 of 52 (77%) cases, subtotal occlusion in nine (17%) cases, and incomplete occlusion in three (6%) cases.<sup>5</sup> In a follow-up to the initial

study, Moret et al described a two-catheter remodeling technique in which one catheter was placed within the aneurysm sac while a second catheter was used to place an intraluminal balloon across the neck of the aneurysm that, when inflated, prevented the coils from

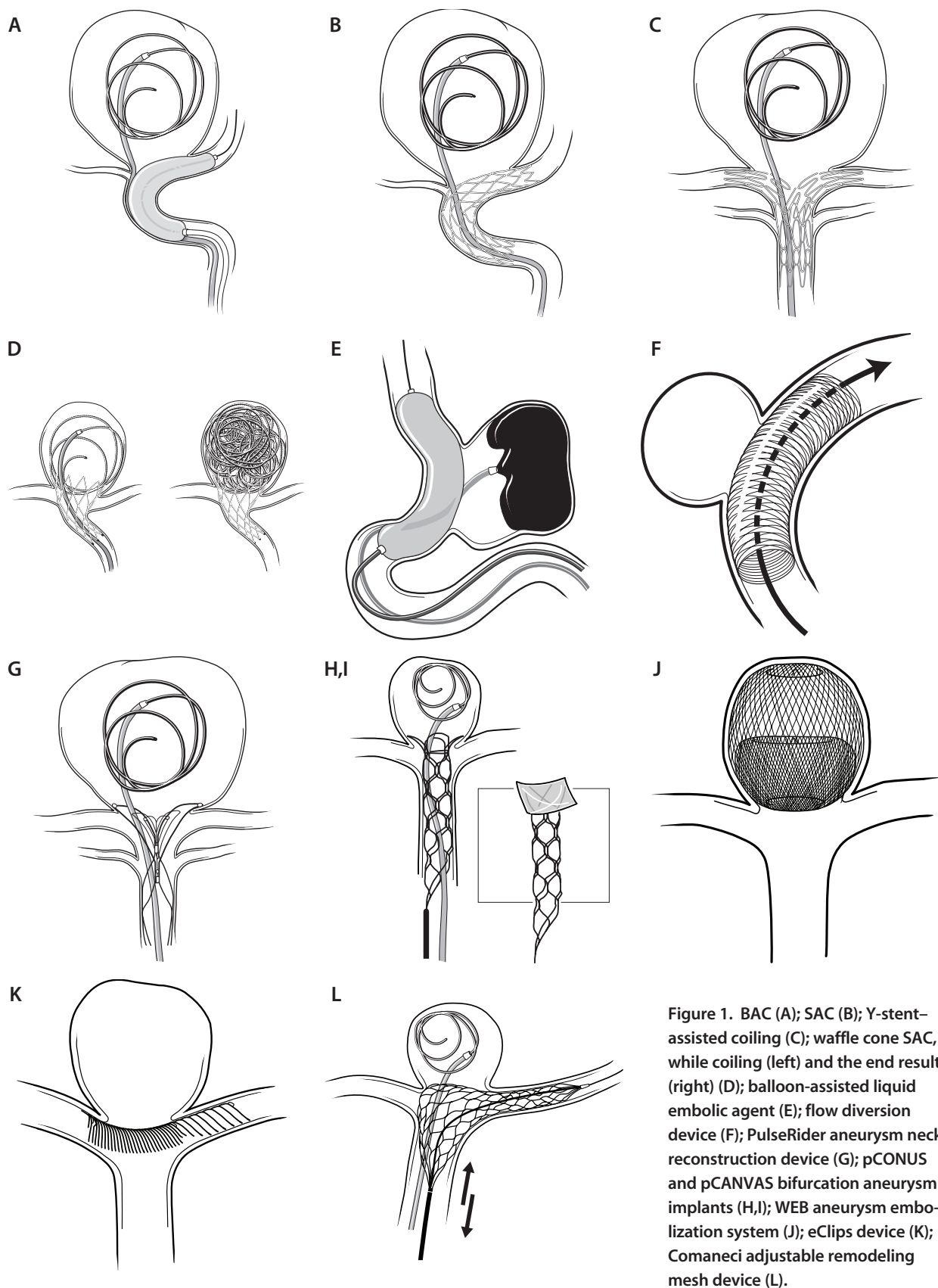


Figure 1. BAC (A); SAC (B); Y-stent-assisted coiling (C); waffle cone SAC, while coiling (left) and the end result (right) (D); balloon-assisted liquid embolic agent (E); flow diversion device (F); PulseRider aneurysm neck reconstruction device (G); pCONUS and pCANVAS bifurcation aneurysm implants (H,I); WEB aneurysm embolization system (J); eClips device (K); Comaneci adjustable remodeling mesh device (L).

herniating into the parent vessel during deployment (Figure 1A).<sup>6</sup> A large meta-analysis that included 23 studies comparing 273 aneurysms treated with BAC and 867 treated with standard coil embolization concluded that BAC was safe and was not associated with an increased rate of thromboembolic events or iatrogenic aneurysm rupture.<sup>7</sup> BAC is an effective treatment for sidewall aneurysms; however, the irregular intraluminal morphology of bifurcation aneurysms limits the effectiveness of BAC.

BAC is generally accepted as a safe method for the treatment of wide-necked aneurysms, but this does not mean it is without risk. A large single-center study comparing coil embolization alone and BAC found a significantly higher rate of serious procedural complications (death or dependency) in BAC (14.1% vs 3.0% with coil embolization;  $P < .0001$ ).<sup>8</sup> It is important to note that the aneurysms in the BAC group were significantly larger than those in the coil embolization group.<sup>8</sup> One of the major risks of the BAC technique is the need for temporary occlusion of the parent vessel while the balloon is inflated, and this may preclude BAC as an endovascular option in individuals with limited collateral cerebral blood flow. In addition, occluding the parent vessel warrants heparinization with supratherapeutic activated coagulation times close to 300 seconds and careful monitoring of occlusion times. BAC also carries a risk of coil herniation into the parent vessel when the balloon is deflated, although this is uncommon.

### Stent-Assisted Coiling

In an effort to eliminate the need for temporary parent vessel occlusion, the stent-assisted coiling (SAC) technique was developed. Similar to BAC, SAC uses a two-catheter system. One catheter is placed within the aneurysm sac while the other is used to deliver a stent across the aneurysm neck to hold the detachable coils in place (Figure 1B). The first reported SAC was performed by Mericle et al for a dissecting pseudoaneurysm of the petrous internal carotid artery.<sup>9</sup> At that time, neurointerventionalists were largely using balloon-mounted coronary stents. The first nitinol self-expanding intracranial stent, deployed through a standard microcatheter, for use with SAC was approved by the FDA in 2002.<sup>10</sup> Subsequently, many additional devices were developed, all of which served the same general purpose. Fargen et al published one of the first long-term, multicenter studies on SAC outcomes and demonstrated that 81% of aneurysms achieved  $\geq 90\%$  occlusion, including 59% that achieved 100% occlusion.<sup>11</sup> Although occlusion rates are higher with SAC than BAC, SAC has been associated with a higher rate

of morbidity and mortality (9.2%) than coil embolization alone.<sup>11</sup>

The technique for SAC is highly effective for sidewall aneurysms but presents many challenges for the treatment of bifurcation aneurysms. When using this technique in a bifurcation aneurysm, the neurointerventionalist must choose which branch vessel to place the stent across, leaving the second branch vessel unprotected, which increases the risk of coil herniation. To avoid this potential complication, the Y-stent and waffle-cone techniques were developed to improve the effectiveness of SAC in bifurcation aneurysms. The Y-stent technique, first described by Chow et al, involves placing one stent into one branch vessel followed by a second stent through the tines of the first stent into the branch parent vessel (Figure 1C).<sup>12</sup> The waffle-cone technique, described by Horowitz et al, involves using a stent with a flared end.<sup>13</sup> The distal, flared end of the stent is placed within the aneurysm sac with the proximal end in the parent vessel. The coils are then deployed through the stent (Figure 1D). The technique is referred to as the waffle-cone technique due to the resemblance of the final stent/coil configuration to an ice cream cone.<sup>13</sup>

The development of self-expanding SAC eliminated the need for transient luminal occlusion. Nevertheless, the implantation of a stent requires the prolonged use of dual antiplatelet therapy to prevent acute stent thrombosis or postprocedural thromboembolic complications. This increases the risk of periprocedural intracranial or systemic hemorrhage and presents a challenge, especially for the management of ruptured intracranial aneurysms.

### Liquid Embolic Agents

Balloon-assisted injection of liquid embolic agents serves as a third intraluminal-supported technique for the treatment of wide-necked aneurysms. Similar to both BAC and SAC, this technique uses a two-catheter system with balloon assistance; however, dimethyl sulfoxide-compatible catheters and balloons are required, and the aneurysm sac is embolized with a liquid agent (eg, Onyx, Medtronic) instead of a metallic coil (Figure 1E). The CAMEO trial, which investigated the treatment of 100 aneurysms with the Onyx liquid embolic system, found that occlusion rates were similar to those seen for BAC and SAC, with 79% complete occlusion, 13% subtotal occlusion, and 8% incomplete occlusion at 12 months. However, the rate of serious adverse events was significantly higher at 26.8%.<sup>14</sup> Due to the high complication rate, this technique failed to gain traction in the United States, but it remains in practice in other countries.

## A NEW BEGINNING: FLOW DIVERSION

FDA approval of the first flow-diverting stent for the treatment of cerebral aneurysms in 2011 marked a significant change in the conceptual understanding of how wide-necked and larger or giant aneurysms can be treated.<sup>15</sup> Up until that time, the fundamental premise of endovascular aneurysm treatment was direct intrasaccular embolization and immediate protection. Flow-diverting devices challenge this premise by providing an intraluminal device that results in delayed aneurysm occlusion. Flow diverters are finely woven mesh stents that exert their effect by two primary mechanisms: (1) by diverting flow away from the aneurysm sac, allowing for thrombosis of the aneurysm, and (2) by endothelialization of the parent vessel wall.

Compared with traditional intracranial stents, flow diverters have a significantly lower porosity and therefore more metal coverage. For example, the Pipeline Flex embolization device (Medtronic) has approximately 30% metal coverage, whereas traditional intracranial self-expanding stents only have 5% to 16%.<sup>16,17</sup> This property allows flow diversion through the stent, resulting in stasis within the aneurysm sac and subsequent thrombosis of the aneurysm dome (Figure 1F). In addition to diverting flow, over time, the parent vessel that the flow diverter is placed in will incorporate the device into its walls through a process known as endothelialization,<sup>18</sup> which is essential for complete aneurysm occlusion.

Since the approval of these devices, the results of various studies have proven their safety and efficacy as a therapeutic alternative to traditional intrasaccular embolization. The ASPIRE study, a prospective multicenter registry of unruptured aneurysms treated with the Pipeline Flex embolization device, reported a complete occlusion rate of 75% and a 6.8% rate of morbidity and mortality at 8 months.<sup>19</sup> The PREMIER study recently resulted in the FDA expanding indications for Pipeline Flex to all wide-necked aneurysms in the internal carotid artery up to the terminal segment. Flow diverters are a promising addition to the neuro-interventionalist's toolbox, although the associated mechanism of delayed aneurysm occlusion and need for dual antiplatelet therapy use limit their application in ruptured settings.

## NOVEL DEVICES FOR THE TREATMENT OF WIDE-NECKED ANEURYSMS

Since the development of flow diverters, several additional novel devices have been introduced specifically for the treatment of wide-necked aneurysms. Although not an exhaustive list, the following discussion provides

a sample of promising new devices recently approved or under investigation for use by the FDA.

### PulseRider

The PulseRider aneurysm neck reconstruction device (Cerenovus) is a Y- or T-shaped device customized for the treatment of bifurcation aneurysms. PulseRider's novel design allows it to be placed in an intraluminal, intrasaccular, or hybrid configuration and serve as a buttress to support a coil mass from herniating into the parent or branch vessels (Figure 1G). Compared to traditional intracranial stents, PulseRider has < 5% metal surface coverage. The PulseRider device was approved by the FDA for the treatment of unruptured basilar apex and internal carotid artery terminus aneurysms after publication of the ANSWER trial data, in which 34 patients were successfully treated with an 87.9% occlusion rate (Raymond-Roy classification 1 or 2 occlusion) at 6 months.<sup>20,21</sup> The NAPA study (NCT03383666) is currently enrolling patients for the investigation of the PulseRider device to treat distal bifurcation aneurysms, including the middle cerebral artery bifurcation and anterior communicating artery aneurysms.

### pCONUS and pCANVAS

The pCONUS bifurcation aneurysm implant (phenox GmbH) is an intraluminal device that is an iteration of the waffle-cone technique for SAC of bifurcation aneurysms. The distal end of the device has a crown that opens within the aneurysm sac, through which coils are placed, and prevents herniation of the coil mass into the parent vessel (Figure 1H). The distal end of the device is self-expanding and anchors to the wall of the parent vessel. Similar to the PulseRider device, pCONUS has a significantly lower percentage of metal coverage than traditional intracranial stents. The pCONUS device is currently under investigation for the treatment of ruptured and unruptured bifurcation aneurysms and has yet to receive FDA approval.<sup>22</sup> A similar bifurcation aneurysm device, pCANVAS (phenox GmbH), has also shown promise. It is an evolution of pCONUS but uses a fine membrane coverage of the petals, allowing for flow diversion without the need for coil embolization (Figure 1I).

### Woven EndoBridge

The Woven EndoBridge (WEB) aneurysm embolization system (MicroVention Terumo) is an intrasaccular flow-disrupting device for the treatment of bifurcation aneurysms. Unlike traditional flow diverters, which are placed within the lumen of the parent vessel, WEB is a braided, nitinol intrasaccular implant (Figure 1J).



Similar to traditional flow diverters, the WEB device diverts blood flow from the aneurysm sac, promoting stasis and aneurysm thrombosis. Importantly, the WEB system can be used for either ruptured or unruptured aneurysms because dual antiplatelet therapy is not required in conjunction with its use. In a systematic review of clinical outcomes associated with the WEB device, Armoiry et al reported occlusion rates between 65% and 85.4% and a morbidity and mortality rate between 2.2% and 6.7%.<sup>23</sup> The device was recently approved by the FDA for both wide-necked ruptured and unruptured aneurysms.

### eClips

The eClips device (Evasc Neurovascular Enterprises ULC) was specifically designed for treating wide-necked aneurysms and, similar to PulseRider, is noted for having a tight mesh to hold coils within the aneurysmal dome (Figure 1K). The device is designed to have an anchor segment that attaches to the arterial walls beside the neck of the aneurysm and a leaf segment that is mobile, allowing for microcatheter access after the device has been deployed. This device has undergone several iterations. In human trials, it has shown a significant learning curve for safe deployment. An initial clinical series demonstrated successful placement of eClips in 76% of patients with an occlusion rate of 81%.<sup>24</sup> This device still warrants the use of dual antiplatelet therapy agents, and even with antiplatelet therapy, two ischemic events occurred within clinical trials.<sup>25</sup>

### Honeycomb Microporous Covered Stent

A honeycomb microporous covered stent, which is currently in development, is primarily intended for wide-necked aneurysms in the cavernous carotid artery and vertebrobasilar system. The balloon-expandable stent is covered with a polyurethane film that develops a honeycomb pattern after expansion. The addition of the polyurethane film allows a stent with a more traditional, lower metal coverage to promote flow-diverting properties. This device has been tested in animal models, and clinical trials are underway with results pending.<sup>26</sup>

### Comaneci

As previously established, BAC is an effective method for treating wide-necked sidewall aneurysms; however, the need for transient flow arrest while the balloon is inflated is a significant drawback. The Comaneci adjustable remodeling mesh device (Rapid Medical) replaces a balloon with an adjustable and temporary stent, thus eliminating flow arrest and the need for dual antiplatelet therapy. The Comaneci device is placed in

the parent vessel across the aneurysm neck. A second coiling microcatheter is then placed within the aneurysm sac, and the Comaneci device is expanded to hold the coiling microcatheter and coils in place while they are deployed (Figure 1L). The Comaneci device is then retracted and removed, thus not requiring dual antiplatelet therapy. However, because there is no permanent support for the coil mass, this system has the same risk of coil herniation as BAC. The Comaneci device is still under investigation and is not approved for use by the FDA. A preliminary study of 18 aneurysms treated with the device demonstrated an occlusion rate of 77.8%, with the remaining 22.2% requiring stent placement for additional support of the coil mass and morbidity in only one (5.6%) case.<sup>27</sup>

## CONCLUSION

The morphology of wide-necked aneurysms presents a challenge for endovascular embolization due to the risk of coil herniation and incomplete occlusion. However, over the past 2 decades, several innovations and advancements in endovascular techniques and devices have augmented the neurointerventionalist's armamentarium, allowing for the successful treatment of most wide-necked aneurysms and continue to expand the capabilities of endovascular therapies. ■

1. Guglielmi G, Vinuela F, Duckwiler G, et al. Endovascular treatment of posterior circulation aneurysms by electrothrombosis using electrically detachable coils. *J Neurosurg*. 1992;77:515-524.
2. Hope JA, Byrne JV, Molyneux AJ. Factors influencing successful angiographic occlusion of aneurysms treated by coil embolization. *AJNR Am J Neuroradiol*. 1999;20:391-399.
3. Turjman F, Massoud TF, Sayre J, Vinuela F. Predictors of aneurysmal occlusion in the period immediately after endovascular treatment with detachable coils: a multivariate analysis. *AJNR Am J Neuroradiol*. 1998;19:1645-1651.
4. Pierot L, Spelle L, Vitry F. Immediate anatomic results after the endovascular treatment of unruptured intracranial aneurysms: analysis of the ATENA series. *AJNR Am J Neuroradiol*. 2010;31:140-144.
5. Moret J, Cognard C, Weill A, et al. Reconstruction technique in the treatment of wide-neck intracranial aneurysms. Long-term angiographic and clinical results. Apros of 56 cases. *J Neurosurg*. 1997;24:30-44.
6. Moret J, Cognard C, Weill A, et al. The "remodelling technique" in the treatment of wide neck intracranial aneurysms: angiographic results and clinical follow-up in 56 cases. *J Interv Neuroradiol*. 1997;3:21-35.
7. Shapiro M, Babb J, Becske T, Nelson PK. Safety and efficacy of adjunctive balloon remodeling during endovascular treatment of intracranial aneurysms: a literature review. *AJNR Am J Neuroradiol*. 2008;29:1777-1781.
8. Sluzewski M, van Rooij WJ, Beute GN, Nijssen PC. Balloon-assisted coil embolization of intracranial aneurysms: incidence, complications, and angiography results. *J Neurosurg*. 2006;105:396-399.
9. Mericle RA, Lanzino G, Wakhloo AK, et al. Stenting and secondary coiling of intracranial internal carotid artery aneurysm: technical case report. *Neurosurgery*. 1998;43:1229-1234.
10. US Food and Drug Administration. Humanitarian device exemption (HDE #H020002): Neuroform microdelivery stent. <https://www.accessdata.fda.gov/scripts/cdrh/cdohs/cfpma/pma.cfm?id=H020002>. Accessed January 10, 2019.
11. Fargen KM, Hoh BL, Welch BG, et al. Long-term results of Enterprise stent-assisted coiling of cerebral aneurysms. *Neurosurgery*. 2012;71:239-244.
12. Chow MM, Woo HH, Masaryk TJ, Rasmussen PA. A novel endovascular treatment of a wide-necked basilar apex aneurysm by using a Y-configuration, double-stent technique. *AJNR Am J Neuroradiol*. 2004;25:509-512.
13. Horowitz M, Levy E, Sauvageau E, et al. Intra/extra-aneurysmal stent placement for management of complex and wide-necked-bifurcation aneurysms: eight cases using the waffle cone technique. *Neurosurgery*. 2006;58(suppl 2):ONS-258-262.
14. Molyneux AJ, Cekirge S, Saatici I, Gal G. Cerebral Aneurysm Multicenter European Onyx (CAMEO) trial: results of a prospective observational study in 20 European centers. *AJNR Am J Neuroradiol*. 2004;25:39-51.
15. US Food and Drug Administration. Premarket approval (PMA #P100018): Pipeline embolization device. <https://www.accessdata.fda.gov/scripts/cdrh/cdohs/cfpma/pma.cfm?id=P100018>. Accessed January 10, 2019.
16. Medtronic. Instructions for use: Pipeline Flex embolization device. <https://www.medtronic.com/us-en/healthcare-professionals/products/neurological/hemorrhagic-stroke/pipeline-flex/indications-safety->

warnings.html. Accessed January 10, 2019.

17. Cho SH, Jo WI, Jo YE, et al. Bench-top comparison of physical properties of 4 commercially-available self-expanding intracranial stents. *Neurointervention*. 2017;12:31-39.

18. Kadirvel R, Ding YH, Dai D, et al. Cellular mechanisms of aneurysm occlusion after treatment with a flow diverter. *Radiology*. 2014;270:394-399.

19. Kallmes DF, Brinjikji W, Boccardi E, et al. Aneurysm study of Pipeline in an observational registry (ASPIRE). *Interv Neurol*. 2016;5:89-99.

20. Spiotta AM, Derdeyn CP, Tateshima S, et al. Results of the ANSWER trial using the PulseRider for the treatment of broad-necked, bifurcation aneurysms. *Neurosurgery*. 2017;81:56-65.

21. US Food and Drug Administration. Humanitarian device exemption (HDE #H160002): PulseRider aneurysm neck reconstruction device. <https://www.accessdata.fda.gov/scripts/cdrh/cfdocs/cfhde/hde.cfm?id=H160002>. Accessed January 10, 2019.

22. Pérez MA, Henkes H, Bouillot P, et al. Intra-aneurysmal hemodynamics: evaluation of pCONus and pCANvas

bifurcation aneurysm devices using DSA optical flow imaging. *J Neurointerv Surg*. 2016;8:1197-1201.

23. Armoiry X, Turjman F, Hartmann DJ, et al. Endovascular treatment of intracranial aneurysms with the WEB device: a systematic review of clinical outcomes. *AJNR Am J Neuroradiol*. 2016;37:868-872.

24. Chiu AH, De Vries J, O'Kelly CJ, et al. The second-generation eCLIPs endovascular clip system: initial experience. *J Neurosurg*. 2018;128:482-489.

25. Ricci DR, de Vries J, Blanc R. Role of preliminary registry data in development of a clinical trial for an innovative device: a small but integral piece of a health policy initiative. *J Mark Access Health Policy*. 2017;5:1283106.

26. Nakayama Y, Satow T, Funayama M, et al. Construction of 3 animal experimental models in the development of honeycomb microporous covered stents for the treatment of large wide-necked cerebral aneurysms. *J Artif Organs*. 2016;19:179-187.

27. Fischer S, Weber A, Carolus A, et al. Coiling of wide-necked carotid artery aneurysms assisted by a temporary bridging device (Comaneci): preliminary experience. *J Neurointerv Surg*. 2017;9:1039-1097.

## Matthew J. McPheeters, MD, MBA

Department of Neurosurgery  
Jacobs School of Medicine and Biomedical Sciences  
University at Buffalo  
Department of Neurosurgery  
Gates Vascular Institute at Kaleida Health  
Buffalo, New York  
*Disclosures: None.*

## Kunal Vakharia, MD

Department of Neurosurgery  
Jacobs School of Medicine and Biomedical Sciences  
University at Buffalo  
Department of Neurosurgery  
Gates Vascular Institute at Kaleida Health  
Buffalo, New York  
*Disclosures: None.*

## Stephan A. Munich, MD

Department of Neurosurgery  
Jacobs School of Medicine and Biomedical Sciences  
University at Buffalo  
Department of Neurosurgery  
Gates Vascular Institute at Kaleida Health  
Buffalo, New York  
*Disclosures: None.*

## Adnan H. Siddiqui, MD, PhD

Department of Neurosurgery  
Department of Radiology  
Jacobs School of Medicine and Biomedical Sciences  
Canon Stroke and Vascular Research Center  
University at Buffalo  
Jacobs Institute  
Department of Neurosurgery  
Gates Vascular Institute at Kaleida Health  
Buffalo, New York  
asiddiqui@ubns.com

*Disclosures: Research grant, Coinvestigator for NIH/NINDS 1R01NS091075 Virtual Intervention of Intracranial Aneurysms; financial interest/investor/stock options/ownership in Amnis Therapeutics, Apama Medical, Blink TBI Inc., Buffalo Technology Partners Inc., Cardinal Consultants, Cerebrotech Medical Systems, Inc., Cognition Medical, EndoStream Medical Ltd., Imperative Care, International Medical Distribution Partners, Neurovascular Diagnostics Inc., Q'Apel Medical Inc, Rebound Therapeutics Corp., Rist Neurovascular Inc., Serenity Medical Inc., Silk Road Medical, StimMed, Synchron, Three Rivers Medical Inc., Viseon Spine Inc.; consultant/advisory board for Amnis Therapeutics, Boston Scientific Corporation, Canon Medical Systems USA Inc., Cerebrotech Medical Systems Inc., Cerenovus, Corindus Inc., EndoStream Medical Ltd., Gore & Associates, Guidepoint Global Consulting, Imperative Care, Integra LifeSciences Corp, Medtronic, MicroVention, Northwest University—DSMB Chair for HEAT Trial, Penumbra, Inc., Q'Apel Medical Inc., Rapid Medical, Rebound Therapeutics Corp., Serenity Medical Inc., Silk Road Medical, StimMed, Stryker, Three Rivers Medical, Inc., VasSol; Principal Investigator/steering committees for Cerenovus (LARGE, ARISE II), Medtronic (SWIFT PRIME, SWIFT DIRECT), MicroVention (FRED, CONFIDENCE, MUSC POSITIVE), and Penumbra, Inc. (3D Separator, COMPASS, INVEST).*