

# Managing Type II Endoleaks

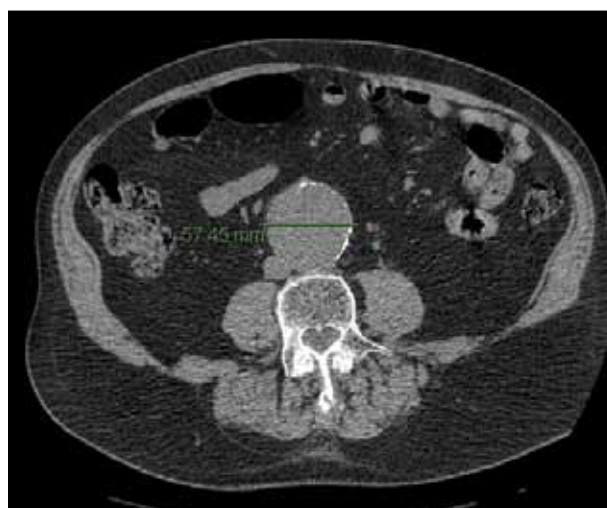Although a common complication, type II endoleaks are not always benign and require innovative treatment strategies.

**BY NAVEED U. SAQIB, MD; KRISTOFER M. CHARLTON-OUW, MD;  
AND ALI AZIZZADEH, MD, FACS**

**A**n endoleak is defined as persistent blood flow in the aneurysm sac extrinsic to the endograft<sup>1</sup> and is the most common complication after endovascular aneurysm repair (EVAR). It has been reported to occur in 10% to 30% of patients at any time during follow-up.<sup>2,3</sup> Type II endoleak results from collateral retrograde flow from the aortic branches, usually from the lumbar arteries, inferior mesenteric artery, or middle sacral artery.<sup>1,4</sup> Because type II endoleaks are the most common type of endoleak after EVAR, they are generally considered to have a benign prognosis. Although this complication has been extensively studied, unresolved issues still remain. The merit for intervention, the optimal timing of intervention, the most efficacious modality for diagnosis, and the treatment of type II endoleaks that occur subsequent to EVAR remain controversial.

The natural history of type II endoleak is still not completely understood; however, it is widely accepted that those associated with aneurysm sac growth are not innocuous. A recent publication revealed a high incidence of secondary interventions (20%), continued aneurysm sac growth (37.9%), and a need for graft explantation (8.4%) in patients with type II endoleaks.<sup>5</sup> The EUROSTAR trial revealed that patients with type II endoleaks require more secondary interventions and have higher rates of open conversion but no increased risk of rupture.<sup>6</sup> Apart from the risks of each reintervention and graft explant, there is also a small but persistent risk of aneurysm rupture (0.5%–2.4%) in the setting of type II endoleak with aneurysm sac growth.<sup>6–9</sup>

Due to the incidence of endoleaks and device-related complications, EVAR patients require lifelong surveil-



**Figure 1. Preoperative CT of an 87-year-old man with a 5.6-cm AAA.**

lance with serial radiologic imaging. It is argued that early advantages conferred by EVAR are substantially offset by the need for serial endograft surveillance and frequent secondary interventions.

Imaging from a patient with an abdominal aortic aneurysm (AAA) who underwent routine EVAR and subsequently required intervention for aneurysm growth secondary to a type II endoleak is shown in Figures 1 through 5. Preoperative CT angiography (CTA) shows a 5.6-cm AAA (Figure 1). Diagnostic and completion angiography (Figure 2) show a successful EVAR procedure using an Excluder device (Gore & Associates, Flagstaff, AZ). Surveillance CTAs at 6-month intervals show persistent aneurysm growth with no

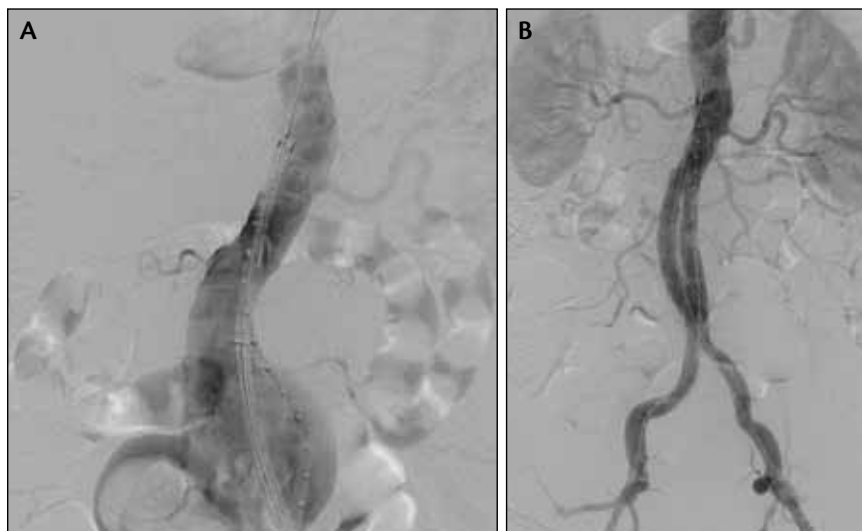


Figure 2. Diagnostic (A) and completion (B) angiograms after successful EVAR.

identifiable endoleak (Figure 3). Subsequent diagnostic angiography identified a type II endoleak from a sacral artery (Figure 4A). Successful CT-guided translumbar embolization was performed using coils and cyanoacrylate glue (Figure 4B). Finally, a follow-up CTA postembolization showed aneurysm shrinkage (Figure 5).

### SURVEILLANCE AFTER EVAR

The Society for Vascular Surgery published guidelines<sup>2</sup> addressing post-EVAR surveillance. The recommended radiologic surveillance is triple-phase CTA at 30 days and 12 months after EVAR. If an endoleak or aneurysm sac growth is identified on the 30-day CTA, a 6-month post-EVAR CTA is recommended. If both 30-day and 12-month post-EVAR CTA scans reveal no endoleak, device abnormality, or aneurysm sac enlargement, surveillance with annual color duplex ultrasound is an accepted alternative to CTA scans when the duplex scan is performed by a skilled technician in an accredited noninvasive vascular lab-

oratory. Although the risk of endoleak declines as the number of negative postoperative scans increases, new endoleaks may be identified many years after EVAR. Identification of a new type II endoleak warrants an initial CTA, a 6-month interval CTA, and subsequent follow-up with duplex imaging if there is an absence of continued aneurysm sac growth, especially for patients whose aneurysm sac measures < 6.5 cm in diameter.

### Is MRI the Best Way to Detect Endoleaks?

CTA may not be able to identify all endoleaks (eg, occult endoleaks) in patients with aneu-

rysm sac growth (Figure 3) and may not identify all of the feeding vessels in patients with apparent type II endoleak.<sup>10</sup> More sensitive imaging is needed to detect endoleaks. A new generation of MRI contrast agents may better detect low-flow leaks.

Blood pool contrast agents bind to albumin, resulting in longer serum half-life and enabling late-phase MRI. Cornelissen et al utilized a weak albumin binder, gadofosveset trisodium, to perform MRI in patients with continued aneurysm sac growth without endoleak on CTA. Thirty-minute delayed MRI revealed type II endoleaks in six of 11 patients (55%), with no endoleaks on CTA.<sup>10</sup> However, MRI has its own limitations: not all endografts are compatible with MRI, not all patients can undergo MRI, the equipment is not always readily available, and studies have not yet confirmed improved outcomes of EVAR due to the early detection of the endoleaks and more extensive identification of feeding vessels.<sup>10</sup>

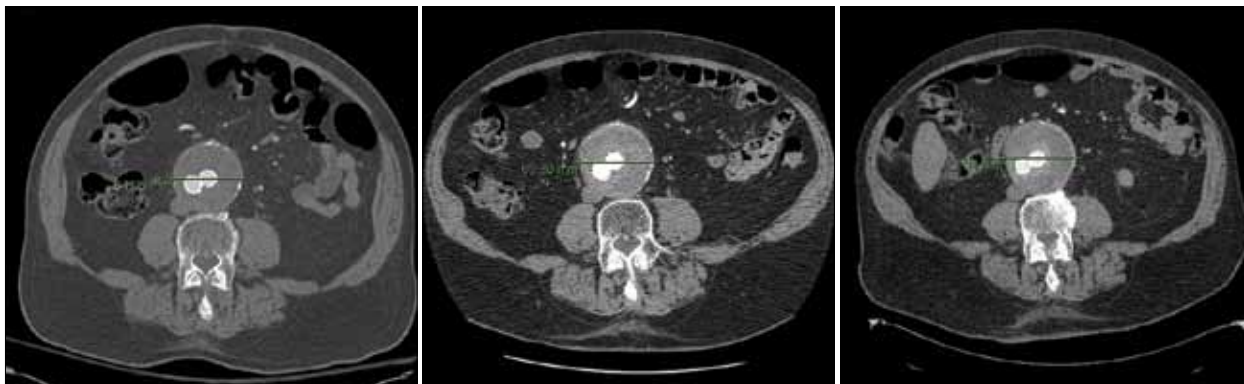

Figure 3. Surveillance CTA at 6-month intervals shows persistent aneurysm growth with no identifiable endoleak.

### Pressure Sensors

Pressure sensors implanted at the time of EVAR have also been studied as a modality to identify and monitor endoleaks. Currently, the only pressure sensor approved by the US Food and Drug Administration consists of a resonant circuit (EndoSure, CardioMEMS, Inc., Atlanta, GA)<sup>11</sup> that is powered by an external radiofrequency antenna. The device must be correctly positioned inside the aneurysm sac and not between the endograft and landing zone of the aortic wall. Several studies have shown its efficacy in detecting type I and II endoleaks.<sup>12,13</sup> Because its safety, long-term complications, efficacy, and accuracy are still debated for type II endoleaks, pressure sensors remain an adjunct to standard imaging modalities until more clinical data become available.<sup>4,11</sup>

### DEVELOPMENTS IN TREATMENT MODALITIES

A variety of strategies have been proposed and implemented to treat type II endoleaks. Treatment with transfemoral embolization,<sup>14</sup> translumbar direct sac embolization,<sup>15</sup> transfemoral transsealing embolization, open and laparoscopic ligation<sup>16</sup> of the lumbar and mesenteric arteries, aneurysm sac placcation,<sup>17</sup> and open conversion<sup>2,18</sup> are offered for patients with type II endoleaks who have aneurysm sac growth of  $> 5 \text{ mm}^2$  or persistent endoleaks<sup>8</sup> ( $> 6$  months).

### Preemptive Treatment Is Effective, But Is It Necessary?

The verdict is still out in regard to the utility of preemptive treatment to prevent the occurrence of type II endoleak. Investigators have suggested preemptive treatment to prevent the occurrence of endoleaks using Onyx (Covidien, Mansfield, MA),<sup>19</sup> placement of a thrombogenic absorbable sponge, polyurethane foam, and fibrin glue concurrent to the deployment of the endograft.<sup>20</sup> Ronsiville et al<sup>21</sup> recently published outcomes of inducing concurrent intrasac thrombosis in 180 EVAR patients compared with 224 EVAR patients without intrasac clotting. The preventive sac thrombosis was reported to produce a decreased risk of type II endoleak (2.2% vs 15.2%;  $P < .001$ ).<sup>21</sup>

Axelrod et al<sup>22</sup> advocated selective preoperative embolization of large inferior mesenteric arteries (IMAs), but the value of this approach was never verified or adopted on a large scale. Opponents to the preemptive approach

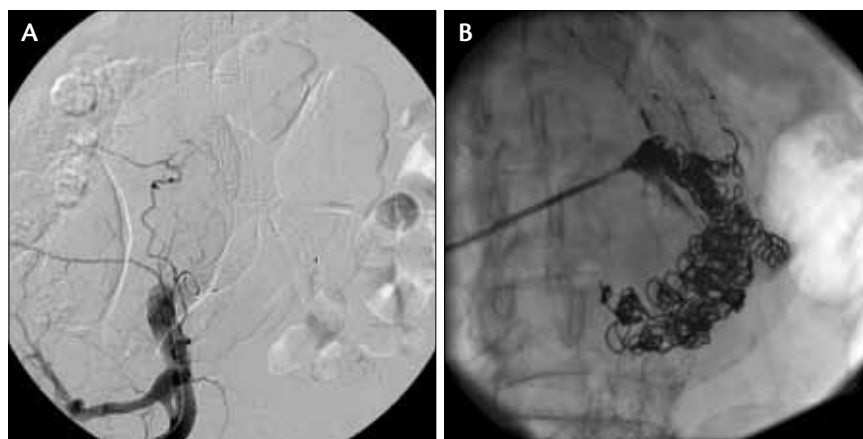


Figure 4. Diagnostic angiogram identifying a type II endoleak (A). Successful translumbar embolization using coil and cyanoacrylate glue (B).

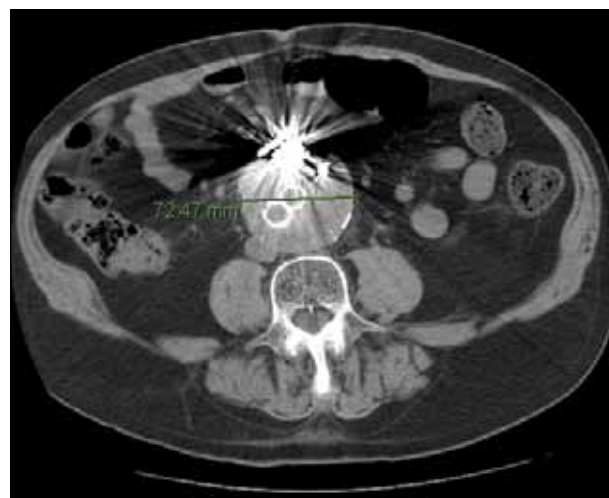

Figure 5. Surveillance CTA after embolization showing aneurysm shrinkage.

suggest that such treatment is not warranted due to the low incidence of type II endoleaks with aneurysm sac growth coupled with the risks and costs of preemptive treatment.<sup>4</sup> The clot engineering concept for prevention of type II endoleaks will lead to future research in the field of biomaterials and polymers.<sup>21</sup>

### Selective and Aggressive Approaches Have Similar Outcomes

A meta-analysis compared conservative, selective, and aggressive approaches for treating type II endoleaks in 2,705 patients who underwent EVAR.<sup>23</sup> Of these, 230 patients (0.08%) developed type II endoleaks. Next, 30.7% of the type II endoleak patients were treated conservatively (close serial surveillance without intervention), 45% were treated selectively (intervention for sac growth  $> 5 \text{ mm}$  or persis-

tent endoleak > 6–12 months), and 24.2% were treated aggressively (intervention for any endoleak present for > 3 months). The study revealed that aggressive or selective treatment neither reduced sac expansion nor improved sac regression compared to the conservative approach. There was no rupture reported in any of the groups.

### Transfemoral and Translumbal Embolization Techniques Are Equivalent

Obliteration of type II endoleaks can be challenging and requires advanced endovascular skills.<sup>24</sup> Transfemoral retrograde catheterization using microcatheters with occlusion by coiling or embolic materials has been shown to have technical success in the range of 65% to 100%.<sup>25</sup> Embolization of both inflow and outflow vessels is considered to be the principle of this approach. In general, type II IMA endoleaks are treated by selecting the middle colic artery through the superior mesenteric artery and retrograde access to the IMA through the marginal artery.<sup>14,24–26</sup> Type II lumbar endoleaks are accessed through retrograde cannulation of the ilio-lumbar arteries (Figure 4A) from the internal iliac arteries.<sup>14,24,27</sup> Direct aneurysm sac puncture under fluoroscopic or CT guidance for translumbar embolization is technically easier (Figure 4B). The aneurysm sac is cannulated with a spinal needle while the patient is in the prone position, and the sac is then injected with glue.<sup>5</sup>

Reports of higher failure rates after transfemoral embolizations (80% vs 8%) have been attributed to embolization of a single vessel and failure to obliterate the endoleak sac and the outflow vessel at the initial attempt. When both the feeding artery and endoleak sac were embolized, comparable success rates of 72% versus 78% were reported by Stavropoulos et al<sup>28</sup> in a recent study. Sarac et al<sup>5</sup> also did not find any significant difference in success rates between transarterial and translumbar techniques, even after 5 years of follow-up.

Interventions to treat endoleaks also carry some risk. The intervention-related 30-day complications have been reported in the range of 2% to 9%. Sarac et al reported a complication rate of 8.6%, comprising atrial fibrillation, myocardial infarction, retroperitoneal bleed, lumbar plexopathy, formation of pseudoaneurysms, aspiration pneumonia, multiple organ failure secondary to bowel ischemia, renal artery perforation, contrast nephropathy, catheter sepsis, and colonic ischemia.<sup>5</sup>

### Coil Embolization Alone Results in Higher Secondary Interventions

Regardless of the technique used to treat type II endoleaks, there is a relatively frequent need for

repeat interventions, reportedly ranging between 2% to 20%.<sup>3,5,28,29</sup> Sarac et al noted that type II endoleaks treated by coil embolization alone required more secondary reinterventions, but this did not result in increased aneurysm sac growth or open conversion.<sup>5</sup> This particular finding has not been previously reported in the literature. There was no difference in the materials used in preventing sac expansion in their experience. However, patients who underwent only coil embolization were more likely to require a second intervention (51%; 95% confidence interval [CI], 34%–76%;  $P = .006$ ). Additionally, patients undergoing an additional embolization procedure had a higher incidence of requiring additional subsequent embolizations ( $P < .001$ ).<sup>5</sup> The authors postulate that during the secondary interventions, the remaining culprit vessels not identified or treated during the initial embolization resulted in resolution of the endoleak, underlying the importance of treating as many endoleak sources as possible, including inflow, outflow, and the aneurysm sac itself, for successful endoleak obliteration.<sup>30</sup>

Liquid embolization agents (Onyx, glue, thrombin, polymers) disperse beyond the site of injection to thrombose the treated vessel and treat the outflow and the endoleak sac. Recent publications have revealed an increase in the utilization of glue embolization. However, glue and Onyx are relatively expensive and have been reported to cause unintended spill, resulting in a higher complication rate, especially in patients with small AAA sacs, short IMAs, and abundant lumbar collateral networks. Based on these findings, Sarac et al recommend performing glue embolization of type II endoleaks as the first choice of therapy and reserving coils embolization for large vessels and those with short necks when the risk of spilling of glue is higher.<sup>5</sup>

### Long-Term Results of Treatment of Type II Endoleaks

Early success (Figure 5) in treating type II endoleaks has been documented by several authors.<sup>18,25</sup> However, Sarac et al<sup>5</sup> are the first to report long-term outcomes (5 years) after the treatment of type II endoleaks. Out of 809 EVARs performed, 95 patients with type II endoleaks were treated with 140 interventions. Despite excellent early success at 1 year (92.4% cumulative survival, 100% freedom from explantation, 84.9% freedom from secondary intervention, 81.5% freedom from aneurysm sac growth), the long-term follow-up revealed continued decline in success at 5 years (64.5% cumulative survival, 88.8% freedom from explantation, 75.8% freedom from secondary intervention, 43.7% freedom from aneurysm sac growth). Endograft explantation was needed in nine patients (8.4%). No aneurysm rupture occurred in this



series. Secondary embolizations were required in 20% (19 patients). Univariate analysis revealed that tobacco use is a risk factor for aneurysm sac growth (hazard ratio, 2.3; 95% CI, 1.02–5.13;  $P = .04$ ), and hyperlipidemia is a risk factor for secondary embolization intervention (hazard ratio, 9.64; 95% CI, 2.22–41.86).<sup>5</sup>

Most long-term studies have reported no difference between endograft types and the development of type II endoleaks.<sup>25,31</sup> However, in a recent publication, Sarac et al reported that in their experience, the Zenith stent graft (Cook Medical, Bloomington, IN) was less likely to be explanted than other grafts (97%; 95% CI, 91%–100%;  $P = .003$ ) and had a lower incidence of aneurysm sac growth ( $> 5$  mm at 5 years), without reaching statistical significance.<sup>5</sup> These findings demonstrate the importance of continued surveillance and close follow-up even after early successful treatment of type II endoleaks.

### Management Options When Endovascular Interventions Fail

Endovascular embolization approaches are the first line of therapy, but as noted above, 8% to 10% of persistent type II endoleak patients require open conversion<sup>6</sup> and endograft explantation for continued growth in the aneurysm sac. Laparoscopic<sup>16</sup> or robotic<sup>32</sup> ligation of mesenteric and lumbar arteries, laparotomy with plication<sup>17</sup> of the endoleak source from within the sac, and total robotic ligation of the IMA have been reported with acceptable success rates to avoid open conversion.

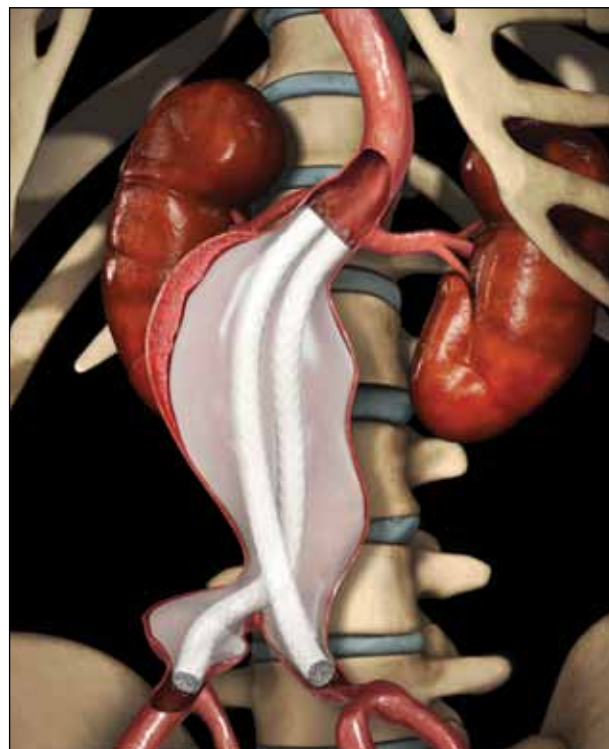### FUTURE INNOVATIONS

The poor results of type II endoleak treatments underline the need for further innovations in endograft design directed at eliminating the incidence of type II endoleaks in the first place.

### Endovascular Aneurysm Sealing

The Nellix device (Endologix, Inc., Irvine, CA) is an investigational endovascular aneurysm sealing (EVAS) system designed for the treatment of infrarenal AAAs.<sup>33</sup> Nellix is a next-generation AAA therapy intended to treat more challenging anatomies than currently approved devices and is the only technology in which the operating principle is centered on sealing the aneurysm sac. The Nellix system uses polymer-filled endobags to fill the aneurysm sac after placement of dual-balloon-expandable endoframes (Figure 6).

The initial clinical trial experience involving 34 patients was published by Krievins et al,<sup>34</sup> with 2-year follow-up results revealing 100% implant success and no type II endoleak, rupture, device migration, or



Courtesy of Endologix, Inc.

Figure 6. The Nellix device using the EVAS treatment strategy.

endograft explantation. One secondary procedure for a distal type I endoleak has been performed (2.9% of patients). In a recent update of 47 patients by Benenati et al,<sup>35</sup> one patient (2.1%) had a type II endoleak at 30-day follow-up, which resolved without intervention on 6-month follow-up, and there was one postoperative death (2.1%) from multiorgan failure unrelated to the device. An investigational device exemption trial in the United States is expected to commence in the near future. This trial and longer-term follow-up studies are awaited and appear promising.

### Endothelial Denudation of the Aortic Wall With Radiofrequency Ablation

Endothelial denudation of the aortic wall by radiofrequency ablation concurrently at the time of endograft deployment or at the time of endoleak treatment has shown promising results in animal models.<sup>36</sup> Combining embolization and endothelial denudation could be a viable strategy to prevent the occurrence, persistence, or recurrence of endoleaks after EVAR.

### CONCLUSION

Type II endoleaks with aneurysm sac growth are not benign and should be treated by endovascular embolization. An enhanced understanding of the type

## TAKE-HOME POINTS

- Type II endoleaks with aneurysm sac growth are not benign and should be treated by endovascular embolization.
- Current imaging modalities have improved the detection of type II endoleaks, but further improvements are still needed.
- Endograft explantation and open conversion is still required in some EVAR patients.
- Future innovations in next-generation endograft design should focus on eliminating the occurrence of type II endoleaks.

II endoleak circuit of inflow and outflow vessels has led to increased success with embolization techniques. Although current imaging modalities have improved detection of type II endoleaks, further improvements are still needed. Investigational devices have shown promising early results, and long-term follow-up in this regard should be pursued. ■

*Naveed U. Saqib, MD, is Assistant Professor, Department of Cardiothoracic and Vascular Surgery, University of Texas Houston Medical School and Memorial Hermann Heart and Vascular Institute in Houston, Texas. He has disclosed that he has no financial interests related to this article.*

*Kristofer M. Charlton-Ouw, MD, is Assistant Professor, Department of Cardiothoracic and Vascular Surgery, University of Texas Houston Medical School and Memorial Hermann Heart and Vascular Institute in Houston, Texas. He has disclosed that he has no financial interests related to this article.*

*Ali Azzadeh, MD, FACS, is Associate Professor and Director of Endovascular Surgery, Department of Cardiothoracic and Vascular Surgery, University of Texas Houston Medical School and Memorial Hermann Heart and Vascular Institute in Houston, Texas. He has disclosed that he is a consultant to Gore & Associates and Medtronic, Inc. Dr. Azzadeh may be reached at [ali.azzadeh@uth.tmc.edu](mailto:ali.azzadeh@uth.tmc.edu).*

- White GH, Yu W, May J, et al. Endoleak as a complication of endoluminal grafting of abdominal aortic aneurysms: classification, incidence, diagnosis, and management. *J Endovasc Surg.* 1997;4:4152-4168.
- Chakof EL, Brewster DC, Dalman RL, et al. SVS practice guidelines for the care of patients with an abdominal aortic aneurysm: executive summary. *J Vasc Surg.* 2009;50:880-896.
- Aziz A, Menias CO, Sanchez LA, et al. Outcomes of percutaneous endovascular intervention for type II endoleak with aneurysm expansion. *J Vasc Surg.* 2012;55:1263-1267.
- Lee K, Forbes TL. Current understanding of the significance and treatment of type II endoleaks. *Ital J Vasc Endovasc Surg.* 2012;19:191-197.
- Sarac TP, Gibbons C, Vargas L, et al. Long-term follow-up of type II endoleak embolization reveals the need for close surveillance. *J Vasc Surg.* 2012;55:33-40.
- van Marrewijk CJ, Fransen G, Laheij RJ, et al; EUROSTAR Collaborators. Is a type II endoleak after EVAR a

harbinger of risk? Causes and outcome of open conversion and aneurysm rupture during follow-up. *Eur J Vasc Endovasc Surg.* 2004;27:128-137.

- Cho JS, Park T, Kim JY, et al. Prior endovascular abdominal aortic aneurysm repair provides no survival benefits when the aneurysm ruptures. *J Vasc Surg.* 2010;52:1127-1134.
- Jones JE, Atkins MD, Brewster DC, et al. Persistent type 2 endoleak after endovascular repair of abdominal aortic aneurysm is associated with adverse late outcomes. *J Vasc Surg.* 2007;46:1-8.
- Abularrage CJ, Crawford RS, Conrad MF, et al. Preoperative anatomic variables are predictive of persistent type 2 endoleak after EVAR. *J Vasc Surg.* 2010;52:19-24.
- Cornelissen SA, Prokop M, Verhagen HJ, et al. Detection of occult endoleaks after endovascular treatment of abdominal aortic aneurysm using magnetic resonance imaging with a blood pool contrast agent: preliminary observations. *Invest Radiol.* 2010;45:548-553.
- Milner R, De Rango P, Verzini F, Cao P. Are intrasac pressure measurements useful after endovascular repair of abdominal aortic aneurysms? *J Vasc Surg.* 2011;53:534-539.
- Ohki T, Ouniel K, Silveira PG, et al. Initial results of wireless pressure sensing for endovascular aneurysm repair: the APEx trial—Acute Pressure Measurement to Confirm Aneurysm Sac Exclusion. *J Vasc Surg.* 2007;45:236-242.
- Parsa CJ, Daneshmand MA, Lima B, et al. Utility of remote wireless pressure sensing for endovascular leak detection after endovascular thoracic aneurysm repair. *Ann Thorac Surg.* 2010;89:446-452.
- Kasirajan K, Matteson B, Marek JM, Langsfeld M. Technique and results of transfemoral super selective coil embolization of type II lumbar endoleak. *J Vasc Surg.* 2003;38:61-66.
- Rial R, Serrano F, Vega M, et al. Treatment of type II endoleaks after endovascular repair of abdominal aortic aneurysms: translumbar puncture and injection of thrombin into the aneurysm sac. *Eur J Vasc Endovasc Surg.* 2004;27:333-335.
- Wisselink W, Cuesta MA, Berends FJ, et al. Retroperitoneal endoscopic ligation of lumbar and inferior mesenteric arteries as a treatment of persistent endoleak after endoluminal aortic aneurysm repair. *J Vasc Surg.* 2000;31:1240-1244.
- Hinchliffe RJ, Singh-Ranger R, Whitaker SC, Hopkinson BR. Type II endoleak: transperitoneal sacotomy and ligation of side branch endoleaks responsible for aneurysm sac expansion. *J Endovasc Ther.* 2002;9:539-542.
- Faries PL, Cadot H, Agarwal G, et al. Management of endoleak after endovascular aneurysm repair: cuffs, coils, and conversion. *J Vasc Surg.* 2003;37:1155-1161.
- Fry PD, Martin M, Machan L. Endoleaks and the need for a paradigm shift. *J Endovasc Ther.* 2000;7:521.
- Walker SR, Macierewicz J, Hopkinson BR, et al. Endovascular AAA repair: prevention of side branch endoleaks with thrombogenic sponge. *J Endovasc Surg.* 1999;6:350-353.
- Ronsavalle S, Faresin F, Franz F, et al. Aneurysm sac "thrombization" and stabilization in EVAR: a technique to reduce the risk of type II endoleak. *J Endovasc Ther.* 2010;4:517-524.
- Axelrod DJ, Lookstein RA, Guller J, et al. Inferior mesenteric artery embolization before endovascular aneurysm repair: technique and initial results. *J Vasc Interv Radiol.* 2004;15:1263-1267.
- Karthikesalingam A, Thrumurthy SG, Jackson D, et al. Current evidence is insufficient to define an optimal threshold for intervention in isolated type II endoleak after endovascular aneurysm repair. *J Endovasc Ther.* 2012;19:200-208.
- Sampram ES, Karafa MT, Mascha EJ, et al. Nature, frequency, and predictors of secondary procedures after endovascular repair of abdominal aortic aneurysm. *J Vasc Surg.* 2003;37:930-937.
- Sheehan MK, Barbato J, Compton CN, et al. Effectiveness of coiling in the treatment of endoleaks after endovascular repair. *J Vasc Surg.* 2004;40:430-434.
- Görlich R, Rillinger N, Sokiranski R, et al. Embolization of type II endoleaks fed by the inferior mesenteric artery: using the superior mesenteric artery approach. *J Endovasc Ther.* 2000;7:297-301.
- Baum RA, Cope C, Fairman RM, Carpenter JP. Translumbar embolization of type 2 endoleaks after endovascular repair of abdominal aortic aneurysms. *J Vasc Interv Radiol.* 2001;12:111-116.
- Stavropoulos SW, Park J, Fairman R, Carpenter J. Type 2 endoleak embolization comparison: translumbar embolization versus modified transarterial embolization. *J Vasc Interv Radiol.* 2009;20:1299-1302.
- Nolz R, Teufelsbauer H, Asenbaum U, et al. Type II endoleaks after endovascular repair of abdominal aortic aneurysms: fate of the aneurysm sac and neck changes during long-term follow-up. *J Endovasc Ther.* 2012;19:193-199.
- Solis MM, Ayerdi J, Babcock GA, et al. Mechanism of failure in the treatment of type II endoleak with percutaneous coil embolization. *J Vasc Surg.* 2002;36:485-491.
- Ouniel K, Clair DG, Greenberg RK, et al. Endovascular repair of abdominal aortic aneurysms: device-specific outcomes. *J Vasc Surg.* 2003;37:991-998.
- Lin JC, Eun D, Shrivastava A, et al. Total robotic ligation of inferior mesenteric artery for type II endoleak after endovascular aneurysm repair. *Ann Vasc Surg.* 2009;23:255.
- Endologix, Inc. Nellix Endovascular Aneurysm Sealing System. [http://www.endologix.com/investigational\\_devices/nellix/](http://www.endologix.com/investigational_devices/nellix/). Accessed January 3, 2013.
- Krievins DK, Holden A, Savlovskis J, et al. EVAR using the Nellix Sac-anchoring endoprosthesis: treatment of favourable and adverse anatomy. *Eur J Vasc Endovasc Surg.* 2011;42:38-46.
- Benenati JF. A novel approach for sac sealing and preservation of internal iliac artery perfusion in aortoiliac endovascular treatment. Presented at: The International Symposium on Endovascular Therapy; January 15-19, 2012; Miami, FL.
- Lerouge S, Bonneviot MC, Salazkin I, et al. Endothelial denudation combined with embolization in the prevention of endoleaks after endovascular aneurysm repair: an animal study. *J Endovasc Ther.* 2011;5:686-696.