

Carotid Endarterectomy: The Eversion Technique

A look at the eversion approach to CEA, including technical tips, available data, and how to decide when this might be the best option.

BY TIMOTHY M. SULLIVAN, MD, FACS, FSVS, FSVM, FACC

Most vascular surgeons have been trained in standard carotid endarterectomy (CEA), involving a longitudinal arteriotomy from the common carotid artery (CCA) into the internal carotid artery (ICA), removal of plaque, identification and “tacking” of the distal endpoint, and closure either primarily or with a patch of synthetic or autogenous material. I was trained in this method by Drs. Hertzner, Beven, Krajewski, and O’Hara at the Cleveland Clinic in the mid 1990s.¹ At that time, the method of choice included saphenous vein patch angioplasty, typically from a small groin incision. I employed this method for several years following my fellowship training but eventually spent time with Dr. Ramon Berguer in Detroit, who instructed me in the technique of eversion CEA (and reconstruction of the distal vertebral artery). I found the technique to be elegant and efficient, and it has been my technique of choice for the past 2 decades.

Eversion endarterectomy of the carotid bifurcation was first described by DeBakey et al in 1959.² This approach involved transection of the distal CCA, eversion of the ICA and external carotid artery (ECA), and primary anastomosis. This particular technique of eversion endarterectomy is best utilized in those with disease isolated to the carotid bulb and proximal ICA. For most patients, the current technique of eversion endarterectomy involves disconnection of the ICA from the carotid bulb with a long, oblique arteriotomy and subsequent reanastomosis following endarterectomy.

TECHNIQUE

Much like carotid angioplasty and stenting, attention to preoperative medical management is essential for optimal results. Patients are placed on a statin, aspirin, and clopidogrel (75 mg) for at least 1 week

prior to the operation. Additionally, if patients are taking warfarin, they are left on this medication (with therapeutic international normalized ratio [INR]) and daily aspirin (81 mg) is added. We have found that in patients undergoing eversion endarterectomy, there is no increase in bleeding risk in those with therapeutic INR or those taking clopidogrel.³ We have not extended this practice to patients taking novel anticoagulants, such as apixaban. I typically also give patients 10 mg of dexamethasone intravenously in the preoperative hold-

ADVANTAGES AND DISADVANTAGES OF EVERSION CEA

ADVANTAGES

- Faster operative time
- Reduced incidence of restenosis
- Does not require patch angioplasty
- No synthetic material is required
- Facilitates management of redundant ICA

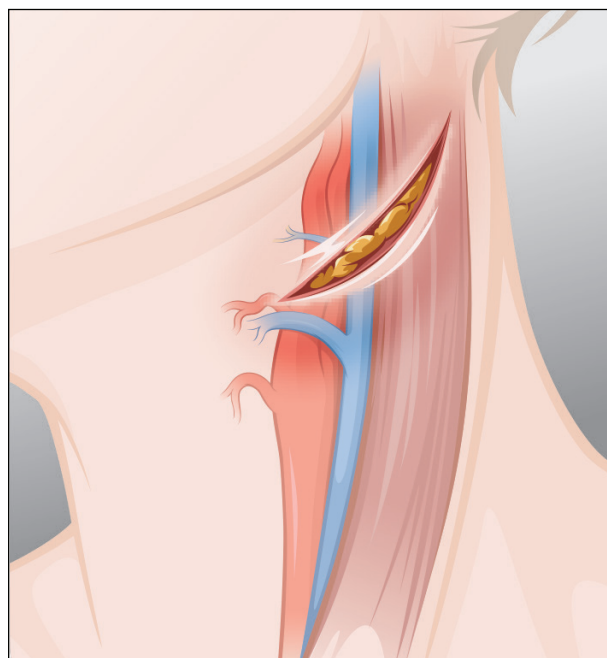
DISADVANTAGES

- More extensive dissection of the carotid bulb and ICA is required
- More challenging to shunt
- May be more difficult to access high lesions for inexperienced surgeons
- Increased incidence of postoperative hypertension

ing area, as there is some evidence that this medication increases the ischemic threshold in patients during carotid clamping and that it may also be beneficial in reducing the incidence of cranial nerve injury.⁴

The carotid arteries are exposed in a standard fashion, as utilized for standard CEA. My personal preference is to place the patient under general anesthesia with continuous intraoperative electroencephalographic monitoring. Alternatively, the procedure can be performed under local anesthesia with a cervical block. Once the patient is under anesthesia, the carotid bifurcation is identified with B-mode ultrasound and marked on the skin. The neck is then prepped in a sterile fashion. A small incision is made along the anterior border of the sternomastoid muscle, centered over the previously marked carotid bifurcation. The incision is kept to < 4 cm in length. The vagus and hypoglossal nerves are identified and preserved, and the patient is systemically anticoagulated with heparin prior to manipulation of the carotid bulb and internal carotid arteries. Activated clotting times are monitored throughout the operation, maintaining a value of > 250 seconds. A self-retaining retractor (pediatric Omni-Flex system, Integra LifeSciences Corporation) is placed, allowing superb visualization of the distal ICA. Although many texts specify that a length of distal ICA equal to the length of the plaque should be exposed (to facilitate eversion), I have found this to be unnecessary, as satisfactory eversion with visualization of the distal ICA endpoint can be achieved with a lesser length of exposed ICA.

One of the disadvantages of the eversion technique is the relative difficulty of placing a shunt should the patient experience cerebral ischemia with carotid artery clamping. Although technically feasible, the shunt must be placed after endarterectomy of the ICA, which is not the case with the standard technique. To avoid the need for a shunt, mean arterial pressure is typically driven to > 90 mm Hg prior to clamping the ICA. Should the awake patient experience hemispheric symptoms or electroencephalographic changes develop in the patient under general anesthesia during clamping, flow is restored to the ICA and blood pressure is driven a bit higher by the anesthesia team. Often, with several successive attempts at ICA clamping, the patient will ultimately tolerate ICA clamping, due to acute cerebral preconditioning. In the event that this is not possible, the standard endarterectomy technique is employed and a temporary indwelling shunt is placed. In the event that ICA clamping is tolerated, I typically wait for 3 minutes before disconnecting the ICA from the carotid bulb and use this time to circumferentially



Courtesy of Ramon Berquer, MD, PhD.

Figure 1. A small (typically < 4-cm length) incision is made over the carotid bifurcation, which has been identified by B-mode ultrasound.

dissect the bulb and proximal ICA under the protection of a clamped ICA to avoid iatrogenic embolization of plaque.

The ICA is then disconnected from the carotid bulb using a long, oblique arteriotomy. A deep plane is developed between the arterial media and adventitia, and the adventitia is rolled cephalad while maintaining downward gentle traction on the plaque. Small pieces of loose atheroma and medial muscle fibers are removed under loupe magnification as the endarterectomy proceeds, as it is more challenging to do so once the artery is flaccid following plaque removal. The distal endpoint is identified and the plaque removed in a circumferential fashion. As with conventional endarterectomy, the key to a successful operation is to secure the distal endpoint. With the eversion technique, the endpoint is developed around the circumference of the ICA, under direct vision without the need for tacking sutures. A “donut” is removed, leaving behind intima that is adherent to the adventitia; the incidence of intimal dissection leading to postoperative thrombosis, embolization, or stroke is negligible. Inspection of the entire circumference of the distal endpoint is mandatory, so that any persistent flap or intimal defect can be identified and corrected. This is the most important and critical portion of the operation. In most cases, endarterectomy of the distal common carotid,

Courtesy of Ramon Berquer, MD, PhD.

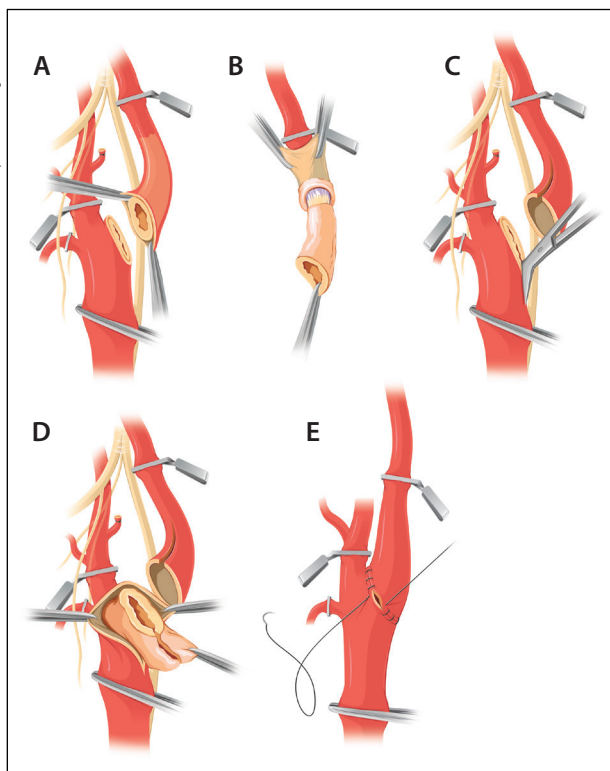
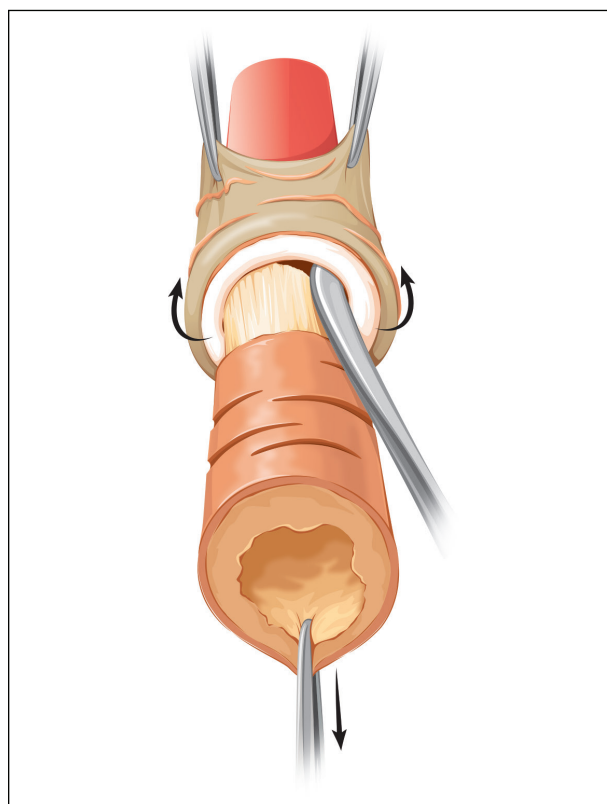


Figure 2. The eversion endarterectomy technique. After proximal and distal control have been obtained with atraumatic clamps, the ICA is disconnected from the carotid bulb with an oblique arteriotomy (A). The ICA is everted, and the plaque is removed (B). The arteriotomy on the CCA is extended proximally (C). If the ICA is redundant, it can be shortened. Endarterectomy of the CCA and ECA (D). The ICA is reconnected to the carotid bulb with continuous polypropylene sutures (E).

carotid bulb, and ECAs is required. I typically use tacking sutures to secure the proximal CCA cuff—a technique that may be associated with a decreased risk of restenosis.⁵

When the ICA is redundant, the eversion technique allows for shortening of the artery before reanastomosis to the carotid bulb. I find that this process is much simpler than in conventional endarterectomy, which requires plication of the proximal ICA prior to patch angioplasty.

Figures 1 through 4 graphically outline the techniques used in successful eversion endarterectomy. In patients with plaque isolated to the carotid bulb and very proximal ICA and ECA, a slight variation in technique may be performed in which the CCA is transected, as described by DeBakey et al.² Proximal CCA eversion is performed, along with simultaneous



Courtesy of Ramon Berquer, MD, PhD.

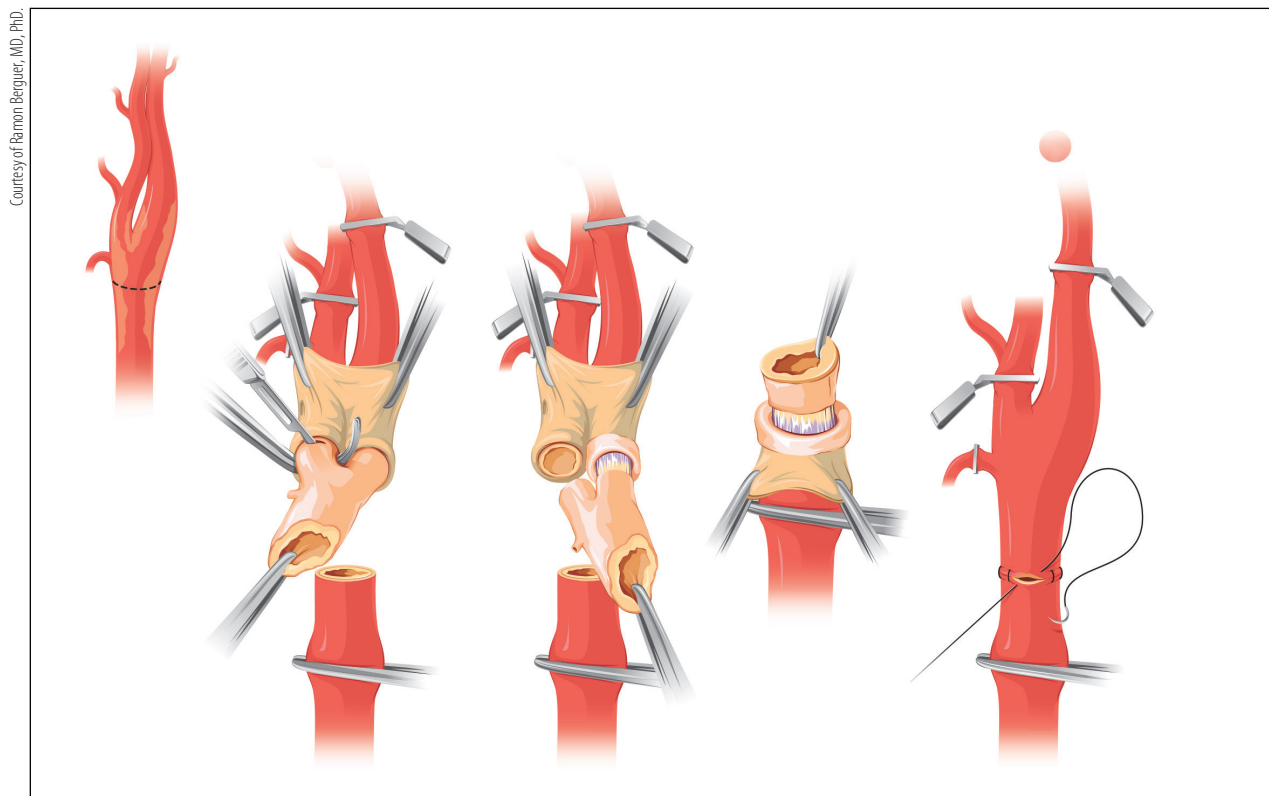
Figure 3. Management of the distal endpoint.

eversion of the ECA and ICA; division of the superior thyroid branch of the ECA may be required to facilitate eversion. In my experience, anatomy conducive to this technique exists in < 5% of cases.

RESULTS

Many studies have compared standard and eversion techniques for CEA. The EVEREST trial compared the two methods in a randomized, prospective study published in 2000.⁶ Over a 2.5-year period, 1,353 patients were randomized to undergo eversion ($n = 678$) or standard ($n = 675$) CEA. The incidence of ipsilateral stroke was 3.3% in the eversion group and 2.2% in the standard group. There were no statistically significant differences in the rate of stroke or death between the two groups ($P = .2$). At 4 years of follow-up, the cumulative restenosis risk was significantly lower in the eversion group when compared with the standard group ($P = .01$).

The most common complication after CEA is blood pressure instability requiring medical treatment. A recently published meta-analysis reviewed the role of surgical technique in postoperative blood pressure. The study reviewed six published reports and found that patients who underwent eversion CEA were more



Courtesy of Ramon Berquier, MD, PhD.

Figure 4. In patients with plaque that is isolated to the carotid bulb and very proximal ICA and ECA, the distal CCA can be transected, and proximal and distal eversion can be performed.

likely to develop postoperative hypertension than those in the standard CEA group ($P < .0001$), and those who underwent standard CEA were more likely to develop postoperative hypotension. There was no difference in the rates of myocardial infarction, stroke, death, or hematoma.⁷ It may be that the increased dissection of the carotid bulb and ICA required for the eversion technique is responsible for this phenomenon. Regardless, close blood pressure monitoring in the immediate postoperative period is required, regardless of technique. The potential advantages and disadvantages of eversion CEA are listed in the *Advantages and Disadvantages of Eversion CEA* sidebar.

CONCLUSION

Eversion CEA is an elegant technique for managing patients with high-grade stenosis of the ICAs and provides excellent long-term stroke prevention for both symptomatic and asymptomatic patients. There is evidence that the rate of significant restenosis is less than that for patients treated with standard CEA. Regardless of the technique chosen, meticulous attention to detail is required in both preoperative and postoperative medical management and operative technique in order to provide optimal results. ■

1. Sullivan T. The greatest generation. *Ann Vasc Surg.* 2014;28:1809-1810.
2. DeBakey ME, Crawford ES, Cooley DA, Morris GC Jr. Surgical considerations of occlusive disease of innominate, carotid, subclavian and vertebral arteries. *Ann Surg.* 1959;149:690-710.
3. Rosenbaum A, Rizvi AZ, Alden PB, et al. Outcomes related to antiplatelet or anticoagulation use in patients undergoing carotid endarterectomy. *Ann Vasc Surg.* 2011;25:25-31.
4. Regina G, Angilletta D, Impedovo G, et al. Dexamethasone minimizes the risk of cranial nerve injury during CEA. *J Vasc Surg.* 2009;49:99-102; discussion 103.
5. Hertzner NR, Bena JF. Patching plus extended exposure and tacking of the common carotid cuff may reduce the late incidence of recurrent stenosis after carotid endarterectomy. *J Vasc Surg.* 2013;58:926-934.
6. Cao P, Giordano G, De Rango P, et al. Eversion versus conventional carotid endarterectomy: late results of a prospective multicenter randomized trial. *J Vasc Surg.* 2000;31:19-30.
7. Demirel S, Goossen K, Bruijnen H, et al. Systematic review and meta-analysis of postcarotid endarterectomy hypertension after eversion versus conventional carotid endarterectomy. *J Vasc Surg.* 2017;65:868-882.

Timothy M. Sullivan, MD, FACS, FSVS, FISM, FACC

Chair, Department of Vascular/Endovascular Surgery
Minneapolis Heart Institute—Abbott Northwestern Hospital

Clinical Professor of Surgery

University of Minnesota

Minneapolis, Minnesota

timothy.sullivan@allina.com

Disclosures: Consultant to Vevyan Medical Ltd.; meeting organizer for Gore & Associates.