

# The Role of Endovascular Interventions in Pediatric Trauma

Types of pediatric trauma and available endovascular tools for management.

BY C. MATTHEW HAWKINS, MD

**T**he role of vascular intervention in adult trauma care is well established. Endovascular embolization in the setting of blunt abdominopelvic and solid visceral injuries has been a long-standing component of the adult trauma care algorithm, has been extensively studied, and is a requirement for adult level 1 trauma centers.

In contrast, the role of interventional radiologists and other vascular specialists in the care of pediatric trauma is largely unstudied and poorly delineated. There are a number of factors that have likely contributed to the inconsistent integration of interventionists into the pediatric trauma team, including: (1) differing etiologies of pediatric trauma, (2) widely variable age range including neonates and young adults, (3) antiquated endovascular equipment that is too large to accommodate small pediatric blood vessels, (4) relative uncommonness of pediatric trauma compared to adults, and (5) wide variation in skill level and willingness of interventionists available to perform pediatric interventional procedures. Despite these reasons, vascular specialists' role in pediatric trauma care appears to be increasing. This growth is driven by more interventionists becoming increasingly comfortable performing interventions on children and equipment that continues to get smaller, which is largely driven by adult arterial interventions below the knee and improved neurovascular equipment.

The purpose of this article is to describe the incidence and types of pediatric trauma, review the available peer-reviewed literature regarding endovascular intervention's role in pediatric trauma, and present case examples of contemporary equipment that may be employed to perform endovascular procedures in young children.

The role of interventional radiologists and other vascular specialists in the care of pediatric trauma is largely unstudied and poorly delineated.

## INCIDENCE AND TYPES OF INJURIES IN CHILDREN

### Solid Organ Injuries

A recent review of the National Trauma Data Bank (NTDB) by Safavi et al demonstrated that from 2011 to 2012, there were 6,799 pediatric patients (age  $\leq 18$  years) with solid organ injuries. Of these, 2,375 had splenic injuries, 2,867 had liver injuries, and 1,557 had renal injuries.<sup>1</sup> To put this in perspective, these totals suggest that there are fewer than 10 pediatric solid organ injuries as reported by the NTDB each day in the United States and Canada. The NTDB is a thorough resource containing more than 1.8 million cases contributed by more than 900 trauma centers across the United States and Canada.<sup>1</sup> Interestingly, of these pediatric solid organ injuries, 3,561 were treated in adult trauma centers, and 3,238 were treated in pediatric trauma centers (a recent designation established by the American College of Surgeons in 2006). When the authors evaluated the cohort of pediatric patients treated at adult trauma centers and compared them to those treated at pediatric trauma centers, the only statistically significant dif-

ference in care was that admission to an adult trauma center increased the likelihood that splenic injuries were treated operatively. This is an important point, as the standard of care in pediatric trauma has shifted to nonoperative management of hemodynamically stable patients with solid organ injuries.<sup>2,3</sup> Additionally, children have a higher mortality rate from sepsis following splenectomy than adults.<sup>4</sup> Thus, the data show that solid organ injury in children is rare; however, the standard of care between adult and pediatric facilities, particularly related to splenic injuries, seems to differ in potentially significant ways.

Endovascular embolization can play a role in the care of these patients. In a 10-year retrospective review, Gross et al demonstrated that 15 of 259 (5.8%) children with splenic injuries were managed with endovascular embolization and that only one in 15 (7%) failed embolization and required splenectomy.<sup>5</sup> Additionally, nine of 227 (4%) patients treated conservatively failed nonoperative management, eight of whom required embolization and one of which required splenectomy. In sum, during the 10-year study period, more successful splenic artery embolizations were performed ( $n = 22$ ) than splenectomies ( $n = 19$ ).

Vo and colleagues performed the largest retrospective review of pediatric abdominal and pelvic trauma treated by endovascular embolization. The authors reviewed 21 solid organ injuries (eight in the liver, six in the spleen, and seven in the kidney) treated via endovascular embolization over an 11-year period. Only one patient died from solid organ injury (in addition to extensive pelvic trauma). All other patients with solid organ injuries were successfully managed via endovascular embolization.<sup>6</sup>

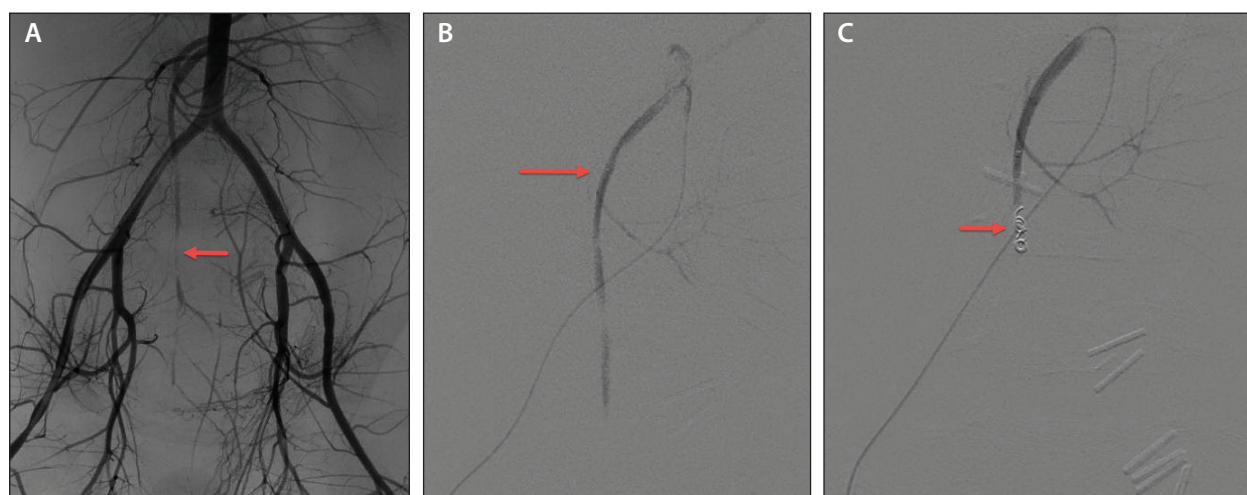
It must be noted that in the studies by Gross et al and Vo et al, the mean and median ages (respectively) of patients treated via embolization were 13.5 ( $\pm 4.5$ ) and 16 years (range, 6–17 years). Thus, the evidence is very limited in the setting of young children with solid organ injuries.

### Pelvic Trauma

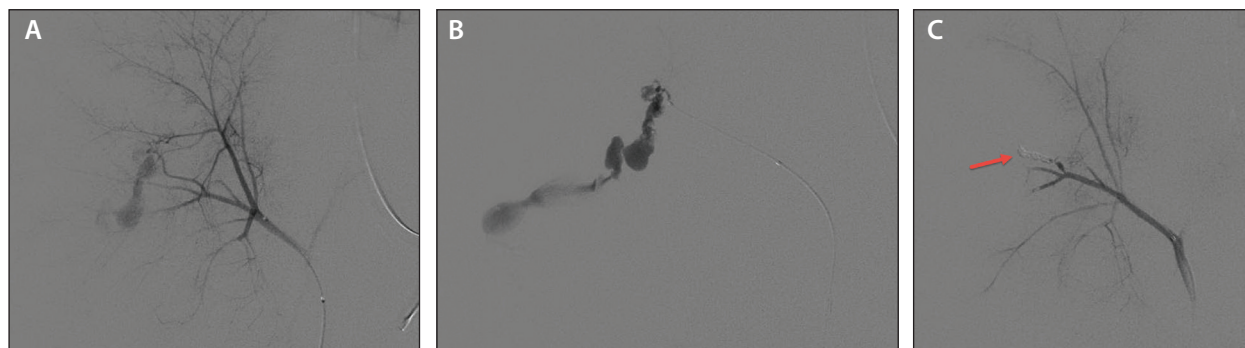
Vo et al further described their institution's experience with pelvic embolization in the pediatric population. In their study, 39 patients underwent arterial embolization for blunt pelvic trauma over an 11-year period (approximately 3.5/year).<sup>6</sup> The clinical success rate of embolization was 90% (35/39 patients). There was one associated complication, overflow urinary incontinence after coil embolization of the left internal iliac trunk. It is also important to note that 43 negative angiograms were performed for suspected arterial extravasation, in addition to patients undergoing intra-arterial embolization procedures. Also, motor vehicle and motorcycle crashes accounted for nearly 50% of all mechanisms of injury, and the median age of all patients was 16 years. This further demonstrates that data regarding endovascular intervention in the setting of trauma in young children remains immature.

### Other Vascular Injuries

A recent review of Sweden's National Vascular Surgery registry (Swedvasc) between 1987 and 2013 demonstrated that of the 222 children (defined as age  $\leq 15$  years) who underwent vascular surgery for traumatic vascular injuries (approximately 8–9 per



**Figure 1.** Angiogram and embolization in a 4-year-old boy with a gunshot wound to the pelvis. Note the stretch injury (red arrow) of the IMA (A). A 2.5-F microcatheter and 0.014-inch microwire were used to access the IMA (red arrow) directly from the aorta (B), and a 0.018-inch coil (red arrow) was used to embolize the vessel (C).



**Figure 2.** Right hepatic angiogram in a 6-year-old patient with hepatic injury following a fall from a balcony (A). A 1.7-F microcatheter and 0.01-inch wire were used to access a segment 6 branch and confirm frank extravasation (B). The vessel was successfully embolized with a 0.01-inch detachable coil (red arrow) (C).

year), 199 of the injuries requiring surgery occurred in the upper and lower extremity arteries, and blunt trauma was the most common etiology.<sup>7</sup> Other vessels, including the thoracic/abdominal aorta, incurred traumatic injuries requiring surgical intervention much less often. No injuries were treated via endovascular intervention.

Further demonstrating the rarity of these injuries in children, Rowland and colleagues performed a systematic review of noniatrogenic traumatic venous injuries in children between 1957 and 2013. In their analysis of 13 articles, there were 508 reported injuries (approximately 9–10 per year). The inferior vena cava (IVC) was the most commonly injured vein, followed by the femoral and internal jugular veins. No reported injuries were managed via endovascular repair.<sup>8</sup>

Collectively, the peer-reviewed literature provides little guidance for interventional radiologists asked to perform endovascular interventions in small children. The relative rarity of these injuries and variability in practice patterns make the study of these injuries in this patient population challenging.

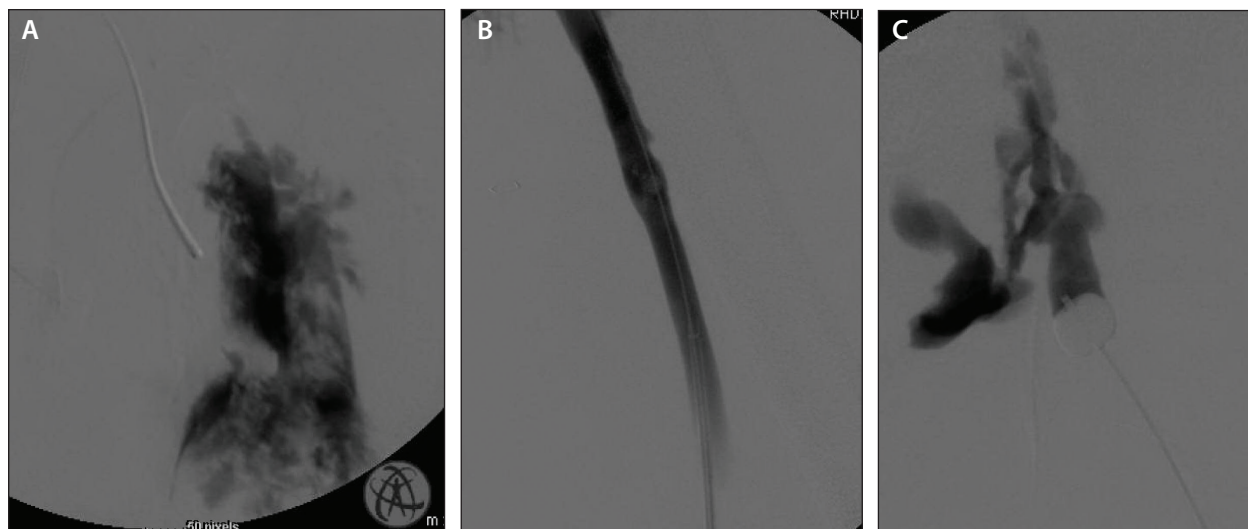
## CURRENT CAPABILITIES AND FUTURE DIRECTION

The smaller size of endovascular equipment is currently being driven by below-the-knee adult interventions and continued improvement in neurovascular microcatheters. In addition to some commonly known available equipment, such as 3-F diagnostic catheters, interventionists can begin to build an inventory that will allow for safe vascular access in very small children and distal embolization in the setting of solid organ and vascular injuries. However, these small access devices do not allow for the delivery of covered stent grafts, such as what might be used for some vascular injuries, but the smaller devices open the door for novel inter-

ventions to be performed more safely and perhaps more effectively in the setting of pediatric trauma.

For example, by utilizing a hemostasis assembly device hub on the back end of a micropuncture transitional dilator, an operator can create a sheath smaller than the traditionally available 4-F sheath. Through this sheath, 3-F diagnostic catheters and microcatheters can be placed to access arteries in children. Figure 1A shows an angiogram performed using a 3-F straight flush catheter (which can inject 8 mL of contrast per second), which demonstrates a stretch injury of the inferior mesenteric artery (IMA) in a 4-year-old boy who suffered a gunshot wound to the pelvis. The IVC was perforated and was repaired surgically; however, the patient suffered from rapidly dropping hemoglobin and an enlarging intra-abdominal hematoma, prompting the need for angiography. Figure 1B shows access of the IMA obtained directly off the aorta via a 2.5-F microcatheter and a 0.014-inch microwire. The vessel was embolized with a single 0.018-inch coil (Figure 1C), with subsequent cessation of hemorrhage.

Use of neurovascular microcatheters allows for more distal embolization of solid organ injuries in children. For example, hepatic abscess formation has been reported with proximal Gelfoam (Pfizer, Inc.) embolization of hepatic arteries in both adults and children.<sup>6</sup> However, additional distal access to these vessels with more precise embolization may reduce the risk of pediatric patients with hepatic injuries. Figure 2A shows a right hepatic arterial angiogram in a 6-year-old patient who fell from a balcony and had frank extravasation of contrast on abdominal CT. Access was achieved via a 1.7-F neurovascular microcatheter, which was used in combination with a 0.01-inch microwire to select the right hepatic artery directly from the aorta. Figure 2B shows further subselection of a posterior segment 6 branch with the microcatheter with frank extravasation



**Figure 3.** Left femoral venogram in a 9-year-old patient following a gunshot wound to the pelvis (A). Because of frank extravasation, more distal femoral vein access was obtained (B), and an occlusion balloon was used in the external iliac vein (C) to impede blood flow and allow for surgical ligation of the injured vessel.

of contrast. A 0.01-inch detachable coil was then used to embolize this branch, with subsequent cessation of hemorrhage.

A final example of the potential role for endovascular intervention in the setting of pediatric trauma is use of occlusion balloons in a multidisciplinary team approach to therapy. Use of aortic occlusion balloons by interventionalists has been described in adults<sup>9</sup>; however, their use may also be beneficial in certain pediatric scenarios. Figure 3A demonstrates an intraoperative venogram obtained after left femoral vein access in a 9-year-old with a gunshot to the left hemipelvis. Interventional radiology was called into the case because of the inability to control venous hemorrhage and identify a single bleeding vessel to surgically repair. Frank extravasation of contrast into the left hemipelvis was demonstrated. Because blood was accumulating so quickly into the pelvis, no normal vein was visualized to “cross” into for covered stent placement, and no single bleeding vein could be identified to be clamped, more inferior left femoral vein access was achieved (Figure 3B), and a 5-F occlusion balloon was inflated in the left external iliac vein (Figure 3C). By occluding blood flow from the offending vessel, the pediatric surgeons were able to identify shredded external and common iliac veins and skillfully ligate them.

## CONCLUSION

With the designation of pediatric trauma centers by the American College of Surgeons in 2006, a more pediatric-centric approach to trauma has been emphasized

nationwide. It will be important for interventionalists to compile and aggregate data related to pediatric trauma in order to evaluate the efficacy of endovascular interventions and define their role in the care of this patient population. Fortunately, technologic advancements have been made to treat smaller blood vessels that were previously unreachable. A multidisciplinary, collaborative approach will also help outline new ways to improve how pediatric trauma victims are cared for via endovascular interventions. ■

*C. Matthew Hawkins, MD, is Director of Pediatric Vascular Interventional Radiology, Children's Healthcare of Atlanta, Emory University School of Medicine in Atlanta, Georgia. He has stated that he has no financial interests related to this article. Dr. Hawkins may be reached at matt.hawkins@emory.edu.*

1. Safavi A, Skarsgard ED, Rhee P, et al. Trauma center variation in the management of pediatric patients with blunt abdominal solid organ injury: a national trauma data bank analysis [published online ahead of print August 28, 2015]. *J Pediatr Surg*.
2. Ein SH. Evidence based guidelines for children with isolated spleen or liver injury: Mcleod RS, Webber E. *Can J Surg* 2004 (December);44:458-460. *J Pediatr Surg*. 2005;40:1217-1218.
3. Safavi A, Beaudry P, Jamieson D, Murphy JJ. Traumatic pseudoaneurysms of the liver and spleen in children: is routine screening warranted? *J Pediatr Surg*. 2011;46:938-941.
4. Bisharat N, Omari H, Lavi I, Raz R. Risk of infection and death among post-splenectomy patients. *J Infect*. 2001;43:182-186.
5. Gross JL, Woll NL, Hanson CA, et al. Embolization for pediatric blunt splenic injury in an alternative to splenectomy when observation fails. *J Trauma Acute Care Surg*. 2013;75:421-425.
6. Vo NJ, Althoen M, Hippe DS, et al. Pediatric abdominal and pelvic trauma: safety and efficacy of arterial embolization. *J Vasc Interv Radiol*. 2014;25:215-220.
7. Wahlgren CM, Kragstern B. Management and outcomes of pediatric vascular injuries. *J Trauma Acute Care Surg*. 2015;79:563-567.
8. Rowland SP, Dharmarajah B, Moore HM, et al. Venous injuries in pediatric trauma: systematic review of injuries and management. *J Trauma Acute Care Surg*. 2014;77:356-363.
9. Horer TM, Hebron D, Swaid F, et al. Aorta balloon occlusion in trauma: three cases demonstrating multidisciplinary approach already on patient's arrival to the emergency room [published online ahead of print October 9, 2015]. *Cardiovasc Intervent Radiol*.