

Large-Access Closure Techniques

Minimally invasive approaches that are safe and reliable in emergent and anatomically challenging situations.

BY THOMAS LARZON, MD, PhD, AND LARS LÖNN, MD, PhD

Treatment for aortic aneurysms has shifted over the last 20 years from open surgery to endovascular repair (EVAR). After failures in the initial years related to early generations of endoprostheses and learning curves, EVAR became an established technique in the late 1990s, and randomized trials indicated at least a short-term benefit for EVAR versus open repair.^{1,2}

Arterial access is a key element in EVAR. The most frequently used vascular access site for performing catheter-based interventions in endovascular surgery is the common femoral artery (CFA). There are three important approaches to expose and close the CFA when using large instruments: (1) exposure of the artery via bilateral open surgical cut-down in the groin, (2) a truly percutaneous approach, and (3) the minimally invasive fascia suture technique. The last two approaches are performed either by placing suture-mediated closure devices before introducing large-bore sheaths or via a small skin incision and suturing of the femoral fascia after the EVAR procedure is finalized.

Patients should be considered candidates for any of the approaches from a strict anatomic perspective. Vessel anatomy, CFA diameter, depth, quality of the vessel wall, vessel tortuosity, and profile of the device used each have an impact. The CFA in normal subjects has a mean diameter of 6.4 mm. Women and patients with diabetes have significantly smaller CFA diameters of 6.1 and 6.3 mm, respectively. EVAR in women is therefore often technically limited by this smaller vessel anatomy. Percutaneous femoral artery access and closure as an alternative to open surgical femoral arterial exposure is advantageous in our experience. Additionally, regional differences, as well as operator preferences and experience, all have major influences when choosing a vascular access approach.

OPEN SURGICAL ACCESS

Traditionally, the bilateral cutdown approach for EVAR has been the standard, owing mostly to the large sheath

sizes of early devices. Surgical exposure of the CFA with vertical or oblique skin incisions is performed bilaterally. The CFA is located in the femoral triangle, where it runs through the femoral canal and is covered anteriorly by the femoral fascia. Access closure is performed with monofilament sutures (running or interrupted). However, the CFA wall may be mechanically damaged after introducer placement, and an endarterectomy with a patch is required.

Because surgical cutdown is considered to be a minor surgical procedure, it is associated with complications such as groin hematoma, seroma/lymphocele, thrombosis, dissection, femoral nerve injury, and delayed wound healing due to infection. The CFA is also exposed to longitudinal stress after surgical cutdown as compared with truly percutaneous EVAR. Another drawback is that future access to the femoral arteries is difficult in the presence of a surgical scar. Sometimes, the anatomy of the external iliac artery makes it necessary to use the common iliac artery as an access site. This can be achieved by retroperitoneal dissection above the inguinal ligament. A stent graft can be inserted directly or via a temporary vascular prosthesis sutured “end to side” to the common iliac artery.

MINIMALLY INVASIVE TECHNIQUES

The introduction of endoprostheses with smaller sheath sizes has facilitated a trend toward minimally invasive methods. A variety of different techniques has been suggested, and for each of them, the appropriate puncture and suture techniques are mandatory. The following sections focus on the presuture and fascia suture techniques as two alternatives for performing aortic repair without using any major open surgical components.

Presuture Techniques

Percutaneous access suture techniques are alternative methods of gaining access with only minor skin trauma and access closure after percutaneous EVAR utilizing a

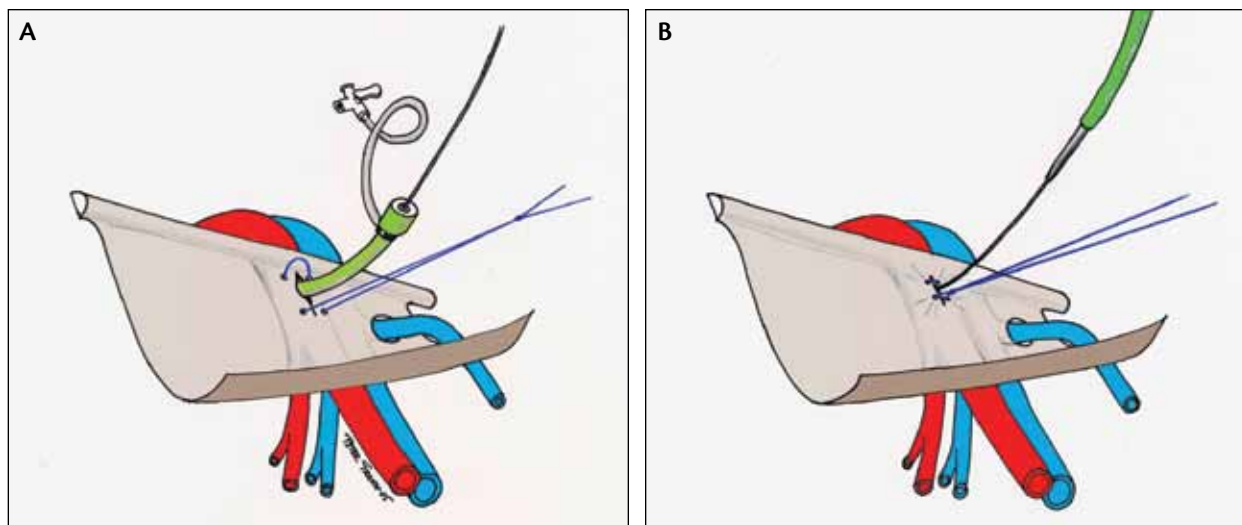


Figure 1. Stitches in the fascia on each side of the introducer with a Gore-Tex suture (A). The sliding knot is tightened as the introducer with the dilator is withdrawn (B). (Drawings produced by Peter Grahn.) Reproduced with permission from the *Journal of Endovascular Therapy*. 2006 ©Copyright (2006) International Society of Endovascular Specialists.³

suture-mediated closure device, the Prostar XL (Abbott Vascular, Santa Clara, CA), which was introduced in the late 1990s.⁴ The endovascular suture technique has been compared with conventional surgical cutdown by Torsello et al⁵ in a randomized study. The authors concluded that both techniques were roughly equivalent in complication severity.

Potential advantages of EVAR without surgical exposure of the femoral arteries are reduced operative time, blood loss, and length of hospital stay, which might justify the additional cost of the device. Patients with the presence of calcification, scarring from previous operations, significant tortuosity of the iliac artery, and obesity have a higher risk for device failure and conversion to femoral artery cut-down. Proper patient selection has therefore been advised for the use of presuture techniques.⁶ Complications such as bleeding, arterial thrombosis, and false aneurysms are known to occur, and there is an extended learning curve involved when introducing this new technique.⁷

The Fascia Suture Technique

A different approach includes minimally invasive but not strictly percutaneous techniques. The fascia suture technique is a method that was described by Dietrich in 1997 by which the femoral fascia (cribriform fascia) covering the CFA is sutured.⁸ Whereas surgical cutdown and the Prostar technique require 5 to 10 minutes of preparation in each groin before the EVAR device is inserted, the fascia suture allows immediate access to the vessel. In emergency procedures, such as ruptured aortic aneurysms, the fascia suture technique is superior because it allows the operating team

to focus on the main task—excluding the rupture and preventing severe bleeding from the aorta.

In Örebro, Sweden, the first fascia suture techniques, although slightly modified in comparison to the technique described by Dietrich, were performed in 2001.³ After the stent grafts are placed and before the large sheaths can be removed, a 4- to 6-cm incision is made at the puncture site. The femoral fascia is exposed after careful digital dissection of the subcutaneous tissues surrounding the CFA. A suture is stitched through the fascia on each side of the introducer along the artery. The arterial wall is intentionally not included in the stitch (Figure 1A). The suture is tightened with a sliding knot as the introducer is withdrawn with the guidewire in place (Figure 1B). If hemostasis is achieved, the guidewire is also withdrawn, and the suture is further tightened. If a bleeding problem occurs, the introducer and dilator are reinserted, allowing supplementary suturing. The suture is tightened to stop the bleeding but not to cause narrowing of the vessel.

It is important to choose a suture with excellent sliding characteristics. The Gore-Tex suture (Gore & Associates, Flagstaff, AZ) has the advantage that the sliding knot easily opens up when the introducer is reinserted. On the other hand, it requires many knots to finally be secured. The aim was to develop a technique that could be used in elective as well as emergency procedures. The fascia suture technique offers a “no-touch” artery closure option, and in cases of endovascular treatment of ruptured aortic aneurysms, the technique is extremely useful in our opinion.

The fascia suture technique is currently the routine tech-
(Continued on page 66)

(Continued from page 63)

nique used in all EVAR and thoracic EVAR procedures in Örebro University Hospital and at the National University Hospital in Copenhagen and has also been adopted by several other centers. Finally, the fascia suture technique has proven in a thesis by Larzon to be effective and competitive with suture devices, but it has until now been difficult to attract a wider group of operators. However, this may change, provided that it will be practically possible to implement well-established training programs. The benefit of the fascia suture technique for EVAR is more cost efficient, has a low complication rate, and offers a notable benefit in emergency situations. In all patients, appropriate management of the groin and CFA is essential in EVAR whether a cutdown or a minimally invasive/percutaneous approach will be used.⁹

CONCLUSION

In order to decrease the incidence of groin access closure complications, we suggest that a percutaneous femoral approach or minimally invasive technique (combined with a proficiently performed puncture technique) should initially be considered for all endovascular aortic procedures. When complications such as bleeding, stenosis, ischemia, or femoral artery injury occur, a low threshold should be considered for conversion to traditional cutdown techniques. ■

Thomas Larzon, MD, PhD, is Head of the Vascular Section with the Department of Cardiothoracic and Vascular Surgery, Örebro University Hospital in Örebro, Sweden. He has disclosed that he has no financial interests related to this article. Dr. Larzon may be reached at thomas.larzon@orebroll.se.

Lars Lönn, MD, PhD, is a Professor of Endovascular Surgery with the Department of Vascular Surgery and Cardiovascular Radiology, National Hospital, Copenhagen University in Denmark. He has disclosed that he has no financial interests related to this article.

1. Greenhalgh RM, Brown LC, Kwong GP, et al; EVAR trial participants. Comparison of endovascular aneurysm repair with open repair in patients with abdominal aortic aneurysm (EVAR trial 1), 30-day operative mortality results: randomised controlled trial. *Lancet*. 2004;364:843-848.
2. Prinssen M, Verhoeven EL, Buth J, et al. A randomized trial comparing conventional and endovascular repair of abdominal aortic aneurysms. *N Engl J Med*. 2004;351:1607-1618.
3. Larzon T, Geijer H, Gruber G, et al. Fascia suturing of large access sites after endovascular treatment of aortic aneurysms and dissections. *J Endovasc Ther*. 2006;13:152-157.
4. Haas PC, Krajcer Z, Dietrich EB. Closure of large percutaneous access sites using the Prostar XL percutaneous vascular surgery device. *J Endovasc Surg*. 1999;6:168-170.
5. Torsello GB, Kasprzak B, Klenk E, Tessarek J, et al. Endovascular suture versus cutdown for endovascular aneurysm repair: a prospective randomized pilot study. *J Vasc Surg*. 2003;38:78-82.
6. Malkawi AH, Hinchliffe RJ, Holt PJ, et al. Percutaneous access for endovascular aneurysm repair: a systematic review. *Eur J Vasc Endovasc Surg*. 2010;39:676-682.
7. Larzon T. Aspects of endovascular treatment of abdominal aortic aneurysms [doctoral dissertation]. Sweden: Ineko; 2012.
8. Dietrich EB. What do we need to achieve durable endoluminal abdominal aortic aneurysm repair? *Tex Heart Inst J*. 1997;24:179-184.
9. Lönn L, Larzon T, van den Berg JC. From puncture to closure of the common femoral artery in endovascular aortic repair. *J Cardiovasc Surg (Torino)*. 2010;51:791-798.