

Ovarian Embolization During Uterine Embolization for Fibroids

Preliminary data suggest that ovarian embolization is an effective and safe adjunct to uterine fibroid embolization.

BY JAMES B. SPIES, MD, MPH

Uterine fibroid embolization (UFE) has become a standard treatment for fibroids, with extensive clinical data supporting its efficacy.¹⁻⁴ It is now recognized by the American College of Obstetricians and Gynecologists as safe and effective in the management of uterine fibroids.⁵ Due to the growing clinical data supporting its use, the procedure has become better accepted in recent years by both gynecologists and patients.

With the broader use of the procedure, its limits have become clearer, and the circumstances that may lead to a failed procedure have gained greater attention.⁶ As early as 1999, ovarian artery collateral supply was recognized as a potential cause of failure.⁷ Yet, despite this recognition, relatively little has been published on supplemental ovarian embolization when embolizing uterine fibroids.

To optimally treat patients, it is important to understand the circumstances when collateral flow might occur, how to best detect it, when and how to treat it, and the potential risks that treatment might entail.

WHEN AND HOW TO ASSESS FOR OVARIAN FLOW

Few patients have an ovarian artery supply requiring treatment. One study found ovarian artery supply to be more than the margin of the uterus in 5.8% of UFE patients.⁸ There may be some circumstances in which the ovarian arteries are more likely to be enlarged. In one study of the frequency of enlarged ovarian arteries, a strong association was noted in patients with a history of previous pelvic surgery (including tubal surgery), tubo-ovarian pathology, or large fundal fibroids.⁹

There are two general approaches to detecting ovarian artery enlargement, either via magnetic resonance angiography before the procedure or by the use of aortography

during the embolization procedure. With an appropriately performed dynamic-enhanced pelvic magnetic resonance imaging examination, three-dimensional vascular reconstructions can be created to screen for the presence of enlarged ovarian arteries. Current evidence would suggest that this has a good negative predictive value.¹⁰

Perhaps more common is the use of aortography at the time of embolization. Usually, the aortogram is obtained after the embolization. Any flow from the ovarian arteries to the uterus detected before embolization needs to be reevaluated after, requiring a second aortogram. In many patients, the uterine and ovarian arterial supply join at the level of the uterus, in what I call “complementary flow.” The flow from the ovarian artery joins and supplements the uterine supply to the fibroids. The flow from the ovarian artery helps carry the embolic to the fibroids. Once the uterine artery embolization is complete, the flow in the ovarian artery slows to a near stop, and additional embolization from the ovarian arteries is often unnecessary.

On aortography, an enlarged ovarian vessel with rapid flow that extends to the level of the pelvis is an indicator of potential flow to the uterus and fibroids.¹¹ However, the extent and significance of the ovarian supply to the uterus cannot be accurately assessed from the aortogram. Selective ovarian arteriography is needed and is discussed in the next section.

OVARIAN CATHETERIZATION TECHNIQUE

Access to the ovarian arteries can be a challenge—the arteries are small and arise from a large vessel, the aorta. This is similar to the challenge of spinal or bronchial arteriography. A recurved 4- or 5-F catheter with a down-going tip is usually needed. One catheter we have found useful is the Mickelson catheter, which was originally designed for spinal

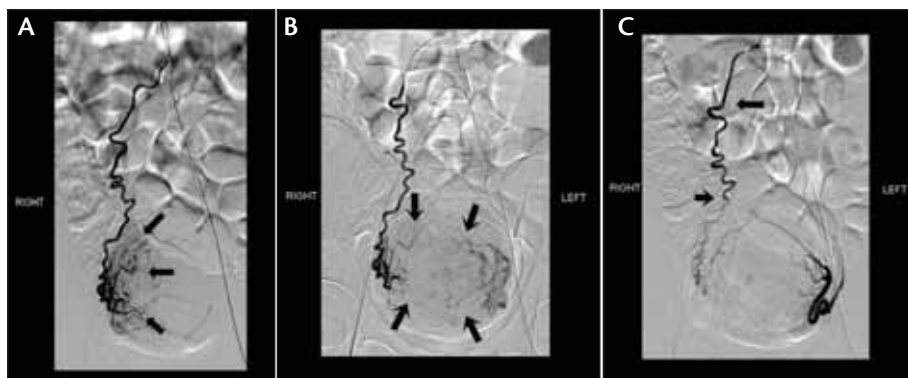


Figure 1. Selective right ovarian arteriogram in a patient with an absent right uterine artery. The arrows show extensive fibroid arterial supply from the ovarian artery (A). Simultaneous injections of the right ovarian artery and left uterine artery demonstrating supply from both to the uterus (arrows) (B). Postembolization bilateral arteriogram showing occlusion of the fibroid supply. A single artery traverses the uterus from left to right not felt to be feeding fibroids. The long arrow shows the level of the microcatheter tip during the embolization. The short arrow shows where the contrast column stops during the injection. Below that level, there is faint contrast from an earlier injection (C).

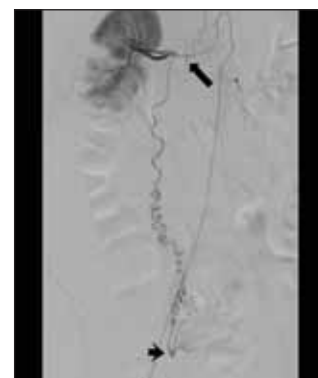

Figure 2. Ovarian artery arising from right renal artery (long arrow). The ovarian connection to the uterine supply is demonstrated at the level of the uterus (short arrow).

arteriography. The RIM catheter or the Sos Omni catheter (AngioDynamics, Inc., Queensbury, NY) are also common choices. The ovarian arteries typically arise from the anterior aortic wall a few centimeters below the renal arteries (Figure 1A),¹² although in a small number of patients, it may arise from a renal artery (Figure 2). The catheter is used to search the anterior wall of the abdominal aorta, using intermittent small injections of contrast material to identify the vessel origin. With contrast opacification of the ovarian artery origin, the tip of the catheter can be guided gently into the vessel. The ovarian artery commonly takes an abrupt upward change in course just after its origin, so the catheter should not be advanced beyond the first few millimeters.

Once the origin of the ovarian artery is catheterized, an arteriogram is needed to determine the actual extent of ovarian supply to the uterus. Because of the instability of the catheters in the ovarian arteries, we perform arteriography with a hand injection of contrast during serial imaging at a frame rate of one image per second.

OVARIAN EMBOLIZATION TECHNIQUE

The judgment as to whether embolization is needed is based on the findings of the ovarian arteriogram, although there are no defined criteria as to when ovarian embolization may be needed. The extent of ovarian contribution to fibroid flow ranges from minimal marginal supply to complete replacement of the uterine artery by the ovarian artery. The decision is further complicated by the location of the fibroids themselves. If the ovarian supply feeds major fibroids, embolization is more likely needed than if there are few or no fibroids in that arterial distribution.

Very little has been written about ovarian embolization technique, and there is no accepted standard method. Most leaders in the field would agree that embolization should be done using a selectively placed microcatheter. The most common approach is to advance a microcatheter several centimeters into the ovarian artery. The initial segment of the vessel is often quite variable, first coursing inferiorly then superiorly before finally turning downward toward the pelvis. The initial downward segment undulates gently approximately one-third of the distance to the pelvis, and then abruptly enters a series of tight curves in the final distance to the ovary and uterus (Figure 1A). We typically place the microcatheter just above this curved segment (Figure 1B) but in any case well within the ovarian artery to avoid reflux of embolic material into the aorta.

After an initial injection to confirm the catheter's position and the fibroid supply, embolization is performed, typically using particulate or spherical embolic material. Spasm can be quite intense in the ovarian arteries, and the embolic material may need to be injected under pressure. The spasm often does not respond to medications. Because of the spasm, determining the endpoint of embolization can be difficult. Usually, an angiogram obtained after embolization will demonstrate occlusion of the branches at the margin of the uterus (Figure 1C).

SAFETY AND EFFECTIVENESS OF OVARIAN EMBOLIZATION

To date, there has been relatively little in the scientific literature about the effectiveness of ovarian embolization as

an adjunct to UFE. There are only a few small series published, the largest with six patients.¹³ In that one brief report, five of six patients treated with ovarian artery embolization (OAE) had successful control of symptoms, and fibroid infarction occurred in all cases. All of the women treated, including three with bilateral OAE, continued regular menstruation, suggesting that menopause is not the inevitable outcome of the procedure. Pelage et al reported on two additional ovarian embolization patients with similar results.⁹

Kroencke and Scheurig recently presented the results of ovarian embolization supplementing uterine embolization in 13 patients.¹⁴ With a mean follow-up of 36 months clinically, 10 of 13 patients had control of symptoms. Two of the patients had onset of menopause. Ultrasound imaging follow-up demonstrated normal-appearing follicles on the side of embolization in nine patients and stable ovarian volume for the group overall. These data add to our understanding of the potential impact of OAE on ovarian function.

These initial results suggest that ovarian embolization may be safe and effective, but clearly more study is needed. Given the limitations in our knowledge, caution is still warranted in performing embolization in clinical practice. It is best used when there is unequivocal substantial fibroid tissue supplied

by the ovarian arteries. In this setting, the patient's outcome likely depends on complete treatment, and we often will embolize at the time of the uterine embolization.

Minor supply may not substantially affect clinical outcome and may not need to be treated. If minor ovarian supply is identified, one option is not to embolize it and assess the patient's clinical outcome. If during that assessment, there is clear residual fibroid perfusion on contrast-enhanced magnetic resonance imaging and the patient's symptoms remain, an appropriate discussion can take place with the patient about the option of ovarian embolization performed as a separate procedure.

SUMMARY

Ovarian embolization is infrequently needed to supplement uterine embolization of fibroids. Having said that, when ovarian arterial supply is encountered, it is important to have a clear understanding of how to assess it, determine its significance, and safely treat it. With appropriate technique, this treatment can be safe and enhance the patient's clinical outcome. ■

James B. Spies, MD, MPH, is Professor and Chair, Department of Radiology, Georgetown University Hospital in Washington, DC. He has disclosed that he holds no financial interest in any product or manufacturer mentioned herein. Dr. Spies may be reached at (202) 444-3450; spiesj@gunet.georgetown.edu.

GORE® EXCLUDER® AAA Endoprosthesis

INDICATIONS FOR USE: Trunk-Ipsilateral Leg Endoprosthesis and Contralateral Leg Endoprosthesis Components. The GORE® EXCLUDER® AAA Endoprosthesis is intended to exclude the aneurysm from the blood circulation in patients diagnosed with infrarenal abdominal aortic aneurysm (AAA) disease and who have appropriate anatomy as described below: Adequate iliac / femoral access; Infrarenal aortic neck treatment diameter range of 19 – 29 mm and a minimum aortic neck length of 15 mm; Proximal aortic neck angulation ≤ 60°; Iliac artery treatment diameter range of 8 – 18.5 mm and iliac distal vessel seal zone length of at least 10 mm. **Aortic Extender Endoprosthesis and Iliac Extender Endoprosthesis Components.** The Aortic and Iliac Extender Endoprostheses are intended to be used after deployment of the GORE® EXCLUDER® AAA Endoprosthesis. These extensions are intended to be used when additional length and / or sealing for aneurysmal exclusion is desired. **CONTRAINDICATIONS:** The GORE® EXCLUDER® AAA Endoprosthesis is contraindicated in patients with known sensitivities or allergies to the device materials and patients with a systemic infection who may be at increased risk of endovascular graft infection. Refer to *Instructions for Use* at goremedical.com for a complete description of all warnings, precautions and adverse events. Rx Only



Products listed may not be available in all markets.
GORE®, EXCLUDER®, and designs are trademarks of W. L. Gore & Associates.
©2010 W. L. Gore & Associates, Inc. AP0830-EN1 DECEMBER 2010

- Goodwin SC, Spies JB, Worthington-Kirsch R, et al. Uterine artery embolization for treatment of leiomyomata: long-term outcomes from the FIBROID Registry. *Obstet Gynecol.* 2008;111:22-33.
- Moss J, Lumsden M, Murray GD, et al. UAE vs. surgery: 5 year outcomes (REST trial). Presented at: Cardiovascular and Interventional Radiology Society of Europe Annual Scientific Meeting; October 4, 2010; Valencia, Spain.
- Spies J, Bruno J, Czeyda-Pommersheim F, et al. Long-term outcome of uterine artery embolization of leiomyomata. *Obstet Gynecol.* 2005;106:933-939.
- van der Kooij S, Hehenkamp WJ, Volkers NA, et al. Uterine artery embolization vs hysterectomy in the treatment of symptomatic uterine fibroids: 5-year outcome from the randomized EMMY trial. *Am J Obstet Gynecol.* 2010;203:e1-13.
- ACOG practice bulletin. Alternatives to hysterectomy in the management of leiomyomas. *Obstet Gynecol.* 2008;112:387-400.
- Spies J. Uterine artery embolization for fibroids: understanding the technical causes of failure. *J Vasc Interv Radiol.* 2003;14:11-14.
- Nikolic B, Spies J, Abbara S, et al. Ovarian artery supply of uterine fibroids as a cause of treatment failure after uterine artery embolization: a case report. *J Vasc Interv Radiol.* 1999;10:1167-1170.
- White AM, Banovac F, Yousefi S, et al. Uterine fibroid embolization: the utility of aortography in detecting ovarian artery collateral supply. *Radiology.* 2007;244:291-298.
- Pelage JP, Walker WJ, Le Dref O, et al. Ovarian artery: angiographic appearance, embolization and relevance to uterine fibroid embolization. *Cardiovasc Intervent Radiol.* 2003;26:227-233.
- Kroencke T, Scheurig C, Kluner C, et al. Uterine fibroids: contrast-enhanced MR angiography to predict ovarian artery supply—initial experience. *Radiology.* 2006;241:181-189.
- Abbara S, Nikolic B, Pelage JP, et al. Frequency and extent of uterine perfusion via ovarian arteries observed during uterine artery embolization for leiomyomas. *AJR Am J Roentgenol.* 2007;188:1558-1563.
- Kadir S. Atlas of normal and variant angiographic anatomy. 1st ed. Philadelphia, PA: WB Saunders; 1991.
- Barth M, Spies J. Ovarian embolization supplementing uterine embolization for leiomyomata. *J Vasc Interv Radiol.* 2003;14:1177-1182.
- Kroencke T, Scheurig-Muenkler C. Safety and efficacy of ovarian artery embolization for symptomatic uterine leiomyomata. Presented at: Cardiovascular and Interventional Radiology Society of Europe Annual Scientific Meeting; October 6, 2010; Valencia, Spain.