

Multiple Mycotic Pulmonary Artery Aneurysms

Endovascular techniques for treating an unusual clinical presentation.

**BY STEPHEN EDWARDS, BS, RT(R)(CV); RAJNEESH AGRAWAL, MD;
AND NANCY DONAHOE, MD**

Mycotic pulmonary artery aneurysm (PAA) is a rare diagnosis with an associated high mortality rate due to the potential for rupture and massive hemoptysis. The finding of multiple and bilateral mycotic PAAs in a single patient is even more rare. Nonmycotic PAAs can be associated with a variety of conditions, including Behcet disease,¹ Hughes-Stovin syndrome,² trauma, connective tissue disorders, and pulmonary hypertension.

Although uncommon, mycotic PAAs can be found in patients with a known history of intravenous drug abuse, infectious endocarditis,³⁻⁵ and persistent patent ductus arteriosus and the related intervention for treating this congenital defect. Historically, mycotic PAAs have been treated conservatively with intravenous antibiotics or more aggressively with surgical resection. Both conservative and surgical treatments can be associated with high morbidity and mortality rates,⁶ although more recent publications have demonstrated stable and even decreasing pseudoaneurysm size with conservative treatments.⁴

The introduction of newer endovascular technology and techniques in recent years has made the endovascular embolization approach a safer and probably more viable option for treating mycotic PAAs. Such technology includes controlled detachable coil systems, guiding catheters, and microcatheters. Originally introduced by the neurointerventional field for treating intracranial aneurysms, these products can provide the added benefit of safety and reliability to peripheral interventional procedures. Controlled detachment and the ability to completely retrieve and redeploy the coil before detachment are the

two primary advantages. These safety features are not available with standard stainless steel or platinum pushable coils.

CASE REPORT

Our institution does not require investigational review board approval for a retrospective case study. We report the case of a 21-year-old man who presented with fever, chest pain, and shortness of breath. He was initially diagnosed with endocarditis and was placed on intravenous antibiotics. Three months later, he was admitted to our hospital with worsening symptoms and mild hemoptysis. The results of an initial computed tomography (CT) scan followed by CT angiography showed multiple cavitory pulmonary nodules with three large mycotic PAAs (one in the right lower lobe and two in the left lower lobe).

Bilateral diagnostic selective pulmonary angiography confirmed these findings (Figure 1). The right lower lobe PAA measured approximately 20 mm, and the two PAAs in the left lower lobe measured approximately 30 mm each. Echocardiography showed extensive tricuspid vegetations with moderate-to-severe tricuspid regurgitation. After discussing the findings with the cardiothoracic team, the patient, and his family, it was determined that the best treatment option would be endovascular embolization of the PAAs with nonfibered coils followed by tricuspid valve surgery.

Access to the PAAs was difficult due to the deep location of the lesions and the lack of stability of the catheters. Specifically, there was great difficulty in maintaining the straight shape of the guiding catheter while crossing

through the right ventricle. After multiple attempts with a traditional guiding catheter and microcatheter combination, we were only able to achieve stability of the microcatheter in the PAA by using the Chaperon guiding catheter (MicroVention-Terumo, Inc., Tustin, CA) and inner catheter system and then placing a microcatheter through the inner catheter. This unique Chaperon system consists of a 6-F outer guide catheter with a 5-F inner diagnostic catheter that luer lock together and form a smooth transition.

A 2.4/1.7-F tapered microcatheter was then triaxially placed through the 5-F catheter into each PAA, with subsequent deployment of multiple platinum (Cosmos, MicroVention-Terumo, Inc.) and hydrogel (HydroSoft, MicroVention-Terumo, Inc.) detachable coils. Imaging performed after embolization showed near complete occlusion of all three PAAs in both the right lower lobe and left lower lobe. The patient tolerated the procedure well without any complications and then underwent successful tricuspid valve replacement.

DISCUSSION

PAAs, although rare, can have a multitude of etiologies, the most common of which is erosion from an adjacent cavitary tuberculosis, which is known as a Rasmussen aneurysm.⁷ Although a misnomer, the term “mycotic aneurysm” usually refers to that which arises from a bacterial infection due to vascular seeding, not a fungal infection.

Mycotic aneurysms are commonly caused by a *Staphylococcus aureus* or a Streptococcal species but have also been documented as coming from *Mycobacterium tuberculosis*, *Treponema pallidum*, and *Corynebacterium diphtheriae*, as well as species of *Candida* and *Aspergillus*.⁸ Other less common causes of mycotic PAAs are those stemming from fungal infections, such as mucormycosis and thoracic actinomycosis.⁸ Aside from fungal and bacterial infections, other rare occurrences have included idiopathic PAA,⁹ as well as a case originating from a fractured ventriculoatrial shunt,¹⁰ once used for the treatment of hydrocephalus in the early 1980s.

Mycotic PAAs and other pulmonary artery lesions have historically been treated both surgically and with conservative management. Originally, surgical resection, lobectomy, pneumonectomy, and arterial banding¹¹ were the only

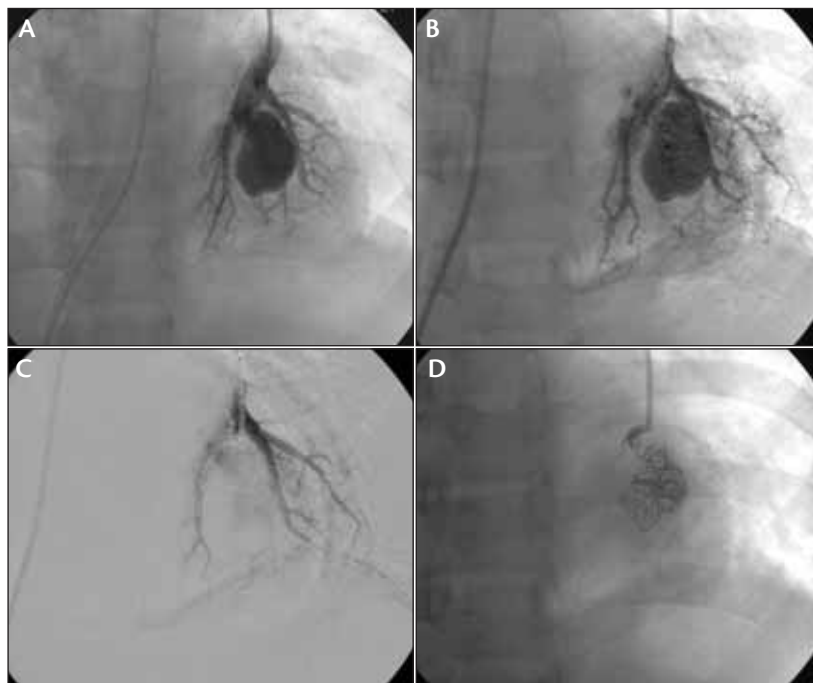


Figure 1. Left lower lobe mycotic pulmonary pseudoaneurysm before coil embolization (A). Partial embolization after deployment of platinum and hydrogel coils (B). Subtracted image after coil embolization (C). Coil cast after embolization (D).

treatment options available for a patient with acute hemoptysis secondary to PAA. Urgent surgical intervention for these patients was recommended due to the high morbidity and mortality associated with massive hemoptysis secondary to a PAA rupture. However, endovascular techniques have been refined during recent years and are becoming the gold standard for treating these difficult vascular lesions.

Mycotic PAAs have also been successfully treated with conservative management consisting of intravenous antibiotics. Conservative management is usually chosen when there is no evidence of acute hemoptysis or other emergent symptoms, or when the patient is not a surgical candidate. Sometimes PAA is secondary to a congenital defect, such as patent ductus arteriosus,⁵ in which the aneurysm resolves after surgical closure of the defect and several weeks of antibiotic therapy. McLean et al⁴ reported the first resolution of bilateral PAA in an intravenous drug abuser without the use of surgical or endovascular intervention. The patient refused endovascular embolization and was treated with intravenous antibiotics and followed closely with CT, which showed a significant reduction in sac size over the course of 12 weeks.

Our patient denied any history of intravenous drug abuse. However, he did have numerous tattoos covering his body, some which were recently acquired, which could

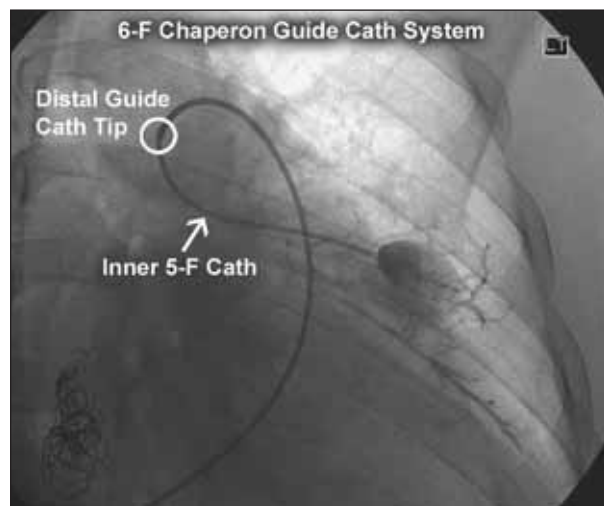


Figure 2. Precoil embolization of a left middle lobe aneurysm. Image shows triaxial access technique using the Chaperon guiding catheter system. A 0.0165-inch inner diameter microcatheter was then placed through the Chaperon device for deployment of the detachable coils.

have been a potential source of the infection. We determined detachable coil embolization to be the safest alternative for treating this patient because of the controlled delivery and accurate placement/deployment within the sac while still preserving the parent vessels. Other endovascular methods have been documented as well. The use of gelfoam, as well as detachable balloons and pushable coils, proved to be a successful treatment for hemoptysis in the late 1970s; however, such techniques had a high rate of recanalization and were more difficult to deliver and deploy to the target site. Most of the historic treatment was parent vessel occlusion, which led to aneurysm recurrence secondary to nontarget embolization.

The first reported coil embolization for mycotic PAA was in 1997.¹² In 2004, Wells et al³ published the first use of detachable coils for this disease and reported a successful outcome. Both authors cited urgent embolization as the management of choice due to safety, efficacy, and lacking the morbidity associated with open surgical resection.

To our knowledge, ours is the first case to describe the use of a triaxial catheter technique for treating PAA. After multiple attempts with a coaxial combination of a diagnostic catheter and microcatheter, we switched to a more stable triaxial combination of guiding catheter, inner catheter, and microcatheter to successfully treat all three mycotic PAAs (Figure 2).

CONCLUSION

The triaxial access method has become common in the neurointerventional radiology field. Physicians routinely use

these tools to treat intracranial aneurysms, fistulae, arteriovenous malformations, and tumors.¹³ Such techniques are less commonly reported in the literature for peripheral interventions. Tulsyan et al¹⁴ describe the use of a triaxial system during treatment of a visceral artery aneurysm. Dr. Robert White, with multiple published reports on pulmonary arteriovenous malformations, described his embolization techniques and use of coaxial and triaxial access and emphasized the importance of a stable catheter access system in achieving successful outcomes.¹⁵ Creating a stable catheter system is the overall advantage of this technique, enabling the practitioner to accurately deliver and deploy the detachable coils to the target location to prevent recanalization of the aneurysm. ■

Stephen Edwards, BS, RT(R)(CV), is with the Nebraska Medical Center, Department of Interventional Radiology in Omaha, Nebraska. He has disclosed that he holds no financial interest in any product or manufacturer mentioned herein. Mr. Edwards may be reached at (402) 559-6462; sedwards@nebraskamed.com.

Rajneesh Agrawal, MD, is with Desert Radiologists, Department of Interventional Radiology in Las Vegas, Nevada. He has disclosed that he holds no financial interest in any product or manufacturer mentioned herein.

Nancy Donahoe, MD, is with Cardiovascular Surgery of Southern Nevada in Las Vegas, Nevada. She has disclosed that she holds no financial interest in any product or manufacturer mentioned herein.

1. Cil BE, Geyik S, Akmanli I, et al. Embolization of a giant pulmonary artery aneurysm from Behcet disease with use of cyanoacrylate and the "bubble technique." *J Vasc Interv Radiol.* 2005;16:1545-1549.
2. Ketchum ES, Zamanian RT, Fleischmann D. CT angiography of pulmonary artery aneurysms in Hughes-Stovin syndrome. *AJR.* 2005;185:330-332.
3. Wells P, Roobottom CA, Morgan-Hughes G, et al. Pulmonary mycotic aneurysm secondary to left-sided infective endocarditis treated with detachable coils. *Clin Radiol Extra.* 2004;59:37-39.
4. McLean L, Sharma S, Maycher B. Mycotic pulmonary arterial aneurysms in an intravenous drug user. *Can Respir J.* 1998;5:307-311.
5. Lertsapcharoen P, Chottivattayarakorn P, Benjacholas V. Mycotic aneurysms of the pulmonary arteries. *Heart.* 2002;88:524.
6. Choyke PL, Edmonds PR, Markowitz RI, et al. Mycotic pulmonary artery aneurysm: complication of Aspergillus endocarditis. *AJR.* 1982;138:1172-1175.
7. Liddell RP, Patel S, Neuwirth M, et al. Transcatheter coil embolization of large pulmonary artery pseudoaneurysms in a child. *J Vasc Interv Radiol.* 2003;14:923-927.
8. Kim HS, Oh Y-W, Noh HJ, et al. Mycotic pulmonary artery aneurysm as an unusual complication of thoracic actinomycosis. *Korean J Radiol.* 2004;5:68-71.
9. Kotwica T, Scumarska J, Stanisewska-Marszałek E, et al. Idiopathic pulmonary artery aneurysm. *Echocardiography.* 2009;26:593-595.
10. Singer-Jordan JR. Mycotic aneurysm of the pulmonary artery complicating ventriculoatrial shunt. *AJR.* 1980;135:378-380.
11. Kumar RV, Roughneen PT, de Leval MR. Mycotic pulmonary artery aneurysm following pulmonary artery banding. *Eur J Cardio Thorac Surg.* 1994;8:665-666.
12. Ghaye B, Trotteur G, Dondelinger RF. Multiple pulmonary artery pseudoaneurysms: intrasaccular embolization. *Eur Radiol.* 1997;7:552-554.
13. Kalimes DF, Jensen ME, Cloft HJ, et al. Percutaneous transvenous coil embolization of a Dujndjian type 4 tentorial dural arteriovenous malformation. *AJNR.* 1997;18:673-676.
14. Tulsyan N, Kashyap VS, Greenberg RK, et al. The endovascular management of visceral artery aneurysms and pseudoaneurysms. *J Vasc Surg.* 2007;45:276-283.
15. White RI. Pulmonary arteriovenous malformations: how do I embolize? *Tech Vasc Interv Radiol.* 2007;10:283-290.