

Visceral Ischemia

Underdiagnosed or a lot of hot air?

BY GUSTAVO S. ODERICH, MD

Diagnosis of uncommon illnesses requires a higher index of suspicion, especially when the diagnosis is difficult to establish. In the case of profound, unintentional weight loss accompanied by abdominal pain, several conditions are nearly always considered: cancer, diabetes, inflammatory bowel disease, malabsorptive disorders, hyperthyroidism, or an infectious cause. Although encountered infrequently, chronic mesenteric ischemia (CMI) is typically manifested by the triad of abdominal pain, weight loss, and “food fear.” Delay in establishing the diagnosis contributes to further cachexia and increases the risk of acute or chronic ischemia with bowel gangrene. Most of these patients already had an extensive evaluation by their primary care physician with a time delay of 9 to 18 months before a definitive diagnosis is made and treatment is recommended.

The most common cause of CMI is ostial atherosclerotic lesions affecting at least two of the three mesenteric arteries, so it is no surprise that these patients have advanced age, multiple cardiovascular risk factors, and diffuse manifesta-

tions of atherosclerosis in other vascular beds. Other less common causes of CMI are vasculitis (eg, Giant cell or Takayasu’s arteritis), fibromuscular dysplasia, spontaneous dissections, neurofibromatosis, abdominal aortic coarctation, trauma, or embolization. Mesenteric revascularization is indicated only in the presence of symptoms and should not be undertaken as a prophylactic measure, because there is only minimal risk of bowel ischemia in the absence of symptoms.

Treatment goals are relief of pain, restoration of normal weight, and prevention of bowel infarction. Open revascularization has been the time-honored treatment and provides immediate relief of symptoms in most patients. However, despite the excellent durability of surgical bypasses, most centers still report a high rate of complications and death.¹ A recent study using national data from 1988 to 2006 analyzed more than 23,000 patients treated who had mesenteric revascularizations in the United States.² During this period, the number of procedures has substantially increased from approximately 180 cases to more than

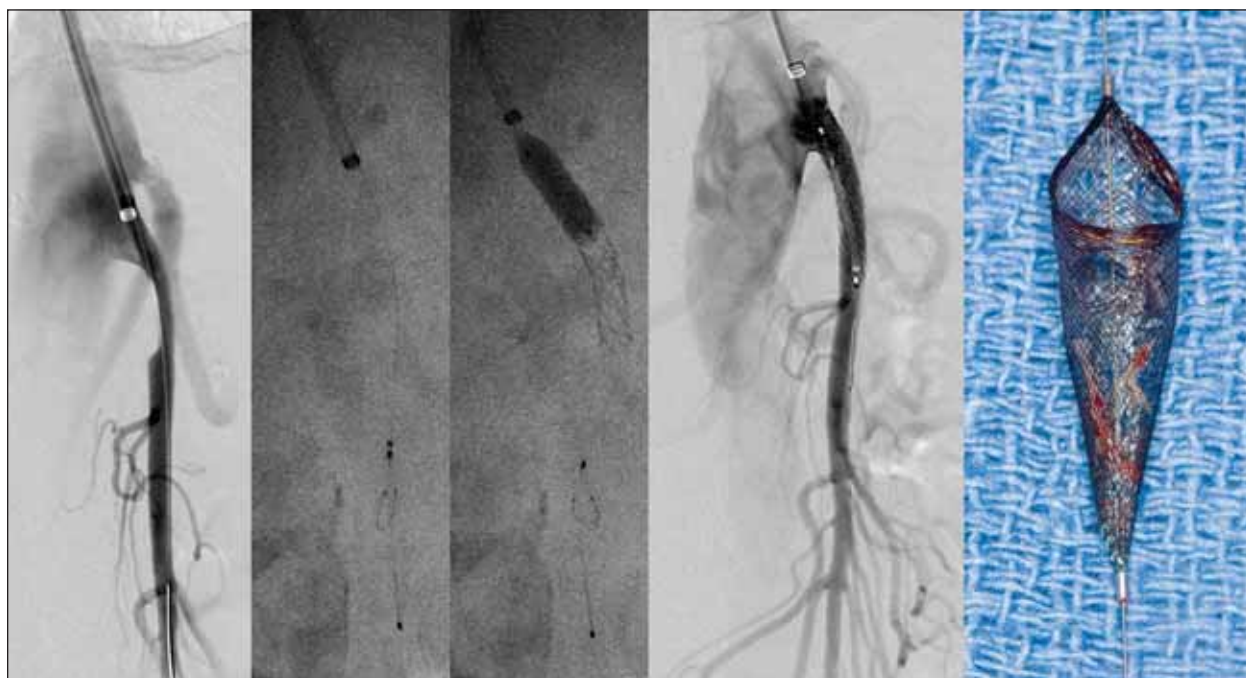


Figure 1. Superior mesenteric artery angioplasty and stent placement with use of a Spider RX embolic protection device (ev3 Inc., Plymouth, MN) in a patient with high-grade stenosis. Significant debris is retrieved in the filter.

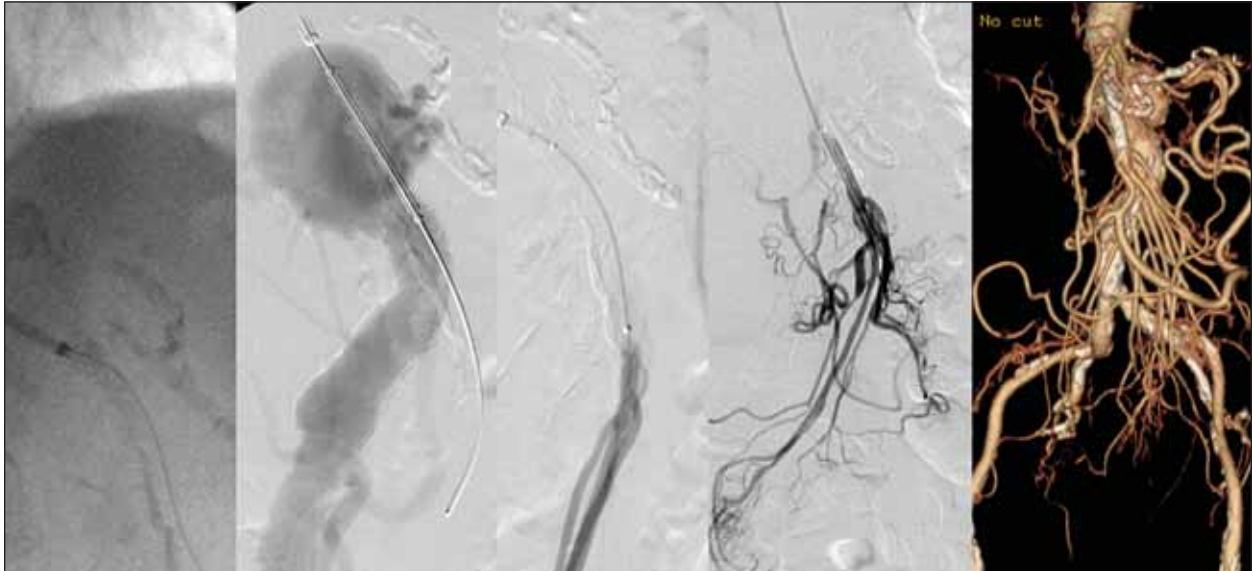


Figure 2. Recanalization of a long-segment superior mesenteric artery occlusion in a patient with severe mesenteric ischemia and a paravisceral aortic aneurysm.

1,300 cases per year, which can be largely attributed to improved diagnoses, better imaging studies, and the introduction of a less-invasive alternative to open surgical bypass—mesenteric angioplasty and stenting (Figures 1 and 2). In fact, since 2002, mesenteric stenting has surpassed open surgical bypass as the primary modality of treatment for CMI in the United States. The overall mortality rate for all revascularization procedures has steadily decreased from an average of approximately 15% in 1988 to 5% in 2006, and the mortality rate in this study was 3.7% for angioplasty and stenting and 15% for surgical bypasses.

The interpretation of treatment guidelines for CMI based on the available literature is difficult for several reasons.¹

First, results of surgical bypass (in healthier patients) and mesenteric stenting (in sicker patients) are not comparable. Second, some reports have small patient numbers treated over long time periods or patients with acute and chronic presentations with a variety of etiologies, such as arteritis and median arcuate ligament syndrome. Third, reporting standards are inconsistent, with no uniform definition of technical success after endovascular revascularization and lack of objective patency determination in several studies.

We have recently reviewed our results at the Mayo Clinic with 229 consecutive patients treated for atherosclerotic CMI (146 open revascularization and 83 endovascular revascularization) and analyzed outcomes according to clinical

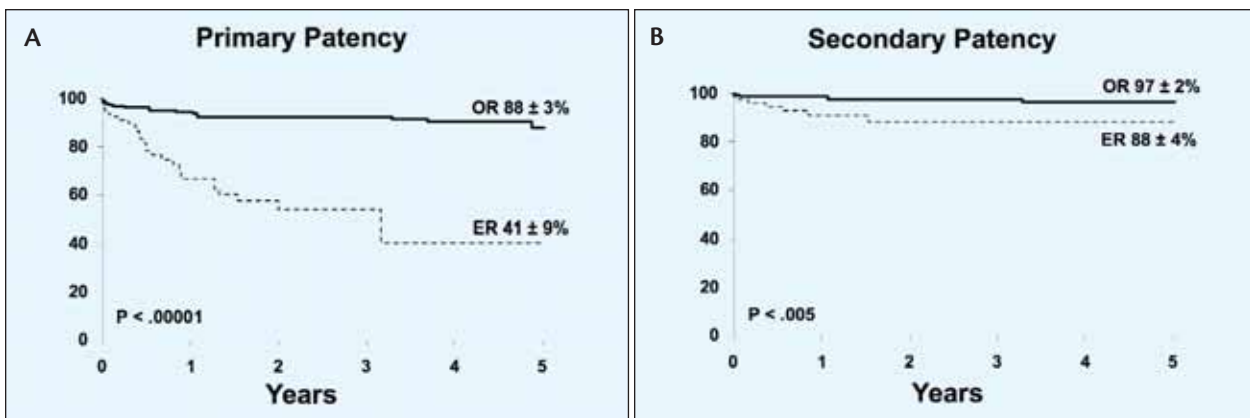


Figure 3. Kaplan-Meier survival estimates of primary (A) and secondary (B) patency rates in a large series of patients with CMI treated with endovascular (ER) or open revascularization (OR). Adapted from Oderich GS, Bower TC, Sullivan TM, et al. Open versus endovascular revascularization for chronic mesenteric ischemia: risk-stratified outcomes. *J Vasc Surg*. 2009;49:1472-1479.³

risk stratification.³ As expected, there were more high-risk patients in the endovascular group (58% vs 31%), but the demographics, cardiovascular risk factors, and presentation were comparable when the low- and high-risk subsets were analyzed separately. The overall mortality rates were 2.6% with four (2.7%) deaths after open revascularization (three of four were high risk) and two (2.4%) after angioplasty or stenting (both high risk). Importantly, the mortality rate for surgical bypass was only 0.9% (1/101) in the low-risk subset, which shows that these operations can be performed safely in tertiary care centers. Both treatment modalities resulted in excellent symptom relief in 97% of patients. The main disadvantage of surgical bypass was a higher rate of complications as compared to endovascular procedures (36% vs 18%), both in low-risk (37% vs 10%) and high-risk subgroups (38% vs 18%), especially due to more cardiac (10% vs 2%) and pulmonary problems (15% vs 1%). Freedom from recurrent symptoms at 5 years was higher ($P < .001$) in the open as compared to the endovascular group ($89\% \pm 4\%$ vs $51\% \pm 9\%$), and cumulative primary and secondary patency rates at 5 years were higher for bypasses compared to angioplasty or stenting ($88\% \pm 3\%$ and $97\% \pm 2\%$ vs $41\% \pm 9\%$ and $88\% \pm 4\%$; $P < .005$) (Figure 3).

However, despite a higher reintervention rate after mesenteric angioplasty or stenting, 95% of these patients reported symptom improvement in their last follow-up visit.

Treatment of CMI has evolved substantially during the last 2 decades, and national and institutional data show an increasing number of endovascular interventions and better outcomes. Currently, mesenteric angioplasty and stenting is the primary modality of treatment for CMI, primarily because of the advantage of early recovery with excellent symptom improvement. However, open surgical bypass can be performed safely and may be a better option in good-risk patients with unsuitable lesions (long occlusions or severe calcification). ■

This article was previously published in the VIVA Today coverage of the 2009 Vascular Interventional Advances meeting.

Gustavo S. Oderich, MD, is Associate Professor of Surgery in the Division of Vascular and Endovascular Surgery at the Mayo Clinic in Rochester, Minnesota. He has disclosed that he is a paid consultant to and has his travel expenses paid for by Cook Medical. He further disclosed that he is a paid consultant to W. L. Gore & Associates. Dr. Oderich may be reached at (507) 284-1575; oderich.gustavo@mayo.edu.

1. Oderich GS, Malgor RD, Ricotta JJ II. Open and endovascular revascularization for chronic mesenteric ischemia: a tabular review of the literature. *Ann Vasc Surg.* 2009;23:700-712.
2. Schermerhorn ML, Giles KA, Hamdan AD, et al. Mesenteric revascularization: management and outcomes in the United States, 1988-2006. *J Vasc Surg.* 2009;50:341-348.
3. Oderich GS, Bower TC, Sullivan TM, et al. Open versus endovascular revascularization for chronic mesenteric ischemia: risk-stratified outcomes. *J Vasc Surg.* 2009;49:1472-1479.