

Supplement to

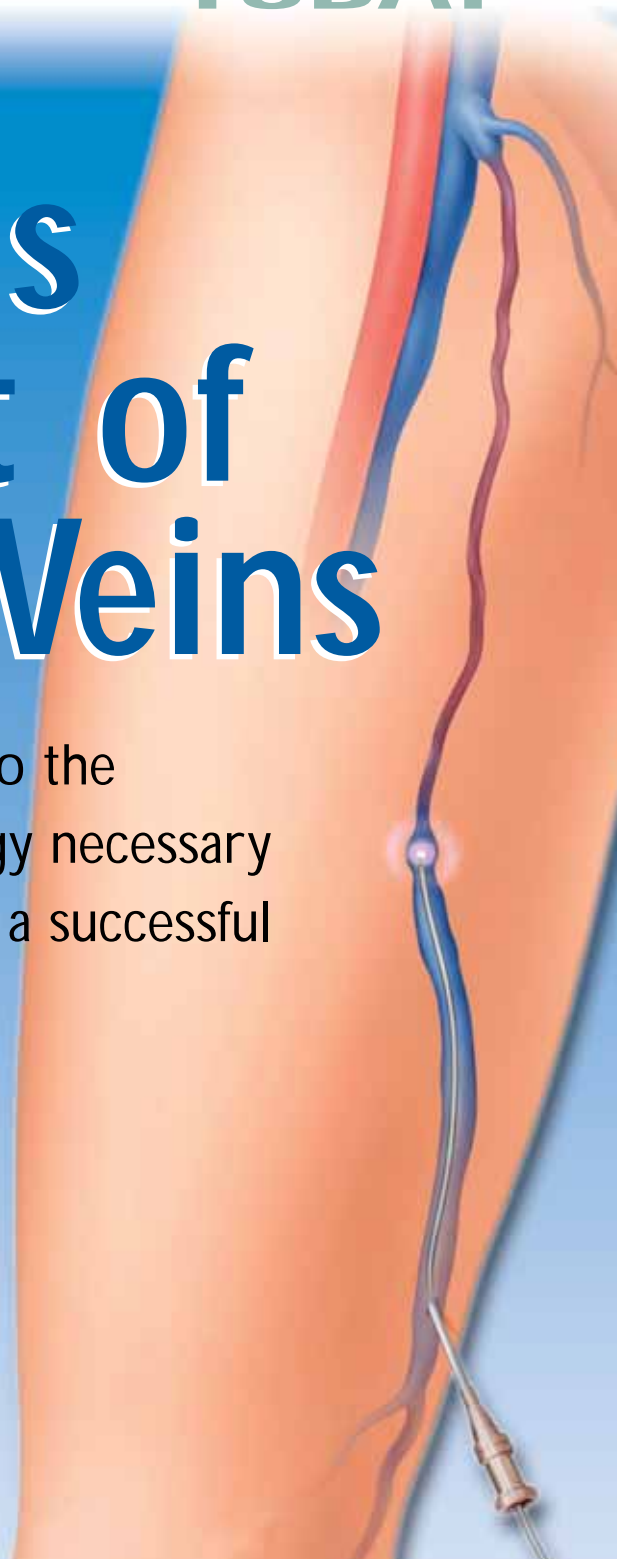
# Endovascular

## TODAY

November/December 2004

# Endovenous Treatment of Varicose Veins

A comprehensive guide to the techniques and technology necessary to establish and maintain a successful venous practice.



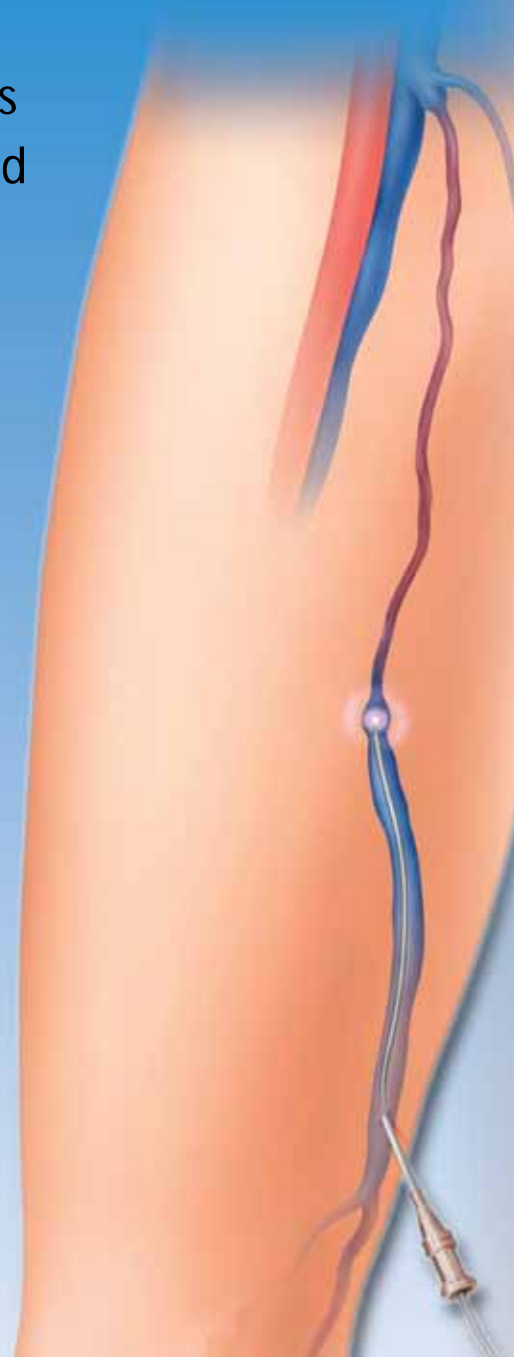# Endovenous Treatment of Varicose Veins

A comprehensive guide to the techniques and technology necessary to establish and maintain a successful venous practice.

Venous insufficiency is a common medical condition, with varicose veins and/or telangiectasias present in tens of millions of people in the US. In addition to causing symptoms such as leg pain, superficial venous insufficiency can progress to cause complications of venous hypertension including skin ulceration, even in the absence of deep venous disease. Despite its disabling nature, many who suffer from venous insufficiency are inadequately evaluated and incorrectly managed. Fortunately, advancements in noninvasive evaluation have improved our understanding of venous disease, and the development of new treatments now offers less invasive and safer options for its sufferers.

Leaders in the treatment of venous disease have contributed to this supplement to *Endovascular Today*, which has been created to provide a current overview of superficial venous insufficiency. It is our hope that continued advancement in the understanding and treatment of venous disorders will help prevent many of the complications arising from venous disease and reduce much of the morbidity and socioeconomic cost resulting from this extremely prevalent but often poorly understood condition.

—Robert J. Min, MD



# Contents

## 4 Duplex Ultrasound Imaging of Superficial Venous Insufficiency

This imaging modality is an essential component of the EVLT procedure.

*By Neil M. Khilnani, MD*

## 8 EVLT® of the GSV

Experience in 376 patients using EVLT of the GSV and miniphelebectomy for collateral varicose veins.

*By Moises Roizental, MD, and Carlos F. Fernández, MD*

## 11 EVLT® of the SSV and Other Truncal Veins

Two centers' clinical experiences using an 810-nm diode laser.

*By Robert J. Min, MD, Moises Roizental, MD, and Carlos F. Fernández, MD*

## 15 RFA Versus Laser Ablation of the Saphenous Vein

The era of minimally invasive surgery has brought new developments in the treatment of chronic venous disease.

*By Jose I. Almeida, MD, FACS*

## 20 EVLT® for Venous Ulcer

A case report confirming the benefit of EVLT in healing venous ulcers and prevention of recurrence.

*By Alessandra Puggioni, MD; Manju Kalra, MBBS; William J. Charboneau, MD; and Peter Gloviczki, MD*

## 23 Treatment of Leg Veins

An introduction to ambulatory phlebectomy, sclerotherapy, and cutaneous laser/light treatment of leg veins.

*By Steven E. Zimmet, MD*

## 28 Credentialing, Quality Control, and Education

Endovenous procedures have been established as important treatment options; now we must work to create the appropriate measures to maintain their safety and efficacy.

*By Peter Gloviczki, MD*

## 31 Establishing a Successful Vein Practice

A few tips on how to go about developing your vein practice.

*By Steve Elias, MD*

## 34 Reimbursement: Coding, Coverage, and Payment

How Medicare and insurance reimbursement policies adapt to incorporate novel therapies such as EVLT.

*By Catherine Morris, RN, BSN, CCM, MHSA*

# Duplex Ultrasound Imaging of Superficial Venous Insufficiency

This imaging modality is an essential component of the EVLT procedure.

BY NEIL M. KHILNANI, MD

**C**linical evaluation based solely on the distribution of a venous abnormality can suggest a pattern of incompetence. Unfortunately, different patterns of incompetence can result in a similar visual appearance of abnormalities. Therefore, treatment decisions based solely on the clinical evaluations, even those supplemented by a handheld directional Doppler, are often fraught with errors. Duplex ultrasound (DUS) is required to evaluate most patients with superficial venous insufficiency. It is advisable that all patients undergoing evaluation for varicose veins, edema, or venous skin changes (CEAP clinical stage 2-6) undergo an ultrasound of the superficial venous system to determine the pattern(s) of incompetence prior to making treatment recommendations.

## ANATOMY

The superficial venous system is composed of the saphenous veins, their primary branches, and their tributaries.<sup>1,2</sup> All of these veins are superficial to the deep or muscular fascia. The main trunks of the saphenous system are the great saphenous vein (GSV) and small saphenous vein (SSV). These trunks and some of the named tributaries of the GSV are actually intrafascial, deep to the superficial but still superficial to the deep fascia.

The GSV begins on the dorsum of the foot, ascending first anterior to the medial malleolus, and then along the inner thigh to ultimately join the femoral vein at the fossa ovale a few centimeters below the inguinal ligament. The GSV has two important tributaries in the calf and in the thigh. In addition, there are three smaller tributaries that join the GSV just prior to entering the fossa ovale (Figure 1). The saphenous veins and these important tributaries are connected to a complex network of collecting veins that drain the skin and subcutaneous tissues, as well as innumerable

able perforating veins that normally drain blood from the saphenous veins and their tributaries through the muscular fascia to the deep veins.

The SSV begins on the lateral foot, passes posterior to the lateral malleolus, and ascends the posterior calf.<sup>3</sup> This intrafascial vein will drain into the popliteal vein just above the popliteal crease in approximately 70% of patients. In most of the other patients, there is a cephalad extension of the SSV that usually drains to the deep veins through a posterior thigh perforating vein or to the GSV via a connection known as the vein of Giacomini.

On axial ultrasound, the SSV and GSV will have the

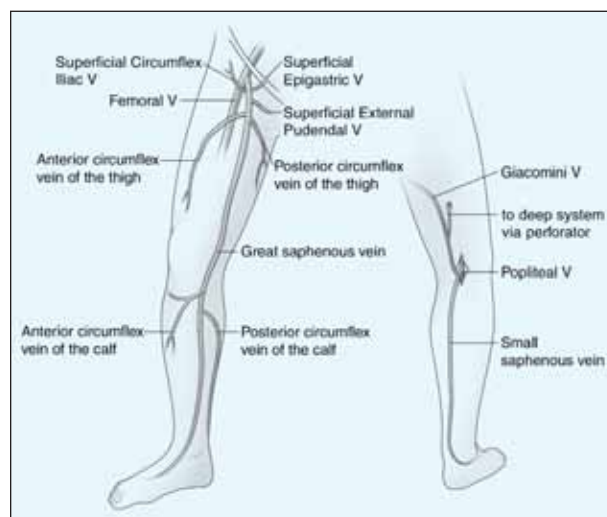
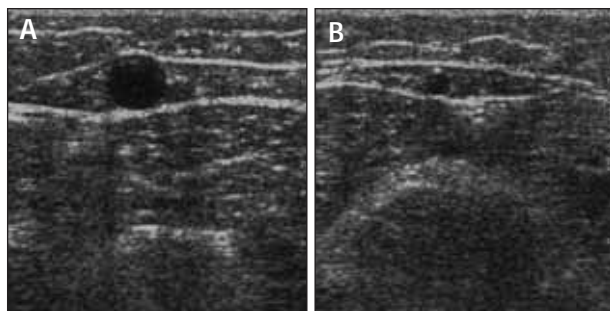


Figure 1. Frontal and posterior diagrams of the lower extremity demonstrating the great and small saphenous veins and their named tributaries. The two saphenous systems can be connected via the vein of Giacomini.



**Figure 2.** Axial DUS appearance of truncal veins. Two-dimensional DUS image of the thigh portion of enlarged refluxing GSV within the saphenous space. The anechoic central circle is the lumen of the GSV surrounded by fat in the saphenous space, which is demarcated by the curvilinear anterior and posterior portions of the saphenous fascia (A). DUS image of a normal diameter SSV at the level of the gastrocnemius muscles. The anechoic vein is also found in a saphenous space demarcated anteriorly and posteriorly by portions of the sheath (B).

appearance of Cleopatra's eye, or of the Seattle Seahawks helmet logo (Figure 2A and B). The vein will appear as the pupil outlined by the curvilinear saphenous space, which is separated from the surrounding tissues by the echogenic superficial and deep fascia. This appearance is helpful in distinguishing the truncal veins from more superficial tributaries.

### DUS TECHNIQUE

The equipment required to perform the examination of the superficial venous system is a linear 7.5- to 10-MHz transducer capable of displaying grayscale two-dimensional and pulse-wave Doppler (PWD) images. Color Doppler is a helpful feature that can make the examination more efficient, but it is not required.

When evaluating patients for reflux, the examination should be performed in the standing position. The reflux that leads to venous pathology can be reliably documented in this position. The examination begins at the saphenofemoral junction (SFJ). The GSV is followed from its junction down beyond the level of any visible varicose veins. The relationship of the GSV to any abnormal veins is assessed by tracing its course and the course of any tributaries that might lead to the abnormal veins. It is important to be aware of the standard tributary anatomy of the GSV and to recognize the frequent variations that are found.<sup>1,2</sup>

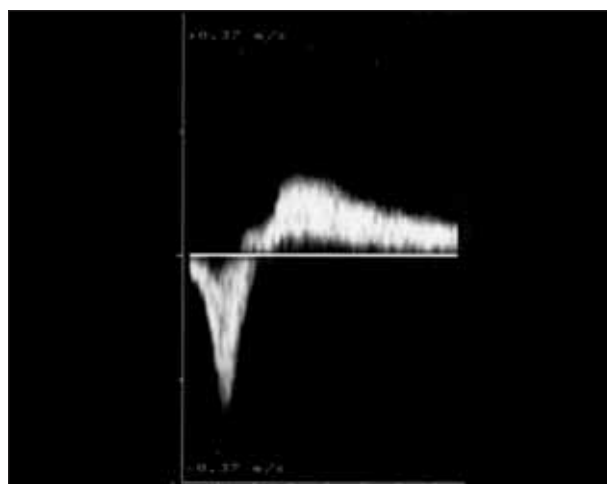
The caliber of the GSV is then assessed. Normally, the vein is  $\leq 4$  mm in diameter. Veins  $> 7$  mm have a high incidence of reflux. Reflux can occur in smaller veins, but even if found, it is usually clinically unimportant. Peripheral to the takeoff of incompetent tributary veins, the caliber of the vein often

decreases.

Any vein segment suspected of having reflux by size or by relationship to varicose veins is then evaluated with color Doppler and PWD to directly visualize the direction of flow. All suspicious segments should be examined with PWD. Reflux can be easily documented by looking for antegrade flow followed by retrograde flow after a quick, firm compression of a peripheral segment of the GSV. Generally, when evaluating the GSV, compression of the calf should lead to augmentation of antegrade venous flow. Upon release of compression, little if any retrograde flow should be noted. Reflux is documented when a significant amount of retrograde flow is found (Figure 3). Although the criteria of  $\geq 0.5$  second of retrograde flow has been used to identify pathological reflux, several seconds of retrograde flow is usually found in patients with incompetence.

Next, the patient is turned away from the examiner and the SSV is evaluated. The process of evaluation is similar to that of the GSV. The SSV normally measures  $\leq 3$  mm; enlarged veins are frequently incompetent. Finally, an evaluation of the femoral vein and the popliteal veins for reflux and obstruction should be included in the examination.

In some cases, DUS in patients with varicose veins will not identify truncal vein incompetence. These nontruncal pathways are much more common in multiparous women and



**Figure 3.** Pulse-wave Doppler imaging of an incompetent GSV segment is performed during and immediately after external compression of the extremity at a more peripheral location. Blood velocities on the y-axis are plotted against time on the x-axis. Augmentation of flow toward the heart is normally seen with calf compression (velocities mapped below the x-axis). However, upon release of external compression, flow directed toward the feet is seen in incompetent segments (velocities above the x-axis). A normal vein may have  $\leq 0.5$  second of retrograde flow.



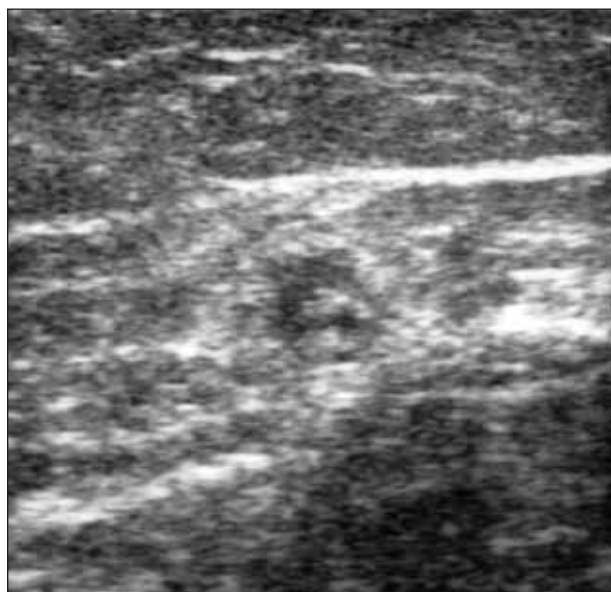


Figure 4. Axial image of the thigh GSV 10 days after EVTA. The vein is smaller in caliber than prior to treatment. It has a thick wall and a small, very hypoechoic lumen. This lumen had no flow when evaluated with DUS.

include pudendal and gluteal vein incompetence.<sup>4</sup> Other important sources of nontruncal reflux include incompetent perforating veins in the medial and lateral thigh and popliteal fossa, which can usually be identified with DUS. Occasionally, these sources, especially the pudendal source, can lead to GSV incompetence more peripherally in the leg, so it is worth completely examining the saphenous trunks in all patients.

#### DUS IN GUIDING ENDOVENOUS THERMAL ABLATION

Endovenous laser thermal ablation (EVLT) of the saphenous veins and their primary tributaries requires detailed US guidance to ensure a safe and successful outcome.<sup>5</sup> DUS is used first to identify the location for venous access, which is generally at the lowest or most peripheral level of the primary incompetent segment. Most operators also use real-time DUS to perform the venous access. After access, DUS is used to position the tip of a laser fiber at, or just below, the SFJ.<sup>1</sup> This is usually best done with a longitudinal projection. With the most commonly used technique for EVLT, a sheath is typically passed into the femoral vein. A laser fiber is then advanced to the tip of the sheath and the sheath is then withdrawn, exposing the laser fiber. Both the sheath and the fiber are withdrawn under DUS guidance. The laser fiber is depicted as an intraluminal echogenic line. The tip of the fiber is withdrawn into the GSV and positioned within 1

cm of the SFJ. Although a confident position can be established with US, confirmation with the red aiming beam is recommended.

Ultrasound is also necessary to guide the delivery of tumescent anesthesia (TA). TA is used not only to make the procedure painless but also to insulate the vein from surrounding nerves, arteries, and the skin, as well as to efface the lumen of the vein to maximize circumferential energy transfer to the vein wall. DUS guidance of the needle used to inject the TA fluid in the perivenous saphenous sheath is essential to maximize the effectiveness and efficiency of its delivery. A successful TA results in a perivenous hypoechoic halo that obliterates the vein lumen from the puncture site to the highest end of the treated segment. Finally, DUS can confirm the location of the laser fiber when it is first activated by observing the creation of steam, which only occurs at its tip.

DUS should always be performed to evaluate the treated vein segments periodically after EVTA.<sup>5,6</sup> This is generally done in the first few weeks after therapy, a few months later, and at yearly intervals. DUS should also be performed to evaluate for the cause of any recurrent varicose veins. In the first several weeks after therapy, the treated veins will either be smaller or the same size as prior to treatment, with a thick wall and nearly obliterated lumen (Figure 4). There should be no flow in the entire treated vein segment. After several months to a year, successfully treated vein segments will usually be difficult to identify or significantly smaller than the vein prior to treatment and will have no flow.<sup>5,6</sup>

#### CONCLUSIONS

All patients with CEAP class 2 to 6 venous insufficiency require a careful DUS examination to identify the pathway of reflux leading to the presenting abnormalities and symptoms. DUS is necessary to guide multiple parts of the EVLT procedure and periodic DUS is necessary to follow the outcomes of this form of treatment. ●

*Neil M. Khilnani, MD, is from Cornell Vascular, Weill Medical College of Cornell University, New York, New York. Dr. Khilnani may be reached at (212) 752-7999; nmkhilna@med.cornell.edu.*

1. Min RJ, Khilnani NM, Golia P. Duplex ultrasound evaluation of lower extremity venous insufficiency. *J Vasc Interv Radiol.* 2003;14:1233-1241.
2. Caggiati A, Bergan JJ, Gloviczki P, et al. Nomenclature of the veins of the lower limbs: an international interdisciplinary consensus statement. *J Vasc Surg.* 2002;36:416-422.
3. Caggiati A. Fascial relationships of the short saphenous vein. *J Vasc Surg.* 2001;34:241-246.
4. Labropoulos N, Tiongson J, Pryor L, et al. Nonsaphenous superficial venous reflux. *J Vasc Surg.* 2001;34:872-877.
5. Min RJ, Khilnani NM, Zimmett SE. Endovenous laser treatment of saphenous vein reflux: long-term results. *J Vasc Interv Radiol.* 2003;14:991-996.
6. Pichot O, Kabnick LS, Creton, D, et al. Duplex ultrasound scan findings two years after great saphenous vein radiofrequency endovenous obliteration. *J Vasc Surg.* 2004;39:189-195.

# EVLT<sup>®</sup> of the GSV

Experience in 376 patients using EVLT of the GSV and miniphlebotomy for collateral varicose veins.

BY MOISES ROIZENTAL, MD, AND CARLOS F. FERNÁNDEZ, MD

Although half of the adult population has some symptoms of venous disease, 20% to 25% of women and 10% to 15% of men have visible varicose veins.<sup>1</sup> Risk factors include female sex, increased age, pregnancy, geographical site, and race. Although many people seek medical treatment for varicose veins for cosmetic reasons, most people with varicose veins also experience symptoms that include pain or discomfort.<sup>2-4</sup> In 1999, Boné<sup>5</sup> first reported on the delivery of endoluminal laser energy. Subsequently, in 2001, Navarro et al<sup>6</sup> published the first report of a minimally invasive method of treating the entire incompetent greater saphenous vein (GSV) segment using an 810-nm diode laser. The goal of this new treatment was to avoid the drawbacks associated with traditional surgical treatments for varicose veins, including increased risk associated with extensive anesthesia, increased cost of hospitalization, and possible complications from surgery.

Although other less-invasive techniques, such as sclerotherapy, miniphlebotomy, ultrasound- and transcatheter-guided sclerotherapy, as well as monopolar and bipolar radio frequency are being utilized in the treatment of truncal varicosities, these procedures have varied results. Endovenous laser treatment (EVLT) with the 810-nm diode laser (Diomed, Inc., Andover, MA) allows delivery of laser energy directly into the blood vessel lumen (Figure 1).<sup>7</sup>

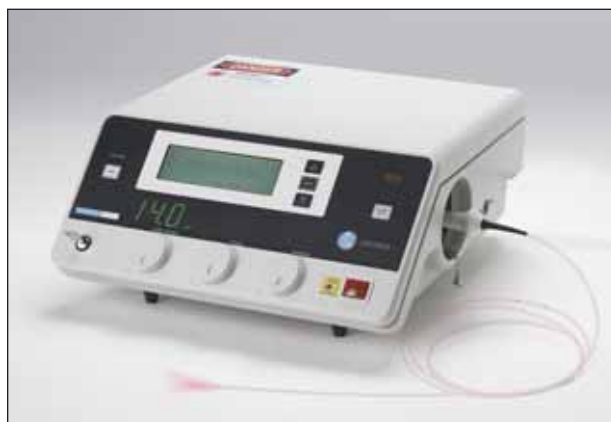

Figure 1. The Diomed D15plus 810-nm diode laser.

Nonthrombotic vein occlusion is accomplished by heating the vein wall via a laser fiber. Sufficient heating of the vein wall is necessary to cause collagen contraction and denudation of endothelium. This stimulates vein wall thickening, eventual luminal contraction, and fibrosis of the vein. This article describes a large cohort of patients treated by two physicians (an interventional radiologist and a vascular surgeon) in a private practice in Caracas, Venezuela.

## MATERIALS AND METHODS

Otherwise unselected patients of all clinical stages presented for routine evaluation at one clinic with two physicians. Three hundred seventy-six patients underwent EVLT of incompetent GSV segments with the 810-nm diode laser delivered intraluminally via a 600- $\mu$ m core fiber for treatment of primary varicose veins. All patients gave written informed consent before treatment.

## Patient Selection

Directed history and physical examination, including duplex ultrasound (US) evaluation of the superficial venous system, was performed on limbs of subjects with varicose veins. Inclusion criteria included varicose veins caused by sapheno-femoral junction incompetence with GSV reflux as demonstrated by duplex US imaging, and at least 18 years of age. Exclusion criteria included nonpalpable pedal pulses; inability to ambulate; deep vein thrombosis; general poor health; pregnancy, nursing, or plans to become pregnant immediately after the treatment; and extremely tortuous GSVs that would not allow endovenous catheterization and passage of the laser fiber as identified on pretreatment venous duplex US mapping. After initial examination and consultation, patients meeting the selection criteria were offered the choice of surgery or EVLT. Nearly all patients chose EVLT over surgical ligation and stripping.

Four hundred five incompetent GSVs were treated with EVLT during a 2-year period. The population treated was 82% (332 of 405) female and 18% (70 of 405) male, with a mean age of  $52.8 \pm 13.2$  years (range, 18-80 years). The pre-operative CEAP scores were as follows: 0.3% (1 of 386) had

a preoperative CEAP score of 2, 45.9% (177 of 386) had a preoperative CEAP score of 3, 40.9% (158 of 386) had a CEAP score of 4, 7.8% (30 of 386) had a CEAP score of 5, and 5.2% (20 of 386) had a preoperative CEAP score of 6. Preoperative CEAP score was not reported for 19 cases. Overall, slightly more left legs (51.1%; 207 of 405) were treated, and 29 patients were treated bilaterally. Six limbs (0.2%) were retreated during the follow-up period.

Pretreatment GSV diameter, measured in the upright position in the most dilated segment of the GSV, ranged from 3 mm to 21 mm, with a mean of  $6.7 \pm 3.2$  mm. Follow-up examinations were conducted at 1 week, 1 month, and 3 months postoperatively.

### Technique

Generally, the procedure was performed as already described.<sup>7</sup> In brief, duplex US was performed, and a percutaneous entry point was chosen where reflux was no longer seen or where the GSV becomes too small to access, usually around knee level. With the use of local anesthesia and sonographic guidance, the GSV was punctured. A 5-F introducer sheath was placed into the GSV over a guidewire and advanced past the SFJ into the femoral vein. Intraluminal position within the GSV was confirmed by aspiration of nonpulsatile venous blood and visualization with US. In the case of small veins (>5 mm), a micropuncture technique in which a 21-gauge needle and an .018-inch wire were used to enter the vein.

A 600- $\mu$ m laser fiber was introduced into the sheath and advanced to the first site mark. The sheath was then withdrawn to the second site mark, exposing the distal 3 cm of the bare-tipped laser fiber. The sheath and fiber were pulled back together and positioned at the SFJ under US guidance. Position was confirmed by direct visualization of the red aiming beam of the laser fiber through the skin.

Tumescent local anesthesia, consisting of 100 mL to 200 mL of 0.2% lidocaine neutralized with sodium bicarbonate, was administered along the perivenous space with use of US guidance. The tip of the laser fiber was repositioned within the GSV 5 mm to 10 mm distal to the SFJ. Tip position was checked by US and direct visualization of the red aiming beam through the skin. Laser energy was delivered using the 810-nm diode laser using 14 W in continuous mode. In one case, the doctor inadvertently treated the patient with 5 W, and the treatment was unsuccessful. The total energy delivered ranged from 250 J to 2,965 J, with a mean of  $1,350 \pm 320.7$  J. The vein was treated from 5 mm to 10 mm below the SFJ to approximately 1 cm above the skin entry site. The length of GSV treated with endovenous laser ranged from 7 cm to 60 cm ( $30.1 \pm 11.5$  cm). The laser fiber was withdrawn at an average rate of 2.2 mm per second.

All patients in this series underwent concomitant miniphlebotomy using a crochet device done through a 2-mm skin cut to remove the dilated collateral veins immediately after the endovascular laser ablation was completed. We believe that performing the miniphlebotomy immediately after the EVLT leads to a better cosmetic outcome.

A class II (30-40 mm Hg), full-thigh, graduated support stocking or pantyhose was worn for at least 1 week at all times, except to sleep or shower. Patients were instructed to ambulate and resume their normal daily activities immediately.

Follow-up examinations were performed at 1 week, 1 month, 3 months, and 6 months, including duplex US. After the initial 290 patients were examined at 6 months, the 6-month examination was discontinued because the results were essentially unchanged from the 3-month examination.

### RESULTS

The procedure was a technical success in 98.5% (399 of 405) of cases and was a failure, or could not be completed, in 1.5% (6 of 405) cases. In three cases (0.7%), the procedure could not be completed because of a tortuous vein; in one case (0.2%) there was severe spasm. In one case (0.2%), the procedure was postponed for unspecified reasons, and in another case (0.2%), the laser unit was not functioning properly.

Successful EVLT, as defined by complete occlusion of the GSV by Doppler US, was seen in 100% (399 of 399) limbs at the 1-week follow-up (Figure 2). All veins remained closed at the 1-month follow-up examination, with the exception of two cases (0.5%). At the 3-month examina-

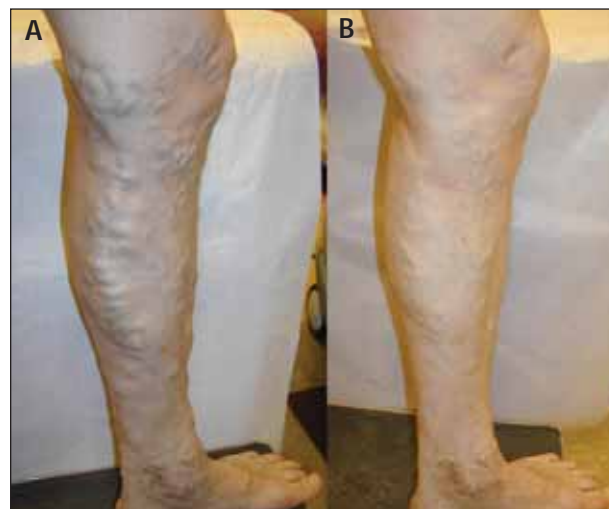

Figure 2. Before (A) and 1 week after (B) EVLT.

(Courtesy of Robert Min, MD, Cornell Vascular)



tion, 97.7% (390 of 399) had a successful outcome. Of the 290 cases examined at 6 months postoperatively, 96.2% (279 of 290) were successful. Six of 399 (1.5%) limbs that were symptomatic and required repeat EVLT due to reflux within the treated GSV were successfully closed with a second EVLT. The other 15 cases that showed an open GSV during follow-up were asymptomatic, and Doppler US showed no significant reflux within a smaller GSV.

Ecchymosis and mild-to-moderate thigh pain were the most common presenting symptoms during the first week and were easily treated with medication. In addition, the following complications occurred after the EVLT procedure: one case (0.3%) of deep vein thrombosis secondary to May-Thurner syndrome required endovenous thrombolysis and stent placement at the left common iliac vein, one (0.3%) thigh hematoma required percutaneous draining, seven cases (1.8%) of superficial phlebitis at the miniphlebectomy site treated medically with no further complications, and 12 patients (3.0%) with local transient paresthesia at a miniphlebectomy site improved spontaneously in 10 of 12 cases.

## DISCUSSION

This study confirms previously published reports that endovenous laser ablation of an incompetent GSV can provide outcomes equal to or better than traditional surgical ligation and stripping.<sup>7</sup> Some practitioners advocate ablating the GSV and treating remaining visible varicosities with sclerotherapy during subsequent follow-up visits. Our chosen protocol is to perform EVLT and remove all varicose veins with microphlebectomy at the same time. Both procedures are done under local anesthesia, often with conscious sedation, and we find that this is well tolerated by patients who prefer complete resolution with just one visit. Our approach mirrors past protocols in which we surgically removed the incompetent GSV in combination with hook phlebectomy. However, unlike our past approach, EVLT does not require an operating room or present the inherent risks associated with general, nor does it require spinal anesthesia. Furthermore, patients experience far less postprocedural pain, no scars, and a recovery time of days rather than weeks.

Venous insufficiency is a genetically influenced, chronic, and progressive disorder, and the ultimate goal of any treatment regimen is to eliminate primary sources of reflux to bring symptoms and progression of disease under control and to extend the time before recurrent varicosities may appear. Although our study does not provide a randomized comparison between EVLT with miniphlebectomy and surgical stripping with stab avulsion, based upon our experience with both approaches, we believe our

results indicate that endovenous ablation offers better "reflux-free" rates than conventional surgery. This is not surprising because we are treating the highest point of reflux as demonstrated by duplex US. Unlike surgery, EVLT does not appear to allow neovascularization at the groin, nor is there a risk of leaving behind a refluxing segment in the thigh.

We did observe some open GSVs after the EVLT procedure (detection of blood flow). However, these veins were noticeably smaller, and in all cases, patients were symptom-free without recurrent varicose veins. As a possible explanation, it could be that shrinking a refluxing vein to a smaller diameter allowed valves to completely or partially close, thus decreasing or eliminating reflux.

## CONCLUSION

The application of EVLT has allowed us to expand our understanding of the nature and pathophysiology of venous disease, and percutaneous techniques for ablating incompetent veins are now being expanded to treat other veins, such as accessory saphenous, lesser saphenous, anterior lateral tributary, and retained refluxing segments of the GSV. By attacking the root of the problem, we can provide patients with a superior alternative to ligation and stripping without the morbidities associated with surgery and general anesthesia. To ensure the best results and patient safety, it is imperative that physicians considering performing EVLT are very well trained in the complexities of venous anatomy and proper administration of minimally invasive techniques. Most important is the need for training in the use of duplex US as a diagnostic tool. ●

*Moises Roizental, MD, is an interventional radiologist at Policlínica Metropolitana, Caracas, Venezuela. He has disclosed that he is a paid consultant of Diomed. Dr. Roizental may be reached at 011 908 06 87; mroizental@cantv.net.*

*Carlos F. Fernández, MD, is a vascular surgeon at Policlínica Metropolitana, Caracas, Venezuela. He has disclosed that he is a paid consultant of Diomed. Dr. Fernández may be reached at carlosefe@cantv.net.*

1. Callam MJ. Epidemiology of varicose veins. *Br J Surg* 1994;81:167-173.
2. Rose SS. Anatomic observations on causes of varicose veins. In: Goldman MP, Weiss RA, Bergan JJ, eds. *Varicose veins and telangiectasia: diagnosis and treatment*. St. Louis, MO: Quality Medical Publishing, 1999:12-17.
3. Goldman M. Pathophysiology of varicose veins. In: Goldman M, ed. *Sclerotherapy: treatment of varicose and telangiectatic leg veins*. St. Louis, MO: Mosby-Year Book, 1995:85-117.
4. Weiss RA, Weiss MA. Resolution of pain associated with varicose and telangiectatic leg veins after compression sclerotherapy. *J Dermatol Surg Oncol*. 1990;16:333-336.
5. Boné C. Tratamiento endoluminal de las varices con laser de diodo: estudio preliminar. *Rev Patol Vasc*. 1999;5:35-46.
6. Navarro L, Min RJ, Bone C. Endovenous laser: a new minimally invasive method of treatment for varicose veins—preliminary observations using an 810 nm diode laser. *Dermatol Surg*. 2001;27:117-122.
7. Min RJ, Khilnani N, Zimmet SE. Endovenous laser treatment of saphenous vein reflux: long-term results. *J Vasc Interv Radiol*. 2003;14:991-996.

# EVLT<sup>®</sup> of the SSV and Other Truncal Veins

Two centers' clinical experiences using an 810-nm diode laser.

BY ROBERT J. MIN, MD, MOISES ROIZENTAL, MD, AND CARLOS F. FERNÁNDEZ, MD

**L**ower-extremity venous insufficiency is a common medical condition afflicting 20% to 25% of women and 10% to 15% of men.<sup>1</sup> Although great saphenous vein (GSV) reflux is the most common underlying cause of significant varicose veins,<sup>2</sup> the impact of incompetence of the small saphenous vein (SSV) system is also significant.<sup>3</sup> Leg symptoms caused by incompetence of the SSV system are similar to those reported due to GSV reflux and include aching, burning, itching, heaviness, cramps, and restless limbs. Chronic venous insufficiency, including skin ulceration, can be caused solely by superficial venous disease. Although much work has been published regarding endovenous laser treatment (EVLT) of the GSV with the 810-nm diode laser,<sup>2,4-6</sup> this article is the first, to our knowledge, that addresses EVLT of non-GSV truncal reflux including the SSV, anterior accessory great saphenous vein (ASV), and posterior thigh circumflex vein (PTC) with the 810-nm diode laser (Figure 1).

This article reports on two groups of subjects: group 1 subjects were treated by one operator at Cornell Vascular in New York; group 2 subjects were treated by two operators in private practice in Caracas, Venezuela.

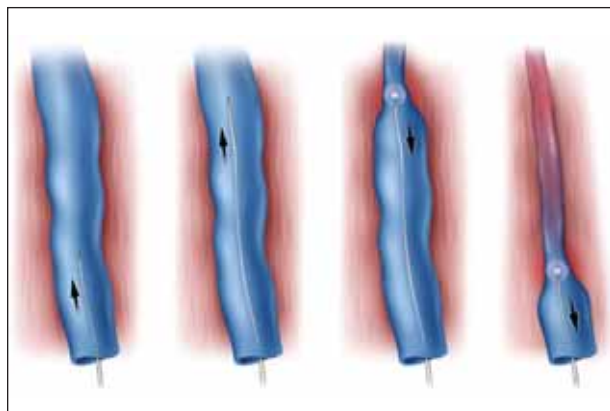


Figure 1. Endovenous laser ablation.

*"Chronic venous insufficiency, including skin ulceration, can be caused solely by superficial venous disease."*

## MATERIALS AND METHODS

### Group 1

All subjects were consecutively treated with EVLT for refluxing veins in the superficial venous system, including significant tributaries and saphenous veins, during a 4-year period and met the inclusion and exclusion criteria included in this analysis. All subjects gave written informed consent before treatment. Directed history and physical examination, including duplex ultrasound evaluation of the superficial venous system, was performed on the limbs of subjects with varicose veins.

Inclusion criteria included patients with varicose veins associated with reflux in the superficial venous system, as demonstrated by duplex ultrasound, including but not limited to reflux in the SSV, ASV, PTC, or other truncal varicosities; age of at least 18 years; and a willingness to sign a written informed consent form. Exclusion criteria included inability to ambulate, deep vein thrombosis, nonpalpable pedal pulses, generally poor health, and pregnancy or nursing.

One hundred eighty-eight subjects were treated by EVLT with the Diomed 810-nm diode laser (Andover, MA) delivered intraluminally via a 600- $\mu$ m core fiber. In 43.1% (81 of 188) of cases, the treatment was of the SSV; in 50.5% (95 of 188) of cases, the ASV was treated; and in 6.4% (12 of 188) of cases, the PTC was treated. During the follow-up period, retreatments were performed in 3.7% (3 of 81) of the SSV cases, in 3.2% (3 of 95) of ASV cases, and in 8.3% (1 of 12) of the PTC cases.

One hundred fifty-three of 188 (81.4%) patients were female, and 18.6% (35 of 188) were male. The patients ranged in age from 23 to 76 years, with a mean of  $46.0 \pm 10.3$  years. The right leg was treated in 52.7% (99 of 188) of cases, and the left leg was treated in 47.3% (89 of 188) of cases.

*"The procedure for endovenous ablation of the GSV is well established and, by following similar protocols, other sources of primary reflux can be treated with this technique."*

Leg pain was present preoperatively in 87.7% (71 of 81) of the SSV cases, in 86.3% (82 of 95) of the ASV cases, and in 75% (9 of 12) of the posterior medial tributary cases. Preoperatively, the mean diameter of the vein was  $9 \pm 3.6$  mm in the SSV group (ranging from 4 mm to 20 mm),  $9.5 \pm 4$  mm in the ASV group (ranging from 3.9 mm to 32 mm), and  $8.6 \pm 2.9$  mm (ranging from 5.3 mm to 14 mm) in the PTC group.

## Group 2

All subjects consecutively treated with EVLT for reflux of the SSV during a 1-year period and who met the inclusion and exclusion criteria are included in this analysis. All subjects gave written informed consent before treatment. Directed history and physical examination, including duplex ultrasound evaluation of the superficial venous system, was performed on the limbs of subjects with varicose veins.

Inclusion criteria included patients with varicose veins associated with reflux in the SSV as demonstrated by continuous wave doppler and/or duplex ultrasound, at least 18 years of age, and a willingness to sign a written informed consent. Exclusion criteria included inability to ambulate, deep vein thrombosis (DVT), generally poor health, and patients who were pregnant or nursing or planning to become pregnant during the follow-up period.

Thirty-one legs in 31 subjects were treated by means of EVLT using the Diomed 810-nm diode laser delivered intraluminally via a 600- $\mu$ m core fiber. No retreatments occurred during the follow-up period. The patients ranged in age from 30 to 76 years, with a mean age of  $50 \pm 14.2$  years. The right leg was treated in 71% (22 of 31) of cases and the left leg was treated in 29% (9 of 31) of cases. Preoperatively, the mean diameter of the vein

was  $5.2 \pm 2$  mm, ranging from 3 mm to 10 mm.

## DESCRIPTION OF TECHNIQUE

### Group 1

The procedure for endovenous ablation of the GSV is well established and, by following similar protocols, other sources of primary reflux can be treated with this technique. An example is given here for ablation of the SSV. With the patient in a standing position, the incompetent SSV is marked from the access point to the highest source of reflux. The entry is usually at the level where the last incompetent tributary vein joins the SSV and below which point the SSV is normal in caliber and regains competence. The origin of reflux is most often just above the knee crease at the saphenopopliteal junction (SPJ); however, normal variant termination of the SSV (ie, into a posterior thigh perforator or vein of Giacomini) is not uncommon and must be noted on duplex examination.

Percutaneous access is obtained in the SSV using ultrasound guidance. A 5-F sheath is advanced to the SPJ over a .035-inch guidewire. The distal tip of the sheath should be positioned at the SPJ. A 600- $\mu$ m optical laser fiber is advanced into the sheath up to the first SiteMark (Diomed, Inc.) (Figure 2). The sheath is pulled back to expose 3 cm of the fiber outside the distal end of the sheath. Using ultrasound visualization and observation of the red aiming beam, the fiber tip is positioned 10 mm to 15 mm below the SPJ. Diluted (0.1%) lidocaine tumescent anesthesia is administered in the perivenous space surrounding the SSV. This local anesthesia will compress the vein, provide analgesia, and protect adjacent tissues from heat. Accurate position of the fiber tip

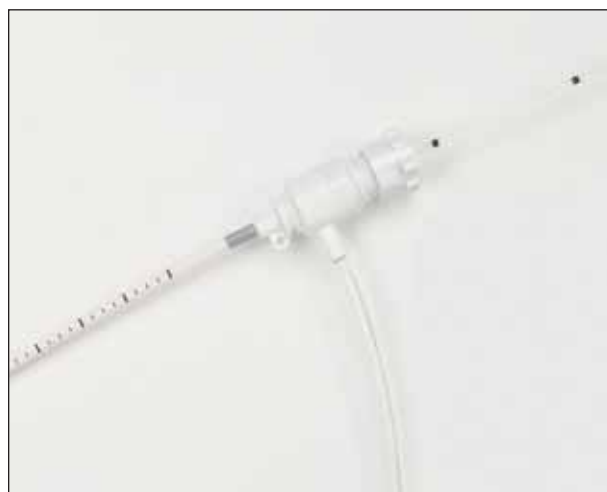

Figure 2. Diomed's marked sheath aids pullback rate, and SiteMarks on the optical fiber ensure accurate placement.

10 mm to 15 mm below the SPJ is confirmed. The 810-nm diode laser is set to 14 W continuous, and the fiber and sheath are withdrawn together at a rate of 1 mm to 3 mm per second.

The average laser administration time was  $77.2 \pm 24.8$  seconds for SSV treatments (ranging from 25 to 122 seconds),  $85 \pm 28$  seconds for ASV treatments (ranging from 35 to 196 seconds), and  $114 \pm 56$  seconds for PTC treatments (ranging from 56 to 234 seconds). The average length of vein treated was  $16.1 \pm 5.1$  cm for SSV treatments (ranging from 8 to 25 cm),  $18 \pm 5.1$  cm for ASV treatments (ranging from 7 to 37 cm), and  $29 \pm 15$  cm for PTC treatments (ranging from 10 to 60 cm). The average total energy in joules (J) delivered per treatment was  $1,080.9 \pm 347.7$  J for SSV treatments (ranging from 350 to 1,708 J),  $1,196 \pm 386$  J for ASV treatments (ranging from 490 to 2,737 J), and  $1,852 \pm 789$  J for PTC treatments (ranging from 784 to 3,276 J). The laser fiber was withdrawn at an average rate of 2.2 mm per second.

*"Although GSV reflux is the most common underlying cause, other sources of truncal reflux often contribute to, or are the sole cause of, significant lower-extremity varicose veins."*

A class II (30-40 mm Hg), full-thigh, graduated support stocking or pantyhose was worn for a minimum of 1 week after the treatment. Patients were instructed to walk immediately after the procedure, and to continue their normal daily activities, with the exception of vigorous exercise.

## Group 2

Duplex ultrasound mapping of the vein to be treated was performed. The treatment area was marked and cleansed with povidone-iodine. Venous access was obtained using local anesthesia (0.1% lidocaine) and ultrasound guidance. Access was obtained using a micropuncture technique in which a 21-gauge needle and an .018-inch wire were used to enter the vein.

The surgical technique used was exactly as described for the group 1 patients. Laser energy was provided by the Diomed 810-nm diode laser using 14W in continuous mode.

The average laser administration time was  $49.9 \pm 16.5$  seconds, ranging from 15 to 77 seconds. The average length of vein treated was  $13.1 \pm 5.7$  cm (ranging from 5

to 35 cm). The average total J delivered per treatment was  $561.8 \pm 238.7$  J (ranging from 115 to 1,088 J). The laser fiber was withdrawn at an average rate of 2.2 mm per second.

A class II (30-40 mm Hg), full-thigh, graduated support stocking or pantyhose was worn for a minimum of 1 week after treatment. Patients were instructed to walk immediately after the procedure and to continue their normal daily activities, with the exception of vigorous exercise.

## RESULTS

### Group 1

Follow-up ranged from less than 1 month to 52 months, with a mean of  $21 \pm 14$  months. Success, as defined by no detectable flow by color duplex ultrasound interrogation, was seen in 96.3% (78 of 81) of SSV segments at the longest follow-up visit. Of the three cases that were not successful, all were retreated and were closed and considered successful at the longest follow-up examination after the retreatment, which ranged from 2 to 32 months.

Success was seen in 96.8% (92 of 95) of ASV segments at the longest follow-up visit. Of the three cases that were not successful, all were retreated and successfully closed at the longest follow-up examination after the retreatment, which ranged from 8 to 33 months.

In the PTC group, success was 91.7% (11 of 12) at the longest follow-up visit. The one case that was not closed was retreated and was closed and successful at the longest follow-up examination after the retreatment, which was at 49 months. Varicose veins improved postoperatively in 100% (188 of 188) of cases treated. Of the subjects that had leg pain preoperatively, 100% (162 of 162) had improvement in their symptoms after treatment. Ecchymoses along the area of tumescent anesthesia administration were noted in most patients and was self-limiting after 2 weeks without treatment. Superficial phlebitis of associated tributary varicose veins was noted in 5% of cases and resolved with graduated compression and over-the-counter nonsteroidal anti-inflammatory medication (if needed) in all cases. There were no paresthesias, skin burns, DVTs, or other heat-related complications. There were no infections.

### Group 2

All patients were seen at 1 week, 1 month, and 3 months after the treatment. Thirty of 31 (96.8%) cases were completed successfully. In one case, there was a severe spasm that led to technical failure of the treatment.

Postoperative success, as defined by no detectable flow by color duplex ultrasound interrogation and continuous-



wave Doppler examination, was 100% (30 of 30) at the 1-week examination. At the 1- and 3-month examinations, 90% (27 of 30) of cases were successfully closed. Varicose veins improved postoperatively in 100% (30 of 30) of the cases successfully treated. In the one case in which treatment was not successfully performed, the varicose vein symptoms did not improve. Superficial phlebitis was noted in 3.3% (1 of 30) of cases. There were no paresthesias, skin burns, DVTs, or other heat-related complications. There were no infections.

*"More than 95% of SSVs, ASVs, and PTCs treated with EVLT were successfully closed with initial treatment."*

## DISCUSSION

Although GSV reflux is the most common underlying cause, other sources of truncal reflux often contribute to, or are the sole cause of, significant lower-extremity varicose veins. These non-GSV sources, including the SSV, ASV, and PTC, were traditionally treated with surgery or less-invasive techniques, such as ultrasound-guided sclerotherapy. Treatment of the SSV, in particular, has been challenging with existing options because of its close proximity to structures such as the sural nerve and sural artery, and the vessel's not uncommon variant termination into the deep venous system. These points remain important when considering minimally invasive treatments for SSV reflux.

Fortunately, advances in duplex ultrasound imaging now permit us to accurately and reliably map out all of the abnormal venous pathways and determine the origin(s) of reflux. Additionally, better understanding and utilization of tumescent anesthesia has also allowed safe and effective treatment of truncal reflux with EVLT. In addition to its role as an anesthetic, delivery of diluted lidocaine in the surrounding perivenous space will (1) compress even the largest diameter veins to ensure circumferential contact between the laser fiber and vein walls maximizing energy transfer, and (2) provide a fluid barrier protecting adjacent nontarget structures from heat-related damage.

Improved understanding of the mechanism of action of EVLT and its high degree of safety and effectiveness in treatment of GSV reflux has led to exploring treatment of non-GSV sources of truncal reflux with intraluminal delivery of 810-nm diode laser energy. Proper evaluation of patients suffering from venous insufficiency (ie, history,

physical examination, and duplex evaluation) is always paramount, but patient selection and meticulous technique are particularly important when treating non-GSV reflux with EVLT.

## SUMMARY

More than 95% of SSVs, ASVs, and PTCs treated with EVLT were successfully closed with initial treatment. Similar to experience with GSV treatment, all but one of the treatment failures occurred prior to 6 months, indicating that these may represent inadequate initial treatments rather than true recurrences. All were successfully re-treated with EVLT. There have been no skin burns, paresthesias, DVTs, or other heat-related complications. This remarkably low incidence of heat-related complications is likely due to proper use of sufficient amounts of tumescent fluid and shallower depth of penetration of 810-nm laser energy, resulting in less damage to surrounding nontarget tissues compared to other endovenous methods utilizing higher laser wavelengths or radiofrequency. These results support previous experience with EVLT of GSV reflux and further validate EVLT as a potential option for treating a variety of sources of underlying truncal reflux. ●

*Robert J. Min, MD, is Director, Cornell Vascular, and Associate Professor and Vice Chairman of Radiology, Weill Medical College of Cornell University, Ithaca, New York. He has disclosed that he is a paid consultant and has a royalty agreement with Diomed. Dr. Min may be reached at (212) 752-7999; Rjm2002@med.cornell.edu.*

*Moises Roizental, MD, is an interventional radiologist at Policlinica Metropolitana, Caracas, Venezuela. He has disclosed that he is a paid consultant of Diomed. Dr. Roizental may be reached at 011 908 06 87; mroizental@cantv.net.*

*Carlos F. Fernández, MD, is a vascular surgeon at Policlinica Metropolitana, Caracas, Venezuela. He has disclosed that he is a paid consultant of Diomed. Dr. Fernández may be reached at carlosefe@cantv.net.*

1. Callam MJ. Epidemiology of varicose veins. *Br J Surg*. 1994;81:167-173.
2. Min RJ, Khilnani N, Zimmet S. Endovenous laser treatment of saphenous vein reflux: long-term results. *J Vasc Interv Radiol*. 2003;14:991-996.
3. Labropoulos N, Giannoukas AD, Delis K, et al. The impact of isolated lesser saphenous vein system incompetence on clinical signs and symptoms of chronic venous disease. *J Vasc Surg*. 2000;32:954-960.
4. Min RJ, Zimmet SE, Isaacs MN, Forrestal MD. Endovenous laser treatment of the incompetent greater saphenous vein. *J Vasc Interv Radiol*. 2001;12:1167-1171.
5. Navarro L, Min RJ, Boné C. Endovenous laser: a new minimally invasive method of treatment for varicose veins—preliminary observations using an 810 nm diode laser. *Dermatol Surg*. 2001;27:117-122.
6. Boné C. Tratamiento endoluminal de las varices con laser de diodo: estudio preliminar. *Rev Patol Vasc*. 1999;5:35-46.

# RFA Versus Laser Ablation of the Saphenous Vein

The era of minimally invasive surgery has brought new developments in the treatment of chronic venous disease.

BY JOSE I. ALMEIDA, MD, FACS

**C**hronic venous disease is a common malady of the peripheral vascular system and includes a wide spectrum of clinical presentations, which range from spider telangiectasias to varicose veins to severe venous ulceration. The manifestations of chronic venous disease may result from primary venous insufficiency or may be secondary to other disorders, the most common of which is deep vein thrombosis (DVT). It is accepted by most investigators that varicose veins develop as a result of incompetent venous valves and/or inherent defects in the vein wall. These abnormalities significantly change venous hemodynamics, and blood fails to return efficiently to the right atrium, resulting in elevated venous pressure in the lower extremities with regions of blood pooling. Symptoms associated with this condition include pain, cramping, itching, restlessness, and heaviness. Reflux secondary to an incompetent great saphenous vein (GSV) and small saphenous vein (SSV) may give rise to clusters of varicosities located in multiple areas of the lower extremities. In severe cases, ulceration of the skin occurs. Treatment is directed toward excluding the defective vein(s) so that venous blood returns to the right heart through normal deep veins.

Treatment of superficial venous disease has undergone dramatic changes during the past 5 years. Prior to this period, elimination of saphenous vein reflux was either accomplished surgically (ligation and stripping) or chemically (sclerotherapy). Surgical ligation and stripping has been demonstrated to be associated with complications including hematoma, paresthesia, and recurrence. Surgical stripping has not been well accepted by patients who perceive the procedure as risky, disfiguring, requiring hospitalization, and requiring lengthy convalescence. Sclerotherapy, on the other hand, is performed commonly throughout the world with minimal risk, but with high failure rates.

The latest innovations in minimally invasive therapies

*"Experience has demonstrated that therapy must be directed toward any venous anatomy that is incompetent and produces varicosities."*

employ the delivery of thermal energy to the vein wall (via intraluminal means) to destroy the intima and denature collagen in the media. The result is fibrous occlusion of the vein. Thermal ablation of refluxing saphenous veins can be achieved with either radiofrequency or laser energy.

Radiofrequency ablation (RFA) and endovenous laser ablation (EVLA) are most commonly applied to the great and small saphenous veins. However, experience has demonstrated that therapy must be directed toward any venous anatomy that is incompetent and produces varicosities. Duplex imaging has demonstrated that saphenous veins are often not the refluxing vessel causing varicosis. Anterolateral tributary veins, posteromedial tributary veins, and even small groin veins (ie, epigastric veins) can be the source of abnormal venous hemodynamics. If a surgeon identifies the correct vein(s) prior to treatment, the outcome will be favorable.

## PATIENT SELECTION

Certain patients are not suitable for endovenous therapy. Patients with multiple comorbidities are not good candidates. Furthermore, patients with known allergy to lidocaine, thrombophilia, prior DVT with incomplete recanalization, and active superficial phlebitis are best treated conservatively with compression.

There are two anatomical considerations that make endovenous therapy undesirable. Veins located just below the surface of the skin are best removed surgically

TABLE 1. RECANALIZATION RATES BY CATHETER TYPE

Catheter Type	N	Recanalization at 12 Months	% Recanalization
EVLA	429	10	2.3
RF	106	8	7.5
Totals	535	18	3.4

(stripped). An endothermally treated vein immediately below the skin will result in an unsatisfactory cosmetic result because patients often develop a stain and/or palpable cord on the skin of the medial thigh and leg. Although resolution of these problems is often spontaneous, they may persist for more than 12 months. Second, vein tortuosity can be a challenge because guidewire navigation is difficult. In some cases, by employing multiple entry sites, these veins can be satisfactorily treated. Experience and careful clinical judgment are essential in these cases.

At Miami Vein Center, we routinely tailor the use of multiple therapeutic modalities to the clinical situation. For example, we have developed the laser-assisted distal stripping technique (LADS). This hybrid technique is useful when the GSV leaves the saphenous canal in the thigh and courses superficially under the skin distally. The thigh GSV is treated in the usual manner, but when the superficial course of the vein is identified by the laser beam, the vein is elevated via a small stab incision, and invagination stripping is performed distally using a 5-F sheath as the stripping device. Other techniques are used liberally as adjunctive procedures, such as ultrasound-guided sclerotherapy for tortuous venous segments, closure of multiple straight refluxing veins with RF or EVLA, and ligations of large perforating veins.<sup>1</sup>

### TUMESCENT ANESTHESIA

Endovenous procedures are performed using tumescent anesthesia. In the early days of RFA, patients were sometimes left with skin burns or paresthesias. After the advent of subfascial perivenous tumescent anesthesia, such complications rarely occur. Using ultrasound guidance, a needle may be placed in the saphenous canal and the entire vein surrounded with tumescent fluid, which accomplishes three things:

1. The reservoir of fluid surrounding the vein acts as a heat sink. When heat is applied inside the vein during venous ablation, the heat is quickly dissipated through the wall of the vein precluding any heat-related injury of surrounding tissue. As a result, the rate of skin burns and the paresthesias has been reduced to less than 1% in

experienced hands.

2. The tumescent fluid compresses the vein, allowing satisfactory treatment of even the most aneurysmal veins. We have successfully treated veins with a characteristic diameter of 30 mm by shrinking the vein down with the tumescent solution, which improves the vein contact with the surface of the endovenous device.

3. This method produces effective analgesia. Patients often find the experience is nearly painless. Postoperatively, most patients are comfortable taking a nonsteroidal anti-inflammatory daily for several days.

The tumescent technique eliminates the hemodynamic risks of sympathectomy associated with a conduction block (epidural or spinal anesthetic) and the cardiac and pulmonary risks associated with general endotracheal anesthesia.

With endovenous thermal ablation of the GSV, mild ecchymosis and a "pulling" sensation in the thigh are seen frequently after treatment. However, complications of paresthesia, hematoma, wound infection, and DVT are considered rare.

### RF ABLATION

The Closure System (VNUS Medical Technologies, San Jose, CA) consists of a bipolar heat generator and a catheter with collapsible electrodes that, when introduced intraluminally, effectively closes veins ranging from 2 mm to 12 mm in diameter. Using ultrasound control, access into the vein lumen is performed percutaneously, and the catheter tip is navigated to the saphenofemoral junction. Tumescent local anesthesia is placed circumferentially along the entire length of the vein, allowing a painless treatment as the catheter is slowly withdrawn at 85°C (185°F). Vein wall impedance and the amount of energy delivered are monitored continuously. Upon completion, absence of flow is assessed with ultrasound. Patent segments are retreated.

The VNUS Clinical Registry was established in 1998 with more than 30 centers contributing data worldwide. Registry results demonstrate the durability of endovenous radiofrequency obliteration. Absence of reflux by duplex ultrasound was 91.4%, 90.1%, 86.3%, and 86.1% at

TABLE 2. RECANALIZATION RATE BY VEIN LOCATION

Catheter Type	Recanalization Site		
	Posteromedial Tributary	GSV	SSV
EVLA	6	0	4
RF	6	2	0

1, 2, 3, and 4 years, respectively. In the VNUS registry, 94% of the ablated veins were invisible by ultrasound examination after the second year of treatment. Five-year follow-up on these patients will be available in late 2004.

Like any new technology, a learning curve invariably has an effect on treatment outcomes. It is intuitive that the patients with the longest follow-up were those treated early, and endovenous outcome data are, therefore, a moving target. Procedural modifications (subfascial perivenous tumescent anesthesia, concomitant treatment of multiple refluxing tributary veins, etc.) have since taken place, as well as improvements in the equipment and changes in energy delivery. The 10% early treatment failures reflected in the registry have been reduced as operators have gained more experience.

Three randomized trials have compared endovenous RF obliteration to vein stripping. Rautio et al randomized 28 patients to either RF obliteration or vein stripping and reported significantly less postoperative pain, less postoperative analgesia requirements, and faster recovery in the RF group.<sup>2</sup> The EVOLVEs study was a multicenter, prospective, randomized study, comparing quality-of-life factors between RF ablation and vein stripping. In all outcome variables, RF ablation demonstrated superior results when compared to vein stripping: faster recovery, less postoperative pain, fewer adverse events, and superior quality-of-life score.<sup>3</sup> EVOLVEs patients at 2 years demonstrated virtually identical treatment results when RF ablation and vein stripping were compared, with 91.2% versus 91.7% of limbs free of reflux, respectively. In addition, quality-of-life scores and pain scores were significantly better ( $P<.05$ ) at 2 years for RF ablation over vein stripping, demonstrating lasting benefit for the patients.<sup>4</sup> Similar findings were reported by the Stötter group in Germany in their own randomized trial.<sup>5</sup>

## EVLA

Endovenous treatment of incompetent venous segments also can be accomplished with laser energy delivered via a fiberoptic catheter. Three wavelengths (810

nm, 940 nm, and 980 nm) are currently FDA-approved; 810 nm (EVLT, Diomed, Inc., Andover, MA) is the first and has the longest published follow-up data. The endothelium of the vein is destroyed by a process known as selective photothermolysis. Proebstle has demonstrated that endoluminal heat damage is caused by steam bubbles originating from boiling blood, whereas others maintain that direct fiberoptic contact with the vein wall is the primary mode of action.<sup>6</sup> In reality, it is most likely a combination of the two.

EVLA mainly acts by laser light energy that is converted to heat when selectively absorbed by tissues within the vein. Heat-related damage to the inner vein wall leads to a thrombotic occlusion of the treated vein.<sup>6,7</sup> Laser wavelength does not seem to play a critical role. Wavelengths of 810 nm, 940 nm, and 980 nm have demonstrated identical results in generating steam bubbles in heparinized blood.<sup>7</sup> Furthermore, the data show equivalent vein closure rates for all three laser wavelengths. Pulsed delivery of laser energy has been replaced by a continuous pullback mode. Continuous pullback of the laser fiber accelerates the EVLA procedure, and theoretically, avoids perforation of the vein wall. Therefore, EVLA-related side effects such as ecchymosis and phlebitis should be reduced with continuous fiber pullback.

Unfortunately, the published data regarding early success or failure of EVLA cannot be linked directly to the administered laser fluences because this parameter is often not reported. However, the data that are available suggest that higher laser energies per vein length (cm) are associated with less failure of EVLA. Furthermore, in a recent study, Proebstle et al showed that the administered laser fluence, as calculated by cylindrical approximation of the proximal GSV segment, proved to be the most significant predictor of early EVLA failure in a multivariate statistical analysis.<sup>8</sup>

Min et al recently presented 3-year data on 499 limbs treated for incompetent GSVs. At 1-month follow-up, successful endovenous laser treatment, defined as use of 810-nm diode laser energy delivered intraluminally, was observed in 490 of 499 limbs (98%). Posttreatment fol-



low-up demonstrated continued GSV closure in 99.3% of limbs (444 of 447) at 3 months, 98.5% of limbs (390 of 396) at 6 months, 97.8% of limbs (351 of 359) at 9 months, 97.5% of limbs (310 of 318) at 12 months, and 93.4% of limbs (113 of 121) at 24 months. There were no recurrences in the 40 limbs followed up at 36 months. Importantly, all recurrences in this series were noted before 9 months, with the majority seen by 3 months.<sup>9</sup>

*"A significant advantage of endovenous techniques is avoiding the groin altogether and preserving venous drainage from the abdominal wall."*

Navarro et al reported their 4-year follow-up on 200 limbs treated with endovenous laser at the 2003 UIP World Congress in San Diego. The success rates presented approached 95%. The investigators noted the recurrences were due to recanalization and not to neovascularization. There was progression of disease secondary incompetence of saphenofemoral junction branches, which were not treated.<sup>10</sup>

Vein wall perforation with associated extravasation of blood has been proposed as the cause of patient discomfort after "pulsed" endovenous laser therapy. Min and Khilnani subsequently reported on the comparison of continuous-mode to pulse-mode endovenous laser therapy. To evaluate the safety and efficacy of continuous-mode endovenous laser therapy and its effect on postprocedure bruising and discomfort, 150 incompetent GSVs were treated in 131 patients with the following parameters: 14W continuous-mode at a pullback rate of 3 to 5 mm/s. Occlusion of the GSV was achieved in 99% of the cases after initial treatment. Nonentry site bruising was noted in 24% of the subjects at the 1-week follow-up visit, 86% of which felt tightness. There were no skin burns, paresthesias, or incidence of DVT. Less bruising was noted with continuous-mode, however, the degree/absence of bruising did not correlate with the degree of patient discomfort.<sup>11</sup>

#### COMPARISON OF RFA AND EVLA

At Miami Vein Center, we reviewed our results comparing RFA to EVLA during a 24-month period. From March 1, 2002 through February 29, 2004, endothermal venous ablation with or without concomitant phlebectomy was performed on 535 limbs in 427 patients, by a

single vascular surgeon. EVLA was performed on 53 limbs, endovenous laser ablation with phlebectomy (EVLA+P) was performed in 376 limbs, RFA was performed in 39 limbs, and RFA with phlebectomy (RFA+P) was performed in 67 limbs. In all cases, endoluminal thermal energy was delivered by catheter using ultrasound guidance and local anesthesia. Successful treatment was defined by absence of flow by color flow duplex imaging in the treated vein segment. Our protocol prescribes ultrasound follow-up at 2 days, 1 month, 6 months, and 12 months postprocedure, and annually thereafter.

Cessation of retrograde flow in the treated axial vein was observed in all patients at the completion of the procedure. Recanalization was observed in 18 limbs within the first 12 months after the procedure (Tables 1 and 2).

In a comparison of EVLA versus RF, the two-sided, *P* value using Fisher's exact test was .014. This suggests a statistically significant difference in favor of EVL. Recanalization by location of the vein treated is given in Table 3.

When the arms of this study are combined, the overall recanalization rate at 12 months was 3.4% in our series, which suggests recanalization is a relatively infrequent event. When recanalization was present in the GSV, it usually occurred proximal to the posteromedial tributary vein. In the SSV, recanalization occurred proximal to the perforator at the gastrocnemius point.

Adverse events associated with endothermal venous ablation were minimal and transient; two limbs in the RF group and one limb in the EVLA group developed paresthesias. Phlebectomy was associated with the development of six small seromas and one wound infection. DVT during follow-up did not occur in our series.

#### NEOVASCULARIZATION

Venous stripping has been vexed with postoperative hematomas, paresthesias, and wound complications, especially in the groin. Although most surgeons have reduced these complications by becoming devotees of invagination techniques, the recurrence rates are still high with these procedures because of neovascularization. Neovascularization refers to the growth of new blood vessels in the groin. In Fischer's study with follow-up to 39 years, neovascularization was seen in 60% of groins after surgical ligation and stripping. Thirty percent required additional treatment.<sup>12</sup>

A significant advantage of endovenous techniques is avoiding the groin altogether and preserving venous drainage from the abdominal wall. Pichot et al reported

clinical and duplex findings of 63 limbs, 24 months after great saphenous vein RF endovenous obliteration. Neovascularity was not identified in any groin.<sup>13</sup>

*"Failure does not appear to be related to vein size, but rather to leaving other large tributaries or perforating veins untreated."*

One theory behind the cause of neovascularization is the concept of frustrated venous drainage. When performing saphenous ligation and stripping, surgeons are trained to sweep, or eliminate, all vessels in the groin. With the new endovenous techniques, however, small venous tributaries in the groin that drain the lower abdomen are preserved, physiologic tributary flow is relatively undisturbed (does not incite groin neovascularity), and the GSV is eliminated as the refluxing conduit.

### ENDOVENOUS FAILURE

The early literature reports failure rates of approximately 10%, using either RFA or EVLA. Failure for endovenous treatments is defined as any recanalization (segmental or full length) of any ablated vein based on examination by ultrasound imaging. In most reported series, the failures seem to occur during the first 12 months. The reason for the 10% failure rate is presently unclear. Failure does not appear to be related to vein size, but rather to leaving other large tributaries or perforating veins untreated.

Recent data from Mark Whitely, MD, Nuffield Hospital, England, and Robert Kistner, MD, Straub Clinic and Hospital, University of Hawaii, who aggressively ablate all perforating and refluxing tributary veins at the time of primary operation with RFA, demonstrate 97% to 99% closure rates at 12 months (personal communication; Lien Xieu, VNUS Medical, October 2003).

Similarly, at Miami Vein Center, if we observe two or three incompetent axial veins in the leg, all are ablated at the same setting. This has reduced our failure rate to less than 2% at 12 months.

### CONCLUSIONS

During the past 5 years, we have seen dramatic improvements in endovenous techniques for treating varicose veins. Recent data have demonstrated the safety and efficacy of these techniques, as well as their superiority to venous stripping in areas of neovascularization

and improved patient comfort.

Both RFA and laser catheters are effective methods of endovenous saphenous ablation and both can be used safely in the office with local anesthesia. Recanalization occurred in 2.3% of cases with EVLA and 7.5% of cases with RFA in a series performed in our center. This difference was statistically significant in favor of EVLA. It is also of interest to note that RFA catheters are approximately sevenfold more costly than EVLA fibers. Using both systems, we found most recanalizations occurred in the first 12 months and developed in the GSV proximal to the posteromedial tributary vein or in the SSV proximal to the perforator at the gastrocnemius point.

Specialists in this field should now turn toward standardizing intraoperative energy dosages, pullback rates, and postoperative duplex nomenclature. Advances in these areas will improve our procedures and thus benefit our patients. ●

*Jose I. Almeida, MD, FACS, is a Board-Certified Vascular Surgeon and Director of the Miami Vein Center, Miami, Florida. He has disclosed that he holds no financial interest in any product or manufacturer mentioned herein. Dr. Almeida may be reached at [jia@bellsouth.net](mailto:jia@bellsouth.net).*

1. Almeida JI. Update on endovenous treatments for varicose veins: new data support the trend toward this less-invasive treatment for varicose veins. *Endovasc Today*. 2004;3(6):33-41.
2. Rautio T, Ohinmaa A, Perala J, et al. Endovenous obliteration versus conventional stripping operation in the treatment of primary varicose veins: a randomized controlled trial with comparison of the costs. *J Vasc Surg*. 2002;35:958-965.
3. Lurie F, Creton D, Eklof B, et al. Prospective randomized study of endovenous radiofrequency obliteration (closure procedure) versus ligation and stripping in a selected patient population (EVOLVE Study). *J Vasc Surg*. 2003;38:207-214.
4. Lurie F, et al. Presentation at the XVII Annual meeting of European Society for Vascular Surgery, Dublin, September 5-7, 2003.
5. Stötter et al. Presentation at the German Phlebology Society, September 2003.
6. Proebstle TM, Lehr HA, Kargl A, et al. Endovenous treatment of the greater saphenous vein with a 940 nm diode laser: thrombotic occlusion after endoluminal thermal damage by laser-generated steam bubbles. *J Vasc Surg*. 2002;35:729-736.
7. Proebstle TM, Sandhofer M, Kargl A, et al. Thermal damage of the inner vein wall during endovenous treatment: key role of energy absorption by intravascular blood. *Dermatol Surg*. 2002;28:596-600.
8. Proebstle TM, Gül D, Kargl A, et al. Non-occlusion and early reopening of the great saphenous vein after endovenous laser treatment is fluence dependent. *Dermatol Surg*. 2004;30:174-178.
9. Min RJ, Khilnani N, Zimmet SE. Endovenous laser treatment of saphenous vein reflux: long-term results. *J Vasc Intervent Radiol*. 2003;14:991-996.
10. Navarro L, Bone C. Endolaser: four years of follow-up evaluation [abstract]. 2003 UIP World Congress.
11. Min RJ, Khilnani N. 2003 endovenous laser treatment of saphenous vein reflux using continuous mode. *J Vasc Interv Radiol*. 2003;14(Suppl):S35.
12. Fischer R, Linde N, Duff C, et al. Late recurrent saphenofemoral junction reflux after ligation and stripping of the greater saphenous vein. *J Vasc Surg*. 2001;34:236-240.
13. Pichot O, Kabnick LS, Creton D, et al. Duplex ultrasound scan findings two years after great saphenous vein radiofrequency endovenous obliteration. *J Vasc Surg*. 2004;39:189-195.

# EVLT<sup>®</sup> for Venous Ulcer

A case report confirming the benefit of EVLT in healing venous ulcers and prevention of recurrence.

BY ALESSANDRA PUGGIONI, MD; MANJU KALRA, MBBS; WILLIAM J. CHARBONEAU, MD;  
AND PETER GLOVICZKI, MD

## CASE PRESENTATION

A 66-year-old woman presented with a left medial malleolar ulcer that failed to heal for the past 9 months. She had a history of postpartum, left lower-limb deep venous thrombosis (DVT) at the age of 27, and left superficial thrombophlebitis approximately 20 years ago. She had recurrent ulcers three times during the past 7 years; all healed after prolonged conservative treatment. Her ulcer had been treated with daily frequent saline-moist dressing changes and 30 to 40 mm Hg elastic compression stockings. Her compliance in wearing the compression stockings was limited by significant pain at the ulcer site, for which she required oral analgesics. The patient was otherwise healthy with no history of smoking, diabetes, claudication, or heart disease.

## PHYSICAL EXAMINATION

Physical examination revealed an obese patient with a superficial 3-cm X 1.5-cm left leg ulcer at the level of the medial malleolus; the ulcer was covered by fibrinous exudate and surrounded by an area of lipoder-

*"The first step toward correcting venous incompetence is ablation of the superficial system."*

matosclerosis and pigmentation. The ulcer was exquisitely tender. There was no ankle edema present. The patient had scattered varicosities. Pedal pulses were palpable.

## Diagnostic Evaluation

Strain gauge plethysmography revealed venous incompetence. There was no deep venous obstruction, and the calf pump function was normal. Venous duplex ultrasound examination revealed marked incompetence of the left common femoral and popliteal veins. The left great saphenous vein (GSV) was markedly incompetent from the saphenofemoral junction (SFJ) through the thigh (Figure 1A). Two small competent perforating veins were identified at the medial aspect of the left

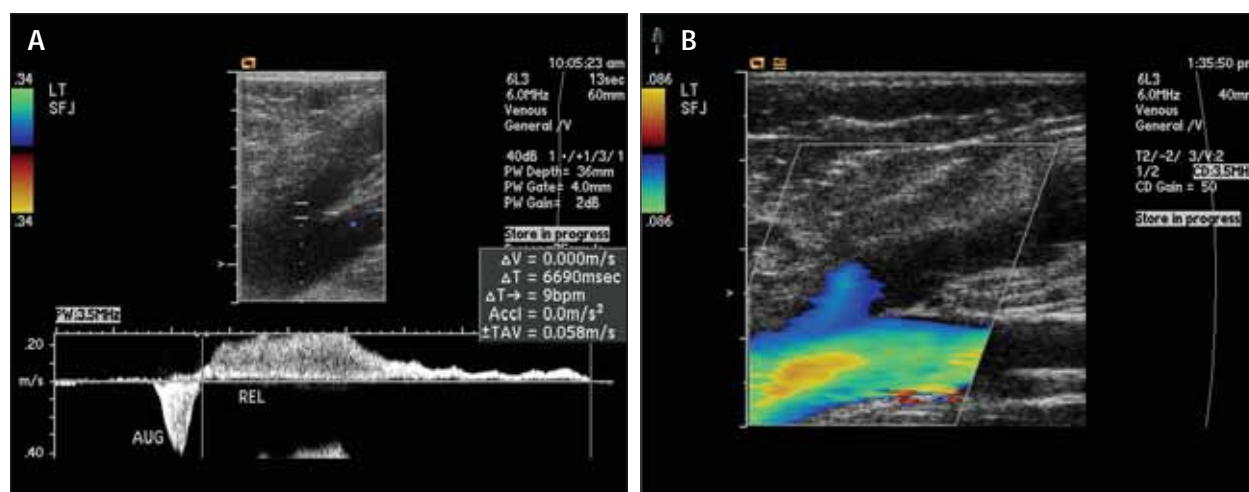


Figure 1. Incompetent GSV prior to EVLT (A). Occluded GSV after EVLT (B).

calf. Arterial Doppler ultrasound showed normal ankle-brachial indexes ( $>1.00$ ) and biphasic waveforms. Transcutaneous oximetry revealed a mild reduction of cutaneous blood flow in the area surrounding the ulcer (regional perfusion index = 0.59).

## TREATMENT

Surgical treatment was recommended to treat the incompetent superficial venous system. For ablation of the GSV, the patient was given the options of endovenous laser therapy (EVLT), radiofrequency ablation of the saphenous vein (Closure), and high ligation with stripping of the GSV. The patient selected EVLT. The outpatient surgery was performed in the operating room under general anesthesia. With duplex ultrasound guidance, the GSV was punctured at the level of the knee with an 18-gauge needle. A 45-cm-long, 5-F sheath was introduced into the vein with the help of a J-tip guidewire. An 810-nm diode laser fiber (Diomed, Andover, MA) was then inserted into the sheath. The position of the laser fiber tip was confirmed by intraoperative ultrasound to be just distal to the SFJ, at 1 cm below the inflow of the inferior epigastric vein. The saphenous subcompartment (Figure 2) along the GSV was then infiltrated with tumescent anesthesia (50 mL of 1% lidocaine and 1 mL of epinephrine 1:1,000 diluted in 1 L of normal saline) from the knee to the groin under ultrasound guidance. The patient was placed in the Trendelenburg position and the GSV was treated with 14 W of continuous energy, withdrawing the laser fiber at a speed of 10 cm/30 sec until a distance of 2 cm to the access site of the GSV at the knee was reached. A total of 420 J/10 cm of energy was delivered. In addition, an accessory saphenous vein was identified with

intraoperative ultrasound, which was also treated by EVLT. After the ablations were completed, occlusion of both the GSV (Figure 1B) and the accessory saphenous vein were confirmed with duplex scanning. Stab avulsion phlebectomies were performed to remove all varicose veins of the leg. At the completion of the procedure, an elastic compressive dressing was applied from the foot to the groin. No complications occurred during the procedure.

*"The recent trend toward minimally invasive surgery has led to the development of percutaneous means of ablating the incompetent GSV with Closure or EVLT."*

## OUTCOME

The patient was discharged 6 hours after the operation with minimal pain and discomfort. She resumed ambulation 3 hours after the procedure and resumed her normal daily activities. Healing of the ulcer was complete within 2 months. The patient discontinued wearing elastic stockings soon afterward. One year later, the ulcer had not recurred and she remained asymptomatic. The patient was highly satisfied with the treatment she received.

## DISCUSSION

The aim of open surgical treatment or endovenous interventions performed on patients with venous ulceration is to reduce ambulatory venous hypertension and thereby promote ulcer healing and prevent recurrence. This case illustrates the important contribution of the incompetent superficial venous system in the etiology of venous ulcers. In 10% of patients with venous ulceration, superficial venous reflux alone is the underlying pathophysiology (Figure 3). In an additional 70%, superficial valvular incompetence is present as a contributory factor in conjunction with perforator and/or deep venous incompetence. Most venous ulcers can be successfully healed over time with conservative medical treatment; however, healing time can be lengthy, at the cost of loss of productive time. In addition, patients with painful leg ulcers have a poor quality of life. The first step toward correcting venous incompetence is ablation of the superficial system. In one study of patients with superficial and perforator but not deep reflux, excellent ulcer healing (90%) and low ulcer recur-

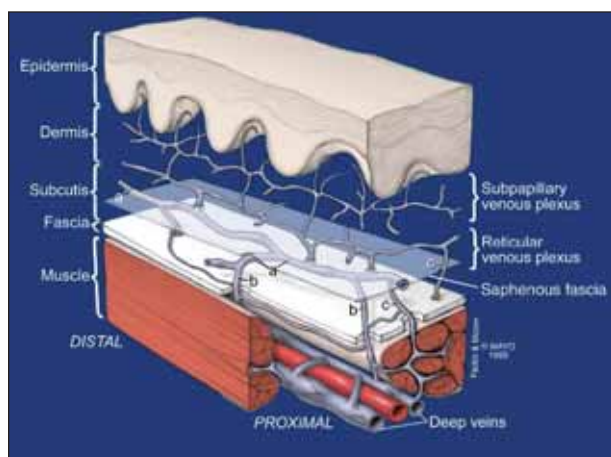


Figure 2. The anatomy of the saphenous fascia and saphenous subcompartment.



rence rates (10% at 3.5 years) have been reported after superficial reflux ablation alone.

*"Healing of venous ulcer and prevention of recurrence can be a major benefit of this operation."*

Ablation of superficial reflux has traditionally been performed by surgical high ligation and stripping of the GSV. The recent trend toward minimally invasive surgery has led to the development of percutaneous means of ablating the incompetent GSV with Closure or EVLT. The basic principle of both techniques is heating of the vein wall with destruction of the intima and denaturation of collagen in the media, with resultant fibrotic occlusion of the vein. The proposed advantages of endovenous techniques are less pain and wound complications, with earlier return to full activity and work compared to conventional stripping. An additional advantage of EVLT is identification and ablation of accessory saphenous systems under ultrasound guidance, as we did in our case. EVLT appears to be a faster technique to achieve the goal, with less restrictions concerning treatable vein size.

The most common complication after EVLT has been tightness and a pulling sensation along the ablated vein requiring analgesics. DVT after EVLT is very rare, although protrusion of the thrombus from the thrombosed saphenous vein is possible after both Closure<sup>1</sup> and EVLT occlusion of the saphenous vein.<sup>2</sup> Leg elevation during treatment, the use of tumescent solution around the vein to compress the vein wall to the laser fiber, and early ambulation after the procedure are recommended to decrease

this complication. Efficacy of EVLT in obtaining early occlusion of the GSV is very satisfactory: in our unpublished series of 54 limbs evaluated with duplex scanning within 30 days of EVLT, the closure rate was 94%. Other investigators have reported early and midterm occlusion rates between 97% and 100%, whereas in the latest publication of Min et al, it was 93% at 2-year follow-up.<sup>3</sup>

## SUMMARY

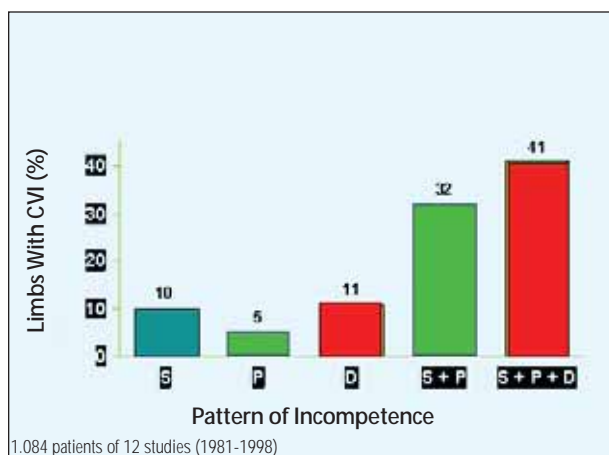
Healing of venous ulcer and prevention of recurrence can be a major benefit of this operation. In a series of 18 patients with open leg ulcers at the time of EVLT treatment, an early healing rate of 83% was reported.<sup>4</sup> Our case with a 1-year follow-up confirms that treating the incompetent superficial system alone can provide lasting benefit even in patients with advanced chronic venous insufficiency and venous ulcer. Late follow-up of this and other patients will provide information if the long-lasting benefits of endovenous therapy will match those results obtained after high ligation and open surgical stripping. ●

*Alessandra Puggioni, MD, is from the Division of Vascular Surgery and Department of Diagnostic Radiology, Gonda Vascular Center, Mayo Clinic, Rochester, Minnesota. Dr. Puggioni may be reached at (507) 284-3407; puggioni.alessandra@mayo.edu.*

*Manju Kalra, MBBS, is from the Division of Vascular Surgery and Department of Diagnostic Radiology, Gonda Vascular Center, Mayo Clinic, Rochester, Minnesota. Dr. Kalra may be reached at (507) 284-3407; kalra.manju@mayo.edu.*

*William J. Charboneau, MD, is from the Division of Vascular Surgery and Department of Diagnostic Radiology, Gonda Vascular Center, Mayo Clinic, Rochester, Minnesota. Dr. Charboneau may be reached at (507) 284-2097; charboneau.william@mayo.edu.*

*Peter Glociczki, MD, is from the Division of Vascular Surgery and Department of Diagnostic Radiology, Gonda Vascular Center, Mayo Clinic, Rochester, Minnesota. Dr. Glociczki may be reached at (507) 284-3407; glociczki.peter@mayo.edu.*



**Figure 3. Patterns of incompetence in limbs with chronic venous insufficiency.**

1. Hingorani AP, Ascher E, Markevich N, et al. Deep venous thrombosis after radiofrequency ablation of greater saphenous vein: a word of caution. *Vasc Surg*. 2004;40:500-504.
2. Mozes G, Kalra M, Carmo M, et al. Extension of saphenous thrombus into the femoral vein: a potential complication of new endovenous ablation techniques. *J Vasc Surg*. Submitted for publication.
3. Min RJ, Khilnani N, Zimmet SE. Endovenous laser treatment of saphenous vein reflux: long-term results. *J Vasc Interv Radiol*. 2003;14: 991-996.
4. Perkowski P, Ravi R, Gowda RC, et al. Endovenous laser ablation of the saphenous vein for treatment of venous insufficiency and varicose veins: early results from a large single-center experience. *J Endovasc Ther*. 2004;11:132-138.

# Treatment of Leg Veins

An introduction to ambulatory phlebectomy, sclerotherapy, and cutaneous laser/light treatment of leg veins.

BY STEVEN E. ZIMMET, MD

Surface veins of all types are often fed by deeper veins. An appropriate history, physical examination, and duplex ultrasound evaluation will elucidate the abnormal venous pattern, as well as the patient's general health status and contraindications to treatment. Treatment should first be directed to the most proximal/deepest source of reflux. Of course, incompetent veins of the deep system are never treated with obliterating techniques. Ambulatory phlebectomy, sclerotherapy, and/or cutaneous laser/light of surface varices are undertaken after treating underlying incompetent veins.

## AMBULATORY PHLEBECTOMY

Modern phlebectomy techniques were introduced in the 1950s by Dr. Muller. His modifications enabled it to be performed on an ambulatory basis under local anesthesia through very small incisions. Ambulatory phlebectomy is now a widely practiced technique, although it was initially received with ridicule.<sup>1</sup>

Ambulatory phlebectomy is perhaps most useful for large, tortuous surface varices. Small varices are readily treated with sclerotherapy. Sclerotherapy of large varices may require several sessions, and pigmentation and indurated segments are common. These problems are much less likely after phlebectomy. I routinely perform phlebectomy immediately after endovenous treatment of incompetent saphenous veins. It can be done in stages, which can be useful in a patient who is elderly or who has extensive varices.

Contraindications to ambulatory phlebectomy include allergy to local anesthetics, hypercoagulable state, pregnancy, infection of the area to be treated, sig-

*"Treatment should first be directed to the most proximal/deepest source of reflux."*

nificant edema or peripheral arterial insufficiency, and serious illness. Patients must be ambulatory.

## Equipment and Preoperative Phase

A power table is useful and should enable the patient to be placed in the Trendelenburg position. I place a mark, using an indelible marker, directly on top of the vein to be treated. Initial markings are made lightly with the patient standing because varicose veins will be easily seen in this position. Final mapping is done with the patient in the position he will be treated because the relative position of the vein to the skin changes when the patient changes position. A transillumination device, such as the VeinLite (TransLite, Sugarland, TX) is extremely helpful when mapping surface veins. Other equipment includes antiseptic solution, sterile drapes, facemask, sterile gloves, mosquito forceps, an 18-gauge needle or #11 blade, and bandaging materials. Emergency resuscitation equipment should be available.

A variety of phlebectomy hooks are available. The Muller, Oesch, Ramelet, Varady, Dortu-Martimbeau, and Tretbar hooks are the most widely used. Each of them comes in several sizes. I recommend trying the various styles to see what works best for you. I use Muller hooks (Figure 1).

I use 0.1% xylocaine with 1:1 million epinephrine for



Figure 1. A #1 Muller hook.

anesthesia, buffered to reduce stinging by adding 1 mL of an 8.4% sodium bicarbonate solution to every 10 mL of lidocaine solution. This provides excellent and long-lasting anesthesia with low toxicity, and aids in dissection of the vein and in achieving hemostasis. One may use as much as 7 mg/kg, to a maximum of 500 mg, in a single session.<sup>2</sup>

*"Ambulatory phlebectomy is an excellent technique that can be used to remove large varices through tiny punctures or incisions."*

### Operative Technique

The leg is prepared and draped in a sterile manner. The anesthetic is injected directly under the vein markings. An 18-gauge needle is used to make a puncture approximately 2 mm lateral to the marked vein. Alternatively, a #11 blade could be used to make 1-mm to 2-mm incisions. The incisions should be made parallel to the long axis of the leg, except around the knee, where the normal skin lines are followed. The hook is turned down so that it will not catch on the undersurface of the skin, and it is used to gently undermine in both directions along the vein. The hook is used to grasp the vein or the connective tissue surrounding the vein. The vein is gently pulled up through the puncture and grasped with a mosquito forceps (Figure 2). Additional forceps are applied to the vein as it is gently pulled up through the puncture site. The vein segment is avulsed. This process is repeated at other sites until the marked segments of the vein are removed. Ligation of the vein stumps is not necessary. Suturing the skin is unnecessary so long as the skin openings are less than 2 mm to 3 mm. Retained venous segments may become indurated and cause tenderness. These usually resolve spontaneously.

Pitfalls, precautions, and technical nuances have been presented elsewhere.<sup>3-5</sup> Trivex (Smith & Nephew Inc., Andover, MA) is a modification of phlebectomy that uses intraoperative transillumination and power suction to remove varices. Comparative studies have not found significant differences between Trivex and conventional phlebectomy.<sup>6,7</sup>

Ambulatory phlebectomy, when properly done, is very well tolerated. Most complications, such as skin blistering (due to friction from the bandage) and pigmenta-

tion, are not serious and resolve spontaneously. Significant complications, such as infection and allergic reactions, are rare. Small sensory nerves may be hooked during phlebectomy. If the procedure has been done under local anesthesia, the patient will experience pain. Nerve injury is usually avoided if the surgeon moves to another operative site. Phlebectomy of the popliteal fold, foot, and the prepatellar and pretibial areas are technically more challenging. In addition, complications such as swelling, hematoma, and nerve and lymphatic injury are more common in these areas.<sup>8,9</sup> More detailed reviews of the complications of phlebectomy have been published elsewhere.<sup>8-10</sup>

### Postoperative Care

Proper bandaging is important and details about bandaging and compression techniques have been published elsewhere.<sup>3,4,10</sup> The status of the peripheral arterial circulation influences the type of compression that can be used. Postoperative pain, usually mild, can be managed with ibuprofen. The patient should walk for 20 minutes immediately after treatment and at least 1 hour per day for 1 week. Ambulation reduces the risk of deep vein thrombosis.

Ambulatory phlebectomy is an excellent technique that can be used to remove large varices through tiny punctures or incisions. Puncture sites are often difficult to find after healing has occurred. Treatment, done in-office under dilute local anesthesia, complements endovenous treatment of underlying incompetent saphenous veins. Complementary sclerotherapy of residual varices can be done approximately 4 weeks after the procedure. This period allows for healing, as well as spontaneous improvement or even resolution of distal varices.

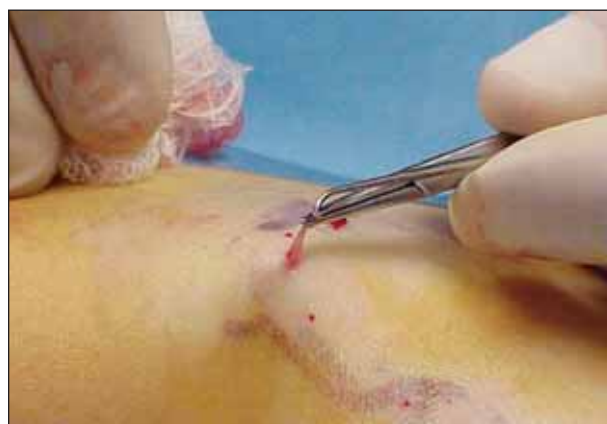

Figure 2. Vein extraction using a #1 Muller hook and mosquito forceps.

## SCLEROTHERAPY

The aim of sclerotherapy is to obliterate incompetent veins. The goal is to deliver a minimum volume and concentration of sclerosant that will irreversibly damage the endothelium of the vein to be sclerosed, without causing collateral damage. Contraindications include, in addition to those mentioned for ambulatory phlebectomy, sclerosant allergy.

### Sclerosants

Many agents have been used for sclerotherapy of leg veins, but only a few are in common use today. Sodium morrhuate, although FDA-approved for sclerotherapy, is not commonly used because of a history of frequent anaphylaxis.<sup>11</sup> This is also true of ethanolamine oleate.

Polidocanol (hydroxypolyethoxydodecane) is a synthetic long-chain fatty acid. It is commonly used in the US, even though it is not approved by the FDA for sale as a pharmaceutical product.

Hypertonic saline (23.4% sodium chloride) is FDA-approved for other uses, but not sclerotherapy. Nonetheless, it is commonly used as a sclerosant for telangiectasias and reticular veins. It is widely available, inexpensive, and without allergenicity (if unadulterated). Its disadvantages include burning pain, rapid dilution limiting the size of vein it can successfully treat, and a high risk of extravasation necrosis.

Dextrose and hypertonic saline (25% dextrose, 10% sodium chloride) is produced in Canada under the trade name Sclerodex (Omega Laboratories Ltd., Montreal, Canada). It contains a small amount of propylene glycol and phenethyl alcohol. It is not FDA-approved for commercial sale in the US, but can be compounded by a pharmacy. I believe it causes less pain on injection and has a lower risk of necrosis if extravasated than hypertonic saline. It is used primarily for telangiectasias and small reticular veins.

Sodium tetradecyl sulfate, a long-chain fatty acid detergent in use since the 1940s, is used in concentrations from 0.1% to 3% to treat telangiectasia and incompetent saphenous veins. It has an excellent safety and efficacy profile. This and other detergent sclerosants may be used as a foam to enhance the sclerosant effect.<sup>12-15</sup>

The efficacy of sclerotherapy can be maximized and

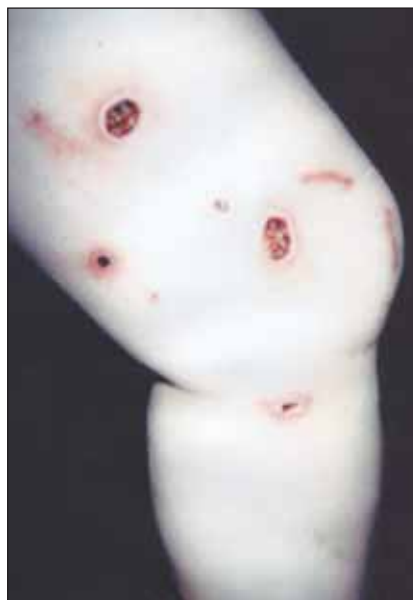

Figure 3. Cutaneous ulcerations due to extravasation of hypertonic saline.

the risk of complications minimized by choosing the proper sclerosant for the vein being treated. The larger the vein to be treated is, the higher the sclerosant concentration and volume should be. A corollary of this is to use the minimum sclerosant concentration necessary to achieve sclerosis.<sup>16</sup> The concentration of sclerosant is generally chosen based on the type and diameter of vein being treated (Table 1). I limit my total sclerosant volume to 10 mL per session.

### Sclerotherapy of Varicose Veins and Perforators

Treatment of varicose veins is done after or at the same time as treatment for underlying incompetent veins. The patient is positioned in a supine, prone, or lateral decu-

bitus position, as needed, so that veins are relatively empty of blood and contact time between the sclerosant and vein wall is maximized. The vein is cannulated briskly, gentle aspiration is performed to confirm intravascular placement, and the sclerosant is administered without undue pressure or speed. Generally, 1 mL or less is injected at any one site to reduce the risk of spread of concentrated sclerosant into the deep system. Injections are administered approximately every 5 cm to 15 cm along the course of the varix.

Incompetent perforators can be treated with sclerotherapy. I usually treat them by injecting the area near where the perforator connects to the overlying varix, to reduce the risk of injecting an accompanying artery.

Duplex ultrasound can be used to guide an injection of sclerosant to incompetent superficial system veins under the skin. Ultrasound-guided sclerotherapy of saphenous veins is an alternative or complementary technique to surgery, endovenous laser, and radiofrequency ablation. UGS is a specialized technique that requires an appropriate level of expertise in both sclerotherapy and duplex ultrasound to utilize in a safe and efficacious manner.

### Sclerotherapy of Small Veins: Spider and Reticular Veins

A 3-mL syringe with a 30-gauge needle is used to inject spider veins, whereas 26-gauge needles are used to inject reticular veins. The injection is stopped if scler-



TABLE 1. INITIAL SCLEROSANT CONCENTRATIONS AND VOLUME BASED ON SIZE AND SITE OF VARICES

Sclerosant	Telangiectasia	Reticular	Varicose	Perforator	Saphenous
STD	0.1-0.2%	0.25-0.5%	0.33-2%	0.75-3%	3%
Poli	0.25-0.5%	0.5-1%	0.67-4%	1.5-4%	4%
HS	11.7-23.4%	23.4%	n/a	n/a	n/a
D/HS	FS	FS	n/a	n/a	n/a

STD= sodium tetradecyl sulfate, Poli= polidocanol, HS= hypertonic saline, D/HS= 25% dextrose/10% saline, FS= full strength.

rosant is not flowing, the patient reports pain, or a bleb is seen. Gentle aspiration of blood can be used to verify that the needle is intravascular with veins larger than spider veins. Just enough sclerosant is injected to blanch a spider vein complex. The amount of sclerosant used to inject a reticular depends on the diameter and length of the vein treated. Generally, 0.25 mL to 0.5 mL per site is injected approximately every 8 cm to 12 cm.

### Posttreatment Care

Compression may improve efficacy by reducing reflux and the diameter of treated veins. It also reduces thromboembolism risk. Ace bandages are an inadequate form of compression. I instruct patients to wear a class I stocking (20-30 mm Hg) for 3 days after treatment of small veins, or a class II stocking (30-40 mm Hg) for 1 week if larger veins have been treated.

Patients walk for 15 to 20 minutes immediately after treatment. Walking reduces pressure in the superficial veins and increases flow through the deep veins. It ensures patients will be nearby during the time an allergic reaction would most likely occur. Patients walk a minimum of 1 hour daily and avoid hot baths for a week. Heat dilates veins and may be counterproductive. Patients are asked to avoid heavy straining after treatment of large veins.

Follow-up is generally conducted at 4 weeks. This gives a reasonable period for the sclerosing process to occur. If there has been incomplete resolution, I will often repeat the same treatment. If no significant change occurs, I consider increasing the sclerosant dose, changing sclerosants, and/or ruling out an unrecognized proximal reflux source. It is not uncommon for a treated vein to have some lumpy segments. These often represent coagula. I drain these areas by puncturing them with a needle and gently expressing the coagulum.

### Sclerotherapy Complications

Cutaneous ulceration, probably the most frequent

cause of malpractice actions after sclerotherapy, may result from extravasation or intra-arteriole injection. I believe extravasation is the most common cause. Hypertonic saline has the highest risk of cutaneous necrosis (Figure 3). If a small bleb of a low-strength agent is noted, massaging the area may be all that is needed. Hyaluronidase (75 units in 3 mL) has been shown in prospective, randomized, and blinded animal studies to significantly reduce the incidence and size of ulceration after intradermal injection of both 23.4% hypertonic saline and 3% sodium tetradecyl sulfate.<sup>17,18</sup> This protective effect is probably due to enhanced egress of the extravasated solution and preservation of cellular function. It is not due to dilution because normal saline given in the same volume had no effect. In the event of ulceration, occlusive dressings reduce pain and speed healing. Excision and primary closure can be considered.

Postsclerotherapy pigmentation, the most common complication of sclerotherapy, represents hemosiderin deposition in the skin. This occurs in approximately 10% to 20% of patients. Spontaneous clearing within 6 to 12 months is typical, although it may occasionally last longer.<sup>19</sup> The incidence of pigmentation is increased if the potency of the sclerosant is too strong for the vein being treated and if a proximal reflux source is untreated. Postsclerotherapy coagula should be drained to reduce the hemosiderin load. Tincture of time is the treatment of choice if pigmentation develops. Laser treatment could be considered if the pigmentation fails to clear spontaneously. Other cutaneous complications include telangiectatic matting (the appearance of fine, tiny red telangiectasias).

The most serious complications of sclerotherapy are anaphylaxis and intra-arterial injection. Although these are rare, you must be prepared to treat them. Proper knowledge of anatomy and danger zones, along with skilled technique, are important to reduce the risk of intra-arterial injections. An extensive discussion of sclerotherapy complications is beyond the scope of this arti-

cle. Other works may be consulted for a thorough review of sclerotherapy and potential complications.<sup>20,21</sup>

Adequate understanding of an appropriate history and physical, ultrasound evaluation, anatomy, pathophysiology, knowledge of sclerosing solutions, patient selection, posttreatment care, as well as the ability to prevent, recognize, and treat complications is required before embarking on treatment.

### CUTANEOUS LASER/LIGHT SOURCE TREATMENT

Light-based treatment of veins depends on adequate heating of the entire vessel without damaging nontarget tissue. Many wavelengths have been used to treat small leg veins, including 532 nm, pulsed dye (585-600 nm), alexandrite, diode (810 nm, 940 nm, 980 nm), 1,064 nm, and pulsed light.<sup>22</sup> Refinements in laser treatment of veins have included improved matching of pulse duration to vein diameter, protective cooling that increases the safety of higher fluences, and the use of longer wavelengths that penetrate more deeply.<sup>23</sup> Nonetheless, laser and pulsed light treatments are more successful for facial rather than leg veins. This is likely because leg veins are deeper and thicker than facial veins and are often fed by underlying incompetent veins.<sup>23</sup> Laser/pulsed light treatment is painfully<sup>24,25</sup> and cutaneous complications have been extremely common in some series.<sup>26-28</sup>

A well-known laser expert initially reported very encouraging results utilizing pulsed light to treat leg veins; approximately 80% of patients achieved 75% to 100% clearance.<sup>29</sup> However, with more experience, he stated his opinion that sclerotherapy is "more efficacious and less painful than laser."<sup>25</sup>

An internationally renowned laser center conducted a study using a long-pulsed 1,064-nm Nd:YAG laser on one leg and .25% sclerotherapy on the other leg. They noted earlier vessel clearing and higher average improvement scores in sclerotherapy treated areas. They concluded "until further refinements are made in laser technology ... the majority of patients with lower-extremity telangiectasias appear to be best treated initially with sclerotherapy."<sup>30</sup>

Laser/light treatment may be useful in some cases of postsclerotherapy matting and in small veins resistant to sclerotherapy. Additional references should be consulted for a more thorough discussion of this treatment technique.<sup>22,23</sup>

### CONCLUSIONS

The complementary use of modern phlebology techniques enables highly successful in-office treatment, under local anesthesia, of patients even with large vari-

cose veins. The outcome is usually excellent, and significant complications are rare. ●

*Steven E. Zimmet, MD, is in private practice in Austin, Texas. He has disclosed that he holds no financial interest in any product or manufacturer mentioned herein. Dr. Zimmet may be reached at (512) 485-7700; zimmet@skin-vein.com.*

- Olivencia JA. Interview with Dr. Robert Muller: father of modern day ambulatory phlebectomy. *Dermatol Surg*. 1998;24:1147-1150.
- Smith SR, Goldman MP. Tumescence anesthesia in ambulatory phlebectomy. *Dermatol Surg*. 1998;24:453-456.
- Ricci S, Georgiev M, Goldman MP. Ambulatory phlebectomy: a practical guide for treating varicose veins. Mosby, St. Louis, MO: 1995.
- Olivencia JA. Pitfalls in ambulatory phlebectomy. *Dermatol Surg*. 1999;25:722-725.
- Olivencia JA. Ambulatory phlebectomy of the foot: review of 75 patients. *Dermatol Surg*. 1997;23:315-318.
- Aremu MA, Mahendran B, Butcher W, et al. Prospective randomized controlled trial: conventional versus powered phlebectomy. *J Vasc Surg*. 2004;39:88-94.
- Scavee V, Lesceu O, Theys S, et al. Hook phlebectomy versus transilluminated powered phlebectomy for varicose vein surgery: early results. *Eur J Vasc Endovasc Surg*. 2003;25:473-475.
- Olivencia JA. Complications of ambulatory phlebectomy. *Dermatol Surg*. 1997;23:51-54.
- Ramelet AA. Complications of ambulatory phlebectomy. *Dermatol Surg*. 1997;23:947-954.
- Weiss RA, Ramelet AA. (2002) Varicose Veins Treated with Ambulatory Phlebectomy. *Emedicine.com*. Retrieved September 25, 2004 from <http://www.emedicine.com/derm/topic748.htm>.
- Lewis KM. Anaphylaxis due to sodium morrhuate. *JAMA*. 1936;107:1298-1299.
- Henriet JP. Expérience durant trois années de la mousse de polidocanol dans le traitement des varices réticulaires et des varicosités. *Phlebologie*. 1999; 52:277-282.
- Cabrera Cabrera J Jr, Garcia-Olmedo MA. Treatment of varicose long saphenous veins with sclerosant in microfoam form: long term outcomes. *Phlebology*. 2000;15:19-23.
- Frullini A, Cavezzi A. Sclerosing foam in the treatment of varicose veins and telangiectasias: history and analysis of safety and complications. *Dermatol Surg*. 2002;28:11-15.
- Breu FX, Guggenbichler S. European Consensus Meeting on Foam Sclerotherapy. April 4-6, 2003, Tegernsee, Germany. *Dermatol Surg*. 2004;30:709-717.
- Sadick NS. Sclerotherapy of varicose and Telangiectatic leg veins: minimal sclerosant concentration of hypertonic saline and its relationship to vessel diameter. *J Dermatol Surg Oncol*. 1991;18:47-52.
- Zimmet S. The prevention of cutaneous necrosis following extravasation of hypertonic saline and sodium tetradecyl sulfate. *J Dermatol Surg Oncol*. 1993;19:641-646.
- Zimmet S. Hyaluronidase in the prevention of sclerotherapy-induced extravasation necrosis: a dose-response study. *Dermatol Surg*. 1996;22:73-77.
- Georgiev M. Postsclerotherapy hyperpigmentation: a one-year follow-up. *J Dermatol Surg Oncol*. 1990;16:608-610.
- Weiss RA, Feied CF, Weiss MA. *Vein Diagnosis and Treatment*. New York, NY: McGraw-Hill, 2001.
- Goldman M, ed. *Sclerotherapy: Treatment of Varicose and Telangiectatic Leg Veins*. St. Louis: Mosby-Year Book, 1995.
- Dover JS, Sadick NS, Goldman MP. The role of lasers and light sources in the treatment of leg veins. *Dermatol Surg*. 1999;25:328-335.
- Weiss RA, Dover JS. Laser surgery of leg veins. *Dermatol Clin*. 2002;20:19-36.
- Eremia S, Li C, Umar SH. A side-by-side comparative study of 1064 nm Nd:YAG, 810 nm diode and 755 nm alexandrite lasers for treatment of 0.3-3 mm leg veins. *Dermatol Surg*. 2002;28:224-230.
- Goldman MP. Laser and sclerotherapy treatment of leg veins: my perspective. *Dermatol Surg*. 2002;10:969.
- Spendel S, Prandl EC, Shintler MV, et al. Treatment of spider leg veins with the KTP (532 nm) laser: a prospective study. *Lasers Surg Med*. 2002;31:194-201.
- Brunnberg S, Lorenz S, Landthaler M, et al. Evaluation of the long pulsed high fluence alexandrite laser therapy of leg telangiectasia. *Lasers Surg Med*. 2002;319:359-362.
- Kono T, Yamaki T, Ercocen AR, et al. Treatment of leg veins with the long pulse dye laser using variable pulse durations and energy fluences. *Laser Surg Med*. 2004;35:62-67.
- Goldman MP, Eckhouse S. Photothermal sclerosis of leg veins. *Dermatol Surg*. 1996;22:323-330.
- Lupton JR, Alster TS, Romero P. Clinical comparison of sclerotherapy versus long-pulsed Nd:YAG laser treatment for lower extremity telangiectasias. *Dermatol Surg*. 2002;28:694-697.

# Credentialing, Quality Control, and Education

Endovenous procedures have been established as important treatment options; now we must work to create the appropriate measures to maintain their safety and efficacy.

BY PETER GLOVICZKI, MD

**P**rogress in endovenous technology has recently focused much-needed attention on the treatment of varicose veins and venous ulcers. This change has been welcomed by both patients and physicians, because in the US, more than 25 million people have varicose veins, more than 2.5 million have more advanced chronic venous insufficiency, and approximately 1 million have venous ulcerations. Annual costs of treating venous ulcer patients are estimated to be between \$150 million to \$1 billion, not counting the indirect costs related to loss of work days, early retirement, and reduced quality of life.

Ablation of the incompetent saphenous vein by surgical or endovenous techniques diminishes venous reflux in the leg and decreases ambulatory venous hypertension. Symptomatic relief is consistently achieved after treatment for varicose veins, and venous ulcers also heal more rapidly after these procedures. Recurrences of both varicose veins and venous ulcers are much less frequent after ablation of the incompetent saphenous vein.

High ligation and stripping have been the classic surgical operations used to treat saphenous incompetence. The recently introduced endovenous techniques, however, are less invasive, and reported early and midterm results have been favorable. Endovenous laser therapy (EVL) and radiofrequency ablation (Closure) of the saphenous vein have been used with increasing frequency in many hospitals and physicians' offices, and today, they are likely performed more frequently than open surgical stripping.

Endovenous laser therapy was approved by the FDA in January 2002. Both the 810-nm and the 940-nm diode lasers have been effective in inducing thrombosis and occlusion of the saphenous vein. Heating of the vein wall causes collagen contraction and denudation of endothelium, which results in vein wall thickening, luminal contraction, and fibrosis of the vein. The 810-nm-wavelength laser energy is delivered via a 600- $\mu$ m laser fiber (Diomed, Inc., Andover, MA).

The use of endovenous ablations has extended well beyond specialty boundaries. Truly, few if any other proce-

*"Credentialing should be performed locally by committees in the individual hospitals in which physicians perform endovenous procedures."*

dures have been embraced by more specialties than EVLT and Closure. General practitioners, phlebologists, vascular internists, vascular, general, plastic and cardiac surgeons, dermatologists, and interventional radiologists have adopted these techniques and use them as part of their traditional practice or work within newly formed vein clinics. The popularity of these procedures has increased day by day. Unfortunately, because multiple specialties have been involved and long-term results are still not available, legitimate concerns about credentialing, quality control, and education have emerged. Although national venous societies like the American Venous Forum and the North American College of Phlebology have recognized the need for sensible guidelines, no document has been published to date in this country to regulate the use of endovenous procedures. Universally accepted credentialing criteria do not exist, training has mostly been performed by representatives of the appropriate laser companies, and guidelines for quality control have been notoriously lacking.

## CREDENTIALING

Credentialing should be performed locally by committees in the individual hospitals in which physicians perform endovenous procedures. The Joint Commission on Accreditation for Health Care Organization (JCAHO) requires that every physician be credentialed by an oversight committee and that a review process be established to evaluate and monitor safety and efficacy of any new technology. EVLT or Closure should be no exception. It is

important and customary that hospitals turn to nationally recognized guidelines, when available, to credential physicians in new procedures. In the field of endovenous ablation, national guidelines are, unfortunately, not yet available.

Similar to requirements suggested for other endovascular interventions, it would appear imperative that the physician or team of physicians performing EVLT possess basic knowledge and competence in (1) the diagnosis and management of chronic venous disorders, including varicose veins and venous ulcers, (2) performance and interpretation of venous duplex scanning, (3) performance of some or most alternative procedures (open surgery, stripping, phlebectomy, sclerotherapy) than can be used together or separately to treat the underlying venous disease, (4) performance of basic endovascular procedures, such as percutaneous cannulation of veins using ultrasound, placement of guidewires and sheaths and placement of intravenous catheters, and (5) performance of procedures with lasers in operating room or office settings. Employees working with class 3b or 4 laser systems are required to have annual training on the associated hazards of the laser and on how to minimize or eliminate the hazards. Although requirements may differ in hospitals, they can usually be fulfilled by viewing a laser safety videotape, attending a laser safety class, reading laser safety materials, or completing computer-based training.

Finally, quality control should include recording and reporting complications of the procedure and provide appropriate short- and long-term follow-up to justify use of this new technology in the future and provide optimal care of patients with chronic venous disease, including adjuvant care of persistent venous hypertension and venous ulcers as well as repeat interventions, which may be needed not infrequently in many patients.

### QUALITY CONTROL

Quality control of endovenous procedures must be ensured using available guidelines of the American Venous Forum (Handbook of Venous Disorders, Guidelines of the American Venous Forum, 2nd ed, Gloviczki P, Yao JST [eds]. London: Arnold, 2001). A revision of the CEAP classification soon to be published in *The Journal of Vascular Surgery* will be the latest resource for all physicians dealing with chronic venous disorders. It is important that CEAP classes are used to describe the stage of the disease to justify indication for treatment, to define the level of investigation required, and to ensure appropriate comparison of different reported studies.

For longitudinal research to assess clinical outcome, Venous Severity Scoring and Quality of Life scores should be used. Quality control should include prevention and man-

agement of potential complications, including pain control, preventing extension of the saphenous vein thrombus into the femoral vein, and prevention of frank iliofemoral deep vein thrombosis. Attention to the details of positioning the tip of the laser fiber, early ambulation, leg elevation, the use of a large amount of tumescent solution injected into the saphenous subcompartment, using compression stockings, and perioperative subcutaneous heparin have been recommended for thrombosis prophylaxis.

### EDUCATION

Education on chronic venous disease in general, and on the procedure in particular, for those who perform EVLT is essential. All interventionists performing the procedure should be involved in the clinical practice of phlebology and should examine the patients at the vein clinic to justify indications and discuss alternative procedures. Patients should be followed in the office after the procedure to ensure long-term benefit and care. Like any other endovascular procedure, EVLT requires clinical experience. Training can be obtained through fellowship programs, postgraduate courses, and from teaching materials prepared by the national venous societies, as well as by the manufacturers. One of the several educational events offered in the US is the Postgraduate Course of the Annual meeting of the American Venous Forum; the next is being held in San Diego, California, February 9 to 13, 2005. For registration, visit [www.venous-info.com](http://www.venous-info.com) or [www.americanvenousforum.com](http://www.americanvenousforum.com).

### CONCLUSION

Once called a stepchild of vascular disease, chronic venous disorders are finally receiving the long-deserved attention they have needed. This supplement to *Endovascular Today* is a testimony of the progress that has been achieved in the field of minimally invasive treatment of venous disease. We have new and effective tools; to stay successful in the long term, we must use them appropriately. We need credentialed venous interventionists, and we must enforce the high quality control that our patients deserve and expect and that it is our obligation to provide quality education to those who are willing to invest time and effort into the challenging but frequently rewarding field of venous diseases. ●

*Peter Gloviczki, MD, is Professor of Surgery and Chair, Division of Vascular Surgery at Mayo Medical School and Director, Gonda Vascular Center, Mayo Clinic, in Rochester, Minnesota. He has disclosed no financial interest in any product or company mentioned herein. Dr. Gloviczki may be reached at (507) 284-4652; [gloviczki.peter@mayo.edu](mailto:gloviczki.peter@mayo.edu).*



# Establishing a Successful Vein Practice

A few tips on how to go about developing your vein practice.

BY STEVE ELIAS, MD

**A**n interventional specialist or vascular surgeon does not wake up one day and decide that he wants to have a vein practice. Most physicians who treat vein disease either exclusively, or as a major aspect of their practice, have developed their vein practice over time. This article will try to quantify and qualify the various essential components of a vein practice. Most importantly, as with any job, you must like what you are doing. If you enjoy treating patients with vein disease, this article will give you some practical ideas regarding how to elevate your care to the next level for your patients' benefit, and for your own. The concepts presented are from my own experience developing an exclusive vein practice and the experience of others who have similar practices. I do not propose to have all the answers, but hopefully this article will help you organize your thoughts in establishing a vein practice that is right for your own unique personality and practice situation.

## PATIENT POPULATION

Who do you want to treat? This will determine everything else you will need to do: the type of skills, office set-up, equipment, insurance participation, etc. Some vein specialists have an all-encompassing practice that involves cosmetic, symptomatic, chronic venous disease, and wound care patients. Others limit themselves to in-office cosmetic and mildly symptomatic patients with spider veins, saphenous incompetence, and varicose veins. Some do not deal with spider veins, instead sending those patients to dermatologists or plastic surgeons. It is my own personal bias that a vein specialist should be able to manage all aspects of vein disease, from spider veins and telangiectasias to venous ulcers and chronic insufficiency. You can then do whatever is appropriate for each patient. Some of the most grateful patients are those with chronic wounds/ulcers that heal with the care of vein surgeon. Yet there are no concrete rules; just decide what type of patients you wish to treat. This determines everything that follows.

*"Some vein specialists have an all-encompassing practice that involves cosmetic, symptomatic, chronic venous disease, and wound care patients."*

## SKILLS, TECHNOLOGIES, TECHNIQUES

There are a multitude of techniques and technologies available. Most venous pathology can be treated by traditional, minimally invasive vein techniques, or a combination of both. Table 1 presents disease states followed by the various relevant treatment options. The "how to" of each will not be part of this overall view of how to develop a vein practice. I have my own ideas and bias regarding the efficacy of some of these technologies/techniques. I use, or have tried, most of those listed. The majority of my patients are now treated with minimally invasive vein surgery techniques; most of which are available now, although some are in clinical trials.

Table 1 lists the treatment options that are currently available. One should be facile with the traditional, as well as the less-invasive techniques. When evaluating any of the newer technologies, perform some cases of your own before deciding what you need. Do not dismiss any new technique before you have had your own experience with it. To do it any other way would be unfair to you and unfair to the new technology.

## VASCULAR LAB

Almost all of the diagnostic information regarding venous pathology is obtained in the noninvasive vascular lab. Some surgeons perform the studies themselves, whereas others train the technologist to conduct a detailed examination for venous insufficiency. Most labs can image for venous thrombosis, but many do not have a protocol for insufficiency. Almost all therapy is based on the lab find-

ings. Therefore, it is best to standardize the protocol for insufficiency (patient position, augmentation, vein size, valve closure time, etc.). If you are going to allocate resources, good vascular technologists are high on the list of priorities.

Once you have the technologists, it is a good idea to have them observe the various procedures so they have an appreciation for the information you need. For example, once perforators are visualized during a SEPS procedure, the technologist will better understand why you need to know perforator location/size in venous ulcer patients. The more communication there is between the specialist and the lab, the more pathology will be identified. The reports generated from the lab should be detailed. Important information should include the site of insufficiency, valve closure times, size of vein segments, and location of superficial varicosities. One should be able to draw a mental picture of the patient's leg from each written report. This helps to plan therapy and also facilitates insurance authorization.

## SETTING

These techniques can be performed in the office, on an outpatient basis, in ambulatory surgery centers, or in hospital locations. Some techniques, such as sclerotherapy, hook phlebectomy, stripping, and endovenous ablation, can be performed as office or ambulatory surgery procedures. More advanced disease states are usually treated in an ambulatory setting (ie, transilluminated powered phlebectomy, subfascial endoscopic perforator surgery). Others are usually done as in-patient procedures (ie, valve repair or Linton procedure).

Working in the setting in which you are most comfortable is important. There may be particular reasons that you want a primarily office-based practice or ambulatory surgery practice. Usually, most vein surgeons have a practice that encompasses both. There are many excellent vein courses offered throughout the country that address the advantages of office-based practices and how to build them. Also, private or industry courses are available that outline the advantages of a total vein practice (ie, partial office and partial ambulatory surgery setting). In deciding where you want to take care of patients, remember that establishing a vein practice is something that you should enjoy, so don't complicate your setup if you don't need to.

## OFFICE AND STAFF

In general, a vascular surgery or interventional practice consists of patients who have arterial problems that can be life or limb threatening. A general surgery practice treats patients who have some acute event or chronic disabling problem. The mindset of the vein specialist, office staff, and the nature of the office setup should be very different when treating elective, cosmetic, or mildly symptomatic patients with lifestyle-affecting problems.

If one chooses to maintain an arterial or general surgery component to a vein practice, these patients are best seen at separate times. In fact, even if one develops an exclusively venous practice, wound patients and chronic venous disease patients are best seen separately from mildly symptomatic patients. The needs and concerns of these patients are different. To put it bluntly, a below-the-knee amputee is not someone who should be seen in the office at the same time as a postsclerotherapy patient.

By separating the various patient groups, the needs of each patient can be appropriately addressed. Patient needs can range from insurance issues to wound issues to dressing changes. In treating elective vein patients, the surgeon and staff need to think as plastic/cosmetic surgeons, and in caring for arterial or advanced-stage venous patients, the outlook/endpoints are completely different. It is advanta-

**TABLE 1. CURRENTLY AVAILABLE TREATMENT OPTIONS**

<b>Spider Veins</b>	• Laser therapy
<b>Telangiectasia</b>	• Sclerotherapy
<b>Reticular Veins</b>	
<b>Small Varicose Veins</b>	
<b>Saphenous Incompetence</b>	• Inversion stripping and/or ligation • Endovenous ablation-laser energy • Radiofrequency energy • Foam injection
<b>Varicose Veins</b>	• Hook phlebectomy/stab avulsion • Excision • Sclerotherapy • Transilluminated powered phlebectomy
<b>Perforator Incompetence</b>	• Linton procedure • Subfascial endoscopic perforator surgery • Ultrasound-guided sclerotherapy
<b>Deep Venous Insufficiency</b>	• Valvuloplasty • Vein valve transplant • Percutaneous vein valve bioprosthesis

geous to speak with your plastic surgery colleagues or experienced vein surgeons when addressing this very important issue. The right mindset of surgeon and office staff for the particular patient class is the key to success. Most vein patients do not think of themselves as “sick.” In general, they are active people with a problem they would like fixed so they can get back to their lives feeling and looking better.

### INSURANCE PARTICIPATION

The question of being a participating provider or opting out of insurance participation can be a tough issue. To help resolve this matter, you have to get good data as to what amount you are being reimbursed under a particular plan for a particular procedure. Traditionally, our mindset was geared toward the number of cases performed per year and not only the amount of money made per year. Classic thinking said that the more cases done, the more money made. This does not necessarily ring true in our current insurance environment. For example, if an insurance company reimburses \$300 for varicose vein excision and the vein specialist charges more for the same procedure done for cosmetic or non-medically necessary reasons, you can make the same amount of money by caring for fewer patients. Or, as a nonparticipating physician, when the procedure is medically necessary, you will receive greater reimbursement, in general. Volume is no longer the only issue.

The vein specialist needs to re-evaluate his particular reimbursement for particular procedures with particular insurance carriers, and make some educated decisions about which, if any, carriers are worth participating with. Having fewer patients does not always mean less money. As to what fees your market will bear, use the experiences of your plastic surgery colleagues as a guide. What do they charge for rhinoplasty, breast augmentation, or liposuction? It does not mean you can charge what they charge, but for cosmetic or nonparticipating procedures, you will have some idea as to what to charge. Can you equate fixing someone's nose to improving the cosmesis of their legs? You can use this evaluation process to help set your fees appropriately.

### ADVERTISING AND PRACTICE BUILDING

Once all of the previously mentioned elements are in place, you need to let referring physicians and the public know what you can offer them. There are numerous ways to attain this goal. Your approach will depend on your personality, personal energy, and financial resources. The choices range from partnering with your hospital, surgery center, or industry to contracting with various practice

building companies or certain turnkey operations that will do everything. The key is to recognize that vein disease is a self-diagnosed disease: people need only look at their legs to know that they have some sort of vein disease. The “If you build it, they will come” philosophy will work here. Everyone knows someone with some form of vein disease; the question is, what is the best way, in your particular situation, to let them know what you offer?

Partnering with your hospital or ambulatory surgery center gives the most credibility without appearing too blatantly commercial. It gives the legitimacy of an established institution. For instance, I am the Director of the Center for Vein Disease at Englewood Hospital and Medical Center, Englewood, New Jersey. Patients feel they are coming to a hospital-endorsed program. This works for me, it may not work for you. The tradeoff is that the hospital does most of the advertising and they get some benefit from the patients' visits and use of their vascular lab and same-day surgery center. Other vein surgeons have partnered with industry for help, and others have gone out on their own—your choice depends on your personality, resources, and needs.

For instance, many of the companies have preprinted patient and referring physician brochures, which you can send along with an introductory letter. Free vein disease screenings in your office or facility is another way of increasing public awareness. Lastly, community talks promoting vein awareness can also be helpful. You will need to put in your own time, but usually in this case, it is beneficial. For example, our vein screenings, with proper-targeted advertising, bring about 150 new patients for the Center for Vein Disease per year. Of these 150, we have a conversion rate of about 90%. This means some future treatment is performed (ie, vascular lab study, sclerotherapy, minimally invasive procedure, or any combination thereof).

### CONCLUSION

There is no single way to develop a vein practice; there are many. We do not have all the answers, but hopefully with this overview, those surgeons interested will begin a thought process and arrive at a plan. I, as well as others, am available to help you in attaining your goals. Developing a vein practice, if your heart is in it, is extremely satisfying and enjoyable. But you have to really want to treat vein disease, that's key. ●

*Steve Elias, MD, is Director of the Center for Vein Disease at Englewood Hospital and Medical Center, Englewood, New Jersey, and Assistant Clinical Professor of Surgery at Mount Sinai School of Medicine, New York. Dr. Elias may be reached at (201) 816-0666; veininnovations@aol.com.*

# Reimbursement: Coding, Coverage, and Payment

How Medicare and insurance reimbursement policies adapt to incorporate novel therapies such as EVLT.

BY CATHERINE MORRIS, RN, BSN, CCM, MHSA

Each year, the health care system is flooded with an array of new products and technologies, most offering safe, effective, less-invasive alternatives to current (traditional) treatments. Some demonstrate cost savings; others increase cost but improve quality of life. A mechanism for evaluation is essential to ensure consumer quality and, for Medicare, to maintain budget neutrality.

There are innumerable health insurance plans in the US, most with their own caveats. Many follow Medicare policy, often guided by the Medicare technology assessment. Technology assessments identify new medical products and procedures that have regulatory approval, are safe and effective, are as beneficial as the alternatives, and can be provided outside the investigational setting. Payors will review clinical trials and will be looking for peer-reviewed literature and broad acceptance from involved professional medical associations.

## CODES

Developers introduce new technologies into the health care system through clinical thought leaders. Part of dissemination into the system involves payment. Payment is often (but not always) determined by a code. A code is a numeric identifier and tracking device used to communicate between providers and payors. If there is a pre-existing code that exactly describes the new procedure, it is acceptable to use that code. For many new procedures, however, there is no existing code. These procedures must be billed using an unlisted code. Any new technology must be on the market for a minimum of 6 months before a code can be requested. Once requested, processing time is approximately 24 months for an ICD-9 code, up to 15 months for a HCPCS code, and 27 months for a CPT code.

Codes serve to track utilization and establish reim-

*"A mechanism for evaluation is essential to ensure consumer quality and, for Medicare, to maintain budget neutrality."*

bursement rates for facility and professional services. Sometimes, a temporary ("S" code) may be assigned to track a new technology.

Existing codes fit the system, allowing electronic data to be processed in a timely and uneventful fashion. However, unlisted codes require supplemental information, manual billing, and delayed payment. This is clearly an inconvenience, but it also presents an opportunity for clinicians to educate payors both in terms of the procedure, as well as the value and impact on clinical practice and patient outcomes. Educating payors helps them to become familiar with, and have a clear understanding of, the new technology, which will help facilitate a positive coverage decision and realistic payment.

There are always concerns regarding the level of payment that should be requested and that which will be received. A practical solution is to compare the new technology with what it is replacing (or another similar procedure). How does it compare in relation to the physician learning curve, length of time for the procedure, relative level of difficulty, danger to patient, consumption of resources, etc.

## CODE DETERMINATION

When a code is requested, the American Medical Association (AMA) will survey medical experts to determine the relative value of the new technology compared to current technology. This relative value unit (RVU) will determine the physician payment.



Physician payment is based on the RVU multiplied by a conversion factor. The Medicare conversion factor for 2004 is \$37.3374.

If the new technology is an office-based procedure, the AMA will add a component amount for practice expense and an additional amount for liability insurance. These three elements represent the resource-based relative value scale (RBRVS).

*"It is important to remember that non-Medicare carriers often relate payment to Medicare reimbursement."*

Medicare is a prospective payment system. There is a predetermined payment for inpatient care, hospital outpatient care, and ambulatory surgical center care, based on clinical similarity and consumption of resources. It is up to the provider to identify and commit to the value of a new technology. Once coded, it too will be placed within the prospective payment system. Time spent with an unlisted code can be invaluable in helping the payor to place the technology in a financially appropriate category. It is incumbent upon the provider to establish this level of value. It is important to remember that non-Medicare carriers often relate payment to Medicare reimbursement.

#### **EVLt CODING—NEW CPT CODES RELEASED**

EVLt has obtained written coverage policies from more than 50 carriers, including large national programs and smaller regional carriers, covering more than 150 million lives. In November 2004, specific CPT codes for endovenous laser ablation were released that will take effect in January of 2005 and are defined as follows:

•36478: Endovenous ablation therapy of incompetent vein, extremity, inclusive of all imaging guidance, monitoring, percutaneous, laser, first vein treated.

•36479: Second and subsequent veins treated in a single extremity, each through separate access sites (list separately in addition to code for primary procedure).

These codes also have been assigned relative values for payment. The unadjusted national average Medicare reimbursement is:

•36478: \$2041.16 for office-based procedures or \$364.57 "professional payment" when services are provided within a hospital facility. Facilities would then be

reimbursed according to applicable ambulatory payment classification codes.

•36479: \$437.00 for office-based procedures or \$178.11 when services are provided within a hospital facility.

Lastly, Geographic Practice Cost Indices (GPCI) are applied to determine a final Medicare payment rate. The GPCI have the same effect on payment for EVLT as they do for all other procedures and practitioners should be aware of their specific adjustment factors.

#### **DIOMED'S REIMBURSEMENT SUPPORT DEPARTMENT**

Since FDA clearance of EVLT in 2002, physicians have proactively worked to educate insurance carrier medical directors and have presented the procedure's safety and efficacy to technical assessment/review committees. Diomed's (Andover, MA) Reimbursement Support Department has supported these activities while also educating ancillary health care experts, such as registered nurses, case managers, and utilization review specialists through certified continuing education programs. This grassroots effort has proven to be one of the most effective ways to introduce a new technology, and for medical providers to educate the payor community.

#### **CONCLUSION**

The standard of care is changing. Physicians are moving from surgical procedures to less-invasive technologies. Patients are educated consumers. They expect new technology and are willing to press their carriers for coverage. Many are willing to pay out of pocket for proactive, noninvasive procedures that add value to their overall wellness. For example, people are willing to pay \$1,000 for a "Wellness" body scan to assure themselves that they are free of disease. Many people will pay for EVLT to address the issue before reflux disease develops. It is incumbent upon the practitioner, with support from the manufacturer, to identify the best technologies and advocate for equitable coverage and payment. ●

*Catherine Morris, RN, BSN, CCM, MHSA, is Director For Reimbursement, Diomed, Inc., Andover, Massachusetts. Ms. Morris may be reached at (978) 824-1853; cmorris@diomedinc.com.*

1. Rautio T, Ohinmaa A, Perala J, et al. Endovenous obliteration versus conventional stripping operation in the treatment of primary varicose veins: a randomized controlled trial with comparison of the costs. *J Vasc Surg.* 2002;35:958-965.