

Management of Femoral Arterial Access: To Close or Hold Pressure?

Manual compression may not be benign, but is it the lesser of two evils?

BY THOMAS M. TU, MD, AND JENNIFER A. TREMMEL, MD, SM

When Seldinger introduced a novel technique for percutaneous vascular access in 1953, he also reported a method to achieve hemostasis at the entry site, “20 to 30 minutes of hand-held pressure after catheter removal followed by overnight bedrest.”¹ Since then, manual compression has remained the gold standard for access site management, essentially using the same method reported more than 50 years ago. Despite subsequent evolution in percutaneous arterial procedures, access site management remained largely unchanged until the development of interventional cardiovascular procedures during the 1980s and 1990s. The use of larger sheaths and multiple anticoagulants increased the risk of bleeding complications, demonstrating the need for better hemostatic techniques. Other concerns, including patient comfort and catheterization lab throughput, have also encouraged innovation. Vascular closure devices (VCD) were developed in response to the limitations of traditional manual compression.

A wide variety of devices, including sutures, plugs, clips, gels, and patches have since been designed and approved to address access site management. Although these products have significantly increased the options available for the practitioner, several shortcomings remain. Issues such as cost, device complexity, and complication rates have kept VCDs from supplanting manual compression as the standard for access man-

agement. No single access management scheme, either manual compression or VCD, is ideal for the entire spectrum of patients and anatomy. With the recent increase in peripheral interventional procedures, the next challenge in vascular access management will be the broader application of closure in complex situations and non-traditional access sites.

LIMITATIONS OF MANUAL COMPRESSION

Manual compression is an often-underappreciated task performed at the conclusion of a percutaneous arterial procedure. It has been described as “problematic... unglamorous, time-consuming, and potentially

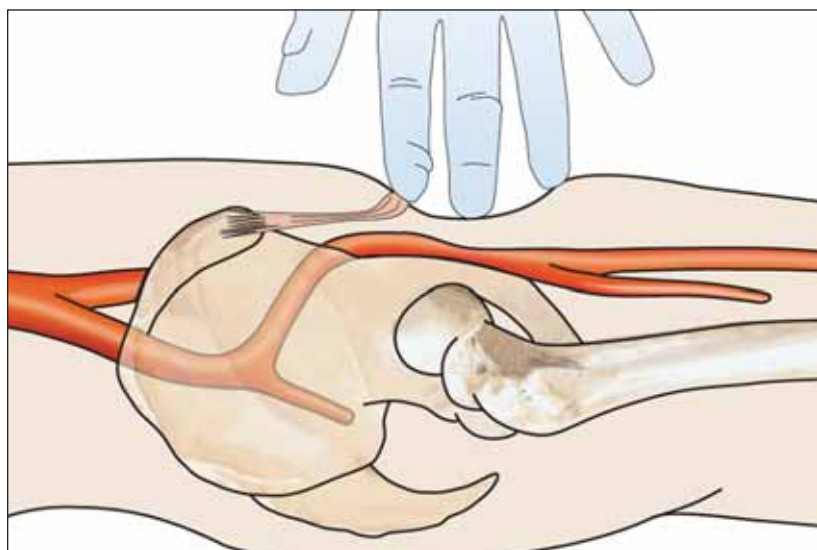


Figure 1. Manual hemostasis is achieved by compressing the femoral artery between the index and middle fingers anteriorly and the femoral head posteriorly. Fingers are placed directly over the arteriotomy site, allowing visualization of the skin entry point to assess for bleeding. Proper positioning of the patient will reduce the risk of chronic injury for the caregiver.

lethal,” yet it remains the standard means of achieving hemostasis after catheterization.² Procedures are often performed in a busy outpatient setting, with speed and efficiency being primary concerns. Patients are commonly held supine for 4 to 6 hours after manual sheath removal, straining staff and slowing workflow. The compression and bedrest can be uncomfortable for elderly patients and those with orthopedic problems. Manual compression is also challenging for those with obesity or peripheral arterial disease, which can make it difficult to achieve hemostasis manually. Caregivers who perform a large number of these procedures are at risk of repetitive stress injury, particularly if proper ergonomic technique is not followed (Figure 1).³

“Manual compression is an often-underappreciated task performed at the conclusion of a percutaneous arterial procedure.”

Despite the importance of proper manual compression technique to procedural outcomes and patient comfort, it is typically learned through an apprenticeship process: see one, do one, teach one. A wide variety of healthcare workers perform compression, leading to significant variation in technique and skill level. Protocols for manual compression method, hold times, and time to ambulation vary widely across institutions. There has been little literature to establish a widely accepted standard for practice.

Although it has been known that VCDs can cause some degree of local injury, recent concern has been raised about a similar phenomenon occurring with manual compression. Inflammation and scarring of the arteriotomy and surrounding soft tissue may lead to vessel stenosis and limit ability for reaccess. In a porcine model of arterial closure, 30 days after percutaneous arterial sheath insertion, mononuclear infiltrate and fibrous deposition were seen in the arterial wall and subcutaneous tissues consistent with fat necrosis.⁴ The severity of these changes was similar between arteries closed with manual compression and a collagen sponge. Silver and Quintero⁴ concluded that pressure injury from both manual compression and device implantation was the major contributor to this process. Another study evaluated the external appearance of the healed femoral arteriotomy via surgical exposure an average of 2 weeks after diagnostic angiography.⁵ Allie et al⁵ used a semiquantitative method to assess the severity of periadventitial morpho-

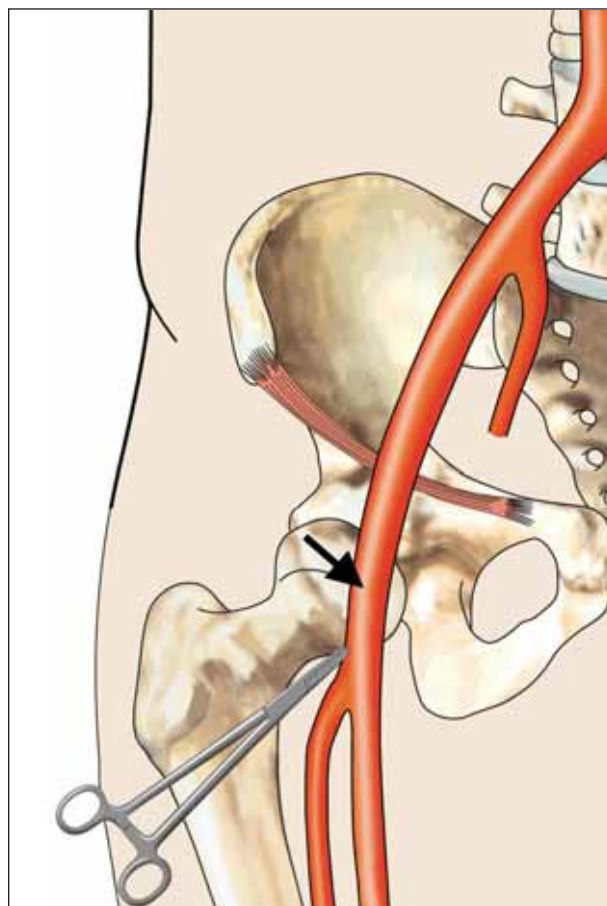


Figure 2. The proper skin entry point is identified by marking the inferior border of the femoral head using fluoroscopy (clamps). The ideal arterial entry point (arrow) overlies the center of the femoral head.

logic changes. Although VCDs were associated with significant scarring and inflammation, it was notable that those closed with manual compression showed these changes to a similar degree.

MANUAL COMPRESSION REMAINS A FUNDAMENTAL TECHNIQUE

Despite the fact that VCDs have been shown to reduce time to ambulation and improve catheterization lab efficiency,^{6,7} there are several reasons why manual compression remains a fundamental component of sheath management. The initial cost is lower, although the benefit might be reduced by increased staffing requirements. Certain patients probably do not require prolonged bedrest after achieving hemostasis. In a study by Doyle et al, low-risk patients (diagnostic catheterization through a 5-F sheath, no anticoagulation) had excellent outcomes with 10 to 15 minutes of manual compression and 1 hour

of bedrest followed by 1 hour of observation after ambulation.⁸ The reported risks of minor (3.3%) and major (.1%) complications were quite low. It should be noted that this degree of success was achieved in a center with a large and experienced nursing staff. These results may not be generalized to smaller institutions with less extensive training on hemostatic techniques.

Despite the large number of devices and techniques available, VCDs have not clearly been shown to reduce the incidence of bleeding and vascular complications when compared with traditional compression.⁹⁻¹¹ Also, many patients are not good candidates for closure for anatomical reasons. Angiography is recommended before deployment of VCDs to ensure a single front-wall common femoral arterial puncture (Figure 2). These devices are not indicated for use in patients with an arteriotomy above the inguinal ligament or below the femoral bifurcation. A study of entry points in 200 consecutive femoral arterial procedures demonstrated that access was suboptimal in 54% of patients and completely outside the common femoral arterial in 13%.¹² Many other access misadventures can occur, including multiple punctures, side/back-wall sticks, and arterial puncture through the femoral vein (Figure 3). Occasionally, a VCD will fail due to improper deployment or inability to obtain hemostasis. Traditional VCDs do not deal well with these complex situations, leaving manual compression as the default management option.

Additionally, VCD use is often precluded due to the presence of atherosclerotic plaque or a bypass graft. Given the recent increase in the number and type of cardiac and endovascular procedures being performed, many patients are having repeat procedures via the same access point. Furthermore, these patients are likely to have complicating factors such as peripheral arterial disease and scarring of the surrounding soft tissue. Techniques that allow for immediate re-entry and preserve the site for future access should be favored. For these reasons, manual compression continues to be a mainstay of arterial access management.

CURRENT VCDs ARE LIMITED BY RATES AND SEVERITY OF COMPLICATIONS

Despite the initial promise of VCDs, complication rates compared with manual compression have dampened enthusi-

asm about their widespread use. Koreny et al published a meta-analysis of 30 VCD trials that reported hematoma rates of 0% to 36% and bleeding rates of 0% to 15%.¹³ In the subset of trials that used intention-to-treat analysis, the risk of hematoma formation and pseudoaneurysm formation was higher with VCDs than with manual compression. These bleeding complications are uncomfortable for the patient and can lead to additional testing, procedures, and length of hospital stay. VCDs do not seem to reduce the risk of retroperitoneal bleeding in patients who undergo coronary intervention.¹⁴ Because access site bleeds and the need for transfusion in patients with acute coronary syndromes are associated with adverse cardiac events, preventing these complications is important to improving short- and long-term outcomes.^{15,16} Novel closure devices must be effective in reducing bleeding complications—not just time to ambulation—if they are to replace manual compression as the standard of care.

Even more concerning are the rare but catastrophic complications that are unique to VCD use. There are several examples in the literature of VCD-related complications, such as device entrapment, arterial stenosis/thrombosis, perforation, and infection.¹⁷⁻²⁰ The

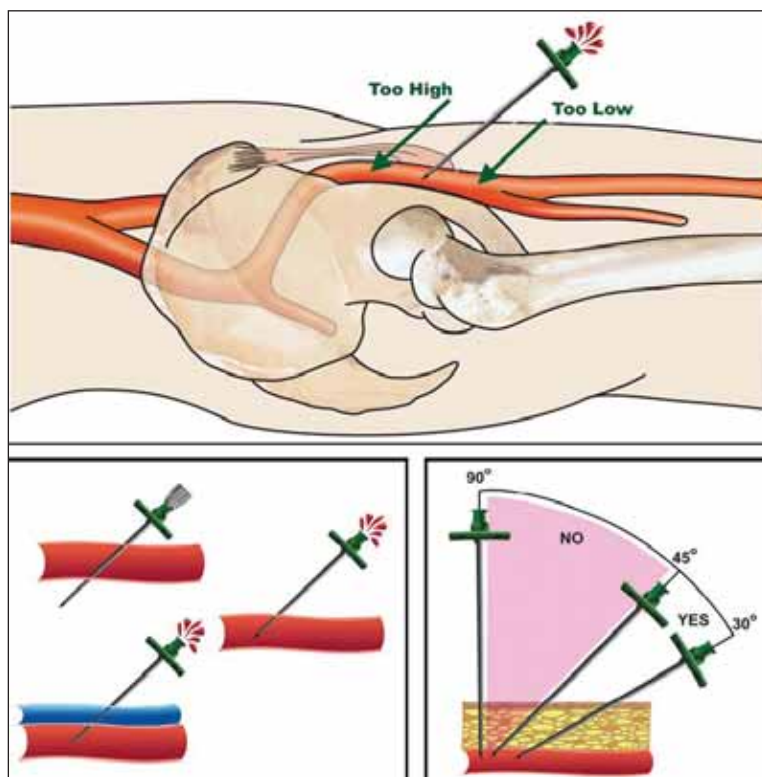


Figure 3. Suboptimal arterial sticks: too high, too low, puncture through the back wall, puncture through the femoral vein into the artery, and too steep of an approach angle.

consequences of these events are considerable and include neurologic injury, limb loss, and even death. Because the chief benefit of vascular closure is one of convenience due to early ambulation, the expectation of safety should be quite high. Improving safety is a critical feature for the next generation of closure devices.

“Techniques that allow for immediate reentry and preserve the site for future access should be favored . . . manual compression continues to be a mainstay of arterial access management.”

There are several technical reasons why VCDs have yet to meet their promise of rapid, safe, and reliable hemostasis. Despite several successive generations of these devices, they remain somewhat complex to use. Failure to apply proper techniques or use in high-risk patient and anatomical subsets increases the likelihood of complications. In the event of deployment failure, many devices do not have a bailout mechanism that allows reattempt at closure. By depositing foreign material in the vessel and soft tissue, there is a risk of infection and thrombosis. These devices can be improved by the development of an atraumatic mechanism of closure and avoidance of retained material.

CONCLUSION

The objectives for ideal access management include minimizing patient discomfort, reducing bleeding and other vascular complications, facilitating early ambulation, and preserving the entry site for future procedures. Accomplishing these goals requires a comprehensive approach, starting with proper placement of the arterial puncture and ending with the correct choice and implementation of the access management method. Many options are available, and decisions should be tailored to the individual patient and situation. Factors such as patient gender, size, and anticoagulation status play a role, as do their anatomical features.

Manual compression has long been considered the standard of care, having changed little despite 5 decades of technological advancement. VCDs have been developed to improve the process of hemostasis; however, barriers remain to widespread adoption. VCDs have been successful in decreasing time to ambulation but have not reduced the rate of serious complications. Their use is contraindicated in many patient subsets. The retained foreign material used in these devices may

paradoxically increase the severity of complications due to the risk of vessel thrombosis and infection. There is still a need for a vascular access management system that provides rapid and robust hemostasis while addressing the shortcomings of indwelling VCDs. ■

The authors would like to thank Duane Pinto, MD, and Bernadette Longo, PhD, for their editorial assistance in the preparation of this manuscript.

Thomas M. Tu, MD, is the Cardiac Catheterization Lab Director, Louisville Cardiology, in Louisville, Kentucky. He has disclosed that he is the Principal Investigator of the Boomerang Catalyst Trial and receives research funding from Cardiva Medical, Inc. Dr. Tu may be reached at (502) 893-7710; ttu@bellsouth.net.

Jennifer A. Tremmel, MD, SM, is an interventional cardiologist and instructor, Cardiovascular Medicine, Stanford University Medical Center, in Stanford, California. She has disclosed that she holds no financial interest in any product or manufacturer mentioned herein. Dr. Tremmel may be reached at (650) 725-2621; jtremmel@cvmed.stanford.edu.

1. Seldinger SI. Catheter replacement of the needle in percutaneous arteriography. *Acta Radiol.* 1953;39:366-376.
2. Hoffer EK, Bloch RD. Percutaneous arterial closure devices. *J Vasc Interv Radiol.* 2003;14:865-885.
3. Allie DE, Smalling R, Hebert CJ, et al. The cost of VAM complications. *Endovasc Today.* 2006;5:21-28.
4. Silver FH, Quintero L. Comparison of the histological responses observed at the arterial puncture site after employing manual compression and a new collagen technology to achieve hemostasis. *Cath Lab Digest.* 2004;11:52-58.
5. Allie DE, Hebert CJ, Walker CM, et al. Manual compression may not be benign. *Endovasc Today.* 2003;4:42-46.
6. Baim DS, Knopf WD, Hinohara T, et al. Suture-mediated closure of the femoral access site after cardiac catheterization: results of the Suture To Ambulate and Discharge (STAND I and STAND II) trials. *Am J Cardiol.* 2000;85:864-869.
7. Kapadia SR, Raymond R, Knopf W, et al. The 6Fr Angio-Seal arterial closure device: results from a multimer prospective registry. *Am J Cardiol.* 2001;87:789-791.
8. Doyle BJ, Konz BA, Lennon RJ, et al. Ambulation 1 hour after diagnostic cardiac catheterization: a prospective study of 1009 procedures. *Mayo Clin Proc.* 2006;81:1537-1540.
9. Carey D, Martin JR, Moore CA, et al. Complications of femoral artery closure devices. *Cathet Cardiovasc Interv.* 2001;52:3-7.
10. Dangas G, Mehran R, Kokolis S, et al. Vascular complications after percutaneous coronary interventions following hemostasis with manual compression versus arteriotomy closure devices. *J Am Coll Cardiol.* 2001;38:638-641.
11. Resnic FS, Blake GS, Machado LO. Vascular closure devices and the risk of vascular complications after percutaneous coronary intervention in patients receiving glycoprotein IIb/IIIa inhibitors. *Am J Cardiol.* 2001;88:493-496.
12. Schnyder G, Sawhney N, Whisenant B, et al. Common femoral artery anatomy is influenced by demographics and comorbidity: implications for cardiac and peripheral invasive studies. *Cathet Cardiovasc Interv.* 2001;53:289-295.
13. Koren M, Riedmuller E, Nikfarjam P, et al. Arterial puncture closing devices compared with standard manual compression after cardiac catheterization. *JAMA.* 2004;291:350-357.
14. Farouque HM, Tremmel JA, Raissi Shabari F, et al. Risk factors for the development of retroperitoneal hematoma after percutaneous coronary intervention in the era of glycoprotein IIb/IIIa inhibitors and vascular closure devices. *J Am Coll Cardiol.* 2005;45:363-368.
15. Rao SV, O'Grady K, Pieper KS, et al. A comparison of the clinical impact of bleeding measured by two different classifications among patients with acute coronary syndromes. *J Am Coll Cardiol.* 2006;47:809-816.
16. Rao SV, Jollis JG, Harrington RA, et al. Relationship of blood transfusion and clinical outcomes in patients with acute coronary syndromes. *JAMA.* 2004;292:1555-1562.
17. Sohail MR, Khan AH, Holmes DR Jr, et al. Infectious complications of percutaneous vascular closure devices. *Mayo Clin Proc.* 2005;80:1011-1015.
18. Hollis HW, Rehning TF. Femoral endarteritis associated with percutaneous suture closure: New technology, challenging complications. *J Vasc Surg.* 2003;38:83-87.
19. Fowler SJ, Nguyen A, Kern M. Trapping of vascular clip closure device in previously accessed closure site. *Cathet Cardiovasc Interv.* 2007;70:62-64.
20. Shaw JA, Graveriaux EC, Winters GL, et al. An unusual case of claudication. *Cathet Cardiovasc Interv.* 2003;60:562-565.