

Proximal Occlusion and Flow Reversal

The ideal cerebral protection method during carotid artery stenting.

BY JUAN C. PARODI, MD (FACS HON.); FEDERICO E. PARODI, MD;
AND CLAUDIO SCHÖNHOLZ, MD



It is recognized that embolization to the brain is a universal occurrence during carotid artery stenting (CAS) procedures. Information comes through several well-conducted *ex vivo* studies,¹⁻³ by the routine use of transcranial Doppler monitoring (TCD), and by analyzing the blood aspirated after the use of distal occlusion balloons. It is also widely agreed upon that the goal of cerebral protection during CAS is to suppress or decrease the number of particles and/or air bubbles reaching the brain during the procedure.

FACTORS CONTRIBUTING TO EMBOLIZATION

Embolization occurs during every stage of CAS, but embolic protection starts once the cerebral protection device is deployed and finishes when it is retrieved; this means that embolization can still occur during the initial placement of the guide catheter in the artery and can also be seen after the procedure is completed. Careful technique and limitation of instrumentation is crucial to reduce or suppress embolization during the initial phase of the procedure, and administration of antiplatelet medication and appropriate use of stents of adequate size and cell configuration will sufficiently address most of the postprocedure emboli.

Crossing the lesion produces significant embolization (40,000 particles on average).³ In our study of carotid plaques after endarterectomy, we found that 24% of

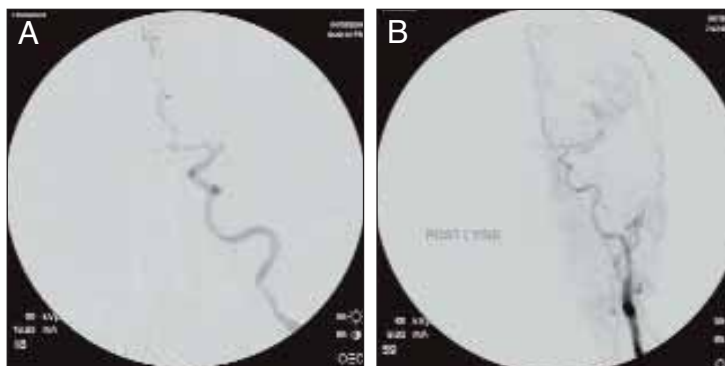

Figure 1. Embolic middle cerebral artery occlusion after crossing a carotid lesion with a filter during CAS (A). Middle cerebral artery is patent after mechanical thrombectomy and lytic therapy (B).

plaques have thrombus lining.⁴ In a study performed at Stanford, the incidence was 49%.⁵ Thus, embolization caused while crossing the lesion can be critical, as was evidenced in one of our clinical cases, which ended with a complete occlusion of the middle cerebral artery after crossing an irregular lesion of the internal carotid artery with a filter (Figure 1A); fortunately, we were able to treat the occlusion with full recovery of the patient (Figure 1B).

IMPACT OF EMBOLIZATION

Outcomes after CAS are related to multiple factors, including age of the patient, symptoms, plaque morphology, cerebral functional reserve, arch anatomy, experience of the operator, and cerebral protection device used,

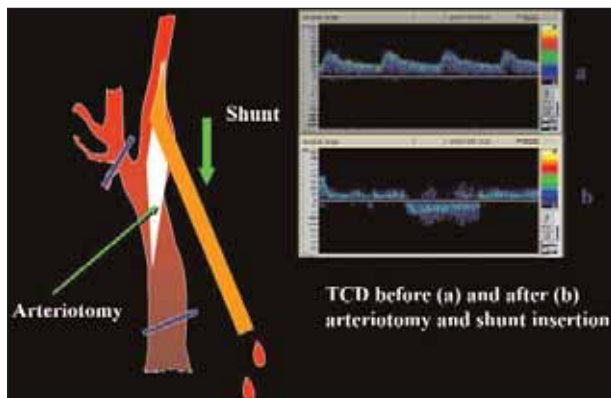


Figure 2. Observation during open carotid endarterectomy using transcranial Doppler monitoring.

among others. There is not yet proof that micro embolic signals (MES) or high-intensity transitory signals (HITS) are related to new lesions using diffusion-weighted MRI studies. Correlation between these factors and cognitive function is still debatable. It is recognized, however, that HITS are better tolerated in young patients with good cerebral functional reserve than in older individuals with low functional reserve. It seems reasonable to say that HITS cannot do any good to the brain, and their occurrence should be at least a reason for concern. Until we have conclusive evidence about HITS and its potential damage to the brain, we prefer to try to suppress or minimize its occurrence. Flow reversal appears to be closer to the ideal device when CAS is undertaken.

Subtle changes in cognitive function are currently being assessed after CAS. What is already known is that silent cerebral infarcts are relevant because they produce a steeper decline in cognitive function and increase the incidence of dementia.⁶

Deleterious effects of iodinated contrast media injected in the cerebral vasculature are well-described. Using flow reversal, contrast can be readily aspirated once the injection has delineated the artery or arteries interrogated. Bubbles that are trapped in the delivery system were detected during stent deployment; aspiration will bring those bubbles out of the body using flow reversal.

PRINCIPLES OF FLOW REVERSAL

We made an observation during an open carotid endarterectomy using transcranial Doppler monitoring. Clamping the common and external carotid artery and inserting a shunt in the distal end of an arteriotomy induced flow reversal in the middle carotid artery if the other end of the shunt was left open to the air (Figure 2). Initially we were using the same principle through a small incision done at the base of the neck. We used a short, 7-F introducer placed in

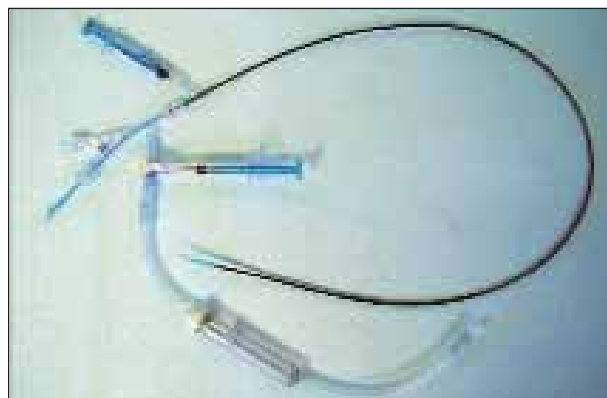


Figure 3. The first-generation reversal-of-flow catheter (Gore & Associates, Flagstaff, AZ).

the CCA facing the lesion and occluding the ECA with a coronary balloon. The side port of the arterial line was then connected to a side port of a sheath placed in the internal jugular vein. Very soon we developed a long arterial sheath with a balloon at its end (Figure 3). We designed the tip of the catheter in such a way that particles could not be trapped around the distal guiding catheter (Figure 4). We also developed an external balloon mounted in a hypotube and a filter to be placed in between the side port of the artery line and a venous sheath placed in the femoral vein.

Gradient between the ICA and the femoral vein produces flow reversal in the ICA. Intermittent aspiration enhances flow reversal during critical stages of CAS and before injecting contrast media in the guiding sheath.

SHORTCOMINGS AND POTENTIAL DANGERS OF FILTER PROTECTION

Showers of particles are often seen during lesion crossing (Figure 5), and the need for predilatation to allow the filter to cross the lesion produces a significant increase in the incidence of stroke. This is a significant distinction between the use of embolic protection filters and the concept of flow reversal. Using flow reversal, protection is established before crossing the lesion.

Pore Size Versus Particle Size

The pore size of filters generally ranges from 100 μ m to

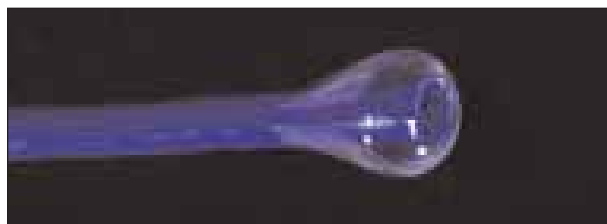

Figure 4. The distal balloon of the reversal-of-flow system.

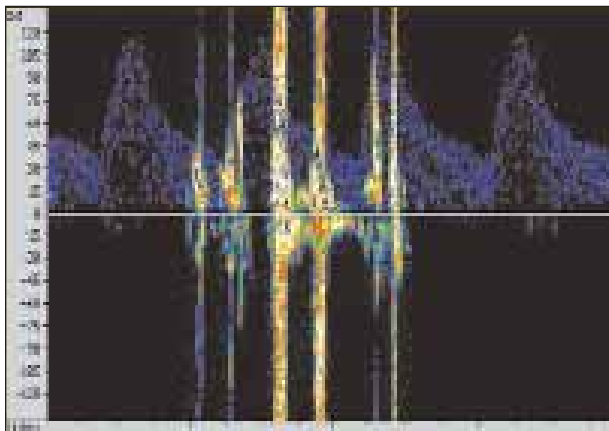


Figure 5. Transcranial Doppler image of showers of particles during lesion crossing.

120 μm . However, it is known that most of the particles generated during stenting are smaller than 100 μm .¹⁻³ Particles larger than 50 μm are known to produce ischemic lesions in experimental animals in which particles are injected through needles or catheters into the cerebral circulation.⁷

HITS

HITS or (MES) are detected throughout the procedure when filters are utilized. This is clearly reproducible using TCD monitoring. In addition new lesions utilizing diffusion-weighted MRI studies are seen after CAS protected with filters.⁸ Particles and bubbles pass through and around the filters. Apposition is variable according to which filter is used. Filters effectively capture big particles (more than 100-150 μm) providing that the apposition of filters are perfect. This is another significant difference between filters and flow reversal. When flow reversal is established, it is impossible by definition to embolize the brain. Proximal occlusion *per se* decreases the number of particles in comparison to filters, but complete suppression of emboli is only seen with flow reversal (Figure 6).⁹

Unsuitable Anatomy

Filters are not appropriate when the internal carotid artery is tortuous. A pin-point lesion can not be crossed with a filter unless is predilated under no protection. The need to use a “buddy wire” increases the risk of producing emboli. In addition, spasm and dissections of the internal carotid were described after using filters. Incomplete apposition of filters to the wall allows particles to pass by the filter. If filters become full of material, excess material remains outside and later embolizes. Removing a filter full of material can induce embolization by squeezing the filter.

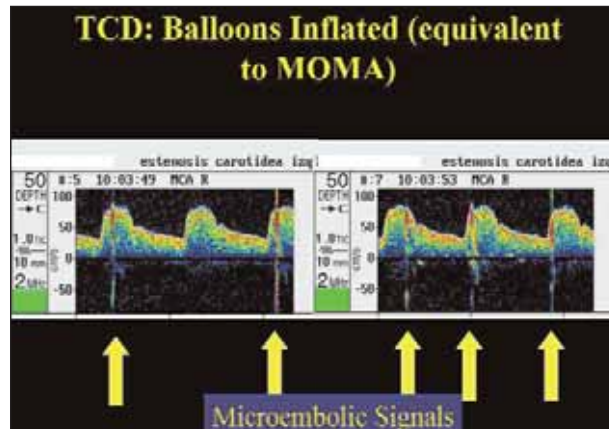


Figure 7. Transcranial Doppler image during CAS with proximal occlusion without reversal of flow shows presence of HITS.

Plaque Morphology

Plaque morphology appears to be a very important variable during CAS. Neurological events using filters in cases of echolucent lesions (gray scale median <25) occurred in 12.9 % of the cases reported in the ICARUS registry.¹⁰ Several studies showed a significant number of new lesions on diffusion-weighted MRI when filters were utilized during CAS.^{11,12} Even though we do not have complete information about these changes using flow reversal, the number of particles embolizing the brain is drastically reduced using this procedure.

FLOW REVERSAL PRECAUTIONS

One disadvantage of flow reversal is the lack of flow that produces intolerance in a small percentage of patients. Despite the intolerance that has been seen in approximately 5% of our patients, all procedures could be completed either by disregarding symptoms of intolerance that were related with cloudiness of conscience or by completing the procedure in stages. Cerebral preconditioning has been described using the PercuSurge device (Medtronic, Inc., Santa Rosa, CA) and corroborated by us. Filters allow flow to the brain throughout the procedure unless the filter becomes full of material, which occurs rarely.

Patients with isolated middle cerebral artery flow should not be treated by flow reversal unless pial collaterals are well-established and the stenosis is very severe. In our practice, the very rare cases of isolated middle cerebral artery cases are treated with combination of flow reversal and filters. The lesion is crossed under flow reversal and once the filter is opened the flow is re-established. Flow reversal is applied at the end of the procedure to close and retrieve the filter. We called this maneuver the “air bag-seat belt” technique.¹³

In the occasions we used this combination, particles

COVER STORY

ASSESSING CEREBRAL PROTECTION DEVICES

were captured by both devices indicating the value of the combination and the incomplete protection of filters alone.

CONCLUSION

It seems that it is reasonable to reverse the flow instead of filtrating the blood during CAS in order to suppress or decrease embolization. Drawbacks of proximal occlusion with flow reversal, such as increased profile of the sheath and potential intolerance, should be addressed, and case selection should be defined according to symptoms and anatomy. Evolution of the device includes a 7-F guiding sheath with a shaft with good flexibility and kink resistance completed by Gore & Associates. ■

Juan C. Parodi, MD, is Professor of Surgery, chief of endovascular and clinical vascular surgery, and consultant of vascular surgery at FLENI Institute in Buenos Aires, Argentina. He has disclosed that he is a shareholder in Gore & Associates. Dr. Parodi may be reached at (305) 878-4850; jparodi@med.miami.edu.

Federico E. Parodi, MD, is a resident of the Department of Surgery at Jackson Memorial Hospital corresponding to Miller School of Medicine of the University of Miami, Florida. He has disclosed that he has no financial interest in any product or company mentioned herein. Dr. Parodi may be reached at (305) 666-8294; feparodi@yahoo.com.

Claudio Schönholz, MD, is Professor of Radiology of the Medical University of South Carolina. Heart and Vascular Center. Charleston, South Carolina. He has disclosed that he is a paid consultant to Gore & Associates.

1. Ohki T, Marin ML, Lyon RT, et al. Ex vivo human carotid artery bifurcation stenting: correlation of lesion characteristics with embolic potential. *J Vasc Surg.* 1998;27:463-471.
2. Rapp JH, Pan XM, Sharp FR, et al. Atheroemboli to the brain: size threshold for causing acute neuronal cell death. *J Vasc Surg.* 2000;32:68-76.
3. Coggia M, Goeau-Brissonniere O, Duval JL, et al. Embolic risk of the different stages of carotid bifurcation balloon angioplasty: an experimental study. *J Vasc Surg.* 2000;31:550-557.
4. Milei J, Parodi JC, Ferreira M, et al. Atherosclerotic plaque rupture and intraplaque hemorrhage do not correlate with symptoms in carotid artery stenosis. *J Vasc Surg* 2003; 38:1241-1247.
5. Bassiouny H, Davis H, Massawa N, et al. Critical carotid stenoses: morphologic and chemical similarity between symptomatic and asymptomatic plaques. *J Vasc Surg.* 1989;9:202-212.
6. Vermeer SE, Prins ND, den Heijer T, et al. Silent brain infarcts and the risk of dementia and cognitive decline. *N Engl J Med.* 2003;348:1215-1222.
7. Heistad DD, Marcus ML, Busija DW, et al. In: Passonneau JV, ed. *Cerebral Metabolism and Neural Function.* Baltimore, MD: Lippincott Williams and Wilkins. 1980:202-211.
8. Jaeger HJ, Mathias KD, Hauth E, et al. Cerebral ischemia detected with diffusion-weighted MR imaging after stent implantation in the carotid artery. *Am J Neuroradiol.* 2002;23:200-207.
9. Schmidt A, Diederich K, Scheinert S, et al. Effect of two different neuroprotection systems. *J of the Am Coll Cardiol.* 2004;44:1966-1969.
10. Biasi GM, Froio A, Diethrich EB, et al. Carotid plaque echolucency increases the risk of stroke in carotid stenting: the Imaging in Carotid Angioplasty and Risk of Stroke (ICAROS) study. *Circulation.* 2004;110:756-762.
11. Jordan WD Jr, Voellinger DC, Doblar DD, et al. Microemboli detected by transcranial Doppler monitoring in patients during carotid angioplasty versus carotid endarterectomy. *Cardiovasc Surg.* 1999;7:33-38.
12. Vos JA, van den Berg JC, Ernst SM, et al. Carotid angioplasty and stent placement: comparison of transcranial Doppler US data and clinical outcome with and without filtering cerebral protection devices in 509 patients. *Radiology.* 2005;234:493-499.
13. Parodi JC, Schönholz C, Ferreira LM, et al. "Seat belt and air bag" technique for cerebral protection during carotid stenting. *J Endovasc Ther.* 2002;9:20-24.