

# Pelvic Congestion Syndrome Update

Diagnostic and therapeutic options for this often unrecognized condition and one center's approach to treatment.

BY COLLEEN J. MOORE, MD

**O**varian vein incompetence can be seen in up to 10% of women, and it is associated with symptoms of pelvic congestion syndrome (PCS) in up to 60% of those women.<sup>1</sup> PCS is often overlooked and undertreated in most venous practices. Reasons for this are multifactorial and include an underreporting of symptoms by women, as well as the fact that there are few cosmetic or external manifestations of the disease. When directly questioned about potential symptoms of PCS, most women are reluctant to answer and openly discuss the condition with their physician. Many women do not view it as a treatable medical condition but rather as something they are destined to endure. Most reports of PCS are primarily observational, and large, prospective randomized trials regarding therapies are few. What follows is a brief description of the manifestations of PCS, as well as our approach to the evaluation and management of this condition.

“Seventy-five percent to 80% of women report an improvement of symptoms within the first 2 weeks after embolization.”

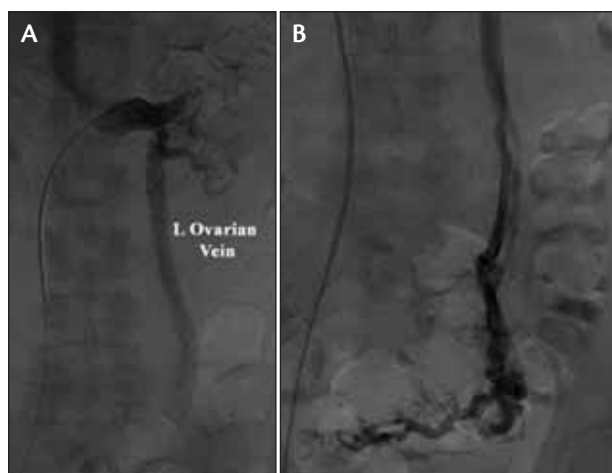
## MANIFESTATIONS

PCS is generally listed under the causes of chronic pelvic pain. This makes it difficult to evaluate because many of the causes of chronic pelvic pain have overlapping symptoms and manifestations. Most women will be young and multiparous. The hallmark symptom is dull, aching lower abdominal pain exacerbated by long periods of sitting or standing. It can be accompanied by feelings of fullness in the legs. Intensity of the pain can vary during phases of the menstrual cycle. Women may describe a feeling of dysuria and frequency similar to that of cystitis. This is secondary to varices that may develop in the trigone region. Dyspareunia is another symptom that often goes unreported by many women afflicted with PCS and can result in avoidance of intercourse and relationship difficulties.

## EVALUATION AND IMAGING

In our practice, women with PCS are often referred from a gynecologist's office. We have worked to develop a collaborative relationship with physicians that specialize in the evaluation and management of pelvic pain. The referring specialist takes a thorough sexual and gynecologic history and completes an examination and imaging evaluation as deemed appropriate. If the initial treatment recommendations are unsuccessful or if no etiology can be determined, the patient is often referred to our practice for PCS.

Another avenue for referrals has been through primary



**Figure 1.** Nonselective venography of the left ovarian vein showing a dilated ovarian vein with reflux (A). Selective catheterization of the ovarian vein is used to visualize the pelvic varices (B).

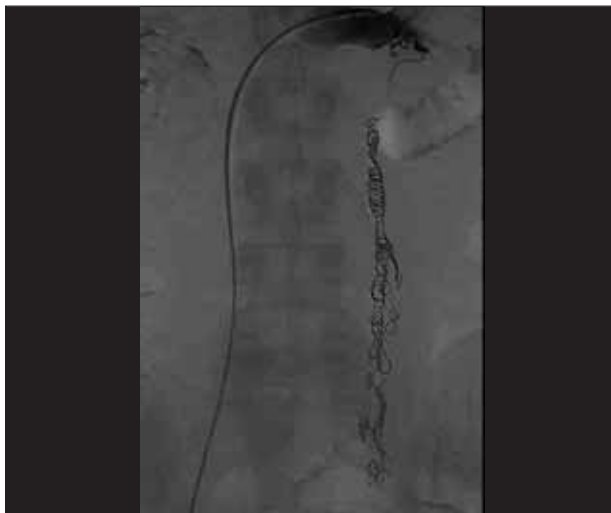

Figure 2. Postembolization venogram showing no further reflux in the ovarian vein.

care physicians. Computed tomography (CT) scans are often ordered for abdominal pain, which show venous varices in the area of the uterus or in the pelvis. In addition, careful review of the images often shows a large, dilated ovarian vein. Once the possible diagnosis of PCS has been raised, patients are often referred for further evaluation.

Upon presentation to our office, the patient's history is gathered and a physical is performed, which concentrates on the symptoms of PCS as well as any lower extremity symptoms that may be associated with chronic venous insufficiency. There are few external manifestations of PCS, and aside from a lower extremity evaluation, no targeted genital or pelvic examination is performed. If the patient's symptoms are believed to be consistent with PCS, imaging can be performed to confirm the diagnosis.

#### Lower Extremity Venous Duplex

A lower extremity venous duplex and standing venous reflux examination are performed because the symptoms of lower extremity venous insufficiency and PCS can overlap, with some PCS patients complaining of pain and fatigue in the legs. Some PCS patients will present with posterior thigh varices that are not in the distribution typical of the great saphenous vein. If the great saphenous vein is found to be incompetent, consideration should be given to alternate etiologies and therapies.

#### Pelvic Ultrasound

This is a noninvasive test that is performed either transvaginally or transabdominally, often in the gynecologist's

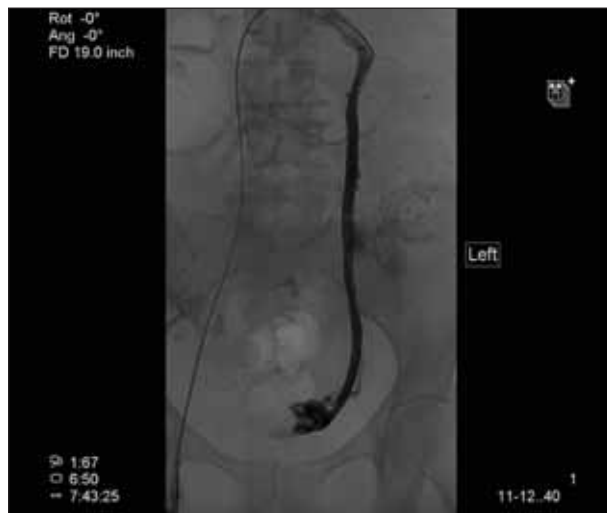

Figure 3. Venographic images of the left ovarian vein showing a dilated ovarian vein and the free reflux of contrast into pelvic varices.

office before a referral for PCS. When used during the initial assessment of pelvic pain, it can be useful to rule out other etiologies of pelvic pain. Diagnostic criteria for diagnosing PCS can be exacerbated by having the patient stand or performing a Valsalva maneuver and are as follows:<sup>2</sup>

- tortuous pelvic vein > 6 mm in diameter;
- blood flow of 3 cm/s or reversed caudal flow;
- dilated arcuate veins in the myometrium; and
- polycystic changes of the ovaries.

#### MRI or CT Venography

Magnetic resonance imaging (MRI) or CT is often performed by primary care providers to evaluate chronic pelvic pain in women. Both studies are excellent for excluding alternate pathology, but visualization of a dilated ovarian vein or parauterine or pelvic variceal complexes is highly suggestive of PCS. Extension of varices to the broad ligament or the paravaginal plexus is often seen as well. Careful review of these studies also demonstrates an easily visible, dilated left ovarian vein. Imaging must be performed in the supine position. Otherwise, this can lead to underestimation or inadequate visualization of the pelvic varices. We do not routinely order MRIs or CTs unless the diagnosis is in question because it extends the evaluation and delays treatment. If CT or MRI imaging are available for review, criteria suggestive of PCS includes:<sup>3</sup>

- four ipsilateral parauterine veins of varying caliber with one measuring > 4 mm in diameter and
- ovarian vein diameter > 8 mm.

### Retrograde Ovarian and Internal Iliac Venography

Ovarian vein venography is performed via cannulation of the left renal vein and remains the gold standard test for diagnosis of ovarian vein reflux and PCS. Although venous access can be obtained from either the jugular or femoral vein approach, it is my preference to cannulate the right common femoral vein.

A Kumpe catheter (Cook Medical, Bloomington, IN) is advanced into the orifice of the left renal vein. If the ovarian vein is difficult to cannulate, a cobra-type or vertebral catheter can be used. Selective left renal and ovarian vein venography are then performed during a Valsalva maneuver or with the table in the reverse Trendelenburg position. The right ovarian vein can be visualized as well and cannulated with the same Kumpe catheter.

Alternate options include a cobra-type catheter or a Simmons-shaped catheter. Reflux can also be exacerbated by tilting the table into a semi-upright position.

These maneuvers often demonstrate an enlarged ovarian vein and reflux into variceal complexes along the pelvic floor. This is often not a subtle finding because contrast is readily visualized, tracking retrograde through the ovarian vein into pelvic varices (Figure 1). The presence of one or more of the following findings on venography is highly suggestive of PCS:<sup>4</sup>

- ovarian vein diameter > 10 mm;
- uterine venous engorgement;
- congestion of the ovarian plexus; or
- filling of the pelvic veins across the midline or filling of thigh varices.

### TREATMENT

Before the advent of endoluminal therapies for PCS, medical therapy with hormonal manipulation was the first-line therapy. Those women whose symptoms did not respond to medical management were then often referred for hysterectomy and oophorectomy. Minimally invasive surgical techniques for oophorectomy or ovarian vein ligation were introduced as less-invasive options. Now that endoluminal therapy is available, these surgical options are often reserved for when all other modalities have failed. Transcatheter therapy for PCS was recently addressed by the American Venous Forum and the Society for Vascular Surgery and given a grade 2B recommendation.<sup>5</sup>

Endoluminal interventions are divided into either sclerotherapy or transcatheter embolization. Both are equally successful in the symptomatic management of PCS and can be combined in some cases. The performance of both procedures begins with retrograde ovarian vein venography as previously described. If ovarian vein reflux is identified, a Glidewire (Terumo Interventional Systems,

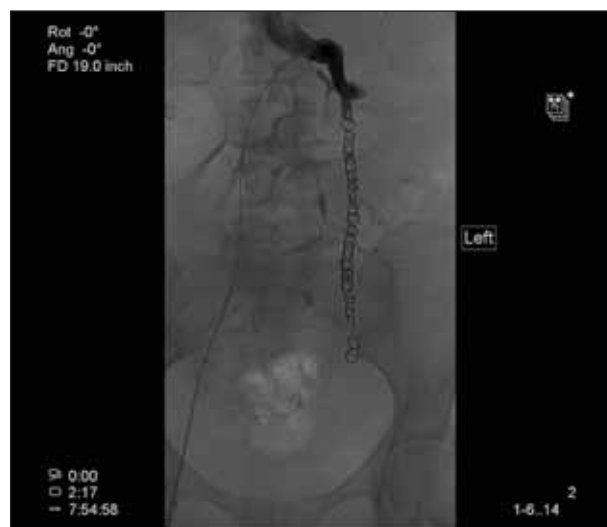

Figure 4. Selective imaging of the left ovarian vein after embolization that shows the coils in place and no further reflux into the pelvic varices.

Somerset, NJ) can be used to advance the Kumpe catheter or a Glide catheter (Terumo Interventional Systems) into the distal ovarian vein for more selective views. This can identify the extent of varices and assess for potential reflux across the midline into the contralateral ovarian vein.

If sclerotherapy and transcatheter embolization techniques are to be combined, sclerotherapy is performed first. The diagnostic catheter is exchanged over a wire for an appropriately sized balloon that is positioned in the proximal ovarian vein. The balloon is inflated to occlude the ovarian vein, and the wire is removed. Contrast is then slowly injected through the wire lumen to opacify the ovarian vein and pelvic varices. The volume of contrast instilled is measured. Once the required volume of sclerosant has been determined, the balloon is deflated.

Although multiple sclerosing agents are available, most practitioners opt for either sodium morrhuate (Luitpold Pharmaceuticals, Inc., Shirley, NY) or sodium tetradecyl sulfate (AngioDynamics, Queensbury, NY). Either agent is combined with contrast and gelfoam to create a slurry that mechanically occludes the pelvic varices and results in chemical phlebitis. The slurry is instilled to occlude the pelvic venous complexes without refluxing into the right ovarian vein and is allowed to remain resident while transcatheter embolization of the ovarian vein ensues.

If combined with sclerotherapy, coil embolization proceeds through the wire lumen of the occlusion balloon that has been left inflated to mechanically occlude the outflow from the renal vein. If performed as a stand-

alone procedure, the diagnostic catheter is advanced into the distal ovarian vein.

Although any 0.035-inch coil can be used, the number of coils required to successfully occlude the entirety of this dilated ovarian vein has led us to primarily use Interlock coils (Boston Scientific Corporation, Natick, MA). These coils come in much larger diameters and in lengths up to 40 cm, which are more appropriate for this indication. Until recently, the Interlock coils required the use of a microcatheter that could be positioned through the diagnostic catheter. This added a step and made the procedure a bit cumbersome; however, a newer 0.035-inch version has been introduced, which remedied this inconvenience. The Interlock coils have the ability to be recaptured until 95% deployed, which allows for optimal placement, especially near the confluence of the ovarian and renal veins. Figure 2 shows a successfully coiled left ovarian vein.

If any reflux is identified within the right internal iliac vein, this can be treated in a similar manner to the left ovarian vein. Access is often easier if approached from the contralateral common femoral vein. Access is achieved, and ablation proceeds just as with the ovarian vein. Technical success is reported in 98% to 100% of cases, with a recurrence rate of < 8%.<sup>2</sup>

## CASE REPORT

A 47-year-old woman was referred to the vascular surgery service for possible PCS. Her symptoms of dyspareunia and pelvic pain had been present for years and were worse with activities such as cycling. The pain associated with intercourse is putting a strain on her relationship with her husband, and she is becoming very frustrated. She has had an extensive evaluation by her gynecologist and underwent multiple failed interventions and therapies.

The symptoms of and treatment for PCS were discussed with her, and she elected to proceed with pelvic venography and possible left ovarian vein embolization. At the time of venography, she was found to have a large, dilated ovarian vein with pelvic varices (Figure 3). These were successfully embolized (Figure 4), and she returned to the office 1 month later for follow-up. She had some worsening pain in the week immediately after the procedure consistent with phlebitis. Subsequent to that, she had a rapid resolution of her symptoms and returned to full activity without pain. She had begun cycling daily and was able to resume a sexual relationship with her husband without pain.

## CONCLUSION

Outcomes with percutaneous intervention for PCS have been very encouraging in our practice, which is consistent

with reported series. Many women return in 4 weeks with near-complete resolution of symptoms. Seventy-five percent to 80% of women report an improvement of symptoms within the first 2 weeks after embolization.<sup>2</sup> Subjectively, they are happier and have resumed activities that they had previously avoided due to pain. As PCS has become increasingly recognized and therapies improved, women can be treated more expeditiously and successfully without requiring major surgery. ■

*Colleen J. Moore, MD, is with the Division of Vascular Surgery, Southern Illinois University School of Medicine in Springfield, Illinois. She has disclosed that she has no financial interests related to this article. Dr. Moore may be reached at (217) 545-7983; cmoore@siumed.edu.*

1. Belenky A, Bartal G, Atar E, et al. Ovarian varices in healthy female kidney donors: incidence, morbidity, and clinical outcome. *AJR*. 2002;179:625-627.
2. Ganeshan A, Upton S, Hon L, et al. Chronic pelvic pain due to pelvic congestion syndrome: the role of diagnostic and interventional radiology. *Cardiovasc Intervent Radiol*. 2007;30:1105-1111.
3. Coakley FV, Varghese SL, Hricak H. CT and MRI of pelvic varices in women. *J Comput Assist Tomogr*. 1999;23:429-434.
4. Kennedy A, Hemingway A. Radiology of ovarian varices. *Br J Hosp Med*. 1990;44:38-43.
5. Gloviczki P, Comerota AJ, Dalsing MC, et al. The care of patients with varicose veins and associated chronic venous disease: clinical practice guidelines of the Society for Vascular Surgery and the American Venous Forum. *J Vasc Surg*. 2011;53:2S-48S.

## GORE® EXCLUDER® AAA Endoprosthesis

**INDICATIONS FOR USE: Trunk-Ipsilateral Leg Endoprosthesis and Contralateral Leg Endoprosthesis Components.** The GORE® EXCLUDER® AAA Endoprosthesis is intended to exclude the aneurysm from the blood circulation in patients diagnosed with infrarenal abdominal aortic aneurysm (AAA) disease and who have appropriate anatomy as described below: Adequate iliac / femoral access; Infrarenal aortic neck treatment diameter range of 19 – 29 mm and a minimum aortic neck length of 15 mm; Proximal aortic neck angulation ≤ 60°; Iliac artery treatment diameter range of 8 – 18.5 mm and iliac distal vessel seal zone length of at least 10 mm. **Aortic Extender Endoprosthesis and Iliac Extender Endoprosthesis Components.** The Aortic and Iliac Extender Endoprostheses are intended to be used after deployment of the GORE® EXCLUDER® AAA Endoprosthesis. These extensions are intended to be used when additional length and / or sealing for aneurysmal exclusion is desired. **CONTRAINDICATIONS:** The GORE® EXCLUDER® AAA Endoprosthesis is contraindicated in patients with known sensitivities or allergies to the device materials and patients with a systemic infection who may be at increased risk of endovascular graft infection. Refer to *Instructions for Use* at [goremedical.com](http://goremedical.com) for a complete description of all warnings, precautions and adverse events. Rx Only



Products listed may not be available in all markets.  
GORE®, EXCLUDER®, and designs are trademarks of W. L. Gore & Associates.  
©2010 W. L. Gore & Associates, Inc. AP0830-EN1 DECEMBER 2010