

# Scoring and Cutting Balloons for SFA Disease Treatment

The role of these devices for percutaneous intervention in this challenging anatomy.

BY MARC BOSIERS, MD; KOEN DELOOSE, MD; JURGEN VERBIST, MD;  
AND PATRICK PEETERS, MD

**P**eripheral artery disease (PAD) has been estimated to affect more than 10 million people in the US and is a multilevel disease involving the femoropopliteal system in more than 50% of cases.<sup>1,2</sup> Bypass surgery has generally been reserved for patients with debilitating symptoms of claudication or as part of the treatment for critical limb ischemia (CLI). More recently, the use of percutaneous transluminal angioplasty has been advocated as an alternative, particularly for TASC A and B lesions and in patients at higher risk of surgical morbidity and mortality.<sup>3</sup>

The percutaneous treatment of superficial femoral artery (SFA) disease has evolved significantly since the initial experience by Andreas Grüntzig with balloon angioplasty in the 1970s.<sup>4</sup> Perhaps more than any other arterial distribution, the treatment of SFA disease has recently witnessed the development of a plethora of new percutaneous devices. These have included a number of atherectomy devices, numerous stent designs, and excimer lasers. However, balloon angioplasty remains the most frequently used technology in the treatment of SFA disease either as primary or adjunctive therapy for stents and other devices.

Conventional balloons are associated with a high rate of uncontrolled dissections that may require bailout stenting, particularly in more complex and diffuse SFA lesions. They may also result in inadequate luminal expansion particularly in fibrocalcific lesions that may be resistant to conventional balloon dilatation. Balloons have also been associated with a low primary patency rate and the resultant frequent need for repeat revascularization.<sup>5</sup>



Figure 1. Inflated cutting balloon with atherotomes exposed.

Recently, several new specialized balloons have been developed to help address some of the limitations of conventional angioplasty balloons in the treatment of complex and diffuse SFA disease. These have included new scoring and cutting balloons, which will be described in more detail and are the main focus of this review article. These devices were developed to overcome certain limitations of conventional balloon angioplasty by concentrating the dilating force along the scoring element or atherotomes, thereby theoretically resulting in more predictable luminal expansion, a lower rate of uncontrolled dissections, and less barotrauma.

## CUTTING BALLOON

The Cutting Balloon (Boston Scientific Corporation, Natick, MA) was first developed in the mid-1980s for




Figure 2. AngioSculpt Scoring Balloon Catheter (5 X 40 mm).

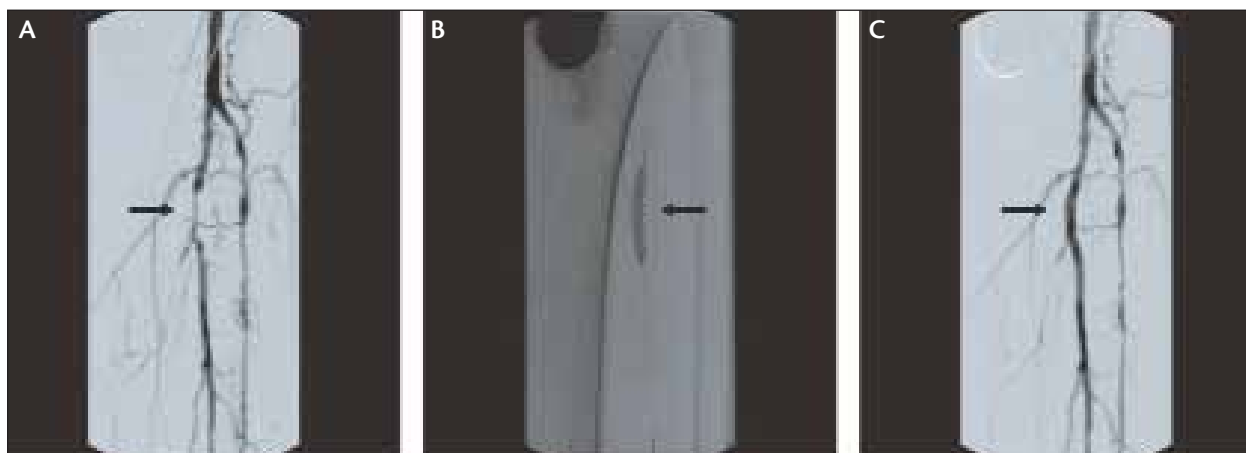


Figure 3. Severe tibioperoneal disease treated with the AngioSculpt. Pre-AngioSculpt (A), AngioSculpt deployment (B), and post-AngioSculpt (C).

the coronary arteries by Dr. Peter Barath and was initially called the Barath Balloon.<sup>6</sup> The device is composed of a conventional balloon catheter with 3 to 4 atherotomes (razor blades) that are attached to the balloon surface (Figure 1). It was hoped that this device would lead to an improved restenosis rate compared to conventional balloons. The pivotal coronary Global Randomized Trial study failed to demonstrate a significant reduction in restenosis, and the device was associated with serious complications including vascular perforations that resulted in delayed FDA approval and limited indications.<sup>7</sup> More recently, larger-diameter balloons have been developed for PAD; however, they are only available in relatively short lengths (10–20 mm) due to the stiffness of the device. The Cutting Balloon has been used most often in focal fibrocalcific or “nondilatable” lesions (although it has a relatively low rated burst pressure of approximately 10 atm) and in-stent restenosis (ISR). A recent study demonstrated a significantly better primary patency rate in patients with focal femoropopliteal disease treated with the Cutting Balloon as compared to standard balloons.<sup>8</sup>

#### ANGIOSCULPT

The AngioSculpt Scoring Balloon Catheter (AngioScore, Inc., Fremont, CA) was first developed in 2003 for the treatment of complex coronary artery disease.<sup>9</sup> It has subsequently been evaluated for the treat-

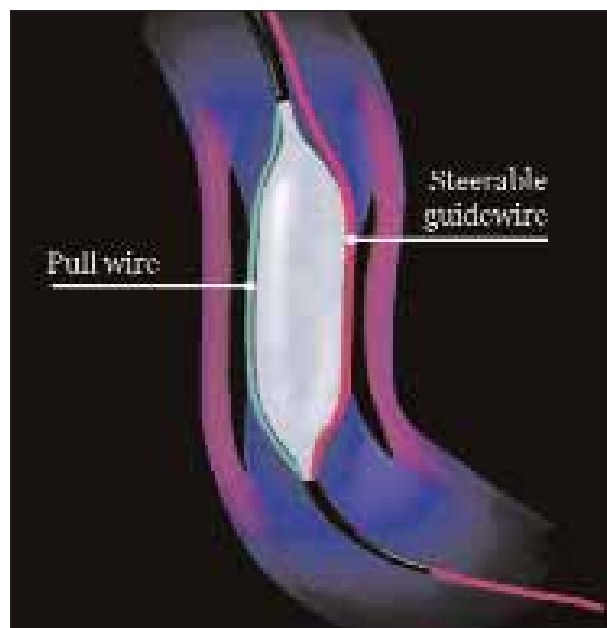


Figure 4. FX miniRAIL.

ment of infrapopliteal disease and CLI and more recently, with the development of longer and larger devices, for SFA disease and stenoses involving hemodialysis fistulae.

The AngioSculpt device incorporates a semicompliant balloon (with rated burst pressures of up to 20 atm)

and a laser cut nitinol scoring element (Figure 2). The scoring element is composed of three to four rectangular-shaped struts that encircle the balloon in a helical pattern. This design results in a very flexible and conforming device that can also be scaled to longer and larger dimensions that are more suitable for the complex and diffuse disease often affecting the SFA. Current devices are available in 2- to 6-mm diameter and 10- to 40-mm lengths. Larger and longer devices are in development to help better address the extensive disease commonly found in the SFA.

The AngioSculpt has received CE Mark approval in Europe for all peripheral indications and has obtained 510(k) clearance in the US for dilatation of lesions in the iliac, femoral, iliofemoral, popliteal, and infrapopliteal arteries and for the treatment of obstructive lesions of native or synthetic arteriovenous dialysis fistulae. Several recent studies have documented the acute safety and efficacy of treating infrapopliteal disease and CLI with the AngioSculpt and sustained benefit in achieving limb salvage in patients with CLI up to 1 year after treatment.<sup>10,11</sup> In the international registry, 93 patients (80% with CLI) and 131 infrapopliteal lesions were treated with the AngioSculpt. The AngioSculpt was successfully deployed in 99.2% (130/131) of lesions attempted and was used without adjunctive stenting in 88.6% of lesions (Figure 3). Dissections were uncommon, occurring in only 9.9% of lesions treated. There were no perforations, and no significant device slippage occurred. In another small two-center study, patients with CLI were treated with the AngioSculpt and followed for up to 1 year after treatment. This study demonstrated a procedural success rate of 100%, a low dissection rate of 9.7% (most minor), and an 86.3% limb salvage rate at 1-year follow-up.

An ongoing European multicenter study is currently evaluating the AngioSculpt in the treatment of patients with SFA disease (MASCOT trial, clinicaltrials.gov identifier NCT00619788). This study will follow patients for up to 1 year and will include serial duplex ultrasound to evaluate vessel patency.

## OTHER SCORING BALLOONS

There have been other scoring balloon designs that have been evaluated clinically. The FX miniRAIL (Abbott Vascular, Santa Clara, CA) was developed primarily for the coronary arteries and utilizes the procedural coronary guidewire and an additional attached short wire ("pull wire") that is external to the balloon in order to score the plaque (Figure 4). This device also incorporates a modified monorail design in which the wire engagement length is very short and only includes the

distal tip of the catheter beyond the balloon segment. The end result is very similar to the "buddy wire" technique that has been used for a number of years.<sup>12</sup> The main limitations of the device are its relatively poor scoring capability and concerns over deliverability due to the very short monorail segment. The FX miniRAIL is currently unavailable in the US due to the manufacturer no longer marketing the device.

"Scoring and cutting balloons have been developed to help address some of the inadequacies associated with conventional balloon angioplasty."

A very similar scoring balloon, VascaTraK2 (YMed, Inc., San Diego, CA, distributed by IDev Technologies, Inc., Houston, TX), has been developed to treat PAD and includes longer length balloons. No clinical studies have been published demonstrating any advantages with this device as compared to conventional balloons.

## DISCUSSION

Despite the recent availability of multiple new technologies for the treatment of SFA disease, angioplasty balloons have remained the most frequently used device. This is due to their simplicity of use, safety, relatively low cost and the paucity of data in most lesion subsets demonstrating any significant advantages with other devices except for nitinol stents.<sup>13</sup> However, conventional balloons have certain limitations in the treatment of complex PAD affecting the SFA. These include a high rate of uncontrolled dissections that may require bailout stenting, inadequate luminal expansion particularly in fibrocalcific lesions, and a low primary patency rate requiring repeat revascularization. Scoring and cutting balloons have been developed to help address some of the inadequacies associated with conventional balloon angioplasty. Additionally, with the increasing use of stents to treat longer lesions in the SFA, ISR is becoming a more frequent and challenging clinical problem. Scoring and cutting balloons may offer advantages over conventional balloons in the treatment of ISR by avoiding slippage or "geographic miss" and achieving superior luminal expansion by more effective mechanical dilatation of the obstructing neointimal tissue and re-expansion of the original stent.<sup>14</sup>

Ongoing and future clinical studies comparing the outcomes of these specialized balloons with conventional balloons are necessary to confirm their clinical

benefits and determine in which lesion subsets they will be most useful. ■

*Marc Bosiers, MD, is with the Department of Vascular Surgery, AZ St-Blasius, Dendermonde, Belgium. He has disclosed that he holds no financial interest in any product or manufacturer mentioned herein. Dr. Bosiers may be reached at +32 5225 28 22; marc.bosiers@telenet.be.*

*Koen Deloose, MD, is with the Department of Vascular Surgery, AZ St-Blasius, Dendermonde, Belgium. He has disclosed that he holds no financial interest in any product or manufacturer mentioned herein. Dr. Deloose may be reached at +32 5225 28 22; koen.deloose@telenet.be.*

*Jurgen Verbist, MD, is with the Department of Cardiovascular & Thoracic Surgery, Imelda Hospital, Bonheiden, Belgium. He has disclosed that he holds no financial interest in any product or manufacturer mentioned herein. Dr. Verbist may be reached at +32 1550 61 97; jurgen.verbist@imelda.be.*

*Patrick Peeters, MD, is with the Department of Cardiovascular & Thoracic Surgery, Imelda Hospital, Bonheiden, Belgium. He has disclosed that he holds no financial interest in any product or manufacturer mentioned herein. Dr. Peeters may be reached at +32 1550 61 97; patrick.peeters@imelda.be.*

1. Dormandy J, Mahir M, Ascady G, et al. Fate of the patient with chronic leg ischemia. A review article. *J Cardiovasc Surg.* 1989;30:50-57.
2. Pentecost MJ, Criqui MH, Dorros G, et al. Guidelines for peripheral percutaneous transluminal angioplasty of the abdominal aorta and lower extremity vessels. *Circulation.* 1994;89:511-531.
3. Norgren L, Hiatt WR, Dormandy JA, et al. Inter-Society Consensus for the Management of Peripheral Arterial Disease (TASC II). *Eur J Vasc Endovasc Surg.* 2007;33(suppl 1):S58-59.
4. Grüntzig A. Transluminal dilatation of coronary-artery stenosis. *Lancet.* 1978;1:263.
5. Holm J, Arvidsson B, Jivegard L, et al. Chronic lower extremity limb ischemia ; a prospective randomized controlled study comparing the 1-year results of vascular surgery and percutaneous transluminal angioplasty (PTA). *Eur J Vasc Surg.* 1991;5:517-522.
6. Barath P, Fishbein MC, Vari S, et al. Cutting balloon: a novel approach to percutaneous angioplasty. *Am J Cardiol.* 1991;68:1249-1252.
7. Mauri L, Bonan R, Weiner BH, et al. Cutting balloon angioplasty for the prevention of restenosis: results of the Cutting Balloon Global Randomized Trial. *Am J Cardiol.* 2002;90:1079-1083.
8. Cotroneo AR, Pascali D, Iezzi R. Cutting balloon versus conventional balloon angioplasty in short femoropopliteal arterial stenoses. *J Endovasc Ther.* 2008;15:283-291.
9. Gershony G, Virmani R, Lotan C, et al. A novel angioplasty catheter for the treatment of complex CAD: AngioSculpt. *Am J Cardiol.* 2003;92(suppl 1):166L.
10. Scheinert D, Graziani L, Peeters P, et al. Results of the multi-center first-in-man study of a novel scoring balloon catheter for the treatment of infra-popliteal peripheral arterial disease. *Cathet Cardiovasc Interv.* 2007;70:1034-1039.
11. Peeters P, Verbist J, Deloose K, et al. PTA advancements: use of AngioSculpt Scoring Balloon for infra-popliteal lesions in patients with critical limb ischemia—12 month results. *In Press, Vascular.*
12. Selig MB. Lesion protection during fixed-wire balloon angioplasty: use of the "buddy wire" technique and access catheters. *Cathet Cardiovasc Diagn.* 1992;25:331-335.
13. Zeller T. Current state of endovascular treatment of femoro-popliteal artery disease. *Vasc Med.* 2007;12:223-234.
14. Fonseca A, Costa JR, Abizaid A, et al. Intravascular ultrasound assessment of the novel AngioSculpt Scoring Balloon Catheter for the treatment of complex coronary lesions. *J Invasive Cardiol.* 2008;20:21-27.