

Remote Endarterectomy

This minimally invasive procedure is a viable treatment option for many patients with peripheral vascular disease.

BY DAVID ROSENTHAL, MD; ERIC D. WELLONS, MD; ALLISON B. BURKETT, MD;
AND PAUL V. KOCHUPURA, MD

Remote endarterectomy (RE), a procedure introduced by Ho and Moll in 1995,¹ is a minimally invasive procedure that is performed through a small inguinal incision, which allows complete debulking of the arterial plaque and placement of a distal stent, as indicated.

RE was initially performed for the treatment of long-segment superficial femoral artery (SFA) occlusive disease (ie, >15 cm, TASC D lesions), because other minimally invasive procedure results with percutaneous transluminal angioplasty (PTA), stent angioplasty, and atherectomy have proved disappointing.²⁻⁶ Since its introduction, RE has continued to evolve to where today it may be used to treat not only long-segment SFA occlusive disease but also iliac artery occlusive disease, and it may be used as an adjunctive procedure for limb salvage when adequate length of the saphenous vein (SV) is not available for a bypass.

REMOTE SFA ENDARTERECTOMY

The technique of remote SFA endarterectomy (RSFAE) using the MollRing Cutter (LeMaitre Vascular, Burlington, MA) has been described previously.⁷ In summary, the SFA is

exposed through a small groin incision. After systemic heparinization, an arteriotomy is made from the origin of the SFA distally, and an endarterectomy is commenced in the standard subadventitial cleavage plane. The atheromatous core is transversely cut at the SFA origin and threaded into the loop of a ring stripper (Vollmar Dissector; Aesculap, San Jose, CA) or a Martin Dissector (LeMaitre Vascular), which is used to create the SFA endarterectomy channel. Under fluoroscopic surveillance, the ring stripper or Martin Dissector is advanced distally down the SFA to the point of SFA reconstitution, the location of which has been determined by intraoperative arteriography. The ring stripper is exchanged for the MollRing Cutter device, which transects the distal atheromatous core under fluoroscopic surveillance. The entire column of plaque is removed, and arteriography is performed to confirm a patent femoral popliteal segment (Figure 1A).

Under fluoroscopic guidance, a guidewire is passed across the distal SFA endarterectomy endpoint, and balloon stent angioplasty is performed, "tacking up" the distal plaque to prevent further dissection (Figure 1B). Completion arteriography verifies RSFAE patency, geniculate arterial collateral

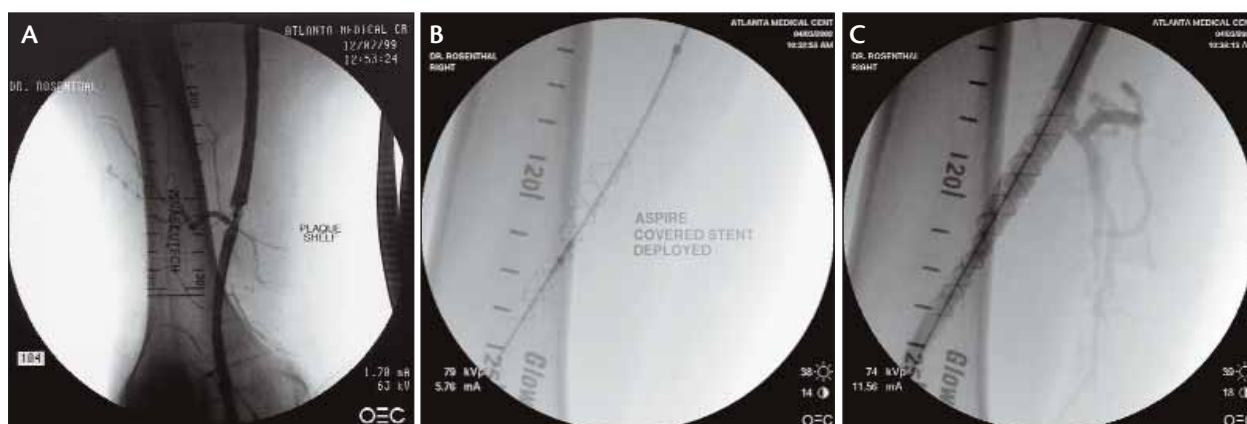


Figure 1. Arteriogram after RSFAE. Note the distal shelf at endarterectomy endpoint (A). Balloon/stent angioplasty (B). Completion arteriogram with collateral preserved (C).

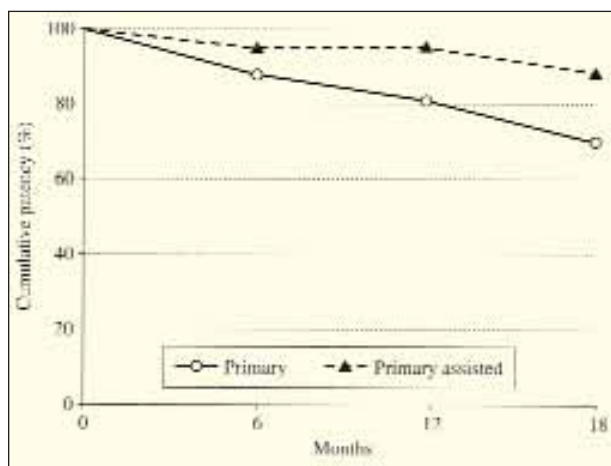


Figure 2. Cumulative primary and primary-assisted patency after RSFAE and distal aSpire stenting.

preservation, and any outflow tract obstruction (Figure 1C). Any loose debris may be removed with a Fogarty Embolectomy or Graft Thrombectomy Catheter (Edwards Lifesciences, Irvine, CA). The arteriotomy may be extended proximally to perform an open endarterectomy of the common femoral artery or profunda femoris ostia, as indicated.

In a recent study, 51 patients underwent RSFAE and distal aSpire stenting.⁷ The aSpire stent (LeMaitre Vascular) is an expanded polytetrafluoroethylene-covered nitinol stent that is flexible yet has high radial strength to withstand torsional stresses at the knee joint. After the stent is across the endarterectomy endpoint, it can be adjusted for diameter and length; if the stent is not in satisfactory position (ie, covering a collateral), it can be repositioned by “wrapping” it back down to a low profile and re-expanded, thereby preserving major geniculate collaterals at the distal endpoint (Figure 1C). The indications for operation

(Society for Vascular Surgery and the International Society for Cardiovascular Surgery, North American Chapter criteria) in this study were chronic lower extremity ischemia category 1 through 3 in 41 patients and category 4 or 5 in seven patients.⁸ The mean length of endarterectomized SFAs was 27.4 cm (range, 13–41 cm). The primary

cumulative patency rate by means of life-table analysis was $69.4\% \pm 13.5\%$ standard error (SE) at 18 months (mean, 13.2 months; range, 1–31 months) (Figure 2). Repeat radiologic intervention was necessary in seven patients (four PTA, three stent angioplasty) for a primary-assisted patency rate of $87.6\% \pm 8.5\%$ at 18 months (Figure 2). Four of the patients whose RSFAE failed underwent above-knee femoropopliteal bypass. One above-knee amputation was performed during follow-up in an elderly diabetic patient who had gangrene of the foot. There were no deaths, and one wound complication occurred (skin edge slough); the mean hospital length of stay was 1.8 ± 0.4 days. The incidence of restenosis after RSFAE remains significant in that 14% (7/51) of patients required an adjunctive procedure (four PTA, three stent angioplasty) to maintain SFA patency. Hopefully, in the near future, the use of improved antiplatelet medications and/or drug therapy will help solve the problem of restenosis, thereby offering patients a minimally invasive, durable procedure with patency rates similar to those of an above-knee femoropopliteal bypass.

REMOTE ILIAC ARTERY ENDARTERECTOMY

RE of external and common iliac artery occlusions continues to evolve. To perform a remote iliac artery endarterectomy (RIAE), the contralateral femoral artery is accessed percutaneously, and an intraoperative arteriography is performed to document the point of iliac artery reconstitution (Figure 3); the guidewire is left in place. A standard common femoral artery exposure is performed on the symptomatic limb, and after systemic heparinization, an endarterectomy is commenced (similar to RSFAE), but proximally, and the distal common femoral endarterectomized core is transected. A Vollmar Dissector that is similar in diameter to the external iliac artery diameter is select-

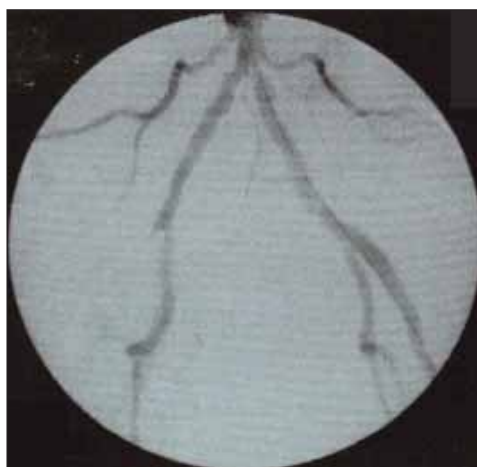


Figure 3. Arteriogram shows right external iliac artery occlusion.

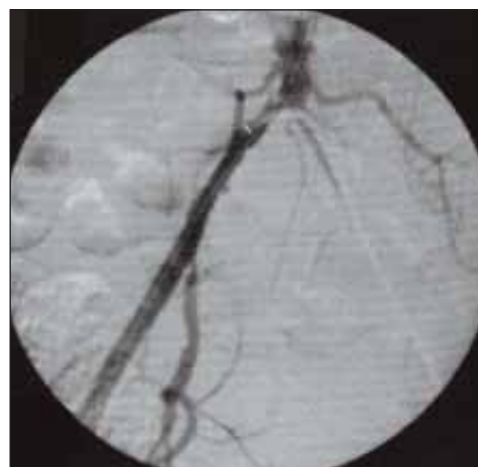

Figure 4. Arteriogram shows successful remote endarterectomy of the common and external iliac artery with preservation of internal iliac artery.

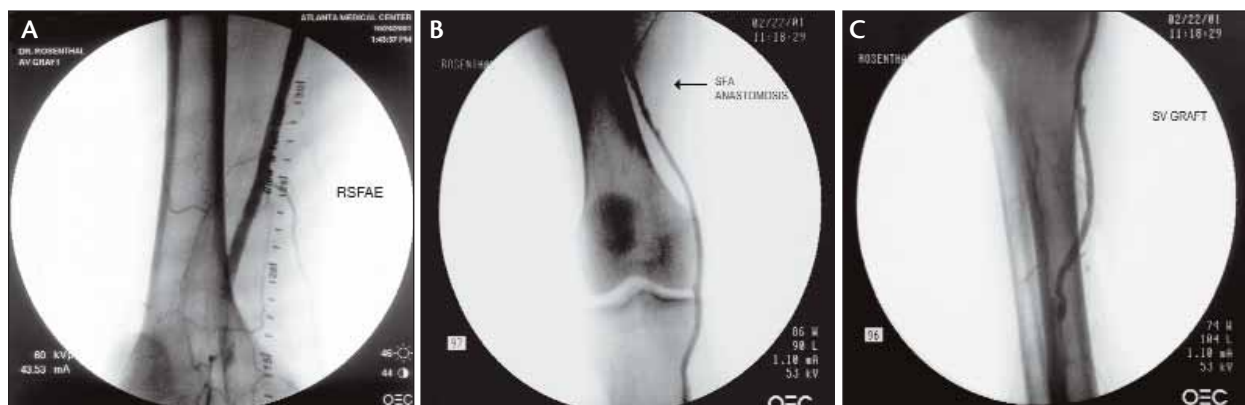

Figure 5. Completion arteriogram of endarterectomized SFA (A). SFA-saphenous vein anastomosis (B). Distal peroneal anastomosis (C).

ed and advanced proximally under fluoroscopic guidance to the patent portion of the iliac artery. The ring stripper is then exchanged for a similar-sized MollRing Cutter, and under fluoroscopic control, the proximal plaque is transected. The entire plaque and MollRing Cutter are removed together by applying slight traction distally. Brisk arterial inflow indicates a satisfactory revascularization, which is verified by a completion arteriogram (Figure 4). If an irregularity is noted at the transection point, a stent may be placed via the ipsilateral side or in an “over-the-top” fashion via the previously accessed contralateral femoral artery. The distal common femoral artery plaque is anchored by “tackling” sutures to ensure a smooth transition zone. If indicated, the arteriotomy can be extended to incorporate the distal common femoral and/or profunda femoris for endarterectomy. The arteriotomy is closed by patch angioplasty. In a study by Smeets et al, 49 RIAEs were performed in 48 patients.⁹ The indications for operation were claudication in 28 patients (57%), rest pain in 13 patients (27%), and gangrene in eight patients (16%). Operative technical success was achieved in 43 (88%) procedures, and the 3-year cumulative primary patency rate was $60.2\% \pm 12\%$ (SE), while the 3-year primary-assisted patency rate was $85.7\% \pm 9.56\%$, and the secondary patency rate was $94.2\% \pm 5.5\%$. When compared to semiclosed endarterectomy or bypass procedures, RIAE offers the advantage of a single, small incision, no risk of postoperative abdominal hernia, and no prosthetic grafts, which may be associated with late anastomotic pseudoaneurysm formation and/or anastomotic stenoses. The procedure is possible under local anesthesia, and the primary (60.2%) and primary-assisted (85.7%) patency rates are comparable to other published operative results for TASC D lesions.¹⁰⁻¹¹ The investigators concluded that RIAE is an appropriate, minimally invasive procedure for the treatment of long-segment iliac occlusive disease.

THE ROLE OF RE IN LIMB SALVAGE

An adjunctive role for RE is in the limb salvage patient when adequate SV for a bypass is not present. SV is the conduit of choice for infrapopliteal limb salvage bypass operations, especially in the presence of a foot infection. Unfortunately, the ipsilateral SV has been reported to be of poor quality, previously stripped, or harvested for coronary bypass in up to 40% of patients who require a distal bypass operation.^{12,13} RSFAE creates the opportunity to use the proximal popliteal artery as the inflow site so that residual SV may be used for a distal vein bypass.

In a study by Rosenthal et al, 21 limb salvage patients underwent RSFAE and distal SV bypass.¹⁴ SV for a femorodistal bypass was unavailable in 14 patients because of previous coronary bypass, had “unusable” segments determined at operation (<2.5-mm diameter, sclerotic, phlebotic) in five patients, and was previously stripped in two patients. After successful RSFAE (Figure 5A), the popliteal artery to SV anastomosis was performed in a standard “end-to-side” fashion in all cases (Figure 5B) and to the target vessel (Figure 5C). Seven SV grafts were performed in situ, eight SV segments were harvested for transposition, and six were reversed by surgeon’s preference. The primary cumulative patency rate by life-table analysis was $62.5\% \pm 15\%$ (SE), (average, 12.4 months; range, 1–18 months). Repeat radiologic intervention was necessary in six patients (four PTA, two stent angioplasty), for a primary-assisted patency rate of $76.4\% \pm 8\%$. Two above-knee amputations were performed during follow-up in patients who were diabetic and dialysis-dependent with gangrene of the forefoot, and the mean hospital length of stay was 3.1 ± 0.6 days. When a femorodistal popliteal tibial bypass is necessary, and adequate SV is not available, RSFAE and distal bypass with residual SV bypass is a safe and moderately durable procedure, which may prove to be a useful adjunct for limb

salvage, especially in the presence of foot infection when an autogenous tissue bypass is preferred.

CONCLUSION

RE combines the advantages of minimally invasive surgery with endovascular techniques. Operative trauma is minimal, allowing for a short hospital length of stay, shorter recuperation, and therefore, healthcare savings. Another advantage of RE is the avoidance of a prosthetic graft with the associated risks of graft infection, false aneurysm, and acute thrombosis, while maintaining similar primary patency rates (69.4% for RSFAE and 60.2% for RIAE) to bypass operations.

It is of interest to note that when an RE fails, the symptoms are generally mild. This may be due to an adjunctive profunda femoris endarterectomy or the gradual loss of the endarterectomized artery as collateral vessels were opened by RE. Conversely, when a bypass graft fails, it usually causes significant symptoms, and a more distal anastomosis is frequently required.

Restenosis after RE remains a concern and remains the Achilles' heel of this and all endovascular procedures. Additional procedures to maintain patency include PTA/stent procedures, but hopefully the use of newly developed statins, angiotensin-converting enzyme inhibitors, antiplatelet agents, and possibly drug-eluting stents will reduce the incidence of restenosis.

RE is a minimally invasive procedure that offers superior patency rates to other endovascular procedures for the treatment of long-segment (TASC C and D lesions) SFA and iliac occlusive disease. Long-term patency rates are similar to prosthetic bypass grafting, but reinterventions are sometimes necessary. RE appears to be a durable adjunct for the treatment of peripheral vascular disease. ■

David Rosenthal, MD, is Chief of Vascular Surgery, Department of Vascular Surgery, Atlanta Medical Center in Atlanta, Georgia. He has disclosed that he holds no financial interest in any product or manufacturer mentioned herein. Dr. Rosenthal may be reached at (404) 524-0095; docro@mind-spring.com.

Eric D. Wellons, MD, is from the Department of Vascular Surgery, Atlanta Medical Center in Atlanta, Georgia. He has disclosed that he holds no financial interest in any product or manufacturer mentioned herein. Dr. Wellons may be reached at (404) 524-0095; ewellons@gmail.com.

Allison B. Burkett, MD, is from the Department of Vascular Surgery, Atlanta Medical Center in Atlanta, Georgia. She has disclosed that she holds no financial interest in any product or manufacturer mentioned herein. Dr. Burkett may be reached at (404) 524-0095; abburkett2000@gmail.com.

Paul V. Kochupura, MD, is a Vascular Fellow, Department of Vascular Surgery, Atlanta Medical Center in Atlanta, Georgia.

He has disclosed that he holds no financial interest in any product or manufacturer mentioned herein. Dr. Kochupura may be reached at (404) 524-0095; pkochupura@yahoo.com.

1. Ho GH, Moll FL, Hedeman Joosten PPhA, et al. The Molling Cutter remote endarterectomy: preliminary experience with a new endovascular technique for treatment of occlusive superficial femoral arterial disease. *J Endovasc Surg.* 1995;2:278-287.
2. Matsi PJ, Manninen HI, Vanninen RL, et al. Femoropopliteal angioplasty in patients with claudication: primary and secondary patency in 140 limbs with 1-3-year follow-up. *Radiology.* 1994;191:727-333.
3. Johnston KW, Rai M, Hogg-Johnston SA, et al. 5-year results of a prospective study of percutaneous transluminal angioplasty. *Ann Surg.* 1987;206:403-413.
4. Diethrich EB. Laser angioplasty: a critical review based on 1894 clinical procedures. *Angiology.* 1990;41:747-767.
5. The Collaborative Rotablator Atherectomy Group (CRAG). Peripheral atherectomy with the rotablator: a multicenter report. *J Vasc Surg.* 1994;19:509-515.
6. Bergeron P, Pinot JJ, Poyen V, et al. Long-term results with the Palmaz stent in the superficial femoral artery. *J Endovasc Surg.* 1995;2:161-167.
7. Rosenthal D, Martin JD, Smeets L, et al. Remote superficial femoral artery endarterectomy and distal aSpire stenting: results of a multinational study at three-year follow-up. *J Cardiovasc Surg.* 47;4:2006:385-391.
8. Rutherford RB, Flanagan DP, Gupta SK, et al. Suggested standards for reports dealing with lower extremity ischemia. *J Vasc Surg.* 1986;4:80-94.
9. Smeets L, Borst GJ, deVries JP, et al. Remote iliac artery endarterectomy: seven-year results of a less invasive technique for iliac artery occlusive disease. *J Vasc Surg.* 2003;38:1297-1304.
10. van den Dungen JJAM, Boonje AH, Kropveld A. Unilateral iliofemoral occlusive disease: long-term results of the semiclosed endarterectomy with the ringstripper. *J Vasc Surg.* 1991;14:673-677.
11. Bell DD, Gaspar MR, Movius HJ, et al. Retroperitoneal exposure of the terminal aorta and iliac arteries. *Am J Surg.* 1979;128:254-256.
12. Taylor LM, Edwards JM, Porter JM. Present status of reversed vein bypass: five-year results of a modern series. *J Vasc Surg.* 1990;11:193-205.
13. Poletti LF, Matsuura JH, Dattilo JB. Should vein be saved by future operations? A 15-year review of infrainguinal bypasses and the subsequent need for autogenous vein. *Ann Vasc Surg.* 1998;12:143-147.
14. Rosenthal D, Wellons ED, Matsuura JM, et al. Remote superficial femoral artery endarterectomy and distal vein bypass for limb salvage: initial experience. *J Endovasc Therapy.* 2003;10:1:121-25.