

# Postthrombotic Syndrome

The most prevalent and least understood complication of deep vein thrombosis.

BY PATRICIA E. THORPE, MD, FSIR

**T**he vast majority of patients diagnosed with acute deep vein thrombosis (DVT) are simply treated with low-molecular-weight heparin (LMWH) and a course of warfarin. The patients I treat are those in whom the alleged “clinical improvement over time” does not occur. These patients have postthrombotic syndrome (PTS) (Table 1). They have chronic venous obstruction. I specialize in treating symptomatic PTS with endovenous therapy. Over and over, I hear a similar story of frustration from patients whose physicians say that “there is not much to offer,” or “you just have to learn to live with this,” or “there is nothing anyone can do, because the clot is so old.” Most of the patients are young (average age, 43 years) and motivated to keep their jobs and care for their families. The clinical sequelae of chronic venous obstruction can take a stiff toll on a patient’s ability to perform and quality of life (QOL). Some patients reach a point of despair as they exhaust sick leave, lose employment, and face the loss of insurance coverage. Frequently, they are exasperated that their doctor did not initially offer the therapy to dissolve the thrombus. Each year, more than 1 million individuals are diagnosed with acute DVT, and a significant number of patients will end up in this PTS group. Some will have mild edema and no pain, and others will have more pain and edema by evening. The progression of the disability varies. Stasis ulcers can form within several years of an acute DVT episode in patients with occult iliac or ilio caval obstruction. The spectrum of signs and symptoms is broad, but the common denominator is venous hypertension (see sidebar Figure 1).

PTS is a chronic, debilitating condition with significant socioeconomic consequences in Europe and the Western Hemisphere.<sup>1</sup> It is the most common complication of DVT and is perhaps the least studied and least understood.<sup>2</sup> Before the introduction of heparin, Bauer reported nearly 80% of patients with DVT progressed to a severe form of post-thrombotic disease, which included stasis ulceration.<sup>3</sup>

Now, with heparin and warfarin therapy, between 20% and 50% will develop PTS within 1 to 2 years of a symptomatic episode of DVT.<sup>4</sup> Moreover, we now recognize the QOL issues associated with PTS. In a patient-reported QOL questionnaire administered to nearly 6,000 patients with chronic venous disease, Kahn et al found a correlation between physician-assessed clinical, etiologic, anatomic, pathophysiologic (CEAP) classification and QOL.<sup>5</sup>

## PATHOPHYSIOLOGY

Venous hypertension, whether due to obstruction, valve incompetence, or both, is the pathology that underlies the development of the signs and symptoms recognized as PTS. The valvular damage may be obscured by the presence of chronic organized thrombus. Valvular incompetence can also occur below the proximal obstructing thrombus. The combination of reflux and obstruction causes the worst manifestations of venous hypertension, as evidenced by edema, dermatitis, hyperpigmentation, skin deterioration, and varicosities. Unrelieved venous hypertension results in a series of soft tissue abnormalities, including disruption of the usual permeability to erythrocytes and fibrin, resulting in breakdown of cells and deposition of hemosiderin under the skin. Fluid shifts in the soft tissue are affected by change in hydrostatic and osmotic forces, as well as factors released by static leukocytes. The chronic tissue pressure leads to hypoxic conditions that cause dermal necrosis. The open sores can become infected, and the inflammation may become painful if nerves are involved. Limb elevation serves to relieve pressure. External compression counteracts the deep venous pressure that perpetuates the cascade of events.<sup>6,7</sup>

## CLINICAL PRESENTATION OF PTS

We have recognized several different clinical patterns of PTS. In the first group, called *heparin failure* (HF), patients present with unremitting pain and edema after the initial

episode of DVT (see sidebar Figure 2). Invariably, these patients have sought and received timely diagnosis and anticoagulation but fail to respond to traditional heparin and warfarin regimens. These patients have significant venous hypertension related to the extent of their thrombosis. They lack sufficient recanalization to prevent edema. They are frequently very disabled, cannot work, drive, or perform normal daily activities. Patients with nonhealing ulcers may be in the heparin failure or recurrent DVT groups. They commonly have chronic compression or occlusion of the left common iliac vein (see sidebar Figure 3). This can cause an ache in the inguinal region and venous claudication with activity. Occasionally, lymphedema is associated with venous obstruction. Individuals in the second group, called *acute-on-chronic* (AC), present with an acute episode of thrombosis, without any documented and/or suspected history of DVT. However, phlebography reveals anatomical changes consistent with previous thrombosis of indeterminate age. Patients in a third group, called *recurrent* (R) DVT, have a common history of one or more episodes of thromboembolism. Many have been hospitalized more than once for pulmonary embolus and/or DVT. They are routinely readmitted for intravenous heparin therapy and further anticoagulation. Recurrent DVT frequently occurs shortly (1 to 3 months) after discontinuing oral anticoagulation. A relatively high number of these patients have a family history of thrombosis, suggesting an inherited hypercoagulability disorder. Ulceration is more common in this group.

## RISK FACTORS

Currently, the ability to predict which patient will develop PTS after acute DVT is limited. Residual thrombus, especially popliteal obstruction, valvular incompetence, and recurrent DVT, are known risk factors for the development of PTS. Acquired risk factors for VTE include malignancy, hospitalization, surgery, trauma immobilization, hormone therapy, pregnancy, and antiphospholipid antibodies. Although these disorders or conditions increase the risk of DVT, none is associated with any known risk of PTS after the initial episode of VTE. What is the role of additional issues associated with the treatment of DVT in the development of PTS? Body mass index has been significantly correlated with the appearance of PTS.<sup>8</sup> Male gender and high D-dimers have been independently associated with PTS after the first episode of DVT.<sup>9</sup>

## Duration of Anticoagulation

The best longitudinal study addressing this issue was conducted in Sweden by Schulman et al.<sup>10</sup> The duration of anticoagulation did not have a statistically significant effect on any of the long-term outcomes. Approximately 900

patients were randomized to one of two regimens: 6 weeks or 6 months of oral anticoagulation; 545 were available for follow-up at 10 years. The duration of warfarin therapy did not affect the incidence of recurrent VTE or PTS. Overall, PTS was identified in 56.3%, and severe PTS was identified in 6% of patients. Recurrent VTE occurred in 29%, and death occurred in 28.5%; the investigators felt this reflected cancer and cardiovascular events in older patients.<sup>10</sup>

## Intensity of Anticoagulation

Kahn and colleagues reported on a Canadian study comparing two levels of target international normalized ratio (INR).<sup>11</sup> They observed 145 patients for an average of 2.2 years after their first episode of DVT. Initially, all patients were treated with conventional therapy (target INR of 2.5) for 3 months. Patients were then divided into two groups: maintenance INR 1.7 versus INR 2.5. This difference did not influence the incidence of PTS. Overall, at 2 years, the prevalence of PTS was 37%, with 4% having severe chronic venous insufficiency. Poorly regulated anticoagulation is, however, thought to contribute to the risk of PTS. Subtherapeutic oral anticoagulation after DVT is common. A study by van Dongen et al suggests that this is related to the development of PTS.<sup>12</sup> In the study, they showed that patients with an INR <2 more than 50% of the time have a higher risk of PTS. This figure would be consistent with recurrent ipsilateral thrombosis on a substrate of residual mural thrombus.

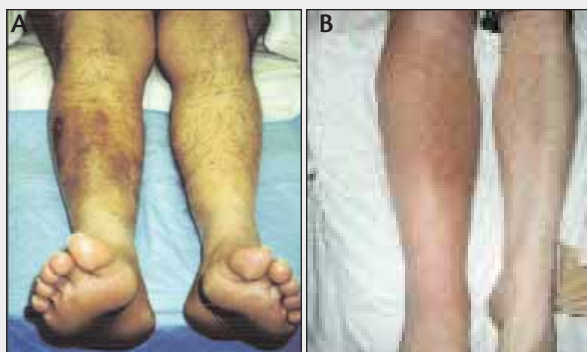## Ipsilateral Recurrence

Prandoni et al studied 528 consecutive DVT patients. He followed their progress over an 8-year period and reported the cumulative incidence of PTS at 2, 5, and 8 years to be 17.2%, 24.3%, and 29.7% respectively.<sup>13</sup> Prandoni noted that recurrent ipsilateral thrombosis was strongly linked to the risk of developing PTS. Residual thrombus has been shown to increase the risk of recurrence.<sup>14</sup> A longitudinal study by Ziegler et al revealed an 82% incidence of PTS among 161 DVT patients followed for 10 years. The more severe clinical symptoms were associated with ipsilateral recurrence.<sup>15</sup>

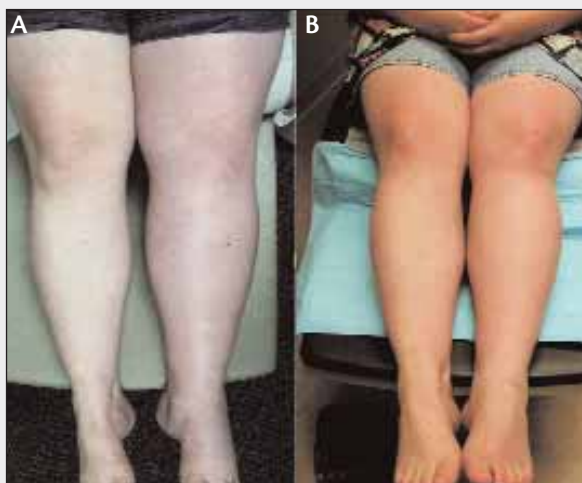
## Location of Thrombus

Overall, the presence of multisegmental thrombus is thought to increase the risk of developing PTS, but interventionists have argued that thrombus load and location do not determine the chance of PTS. An early longitudinal study by Lindner et al showed that 5 to 10 years after lower-extremity DVT was diagnosed and treated with anticoagulation, 80% of patients had both symptoms and abnormal venous hemodynamics independent of the initial site of the thrombosis.<sup>16</sup> A contrasting observation was reported by Janssen et al after following 81 DVT patients for 7 to 13 years (mean, 10 years).<sup>17</sup> Although 37% devel-

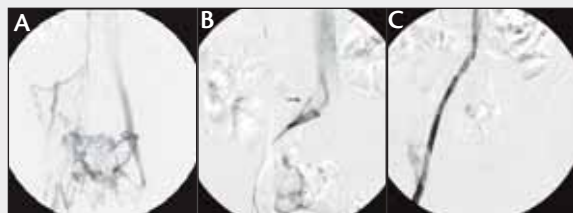## THE CLINICAL SPECTRUM OF PTS



**Figure 1.** Two images of the appearance of PTS. Patient A is 38-year-old man with a 4-year history of pain and swelling. He was previously treated with heparin and warfarin for two episodes of right-leg DVT. He had a small medial malleolar stasis ulcer. The patient has protein-S deficiency. Patient B is a 42-year-old man with right-leg edema and relatively little abnormality evident on the left side. However, this patient had inferior vena cava and bilateral iliac vein thrombosis. On the right side, there was femoral thrombosis, as well. The DVT occurred after surgery for seminoma, 2 years before he presented for evaluation of PTS. After endovascular reconstruction, he was able to return to his job as an emergency room nurse.



**Figure 2.** Before endovascular reconstruction of the left iliofemoral segments that were chronically occluded for 2 years (A). The postpartum left-leg DVT occurred after the birth of her second child. After treatment, the ankle is no longer swollen, and the knee is defined (B). There is still a small amount of asymmetry due to valve damage. The patient no longer has pain but continues to wear a knee-high compression stocking. The stents remain patent at 5 years.



The arrow points to the area of narrowing and chronic fibrosis of the left common iliac vein from the right iliac artery near the bifurcation (B). Completion venogram after placement of tandem Wallstents (Boston Scientific Corporation, Natick, MA) to reconstruct the deep veins in the left pelvis. Note the caval extension of the 12-mm self-expanding stent. It is important to fully stent across the area of compression. The small amount of contrast in the residual collateral is commonly seen directly after the stent system changes the flow pattern (C).

**Figure 3.** Pelvic venogram of a 35-year-old woman presenting with chronic left-leg edema. The before and after treatment images of her legs are shown in Figure 2. The venogram was obtained with the patient prone. Note the absence of the left femoral and iliac segments. Flow is shunted to the right via transpelvic collaterals. A prominent retroperitoneal collateral is seen (A). Classic venographic appearance of the May-Thurner compression.

oped signs and symptoms of PTS, calf-muscle pump abnormalities were noted in 57% of patients. These data led to the conclusion that both the severity of the clinical symptoms and the hemodynamic abnormalities were related to the location of the initial thrombus. Furthermore, the investigators pointed out that the risk of PTS after distal DVT is not negligible. Perhaps this is an area of underdiagnosis and treatment. Stain et al reported that proximal DVT was the strongest risk factor for PTS in their evaluation of 406 first-time DVT patients followed for a median of 5 years.<sup>9</sup>

#### What About Reflux?

Most patients with severe PTS have a combination of deep and superficial reflux, but it is thought that the proximal deep valvular incompetence contributes greatly to PTS.<sup>18</sup> The presence of both residual obstruction and reflux, rather than either one alone, significantly increases the chance of developing PTS.<sup>19</sup> Meissner et al reported that the important determinants of PTS included the rate of recanalization, degree of persistent thrombus, and the presence of popliteal reflux.<sup>20</sup>

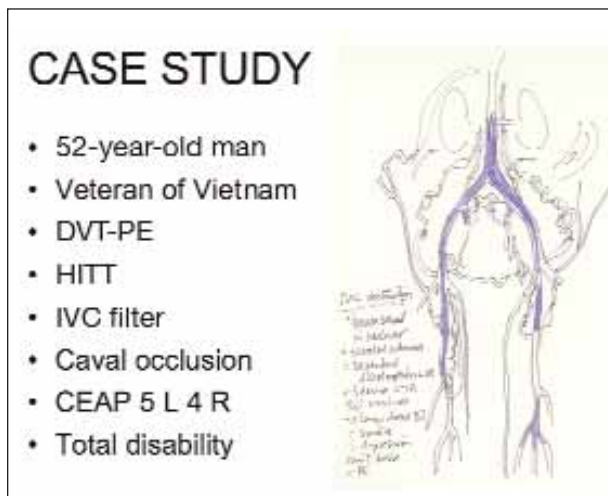


Figure 1. Case study clinical details and drawing of chronic IVC and iliofemoral thrombosis in a 52-year-old man. (Reprinted with permission from *The Vein Book*. Copyright 2007, Elsevier.)

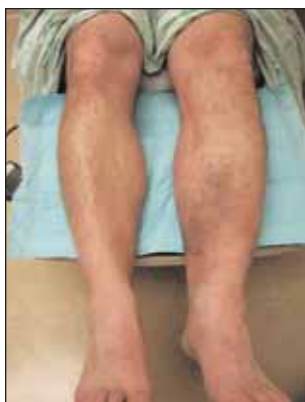

Figure 2. Signs of PTS. Bilateral tightness and painful edema with hyperpigmentation, dependent discoloration, and stasis dermatitis. The degree of edema and discomfort caused total disability.

## TREATMENT

The primary therapy for venous hypertension has remained compression therapy for more than 2,000 years since the time of Hippocrates. Compression, while the limb is dependent and elevated as much as possible, has been the principal means of controlling edema and associated discomfort. Patients with venostasis are traditionally treated with wound care and a combination compression dressing/immobilization apparatus, such as the Unna boot.

In the past decade, vascular interventionists have offered endovascular reconstruction of chronically occluded axial veins. The placement of self-expanding metallic stents in chronically thrombosed proximal venous segments has resulted in therapeutic relief of venous hypertension in upper and lower extremities (Figures 1 through 3). The therapy is effective, although the procedures are technically challenging and costly. Significant clinical improvement and decrease in disability are observed after correction of chronic venous obstruction.<sup>21</sup>

Regardless of the age of the thrombus or the number of times a patient has been hospitalized with DVT, in our

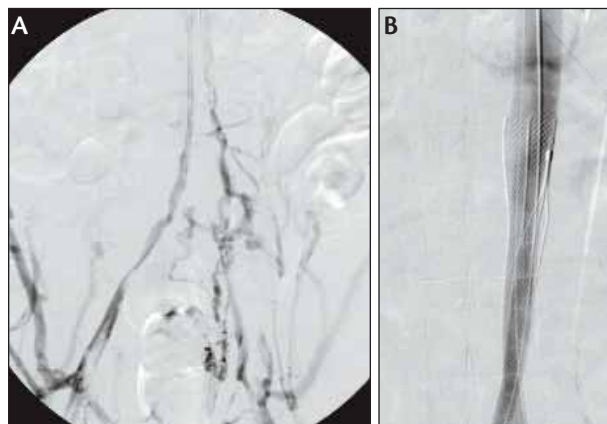


Figure 3. Venogram showing the minimal residual lumens of the iliac segments and the IVC during endovenous thrombolytic therapy with bilateral popliteal approach (A). Final endovascular reconstruction showing kissing stents extending to the IVC level above the occluded filter. Stents were extended into the upper thigh level to ensure good inflow into the reconstructed deep venous system composed of tandem Wallstents (Boston Scientific Corporation) (B). (Reprinted with permission from *The Vein Book*. Copyright 2007, Elsevier.)

experience, subjective and objective improvement can be achieved and sustained with endovascular therapy.<sup>22</sup> Selected patients, such as those with extensive residual thrombus or a known coagulopathy, may require long-term anticoagulation. However, we have treated patients with heterozygous factor V Leiden who do well clinically without warfarin. For patients considering extensive reconstruction with multiple stents, an important criterion for patient selection is the ability take long-term warfarin. As we gain more long-term data on patients with iliac stents, we may be able to identify a profile for patients who do not require lifetime anticoagulation. Our experience indicates this group includes patients with one to three stents in the iliac location, with excellent inflow from relatively normal distal veins.

## THE ROLE OF ENDOVASCULAR THERAPY

Can judicious use of early endovascular therapy minimize or prevent PTS? Although Kahn has stated that there is no clear evidence that thrombolysis of the initial DVT helps prevent PTS, several studies suggest that early thrombolysis does result in less pain and improved QOL.<sup>4,19,23</sup> We have treated patients with acute DVT who return to a totally normal limb condition after having multisegmental obstructing DVT that was unresponsive to anticoagulation alone. Unfortunately, for DVT patients, the universal treatment of acute DVT with thrombolytic therapy is not an option. Although the increased use of combination therapy, utilizing mechani-



cal thrombectomy with lytic agents, may extend the indication of endovascular therapy for acute obstructing iliofemoral DVT, there is still a reticence to refer acute DVT patients for intervention. With combination strategies, treatment times are shorter, and the intensive care unit stay is eliminated in some cases.<sup>24</sup> A lower lytic dose, or isolated lysis with a device such as Trellis-8 (Bacchus Vascular, Inc., Santa Clara, CA), AngioJet (Possis Medical, Minneapolis, MN), and Ekos (Ekos Corporation, Bothell, WA) can decrease the overall risk of bleeding complications related to longer infusions. In the end, a small number of patients will have contraindications to lysis and, in others, the suspected risk of bleeding will be a deterrent. In patients who develop symptomatic PTS, anticipated clinical improvement over time is not sufficient. However, right now, the perception of the risk-benefit ratio of early intervention continues to lean toward risk in the minds of many referring physicians. That is why clinical trials are still needed to guide decision making in treatment of acute DVT. The hope is that, in concert with adequate anticoagulation and compression, timely endovascular intervention in selected patients will help diminish the incidence of PTS.

## Restenosis

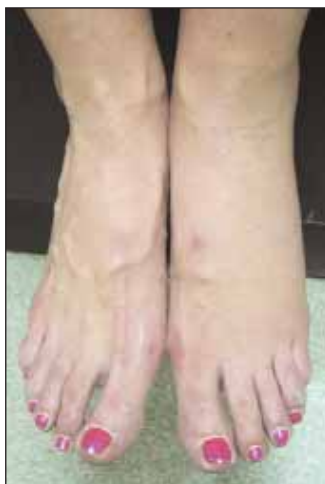The use of endovascular stents in the deep veins is indicated for flow-limiting lesions in the inferior vena cava, iliac, proximal femoral, superior vena cava, and the subclavian segments. We use self-expanding stents that are 12-mm to 16-mm in diameter. Smaller veins, such as the brachial and axillary, are usually stented only in combination with arteriovenous shunts in dialysis patients. Stents must be placed across the entire iliac compression to achieve good results and to avoid rethrombosis—this means extending the stent 1 to 2 cm into the inferior vena cava. The best way to achieve long-term patency is to ensure good inflow as well as outflow, selectively anticoagulate patients with malignancy, thrombophilia, and significant residual thrombus, and diligently monitor patients during follow-up. Assisted patency in the lower extremity is best when rethrombosis is prevented with proactive reintervention.

Intimal hyperplasia causes in-stent restenosis faster, and to a greater extent, in the subclavian segment. Intimal hyper-

plasia occurs in the lower extremity in 20% to 40% of patients.<sup>25</sup> Patients will report a recurrence of edema that resolves more slowly, with elevation, or the resumption of extremity discomfort that was gone after the initial intervention. Duplex ultrasound will not routinely reveal the degree of narrowing. In fact, the ultrasound study of stenotic iliac stents will indicate patency, but there may be a slight decrease in phasicity below the lesion. The best way to evaluate in-stent hyperplasia is with intravascular ultrasound.<sup>26</sup> When in-stent stenosis is clinically suspected, the stent should be redilated via a jugular or popliteal approach. We have successfully removed focal intimal hyperplasia causing 80% narrowing in an iliac stent at 10 years with the SilverHawk (FoxHollow Technologies, Redwood City, CA) atherectomy device. We have also seen effective results in iliac and subclavian stents, using the Flextome Cutting Balloon (Boston Scientific).

## PREVENTION

There are several pertinent clinical issues regarding prevention of PTS after an episode of DVT. First, compression with or without early ambulation, is reportedly associated with a decreased rate of development of PTS.<sup>27</sup> Compression helps prevent the evolution of skin changes that occur when there is unopposed edema from venous hypertension.<sup>28</sup> The use of elastic stockings was associated with a highly significant decrease in the incidence of PTS in DVT patients followed for 2 years. The data were derived from the randomized trials and registries included in the Cochrane analyses.<sup>29</sup> A recent review of published studies indicated that early ambulation was a factor in mitigating PTS in three of four randomized studies. Second, preventing ipsilateral DVT with adequate duration and levels of anticoagulation is thought to play a role in reducing the risk of PTS.<sup>14</sup> LMWH for high-risk patients in high-risk situations (eg, situational thromboprophylaxis) may reduce the incidence of recurrent DVT.<sup>3</sup> Third, early intervention to remove thrombus may prevent PTS. However, this last issue begs the questions that pertain to every patient diagnosed with acute DVT: Will he/she autolyse the thrombus, recanalize at a rapid rate, be prone to recurrence, or have a pulmonary embolus (PE)? It is clear that heparin reduces the incidence of PE. Although it seems empirically obvi-



**Figure 4. Asymmetry suggests venous hypertension.** The absence of toe edema excludes lymphedema. In the absence of varicosities or reflux, an underlying obstruction is possible. There was no history of DVT. The patient was unhappy with the visible difference in the appearance of her legs and ankles. An ultrasound and MRI revealed a nonthrombotic common iliac stenosis or May-Thurner lesion responsible for elevated venous pressure.

ous that early removal of the thrombus mitigates the risk of PE, valve damage, and recurrent DVT, and, *ipso facto* PTS. Large controlled trials with long-term follow-up have not yet been achieved. Our clinical experience indicates that early thrombolysis may be clinically beneficial, but level 1 data are not available. Future NIH-sponsored trials will focus on these issues.

### FUTURE AREAS OF CLINICAL RESEARCH REGARDING DVT AND PTS

Is there a prethrombotic syndrome that we should be identifying to prevent DVT and possibly have an impact on the incidence of PTS? I believe the answer is *yes*. In the hospital, patients are assessed for DVT risk factors. However, healthy, active individuals rarely consider their DVT risk. Several issues regarding proactive prevention, in light of prothrombotic conditions, come immediately to mind. The controversies surrounding screening programs and evaluation for risk factors notwithstanding, it is important to open the discussion about why we do such a poor job of preventing DVT. Most of all, there is a need to teach the public about DVT.

One area of potential opportunity is identification of hypercoagulability states in healthy individuals. We screen for thrombophilia after an individual develops thromboembolism, not before. The case of former NBC reporter David Bloom tragically illustrates how the benefit of knowledge about hypercoagulability may have saved his life. Had he known he was positive for Factor V Leiden, situational prophylaxis could have lessened the risk of thrombosis in a desert environment. Had he known that he was at risk and recognized the signs, he may have received a medical evaluation and treatment for acute DVT, if diagnosed with DVT. Without this knowledge, it was difficult to prevent PE. As we know, Melanie Bloom, his wife, has subsequently contributed greatly to public awareness of DVT. Preventing DVT pre-empts the complications of DVT, such as PE and PTS.

An additional area of potential opportunity to prevent DVT regards the left iliac compression syndrome. If a person notices unilateral edema or venous insufficiency, an evaluation of the left iliac veins may reveal a mechanical compression or narrowing that predisposes such a patient to thrombosis (Figure 4). Raju reported a high prevalence of left-sided iliac lesions that represent a risk factor for DVT. If corrected with a metallic stent, the flow is improved, and the correction may mitigate thrombosis.<sup>30</sup> Should we be diagnosing and treating these nonthrombotic iliac lesions? Although the answer may be *yes* in certain cases and *no* in others, this issue points to a need for greater awareness of venous conditions wherein intervention or situational prophylaxis may be both reasonable and prudent.

TABLE 1. POSTTHROMBOTIC SYNDROME

- Limb pain, heaviness, tightness, numbness
- Edema, gradually worsens with activity
- Decreased stamina
- Limb elevation during the day and evening
- Skin changes include dryness, dependent discoloration, hyperpigmentation, telangiectasia, varicosities, stasis ulcers

If early thrombus removal can prevent venous hypertension by eliminating obstruction and preventing reflux related to valve injury, how can clinicians predict which patients merit such therapy? In other words, how do we know who will fail to respond to conventional therapy and develop PTS? This is an important area for clinical research. Relatively poor recanalization and/or collateral development and ipsilateral recurrence can be observed after the fact but are all difficult to predict *a priori*. We need to develop a profile to predict which patients will respond poorly to standard DVT therapy.

We have thoroughly evaluated more than 130 patients treated for symptomatic PTS to begin development of such a profile. Dr. Francisco Osse and I have noted a high percentage of persons with A+ blood type among symptomatic PTS patients compared to the prevalence of A+ blood type in the general population. The incidence is statistically significant. The incidence of PTS patients with O+ blood type is lower than would be expected if there is no genetic linkage. These data comprise the basis for further investigation of the relationship of blood type and thrombus resolution. The concept and study were presented to the American Venous Forum in February 2007 and submitted for publication.

### CONCLUSION

PTS is a serious problem for individuals and for society. Because the signs and symptoms of venous insufficiency manifest in many variations, PTS is not always recognized. For thousands of years, the standard treatment has been compression to control the edema and pain. The treatment of chronic vascular disease is palliative—a bandage, not a cure. With DVT, however, the sequelae of edema and pain do not develop if the thrombus is autolysed or removed early, before damage is permanent. We are challenged to treat obstructive DVT early with safe and affordable therapy to prevent the endovascular injury that leads to PTS. When patients present with PTS, long after the initial event, we can significantly decrease disability and improve QOL with endovascular reconstruction. ■

*Patricia E. Thorpe, MD, FSIR, is an interventional radiologist specializing in endovascular venous reconstruction for*

*acute and chronic venous disease consulting at the Arizona Heart Institute and Arizona Heart Hospital in Phoenix, Arizona. She has disclosed that she holds no financial interest in any product or manufacturer mentioned herein. Dr. Thorpe may be reached at [patricia-thorpe@venous.com](mailto:patricia-thorpe@venous.com) and [www.venous.com](http://www.venous.com).*

- MacDougall DA, Feliu AL, Boccuzzi SJ, et al. Economic burden of deep-vein thrombosis, pulmonary embolism and post-thrombotic syndrome. *Am J Health Syst Pharm.* 2006;63(20suppl6):S5-S15.
- Bauer G. Nine years' experience with heparin in acute venous thrombosis. *Angiology.* 1950;1:161-169.
- Kahn SR. The post-thrombotic syndrome: the forgotten morbidity of deep venous thrombosis. *J Thromb Thrombol.* 2006;21:41-48.
- Kahn SR. The post-thrombotic syndrome: current knowledge, controversies, and directions for future research. *Blood Reviews.* 2002;16:155-165.
- Kahn SR. Effect of postthrombotic syndrome on health-related quality of life after deep vein thrombosis. *Arch Intern Med.* 2002;162:1144-1148.
- Bergan JJ, Schmid-Schonbein GW, Smith PD, et al. Chronic venous disease. *N Eng J Med.* 2006;355:488-498.
- Phillips IJ II, Sarkar R. Molecular characteristics of post-thrombotic syndrome. *J Vasc Surg.* 2007;45(supplA:A):116-22.
- Agno W, Plantanida E, Dentali F, et al. Body mass index is associated with the development of postthrombotic syndrome. *Thromb Haemost.* 2003;89:305-309.
- Stain M, Schonauer V, Minar E, et al. The postthrombotic syndrome: risk factors and impact on the course of thrombotic disease. *J Thromb Haemost.* 2005;3:2671-2676.
- Schulman S, Lindmarker P, Holmstrom M, et al. Post-thrombotic syndrome, recurrence, and death 10 years after the first episode of venous thromboembolism treated with warfarin for 6 weeks or 6 months. *J Thromb Haemost.* 2006;4:734-742.
- Kahn SR, Kearon C, Julian JA, et al. Predictors of the post thrombotic syndrome during long-term treatment of proximal deep vein thrombosis. *J Thromb Haemost.* 2005;3:718-723.
- Van Dongen CJ, Prandoni P, Frullia M, et al. Relationship between the quality of anticoagulant and the development of postthrombotic syndrome. *J Thromb Haemost.* 2005;3:939-942.
- Prandoni P, Villalta S, Baagatella P, et al. The clinical course of deep-vein thrombosis: Prospective long-term follow-up of 528 symptomatic patients. *Haematologica.* 1997;82:423-428.
- Prandoni P, Lensing AW, Prins MH, et al. Residual venous thrombosis as a predictive factor of recurrent venous thromboembolism. Summary for patients in *Ann Intern Med.* 2002;137:132.
- Ziegler S, Schillinger M, Maca TH, et al. Post-thrombotic syndrome after primary event of deep venous thrombosis 10-20 years ago. *Thromb Res.* 2001;101:23-33.
- Lindner DJ, Edwards JM, Phinney ES, et al. Long-term hemodynamic and clinical sequelae of lower extremity deep vein thrombosis. *J Vasc Surg.* 1986;4:436-442.
- Janssen MC, Haenen JH, van Asten WN, et al. Clinical and haemodynamic sequelae of deep venous thrombosis: retrospective evaluation after 7-13 years. *Cli Sci (Lond).* 1997;93:7-12.
- Haenen JH, Janssen MC, van Langen H, et al. The postthrombotic syndrome in relation to venous hemodynamics, as measured by means of duplex scanning and strain-gauge plethysmography. *J Vasc Surg.* 1999;29:1071-1076.
- Singh H. Comparing short-term outcomes of femoral-popliteal and iliofemoral deep vein thrombosis: early lysis and development of reflux. *Ann Vasc Surg.* 2005;19:74-79.
- Meissner MH, Caps MT, Zierler BK, et al. Determinants of chronic venous disease after acute deep venous thrombosis. *J Vasc Surg.* 1998;28:826-833.
- Neglen P. Venous outflow obstruction: an underestimated contributor to chronic venous disease. *J Vasc Surg.* 2003;38:879-885.
- Thorpe P, Osse F, Dang H. Endovascular reconstruction for chronic iliac vein and inferior vena cava obstruction. In: Gloviczki P, Yao J, eds. *Handbook of Venous Disorders.* 2nd ed. London, UK: Arnold; 2001:347-361.
- Comerota AJ. Quality-of-life improvement using thrombolytic therapy for iliofemoral deep vein thrombosis. *Rev Cardiovasc Med.* 2002;3(suppl 2):251-257.
- O'Sullivan GJ, Lohan G, Gough N, et al. Pharmacomechanical thrombectomy of acute deep vein thrombosis with the Trellis-8 isolated thrombolysis catheter. *J Vasc Interv Radiol.* 2007;19:715-724.
- Neglen P, Raju S. In-stent recurrent stenosis in stents placed in the lower extremity venous outflow tract. *J Vasc Surg.* 2004;1:181.
- Neglen P, Raju S. Intravascular ultrasound scan evaluation of the obstructed vein. *J Vasc Surg.* 2002;4:694.
- Giannoukas A, Labropoulos N, Michaels JA. Compression with or without early ambulation in the prevention of postthrombotic syndrome: a systematic review. *Eur J Vasc Endovasc Surg.* 2006;32:217-221.
- Prandoni P, Lensing AW, Prins MH, et al. Below-knee elastic compression stockings to prevent the postthrombotic syndrome: a randomized, controlled trial. *Ann Intern Med.* 2004;141:249-256.
- Kolbach DN, Sandbrink MW, Hamulyak K, et al. Non-pharmaceutical measures for prevention of postthrombotic syndrome. *Cochrane Database Syst Rev.* 2004;(1):CD004174.
- Raju S, Neglen P. High prevalence of nonthrombotic iliac vein lesions in chronic venous disease: a permissive role in pathogenicity. *J Vasc Surg.* 2006;44:136-143.