

Percutaneous Mitral Valve Repair

An overview of the current devices and techniques.

BY RAYMOND LEUNG, MDCM, AND TED FELDMAN, MD

Mitral regurgitation (MR) arises commonly from the failure of mitral leaflet coaptation during ventricular systole. Functional and structural abnormalities of valve leaflets, annulus, or subvalvular apparatus, and left ventricular (LV) chamber dilatation upset the intricate dynamics of mitral valve function. Longstanding, severe MR leads to progressive LV volume overload, LV failure, and secondary pulmonary hypertension. At late stages of eccentric ventricular dilatation, myocardial dysfunction may become irreversible due to this chronic volume overload. Although vasodilator and diuretic therapies offer symptomatic relief, clinical trials of medical therapy have not demonstrated benefits in delaying surgery or improving survival in patients with MR.¹

Surgical mitral repair has been successful for improving symptoms and apparently improving survival for patients with degenerative MR. Functional MR has been treated with surgical repair as well, but with less impressive out-

comes, particularly in ischemic MR.

Percutaneous therapy for mitral repair has emerged over the past several years as an investigational option for the treatment of MR. A variety of advances in technique and equipment have recently facilitated development of a variety of methods to treat MR via a percutaneous route. Most of these approaches are modifications of established surgical therapies, such as mitral leaflet repair and annuloplasty. A third emerging category involves remodeling of the LV chamber in conjunction with the mitral valve.

PERCUTANEOUS MITRAL LEAFLET REPAIR

In the early 1990s, Alfieri pioneered a novel approach to mitral repair.² By simply placing a suture at the central free edges of the anterior and posterior mitral leaflets, he was able to reduce the severity of MR in patients with mitral prolapse involving the midsegment of the orifice.

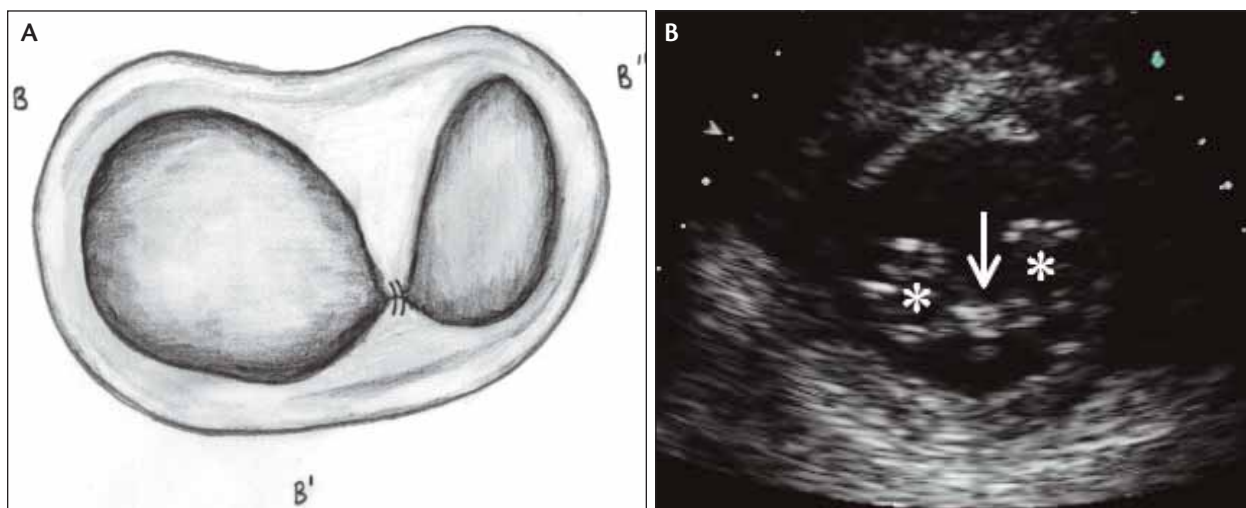


Figure 1. The double orifice or “bow-tie” mitral valve is surgically created by plicating the anterior and posterior leaflets together with a suture (A). A transthoracic echocardiographic short axis view of the mitral valve, obtained in a patient treated with percutaneous mitral leaflet repair using the Mitraclip (Evalve, Menlo Park, CA) (B). The arrow denotes the position of the clip, and the asterisks mark the two orifices.

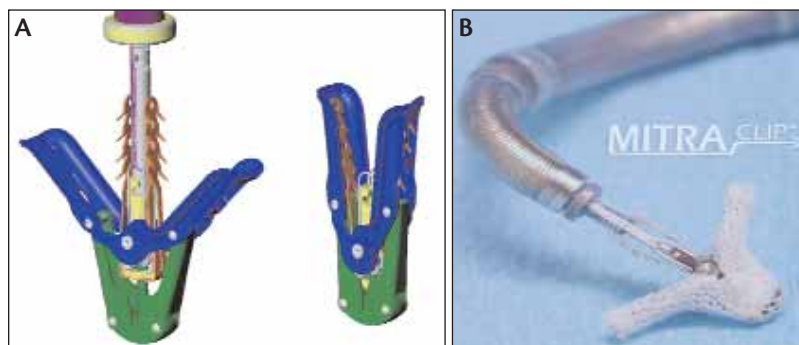


Figure 2. The Mitraclip is made of cobalt chromium. There is a barbed gripping element that captures the mitral leaflets within the clip arms. The clip is covered with polyester fabric to facilitate tissue ingrowth after implantation.

A double, or “bow-tie,” orifice is constructed by the fixation of the anterior and posterior leaflets with such a stitch, which reduces the leaflet mobility, forces leaflet approximation, and decreases regurgitant flow while maintaining normal LV contractile dynamics (Figure 1A).

A percutaneous transseptal approach using venous access to accomplish a similar Alfieri-like result has been developed (Figures 1B and 2). Using a 24-F multi-axial steering sheath/guide catheter system, a metal clip is positioned in the left atrium coaxially above the center of the mitral orifice (Figures 3 and 4). The clip is oriented perpendicular to the line of coaptation, advanced in the LV chamber, and deployed by capturing the individual leaflets simultaneously. Transesophageal echocardiography is used to assist in the positioning of the clip and evaluation of results. If sub-optimal results are achieved in the initial attempt, the clip can be reopened, the leaflets released, the clip repositioned, and the mitral leaflets regripped at a different location. In the event that moderate MR is observed after optimal placement of a first clip, a second clip may be added for improved efficacy.

A phase I clinical trial (EVEREST I [Endovascular Valve Edge-to-edge REpair Study]) using the clip has been reported.³ Surgical candidates with moderate-to-severe or severe MR with symptoms, or asymptomatic patients with signs of LV dysfunction, were included. Included patients met

the AHA-ACC guideline criteria for intervention for MR, and their echocardiograms were assessed using the American Society for Echocardiography method for assessment of MR severity. All of the echocardiograms were evaluated in a core laboratory. Six-month follow-up for 27 patients has been published³ and 1-year outcomes have been reported.⁴ More than 50 patients were ultimately enrolled in the phase I trial. When compared to the STS database, patients referred to this percutaneous procedure were older, with a median age of 71 years compared to 59 years for sur-

gical repair patients, demonstrating a bias for a less-invasive approach in the high-risk elderly population. In the EVEREST-I trial, clips were implanted in 88% of the patients. No intraprocedural major complications were observed. Thirty-day major adverse events included partial clip detachment without embolization in 7% of patients who underwent elective valve surgery and postprocedure stroke in one patient, which resolved at 1 month. All patients needing surgery had their intended, prespecified surgical mitral valve repair or replacement. Even when a clip was placed and surgery was required, subsequent surgical repair was possible as late as 18 months after clip placement.⁵ To date, the procedure has been accomplished safely, and a significant reduction in MR has been achieved in the majority of patients treated with an average length of hospital stay of fewer than 2 nights.

Management of the 24-F femoral venous puncture has not been any more challenging than for other valve interventional therapies via the transseptal route. Kaplan-Meier 2-year freedom from death, mitral valve surgery, or recurrent MR >2+ is 80% among patients discharged with successful clip therapy.

An ongoing randomized controlled trial, EVEREST II, is currently randomizing patients to percutaneous repair versus surgical approach using a 2:1 allocation, with clinical and echocardiographic follow-up. Interestingly, there has never been a prospective, core-lab–evaluated, intention-to-treat trial of mitral repair therapy reported in the surgical

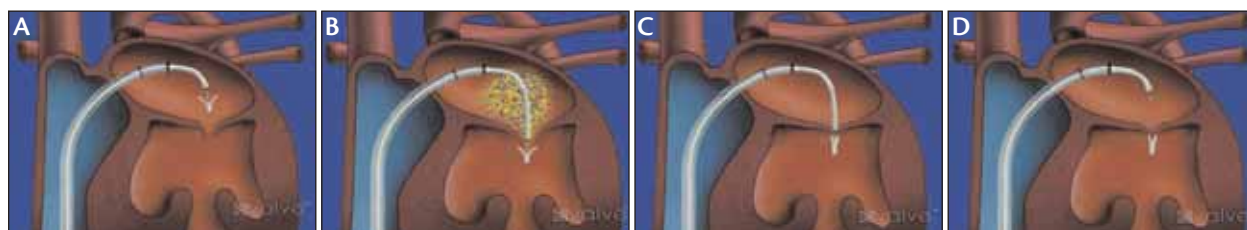


Figure 3. The clip positioned over the mitral valve, having been delivered via transseptal access (A). The clip has been passed through the mitral orifice (B). The clip has been pulled back to grasp the mitral leaflets and then closed (C). The clip after it has been released, with the guide catheter and delivery system still in the left atrial chamber (D).

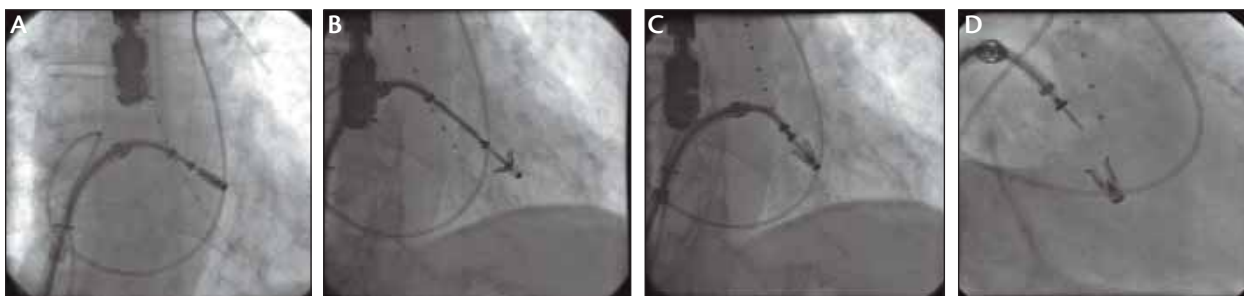


Figure 4. The same steps shown in Figure 3 are illustrated in fluoroscopic frames. The closed clip above the mitral leaflets (A). The clip has been passed into the LV distal to the mitral leaflet tips (B). The clip has been pulled back and partially closed to grasp mitral leaflets (C). The clip after release, with the delivery system remaining in the left atrial cavity (D).

literature. Thus, the proportion of patients for whom repair is intended, but in whom replacement is ultimately performed, is not clearly defined. Moreover, the results of mitral repair, in terms of the degree of reduction of MR, have never been assessed using objective criteria through an echocardiography core lab with semiquantitative MR grading.⁶ The EVEREST phase II trial will be groundbreaking, not only in the development of the percutaneous therapy, but also in defining the contemporary results of mitral valve surgery. Benefits in the subgroups of elderly, high-risk surgical patients, or younger asymptomatic patients with MR, will require further trials and clinical experience.

PERCUTANEOUS MITRAL ANNULOPLASTY

The mainstay of surgical repair for MR has been annuloplasty. Surgical placement of a suture or ring, which partially or completely encircles the mitral annulus, has been

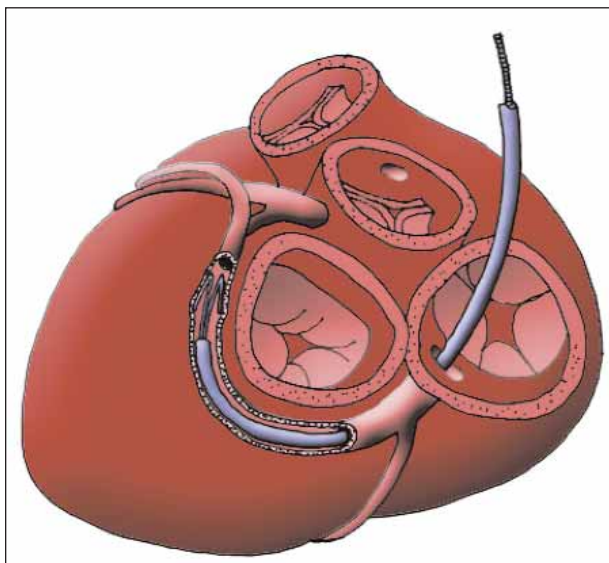


Figure 5. Coronary sinus mitral annuloplasty is performed via access to the coronary sinus from the right internal jugular vein. A guide catheter is placed distal in the coronary sinus, and a device is unsheathed to place tension on the mitral annulus.

employed with variable success for many years.⁷

Recognition that the coronary sinus parallels the mitral annulus has led to several percutaneous approaches.⁸ A device may be passed via the coronary sinus toward the great cardiac vein and thus encircle approximately two-thirds to three-quarters of the circumference of the mitral annulus in a manner analogous to that achieved using surgical annuloplasty rings. The potential to capture enough circumference of the coronary sinus to achieve a reduction in MR is the key element for this approach (Figure 5). A variety of devices, delivered via a transvenous jugular approach, can be placed into the coronary sinus (Figure 6). Tension placed on the coronary sinus results in a decrease in the mitral annular circumference. In animal models, this has resulted in significant, sustained improvements in MR.⁹

Intraoperative testing of some of these coronary sinus implants has been evaluated on a temporary basis, without permanent device implantation. Patients taken for surgical mitral annuloplasty have had a percutaneous device placed while on the operating table. The degree of reduction in MR can be evaluated, and then the device can be removed and the planned surgical procedure completed. Temporary intraoperative experience with this class of devices has shown improvements in MR and provided a foundation for both further device design improvements and some initial human permanent implants.

Preliminary work in autopsy specimens and in limited temporary implantation in small numbers of patients has shown that the relationship of the coronary sinus to the mitral annulus in patients is highly variable compared to what has been observed in preclinical models. In addition, branches of the circumflex coronary artery cross over or under the coronary sinus, and coronary compression may limit the degree to which the coronary sinus may be encircled.

The first permanent human implants of a coronary sinus annuloplasty device were reported recently, using the Monarc device (Edwards Lifesciences, Irvine, CA).¹⁰ The device uses two self-expanding stents connected with



Figure 6. The Carillon (Cardiac Dimensions, Kirkland, WA) device is placed via jugular venous coronary sinus access using a guide catheter (A). The device being released in the coronary sinus and placing tension on the mitral annulus (B). The device has been released, and the regurgitant orifice has been reduced (C).

a spring-like “bridge.” The distal stent anchors in the great cardiac vein, and the proximal stent anchors in the proximal coronary sinus. The bridge between the stents, held initially in a stretched position by bioabsorbable material, diminishes the mitral annular circumference as the bridge shortens over the course of 3 to 6 weeks. Among five reported patients, the bridge fractured in three, without any clinical complications, but with a loss of efficacy, which led to a redesign of the device. The trial has been resumed. It is clear that many problems must be solved before these technologies are ready for widespread use.

An approach to mitral annuloplasty that eliminates some of the challenges posed by the coronary sinus involves direct access to the LV with placement of a device on the ventricular side of the mitral annulus (Figure 7). This direct annuloplasty technique is based on

the surgical use of suture plication annuloplasty.¹¹⁻¹⁴

Access to the annulus via the small space underneath the posterior mitral leaflet via retrograde aortic catheterization has been accomplished using conventional catheter methods. Anchors are placed directly through the mitral annulus and are then tethered together. The tether is tensioned in a manner analogous to tightening the drawstring on surgical scrub pants, resulting in plication of the mitral orifice. Percutaneous direct annuloplasty via this route has been accomplished successfully in animal models.

LEFT VENTRICULAR REMODELING

A novel approach to treating functional MR by remodeling the LV chamber has been evaluated surgically in a phase I trial.¹⁵ The device is composed of a pair of epicardial pads that are anchored on the LV surface, with a tensioning cable passed through the LV cavity to pull the pads together, thereby reducing the septal-to-lateral dimension of the mitral annulus and diminishing the LV chamber diameter (Figure 8). This results in reorientation of papillary muscle and reduction of LV geometric distortion caused by ventricular chamber dilatation. In the surgical experience, reductions in MR have been sustained up to 1 year, and LV chamber dimensions have had sustained improvement. More than 100 patients have been treated with the surgical device, and the technique has been translated to a percutaneous transepicardial approach. Methods for reliable percutaneous pericardial access have been developed and are currently under development in animal models.¹⁶ Another chamber remodeling approach uses a tether passed through the left atrial cavity, using anchors in the coronary sinus and fossa ovalis. The mitral orifice is compressed by indirect tension.¹⁷

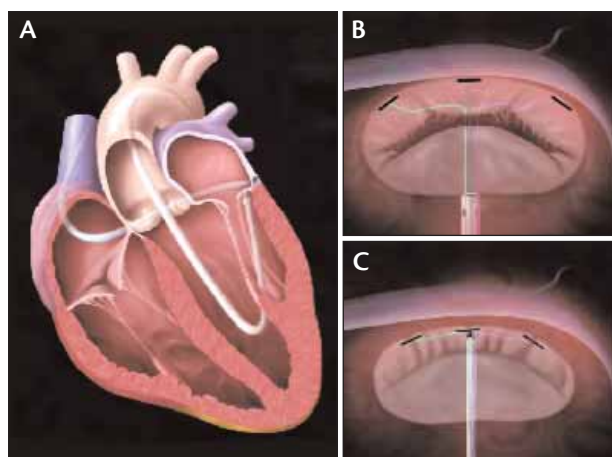


Figure 7. Direct access to the mitral annulus may be obtained by retrograde catheterization of the LV. A catheter placed behind the posterior leaflet, directly abutting the mitral annulus (A). Anchors can be placed in the mitral annulus and tethered together using percutaneous methods (B). When the anchors are tightened, they act as a drawstring to plicate the mitral annulus (C).

CLINICAL TRIAL CONSIDERATIONS

Evaluation of these new devices for MR therapy poses new challenges. Comparisons with surgical results are inevitable. Remarkably, there are almost no prospective

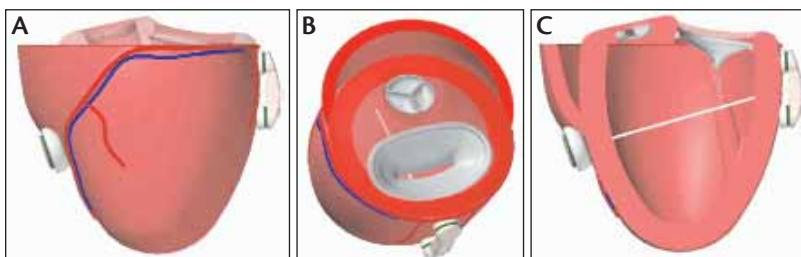


Figure 8. A novel approach to placing tension on the mitral valve from the septal to lateral dimensions, and at the same time, remodeling the LV chamber has been developed as a new surgical procedure using the Mycor Coapsys system (Maple Grove, MN). The anterior and posterior epicardial pads can be seen (A). A tether connects the two pads. When the tether is tensioned, the mitral annulus is compressed, and the LV chamber dimensions are reduced (B, C). A transpericardial percutaneous delivery method has been developed to adapt this surgical procedure to a catheter-based approach.

data on the results of mitral repair surgery. Intention-to-treat analyses of mitral repair surgery have not been performed. Multicenter trials, core echocardiographic laboratories, and events committees have never been utilized for surgical trials. Patient selection for catheter-based approaches is likely to be different than for surgery. This has been noted in the EVEREST phase I trial, in which the median age for catheter repair patients is almost 20 years older than for STS database surgical repair patients.

Trials for many new therapies must demonstrate superiority for efficacy and noninferiority for safety. Because nonsurgical devices are so inherently different from surgery, these device trials will assess efficacy with noninferiority. It is expected that percutaneous devices will have less morbidity than surgery, so safety will be evaluated using superiority endpoints versus surgery.

Catheter-based percutaneous devices are fundamentally different than surgery; specifically, the potential for serial treatment, in a manner similar to staged coronary interventions, is possible with a percutaneous approach.

A few patients in the EVEREST trial have had one clip placed and, at a later time, have undergone placement of a second clip to further improve the degree of MR. In addition, as long as surgical options are not impaired by catheter therapy, the demands for efficacy may be less than for surgery. It will be possible to try a percutaneous approach, defer surgery in some patients, and have surgical options for those in whom catheter treatment is not adequate.

SUMMARY

It is clear that a spectrum of approaches to repair MR is developing.

None of these devices will result in a treatment for all patients with MR, and not all will likely be ultimately successful.¹⁸ Recognition of different pathoanatomy of MR in different patient groups, and definition of specific methods needed to repair different pathologies, is essential for successful surgical or percutaneous treatment. Therapy for dilated cardiomyopathy with functional MR, ischemic MR, and mitral valve prolapse will require different approaches to repair. Continued development from bench to bedside will require a collaborative approach from surgical, diagnostic, and interventional cardiovascular specialists.¹⁹ ■

Raymond Leung, MDCM, is an interventional cardiologist at Royal Alexandra Hospital, Edmonton, Alberta, Canada. He has disclosed that he holds no financial interest in any product or manufacturer mentioned herein. Dr. Leung may be reached at ray@leung.net.

Ted Feldman, MD, is from the Cardiology Division, Evanston Hospital, Evanston, Illinois. He has disclosed that he receives

COMMENTARY

By William A. Gray, MD

The authors have provided a nice overview of the state of the art in percutaneous mitral valve therapies. Although nonsurgical approaches to mitral as well as aortic valvular heart disease are being developed with remarkable new tools and at a rapid pace, it is clear that this is no low-hanging fruit. In spite of the promise of several different technologies and the continued expectation of success, there have been several setbacks to many of the solutions proposed, which have required rethinking and retooling along the way. As evidence of these difficulties, witness that today there is only one randomized trial in progress in the US (EVEREST II) and, save for the Edwards percutaneous implantable aortic valve investigation, precious little other experience in nonsurgical methods.

Nevertheless, prospects for the future of these therapies are good. Patient preference is strongly in favor of nonsurgical approaches, and although inclusion into current and anticipated trials is restrictive, once approved, it is likely that these therapies will be more widely accessible to patients with on-label indications but broader anatomic and clinical presentations.

grant support from Evalve and is a paid consultant with Edwards. Dr. Feldman may be reached at (847) 570-2250; tfeldman@enh.org

1. Carabello B, Chatterjee K, de Leon AC Jr, et al. ACC/AHA 2006 Guidelines for the management of patients with valvular heart disease: a report of the American College of Cardiology/American Heart Association Task Force on Practice Guidelines (Writing Committee to revise the 1998 Guidelines for the Management of Patients with Valvular Heart Disease). *J Am Coll Cardiol*. 2006;48:e1-e148.
 2. Alfieri O, Maisano F, De Bonis M, et al. The double-orifice technique in mitral valve repair: a simple solution for complex problems. *J Thorac Cardiovasc Surg*. 2001;122:674-681.
 3. Feldman T, Wasserman HS, Herrmann HC, et al. Percutaneous mitral valve repair using the edge-to-edge technique: six-month results of the EVEREST Phase I Clinical Trial. *J Am Coll Cardiol*. 2005;46:2134-2140.
 4. Feldman T, Wasserman HS, Herrmann HC, et al. Edge-to-edge mitral valve repair using the Evalve MitraClip: one year results of the EVEREST phase I clinical trial. *Am J Cardiol*. 2005;96(suppl 7A):49H.
 5. Dang NC, Aboodi MS, Sakaguchi T, et al. Surgical revision after percutaneous mitral valve repair with a clip: initial multicenter experience. *Ann Thorac Surg*. 2005;80:2338-2342.
 6. Zoghbi WA, Enriquez-Sarano M, Foster E, et al. Recommendations for evaluation of the severity of native valvular regurgitation with two-dimensional and Doppler echocardiography. *J Am Soc Echocardiogr*. 2003;16:777-802.
 7. Grossi EA, Goldberg JD, LaPietra A, et al. Ischemic mitral valve reconstruction and replacement: comparison of long-term survival and complications. *J Thorac Cardiovasc Surg*. 2001;122:1107-1124.
 8. Mani CV, Patel JB, Reuter DG, et al. Acute and chronic reduction of functional mitral regurgitation in experimental heart failure by percutaneous mitral annuloplasty. *J Am Coll Cardiol*. 2004;44:1652-1661.
 9. Byrne MJ, Kaye DM, Mathis M, et al. Percutaneous mitral annular reduction provides continued benefit in an ovine model of dilated cardiomyopathy. *Circulation*. 2004;110:3088-3092.
 10. Webb JG, Harnek J, Munt BI, et al. Percutaneous transvenous mitral annuloplasty: initial human experience with device implantation in the coronary sinus. *Circulation*. 2006;113:851-855.
 11. Burr LH, Krayerbuhl C, Sutton MS. The mitral plication suture: a new technique of mitral valve repair. *J Thorac Cardiovasc Surg*. 1977;73:589-595.
 12. Nagy ZL, Bodi A, Vaszily M, et al. Five-year experience with a suture annuloplasty for mitral valve repair. *Scand Cardiovasc J*. 2000;34:528-532.
 13. Nagy ZL, Peterffy A. Mitral annuloplasty with a suture technique. *Eur J Cardio Thorac Surg*. 2000;18:739-741.
 14. Aybek T, Risteski P, Miskovic A, et al. Seven years' experience with suture annuloplasty for mitral valve repair. *J Thorac Cardiovasc Surg*. 2006;131:99-106.
 15. Grossi EA, Saunders PC, Woo YJ, et al. Intraoperative effects of the coapsys annuloplasty system in a randomized evaluation (RESTOR-MV) of functional ischemic mitral regurgitation. *Ann Thorac Surg*. 2005;80:1706-1711.
 16. Pedersen WR, Block PC, Feldman TE. The iCoapsys Repair System for the percutaneous treatment of functional mitral insufficiency. *Eurointervention*. 2006;1(suppl A):A44-48.
 17. Rogers JH, Macoviak JA, David A, et al. Percutaneous septal sinus shortening: a novel procedure for the treatment of functional mitral regurgitation. *Circulation*. 2006;113: 2329-2334.
 18. Feldman T. Percutaneous valve repair and replacement: challenges encountered, challenges met, challenges ahead. *Circulation*. 2006;113:771-773.
 19. Vassiliades TA Jr, Block PC, Cohn LH, et al. The clinical development of percutaneous heart valve technology: an interdisciplinary position statement—The Society of Thoracic Surgeons (STS), The American Association for Thoracic Surgery (AATS), The American College of Cardiology (ACC), and The Society of Cardiovascular Angiography and Intervention (SCAI). *Cathet Cardiovasc Diagn*. 2005;65:73-79. *Ann Thorac Surg*. 2005;79:1812-1818. *J Am Coll Cardiol*. 2005;49:1554-1560. *J Cardiovasc Thor Surg*. 2005;129:970-976.
-