

Sponsored and produced in collaboration with Boston Scientific Corporation.

Results Using the PolarCath Peripheral Dilatation System and Sterling PTA Balloon Dilatation Catheter

Percutaneous intervention of an occluded SFA.

BY GREGORY K. KUMKUMIAN, MD

This case study illustrates the endovascular management of an occluded right superficial femoral artery (SFA) utilizing an ultra-low-profile peripheral balloon catheter to assist in canalizing the lesion, and use of the PolarCath Dilatation System (Boston Scientific Corporation, Natick, MA) for final treatment of the site. A 63-year-old woman presented with intermittent claudication of the right leg that had persisted for 8 years. She also had a history of hypertension and renal insufficiency.

During the previous 3 months, the patient's leg pain progressively worsened and significantly limited her ability to walk. Typically, the pain involved a burning sensation in the calf and thigh that improved promptly with rest. Previous evaluations, including Doppler examination, showed a high-grade, proximal right SFA lesion. Medical management and exercise had not improved the patient's tolerance of physical activity and, until recently, she was not interested in invasive therapies to treat her leg pain.

DIAGNOSTIC EVALUATION

The initial evaluation found the left leg to be normal, but the right leg was markedly abnormal. Although the right femoral pulse was 2+, the right popliteal pulse was nonpalpable. The dorsalis pedis and posterior tibialis pulses were also nonpalpable and were obtainable only with Doppler assistance. Arterial Doppler examination revealed ankle-brachial indices (ABI) of 0.8 on the left and 0.5 on the right. There were no other findings of diminished vascular flow to the right leg or foot. Laboratory examination showed a creatinine level of 1.6 mg/dL.

A previous Doppler examination of the lower-left extremity indicated an occluded left peroneal artery but no other significant arterial disease. Evaluation of the right leg showed a severe narrowing of the proximal right SFA, with re-establishment of flow at the level of the popliteal artery, an occluded right peroneal artery, and two-vessel runoff to the right foot.

Magnetic resonance angiography of the lower extremities confirmed

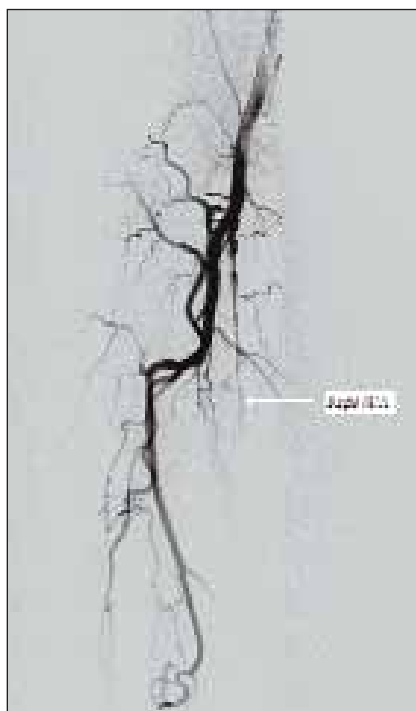


Figure 1. Initial angiogram demonstrating an occluded proximal SFA.

an occluded left peroneal artery and showed a proximal occlusion of the right SFA. The distal right superficial artery/popliteal artery reconstituted at the level of Hunter's canal. Magnetic resonance angiography also confirmed occlusion of the right peroneal artery. There was no evidence of renal artery stenosis.

THE PROCEDURE

Access was attained through the left femoral artery and, using the crossover technique, a 55-mm, 6-F Flexor sheath (Cook Incorporated, Bloomington, IN) was advanced to the right common femoral artery. Angiography of the right leg confirmed an occluded proximal right SFA (Figure 1). Furthermore, fluoroscopy showed a heavily calcified artery. The patent aspect of the proximal SFA appeared small, with severe diffuse disease. There was an extensive array of collaterals that reconstituted flow in the distal superficial artery/popliteal artery at the level of Hunter's canal. Two-vessel runoff to the right foot was verified.

After administration of bivalirudin, an .018-inch, V-18



Figure 2. A Sterling balloon is advanced and inflated at the occlusion site.




Figure 3. A PolarCath balloon is used to dilate and treat the artery.

Control Wire Guide Wire (Boston Scientific Corporation) was selected due to its support and torqueability, and was advanced, with some difficulty, to approximately halfway through the occlusion. At this point, a 4-mm X 100-mm Sterling balloon catheter (Boston Scientific Corporation) (Table 1) was advanced to the tip of the V-18 Control Wire. Using the balloon for back-up support, the guidewire and balloon were advanced through the remainder of the occlusion in a stepwise fashion. The Sterling balloon was then used for initial dilatation of the diseased segment, measuring 25 cm in length (Figure 2). After a series of dilata-

tions, angiography revealed a patent SFA; however, severe diffuse disease persisted.

A 5-mm X 80-mm PolarCath Peripheral Dilation System (Boston Scientific Corporation) (Table 2) was then used to dilate and treat the right SFA (Figure 3). Two inflations were made at each site, beginning at the distal superficial femoral/popliteal artery up to the origin of the right SFA.

TABLE 1. THE STERLING PTA BALLOON DILATATION CATHETER

The Sterling PTA Balloon Dilatation Catheter is an ultra-low-profile peripheral balloon engineered to cross the most challenging lesions, including subtotal occlusions. The balloon catheter is available in both over-the-wire and rapid-exchange platforms in diameters ranging from 3 mm to 10 mm, with lengths up to 100 mm. The balloon features a laser-formed tapered tip and smooth, laser-bonded transitions that promote excellent trackability.

TABLE 2. THE POLARCATH PERIPHERAL DILATATION SYSTEM

The PolarCath Peripheral Dilatation System uses nitrous oxide to fill an angioplasty balloon, cooling its surface to -10°C. As it is inflated, the cold surface of the balloon cools the vascular lesion, which exerts both mechanical and biological effects that may help prevent restenosis. Biologically, cooling promotes a process called *apoptosis*, which reduces excessive thickening of the new layer of smooth muscle cells after angioplasty.

RESULTS AND DISCUSSION

Follow-up angiography showed a widely patent right SFA, with only mild residual stenosis at the previously occluded site (Figure 4). At 8 weeks after the procedure, the patient had no limitations due to claudication. Her ABI on the right side was 0.85. We typically perform a Doppler evaluation at 3 months to confirm patency and a repeat study at 9 to 12 months.

Several techniques employed in this case warrant a brief discussion. Frequently, when a heavily calcified lesion is encountered, it is necessary to exchange for a .035-inch wire or to utilize a guide catheter for additional support in crossing the lesion. However, in this case, an attempt was made to cross the occlusion using only a wire and a PTA balloon. The Sterling balloon catheter was selected because its ultra-low profile would enable us to proceed with an endovascular approach. Furthermore, the balloon's tapered tip may provide an added advantage over a Glidecath Catheter (Terumo Medical Corporation, Somerset, NJ) in its ability to advance through subtotal occlusions.

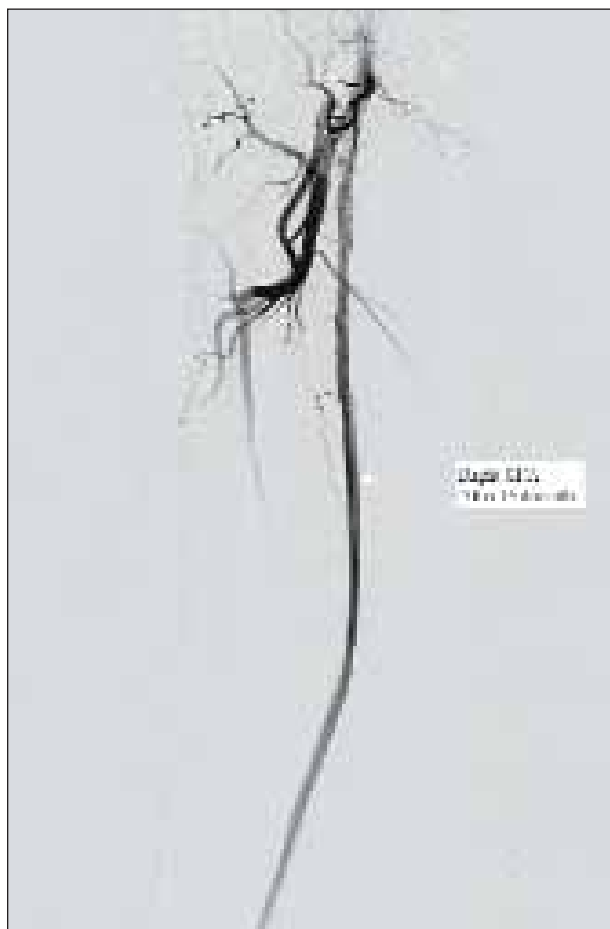

Figure 4. Final angiogram showing widely patent right SFA after percutaneous intervention.

"Recent advances have made the percutaneous approach not only reasonable but often favored."

When treating long, chronic occlusions of the SFA, there is not only a desire to recanalize the artery, as was accomplished with balloon angioplasty in this case, but also to achieve a good acute result. In our practice, stents are typically employed only on a provisional basis because stent fracture and restenosis can be formidable obstacles to long-term patency. Stents also limit potential future interventions, particularly those placed in the femoropopliteal region. Alternately, we have had favorable experience with the short- and long-term patency rates associated with cryoplasty and are encouraged by the acute results, as illustrated by this case.

CONCLUSION

Chronic total occlusions (CTOs) of the SFA are challenging lesions that, in the past, were not approachable percutaneously. Recent advances have made the percutaneous approach not only reasonable but often favored. Various tools are now available to assist in crossing CTOs, including the Excimer laser (Spectranetics Corporation, Colorado Springs, CO) and intravascular ultrasound-guided wires. The Sterling balloon is a very low-profile peripheral balloon that is an excellent new tool available for crossing and initial dilatation of CTOs. Often, as in this case, cryoplasty can be a stand-alone treatment for CTOs. Initial studies have shown good acute and long-term results with this technique.¹ ■

Gregory K. Kumkumian, MD, is an interventional cardiologist at Montgomery General Hospital in Olney, Maryland, and Washington Adventist Hospital in Takoma Park, Maryland. He has disclosed that he holds no financial interest in any product or manufacturer mentioned herein. Dr. Kumkumian may be reached at (301) 670-3000; g.kumkumian@att.net.

1. Laird JR, Jaff MR, Biamino G, et al. Cryoplasty for the treatment of femoropopliteal arterial disease: results of a prospective, multi-center registry. *J Vasc Interv Radiol.* 2005;16:1067-1073.