

The Use of IVUS for Renal Artery Fibromuscular Dysplasia

This imaging modality may play a key role in the endovascular treatment of patients with RAFMD.

BY ALBEIR Y. MOUSA, MD; ARAVINDA NANJUNDAPPA, MD, RVT, MBA;

PATRICK A. STONE, MD; AND JOHN E. CAMPBELL, MD

Since it was first described by Leadbetter and Burkland in 1938, renal artery fibromuscular dysplasia (RAFMD) has been recognized as a main category in nonatherosclerotic arterial diseases especially but not exclusively in women between 20 and 60; the disease can affect elderly men as well as children. RAFMD accounts for < 10% of patients with symptomatic renal artery stenosis. Of the three main types of FMD, medial hyperplasia is the most common; the other two forms are intimal and adventitial dysplasia.^{1,2}

Renal arteries (right more often than left) are affected most frequently followed by carotid arteries and then the iliac arteries. Although it is rare, mesenteric arterial involvement has also been reported. Bilateral vessel involvement can occur in up to 35% of patients. In contrast to atherosclerotic renal artery disease, RAFMD is rarely associated with a decrease in renal mass or function. However, progression of stenosis can occur in up to 37% of patients; fortunately, renal artery occlusion with subsequent renal infarct is extremely rare.¹⁻³ Consequently, some authorities have recommended only medical treatment for patients with RAFMD. The main clinical presentation of RAFMD is uncontrolled blood pressure, especially in young patients in their 20s or 30s.

Better management of this disease starts with early diagnosis; therefore, keeping a high index of suspicion is crucial to initiating adequate therapy. A diagnosis can be established by multiple modalities such as renal artery duplex ultrasound, multidetector computed tomography, and magnetic resonance angiography. Currently, the most accurate diagnostic method is subtraction angiography with a classic “string of beads” appearance, which is

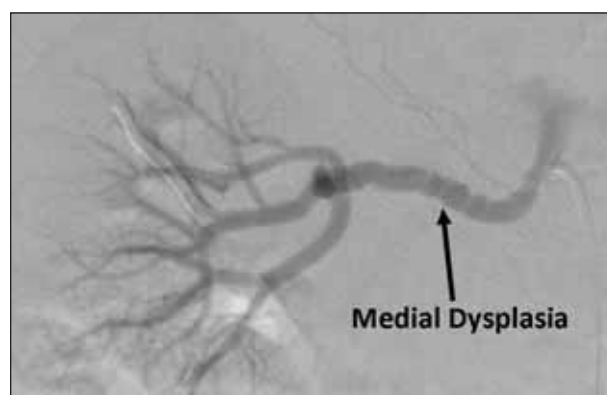


Figure 1. Right renal artery angiogram showing the beading characteristics of the medial type of FMD.

pathognomonic for the medial type of FMD, or focal narrowing that can be seen in a patient with an intimal type of RAFMD (Figures 1 and 2).

However, angiography has its limitations. In the anteroposterior view, the ostium will not be well visualized, proper plaque characterization will be lacking, and a tremendous discrepancy can be encountered when it comes to vessel sizing. It is very important to recognize that the human aorta can change up to 40% with every cardiac cycle; therefore, dynamic assessment is crucial in regard to vessel size. Also, the use of pressure gradients is controversial because the webs associated with FMD can be compressed with a catheter or pressure wire, and this may cause a false-negative reading. Additionally, there could be a flow-mediated impact on downstream tissue that is independent of the gradient. New advancements in technology, including the

development of low-profile systems, have made treatment with endovascular techniques safer with decreased possible complications. However, the single most important advancement that has occurred, in our opinion, is the development of intravascular ultrasound (IVUS) (Figure 3).

IVUS FOR RAFMD

The main idea behind IVUS is that high-frequency sound waves can be emitted from a transducer on a catheter. There are two types of IVUS: mechanical and solid state (digital and rotational catheters). In our practice, we use an IVUS transducer, which has three different catheters that can be used according to the intended vessel for examination: (1) an Eagle Eye catheter (Volcano Corporation, San Diego, CA) over a 0.014-inch wire (for renal and carotid lesions), (2) a Vision MR electrophysiology ablation catheter (Imricor Medical Systems, Burnsville, MN) with a 0.018-inch wire (for iliac vessels), and (3) a 0.035-inch-compatible catheter (for aortic lesions).

Plaque morphology is also important to be aware of. The majority of atherosclerotic plaques are fibrotic, which can contribute to acoustic shadowing and can be misinterpreted as calcium on IVUS. Soft plaques are usually less echogenic, secondary to high lipid content. Identification of such kinds of plaques can aid in case planning to prevent the “toothpaste effect” on adjacent vessels during stent placement. Keep in mind, low-echogenic plaques on IVUS can be secondary to a necrotic zone within the plaque itself or intramural hematoma. Also, careful characterization of vulnerable plaques with a fibrous or lipid core can help to prevent distal thromboembolizations.

The utility of IVUS in RAFMD cannot be underestimated and can help in many aspects before intervention, including proper vessel sizing, estimating the severity and distribution of pathology, detecting incidental plaque morphology and determining the degree of calcium and thrombus (virtual histology can add more value to IVUS to help characterize plaque morphology), and making an accurate diagnosis on dissection, entry point, and length of the lesion.

IVUS can also help in many aspects after intervention, including accurate estimation for cross-sectional area gain, characterization of stent placement (ie, for ostial lesions), proper evaluation of any cross-sectional fibrous bands (webs) after balloon dilation of FMD lesions (Figure 3), evaluation of stent expansion and in-stent restenosis, and providing insight regarding types of stent (coil vs tubular).

There are some limitations to IVUS as well, including bright echoes that can result from calcium load and interfere with proper sizing (calcification is usually brighter than adventitia), reverberations that can cause repeating arcs, and a potential for motion artifact and nonuniform rotational distortion.

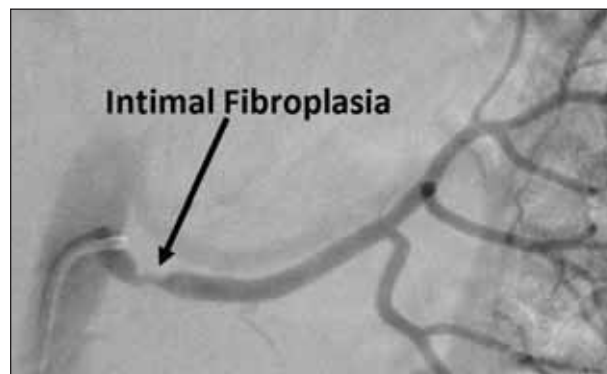


Figure 2. Left renal artery angiogram showing the intimal type of FMD.

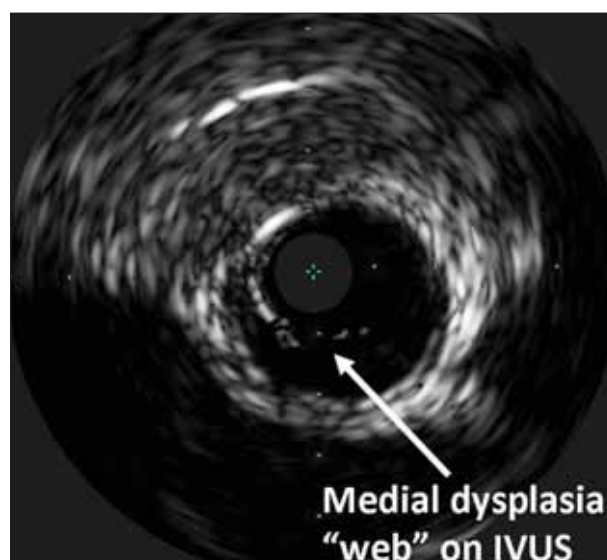


Figure 3. IVUS examination of the renal artery showing the web-like structure in RAFMD.

IVUS is more valuable in the diagnosis of RAFMD because there is no endpoint for the disease on conventional angiography. Identifying the location and integrity of fibrous bands before and after intervention can help to determine the proper treatment (Figure 3). In the event of dissection, the following steps are important: (1) maintain wire access across the lesion; (2) evaluate with IVUS entry point and length of lesion; (3) perform a prolonged inflation with the appropriate balloon (usually a 1:1 balloon); (4) if dissection persists, proceed with a self-expanding stent (1:1 in size); (5) reevaluate with IVUS; and (6) confirm with angiography while wire access is still in place.

TREATMENT OPTIONS AND OUTCOMES

The advent of catheter-based therapy has replaced standard open surgical intervention as the main and initial ther-

apy for renal artery stenosis.¹ The feasibility of renal artery angioplasty to treat FMD that is limited to the main renal artery has been examined and evaluated in many studies, including research by our group.⁴⁻⁷ Some studies have advocated the use of cutting balloons for angioplasty in recurrent or resistant RAFMD lesions after failure of conventional balloon therapy secondary to recoil and significant residual stenosis.⁸ However, extreme caution with accurate balloon sizing is crucial for preventing rupture of the renal artery, which has been reported and can be devastating.^{9,10} In addition, there is no evidence that cutting balloons reduce disease recurrence or enhance outcomes.

We have recently examined the feasibility of angioplasty in patients with RAFMD and conducted a retrospective analysis of all patients with RAFMD who underwent angioplasty during the last 10 years. The effect on glomerular filtration rate and hypertension were examined. All procedures were performed using femoral access and rapid-exchange balloons via a 0.014-inch wire platform. We used conventional balloons (no cutting balloons) during this period. All operators used either a no-touch technique or telescoping technique to prevent atheroembolization during manipulation of the guide catheter. Also, in the majority of our interventions, we used IVUS to prevent undersizing or oversizing of the angioplasty balloon. In addition, the institutional standard was to perform balloon angioplasty alone and to only perform stenting of the lesion for bailout if significant recoil failed to respond to prolonged inflation in cases of associated aorto-ostial atherosclerotic disease or in response to vessel dissection. All patients were discharged home on clopidogrel for 6 weeks followed by aspirin indefinitely.

There were 43 procedures performed in 35 patients with RAFMD. The technical success rate was 100%, with adjunctive stent placement required in the FMD segment for dissection in one patient (2.3%) and in non-FMD aorto-ostial atherosclerotic lesions in four patients (9.3%). Technical success in this cohort was 100%, with 69% of patients having an immediate improvement in hypertension and renal function increasing significantly (estimated glomerular filtration rate, 51%–69%; $P = .002$). At 10 years, 41% of patients had maintained improvement in hypertension, and 64% of patients had freedom from reduced renal function. Long-term outcomes for freedom from recurrent hypertension (> 140 mm Hg systolic blood pressure and > 90 mm Hg diastolic blood pressure) was 95%, 75%, and 43%, and freedom from renal failure was 100%, 95%, and 65% at 1, 5, and 8 years, respectively. Baseline reduced renal function (< 60 mL/min) was an independent predictive variable for long-term renal failure ($P = .003$). Primary and assisted primary patency for the entire group were 95%, 71%, and 50%, and 100%, 97%, and 97% at 1, 5, and 9 years, respectively.

Our study highlighted a few important facts. Renal artery angioplasty is a safe and durable tool for patients with symptomatic RAFMD. Also, the use of IVUS provides accurate and dynamic assessment of web-like lesions of RAFMD, and the long-term effect of maintaining normal hypertension was not as durable as freedom from reduced renal function.

CONCLUSION

RAFMD is a valid concern for younger patients with uncontrolled hypertension. Early diagnosis and prompt management can afford better long-term outcomes. Minimally invasive techniques are a promising tool to treat these lesions, and IVUS can augment our understanding of the severity of the disease and can provide assessment for better treatment of this disease. ■

Albeir Y. Mousa, MD, is Assistant Professor of Surgery at Robert C. Byrd Health Sciences Center, West Virginia University in Charleston, West Virginia. He has disclosed that he has no financial interests related to this article. Dr. Mousa may be reached at amousa@hsc.wvu.edu.

Aravinda Nanjundappa, MD, RVT, MBA, is Associate Professor of Medicine and Surgery, Division of Vascular Surgery at Robert C. Byrd Health Sciences Center, West Virginia University in Charleston, West Virginia. He has disclosed that he has no financial interests related to this article.

Patrick A. Stone, MD, is Assistant Professor in the Department of Surgery at Robert C. Byrd Health Sciences Center, West Virginia University in Charleston, West Virginia. He has disclosed that he has no financial interests related to this article.

John E. Campbell, MD, is Assistant Professor in the Department of Surgery at Robert C. Byrd Health Sciences Center, West Virginia University in Charleston, West Virginia. He has disclosed that he has no financial interests related to this article.

1. Slovut DP, Olin JW. Fibromuscular dysplasia. *N Engl J Med*. 2004;350:1862-1871.
2. Vuong PN, Desoutter P, Mickley V, et al. Fibromuscular dysplasia of the renal artery responsible for renovascular hypertension: a histological presentation based on a series of 102 patients. *Vasa*. 2004;33:13-18.
3. Slovut DP, Olin JW. Fibromuscular dysplasia. *Curr Treat Options Cardiovasc Med*. 2005;7:159-169.
4. Birrer M, Do DD, Mahler F, et al. Treatment of renal artery fibromuscular dysplasia with balloon angioplasty: a prospective follow-up study. *Eur J Vasc Endovasc Surg*. 2002;23:146-152.
5. Bisschops RH, Popma JJ, Meyerowitz MF. Treatment of fibromuscular dysplasia and renal artery aneurysm with use of a stent graft. *J Vasc Interv Radiol*. 2001;12:757-760.
6. Davies MG, Saad WE, Peden EK, et al. The long-term outcomes of percutaneous therapy for renal artery fibromuscular dysplasia. *J Vasc Surg*. 2008;48:865-871.
7. Hagg A, Lorelius LE, Morlin C, Aberg H. Percutaneous transluminal renal artery dilatation for fibromuscular dysplasia with special reference to the acute effects on the renin-angiotensin-aldosterone system and blood pressure. *Acta Med Scand Suppl*. 1985;693:93-96.
8. Tanemoto M, Abe T, Chaki T, et al. Cutting balloon angioplasty of resistant renal artery stenosis caused by fibromuscular dysplasia. *J Vasc Surg*. 2005;41:898-901.
9. Oguzkurt L, Tercan F, Gulcan O, Turkoz R. Rupture of the renal artery after cutting balloon angioplasty in a young woman with fibromuscular dysplasia. *Cardiovasc Intervent Radiol*. 2005;28:360-363.
10. Lupatelli T, Nano G, Inglesse L. Regarding "Cutting balloon angioplasty of renal fibromuscular dysplasia: a word of caution." *J Vasc Surg*. 2005;42:1038-1039; author reply 1039-1040.