

Coil Embolization for Renal Artery Aneurysm

A case report demonstrating coil embolization and stent placement as a safe and effective alternative treatment modality to the traditional open aneurysmectomy and revascularization.

BY KAK RAE KIM, MD; HAMID ZAHIRI, DO; JIAN CAI, RVT; RICHARD WILKERSON, MD; ELLIOTT BADDER, MD; LUIS QUERAL, MD; AND PAUL R. LUCAS, MD

Renal artery aneurysms (RAAs), which were once considered uncommon, are now being diagnosed with increasing frequency with the routine use of computed tomography (CT), magnetic resonance imaging, ultrasonography, as well as angiography. Traditionally, RAA has been treated with open aneurysmectomy with revascularization. In this article, we report a successful endovascular treatment of a 2-cm RAA in a 74-year-old woman as a safe and effective alternative treatment method.

CASE REPORT

A 74-year-old woman with a medical history significant for hypertension, dyslipidemia, hypothyroidism, and hysterectomy was referred to a urologist with complaints of bilateral flank pain, greater on the left, for the previous 2 months. Physical examination was significant for tenderness in her left flank, especially with percussion. A CT scan showed a left RAA measuring 2 cm (Figure 1). This was followed up with a diagnostic arteriogram that confirmed a saccular aneurysm in the distal left main renal artery (Figure 2). Both open and endovascular treatment options were offered to her after presenting the CT and arteriographic findings. She agreed to proceed with endovascular treatment of her RAA.

The patient was brought to the operating room and was placed supine on the table. After IV sedation was administered, her left common femoral artery (CFA) was accessed under fluoroscopic guidance, and a 0.035-inch Glidewire (Terumo Interventional Systems, Somerset, NJ) was inserted into the abdominal aorta. A pigtail catheter (Cordis Corporation, Bridgewater, NJ) was then used to perform a focal aortography to identify the left renal ostium. Five thousand units of IV

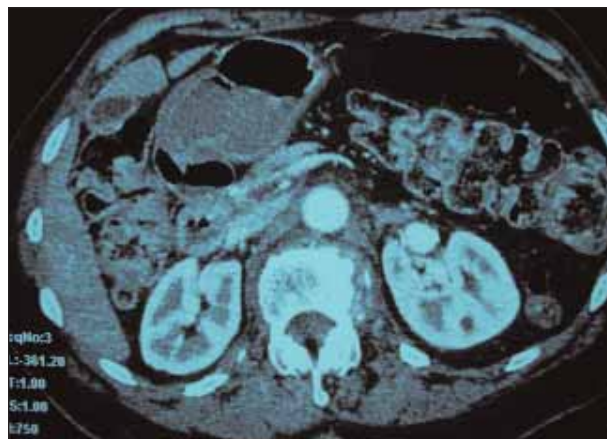


Figure 1. Contrast-enhanced CT scan depicting the left RAA.

heparin was then administered. A long 6-F sheath was placed, and the left renal artery was cannulated using the 0.035-inch Glidewire through an angled taper Glidecath (Terumo Interventional Systems). A selective angiogram delineated that the saccular aneurysm was confined to the main renal artery distally, unaffected by the first-degree branch points. Therefore, a microcatheter was passed into the aneurysm, and coil embolization was performed using three 7/3 Tornado embolization coils (Cook Medical, Bloomington, IN). A 6- X 18-mm Genesis stent (Cordis Corporation) was deployed, isolating the aneurysm as well as securing the previously placed coils. Several more coils were then placed into the aneurysm sac after recannulating the sac through the stent struts. A completion angiogram showed persistent filling of the aneurysmal sac (Figure 3). Protamine was administered to partially reverse the effect of heparin at the conclusion of the procedure. The patient tolerated the procedure well

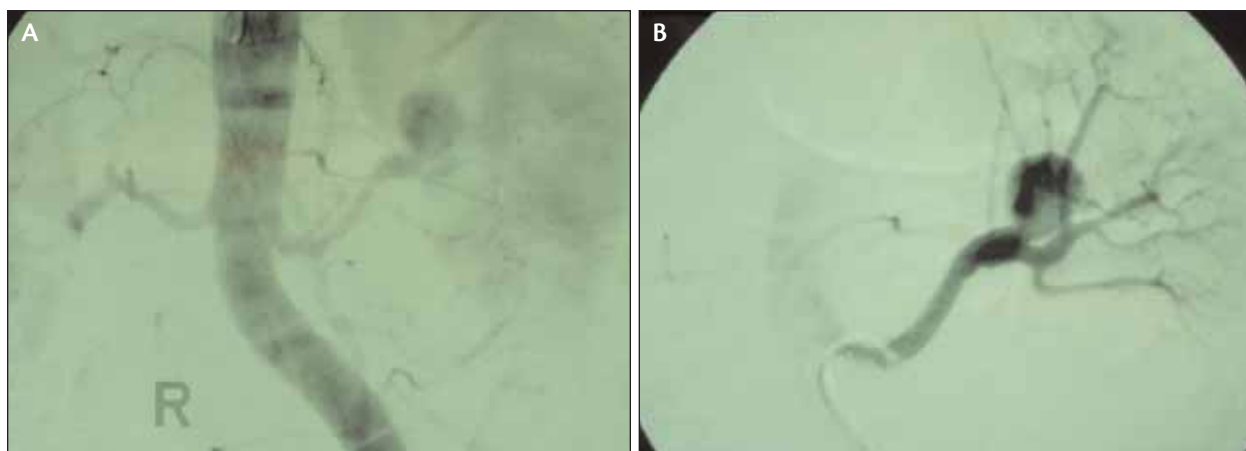


Figure 2. Diagnostic angiogram showing the 2-cm saccular aneurysm (A). A selective left renal artery study delineating the saccular aneurysm in proximity to the renal hilum near the primary branch point (B).

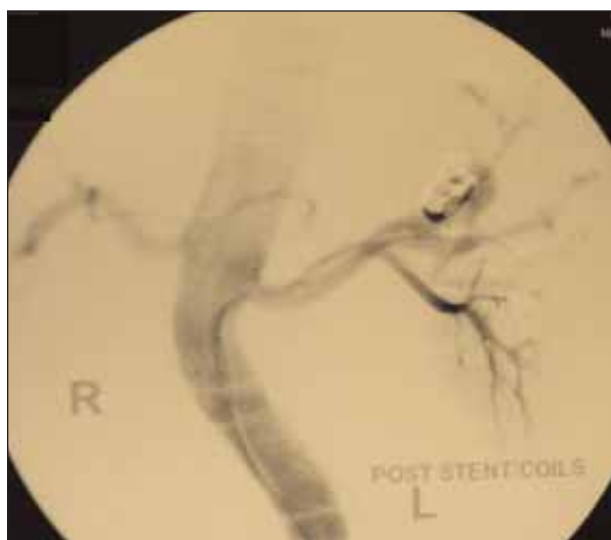

Figure 3. Completion angiogram. The coils and stent are present, and there remains some filling of the aneurysm sac.

and was transferred to the recovery room in stable condition. She was discharged home the next day on clopidogrel.

The patient was seen in follow-up 2 weeks after the procedure and had a significant improvement in the flank pain she originally presented with. Duplex ultrasound was performed, which showed a widely patent left renal artery and stent, with no flow in the aneurysm sac (Figure 4). She has since had follow-up CT scans that show patency of the left renal artery and stent, presence of the coils, and no flow into the sac. This, however, was difficult to ascertain due to significant scatter artifact from the coils (Figure 5). The patient has been completely free of pain since her initial post-operative visit.

DISCUSSION

RAAs are uncommon, with an incidence rate of 0.01% on autopsy report¹ to up to 0.3% to 1% in selected patients undergoing arteriography.² They can be categorized as true, false, or intrarenal aneurysms with a wide spectrum of etiologic factors, the most common of which is fibromuscular dysplasia (FMD).³ True RAAs occur in approximately 0.09% of the general population. Their incidence is 1.2 times greater in women versus men, attributed to a higher incidence of FMD in women. Renal artery bifurcations are the common sites of aneurysms. In general, they are saccular with an average diameter of 1.5 cm. The vast majority develops outside of the renal parenchyma mainly at first- or second-order branch points off of the main renal artery.⁴

The exact cause of RAAs is at times ambiguous, although they may be congenital and have been associated with FMD. These aneurysms may clinically manifest themselves through flank or abdominal pain, as well as hypertension, hematuria, collecting system obstruction, renal infarction, or rarely, rupture. Most RAAs are silent and found only incidentally during investigation for other intra-abdominal pathologies. Symptoms arise when aneurysms are large enough to press on neighboring structures or when thrombus embolizes to the kidneys, which may lead to infarction or rupture.⁵

Acceptable indications for surgical intervention for RAAs include symptomatic RAAs (patients with hypertension, pain, and renal ischemia), RAAs in women who are pregnant or planning to be, RAA diameter 2 cm or greater, those with rapid growth, and RAAs associated with acute dissection.^{6,7} Emergent intervention occurs with the most significant complication of these aneurysms, which is rupture. RAA rupture carries a 10% mortality rate in the nonpregnant population.² In

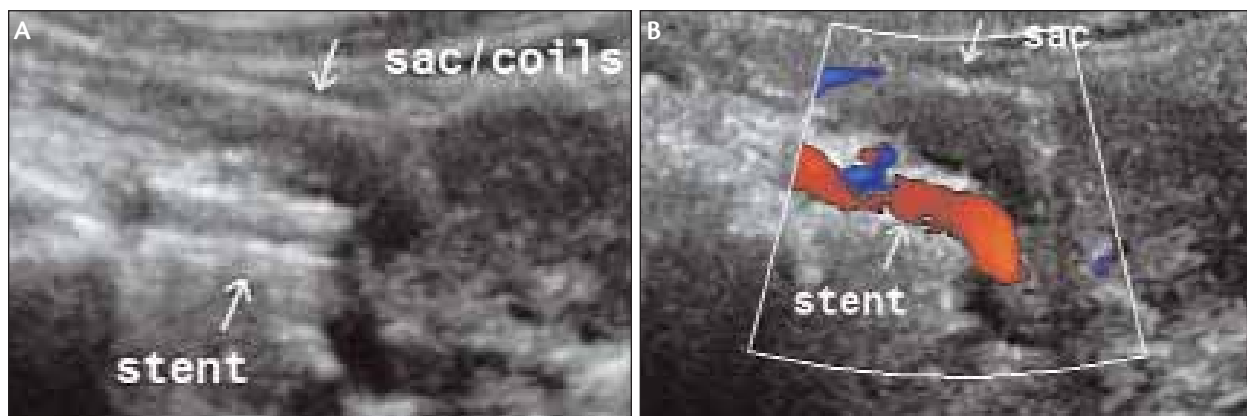


Figure 4. Duplex ultrasound without (A) and with (B) color flow showing patency of the left renal artery stent and no flow into the aneurysm sac.

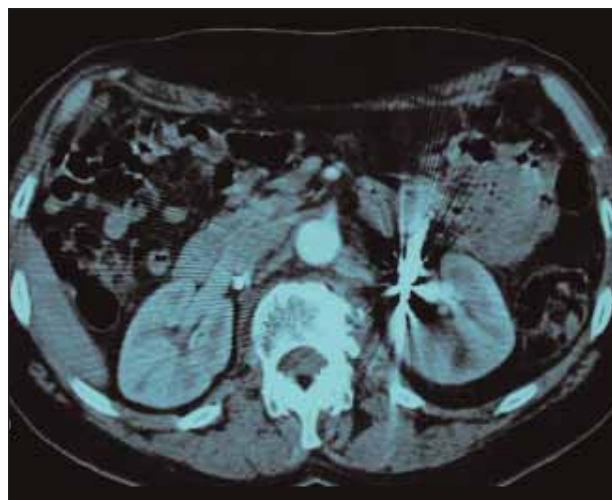

Figure 5. Contrast-enhanced CT scan showing the scatter artifact produced by the present coils within the sac. This limits adequate visualization of the renal artery.

pregnant women, the mortality rates for mother and fetus after rupture are 55% and 85%, respectively.⁵

The optimal repair method of RAAs remains controversial. There are multiple options for intervention. With surgical repair, the site of the aneurysm usually dictates the strategy. Aneurysmectomy with patch angioplasty or excision with end-to-end anastomosis may be utilized for treating more proximal aneurysms of the renal artery. Prosthetic bypass grafts are generally used to repair mid or distal renal artery aneurysms. Autotransplantation is also an option. Aneurysms within the parenchyma usually require nephrectomy.^{5,8}

The morbidity and mortality rates associated with surgical interventions are 12% and 1.6%, respectively.⁹ Therefore, in recent years, there has been an effort to perform more less-invasive therapeutic interventions to

address RAAs. Multiple case reports have documented successful interventions using endovascular embolization and/or endograft stenting to repair renal artery aneurysms.^{7,9} In our case, we were able to combine both embolization and placement of a stent to successfully treat a distal saccular RAA that allowed for continued perfusion of the kidney.

The evolution seen in endovascular abdominal aortic aneurysm repair has extended its concept to repair other aneurysms including RAAs. Several case studies have been published with technical success. As it is with the case presented in this article, most investigators utilize coils, stents, or stent grafts. Initial hesitation to treat only the saccular RAAs with narrow necks has diminished, and now we are able to treat RAAs with wide necks or those that are fusiform in nature.¹⁰

Although awaiting long-term results, the technical feasibility and initial successes appear promising and will further increase with advances in endovascular technique and applied instruments. Although traditional open repair remains the gold standard, endovascular treatment of an RAA using coil embolization and stent placement should be considered as a safe and effective alternative treatment modality. ■

Kak Rae Kim, MD, is an attending vascular surgeon with New York Hospital, Queens, and a member of the New York-Presbyterian Healthcare System, Weill Medical College of Cornell University. He has disclosed that he holds no financial interest in any product or manufacturer mentioned herein. Dr. Kim may be reached at krkurtiskim@gmail.com.

Hamid Zahiri, DO, is a resident in general surgery at the University of Maryland in Baltimore, Maryland. He has disclosed that he holds no financial interest in any product or manufacturer mentioned herein.

Jian Cai, RVT, is Technical Director of the Mercy Vascular Laboratory, Mercy Medical Center in Baltimore, Maryland. He has disclosed that he holds no financial interest in any product or manufacturer mentioned herein. Mr. Cai may be reached at jcai@mdmercy.com.

Richard Wilkerson, MD, is an attending vascular surgeon at Mercy Medical Center in Baltimore, Maryland. He has disclosed that he holds no financial interest in any product or manufacturer mentioned herein. Dr. Wilkerson may be reached at rwilkerson@vassurg.com.

Elliott Badder, MD, is an attending vascular surgeon at Mercy Medical Center in Baltimore, Maryland. He has disclosed that he holds no financial interest in any product or manufacturer mentioned herein. Dr. Badder may be reached at ebadder@vassurg.com.

Luis Queral, MD, is an attending vascular surgeon at Mercy Medical Center in Baltimore, Maryland. He has disclosed that he holds no financial interest in any product or manufacturer mentioned herein. Dr. Queral may be reached at luisqueral@yahoo.es.*

Paul R. Lucas, MD, is an attending vascular surgeon at Mercy Medical Center in Baltimore, Maryland. He has

disclosed that he holds no financial interest in any product or manufacturer mentioned herein. Dr. Lucas may be reached at prlucas@vassurg.com.

**Former affiliate.*

1. Seppala FE, Levey J. Renal artery aneurysm: case report of a ruptured calcified renal artery aneurysm. *Am Surg.* 1982;48:42-44.
2. Tham G, Ekelund L, Herrlin K, et al. Renal artery aneurysms. Natural history and prognosis. *Ann Surg.* 1983;197:348-352.
3. Cinat M, Yoon P, Wilson SE. Management of renal artery aneurysms. *Semin Vasc Surg.* 1996;9:236-244.
4. Calligaro KD, Dougherty MJ. In Rutherford RB, ed. *Vascular Surgery*. 6th ed. Philadelphia, Pa: WB Saunders;1861-1870.
5. Stanley JC, Gilbert Jr RU, Henke PK. Renal Artery Occlusive and Aneurysmal Disease. In: *Greenfield's Surgery*. Lippincott Williams & Wilkins; 2006:1747-1771.
6. Martin RS 3rd, Meacham PW, Ditesheim JA, et al. Renal artery aneurysm: selective treatment for hypertension and prevention of rupture. *J Vasc Surg.* 1989;9:26-34.
7. Bui BT, Oliva VL, Leclerc G, et al. Renal artery aneurysm: treatment with percutaneous placement of a stent graft. *Radiology.* 1995;195:181-182.
8. Pulli R, Dorigo W, Troisi N, et al. Surgical treatment of visceral artery aneurysms: a 25-year experience. *J Vasc Surg.* 2008;48:334-342.
9. Andersen PE, Rohr N. Endovascular exclusion of renal artery aneurysm. *Cardiovasc Interv Radiol.* 2005;28:665-667.
10. Clark TW, Sankin A, Becske T, et al. Stent-assisted Guglielmi detachable coil repair of wide-necked renal artery aneurysm using three-dimensional angiography. *Vasc Endovasc Surg.* 2008;41:528-532.