

# Dissociation and Removal of a Carotid Thrombus

A discussion of this minimally invasive technique and a comprehensive literature review of the different options for the treatment of a carotid thrombus.

**BY EMAD KANDIL, MD; AHMED SAWAS, MD; PRESLEY SWANN, MD; GARY GWERTZMAN, MD;  
AND JONATHAN DEITCH, MD**

**T**he AngioJet Rheolytic Thrombectomy System (Possis Medical Inc., Minneapolis, MN) is designed to remove a thrombus with the Venturi-Bernoulli effect. It introduces multiple saline jets at high velocity and high pressure through orifices in the distal tip of a catheter. These jets create a low-pressure zone, which results in a vacuum effect. This results in the dissociation and removal of bulky thrombi.<sup>1</sup>

There are many methods to remove thrombi; some are pharmacologic, and others are mechanical. Thrombolytic agents can play an important role in thrombus prevention and treatment. However, it is

reported that thrombolytic agents can cause distal embolization when used to treat large thrombus volumes, as encountered in common carotid artery (CCA) thrombosis.<sup>2</sup> Moreover, thrombolytic agents are contraindicated in certain situations. For example, if they are not administered within a specific time window after the onset of stroke symptoms, the benefits of reperfusion are undermined by the risks of cerebral hemorrhage.<sup>3</sup> Using a mechanical method to clear a thrombosed CCA can have a very effective role as long as it does not cause distal embolization. Distal embolization makes any procedure to re-establishing the patency of a CCA a technical challenge. Currently,

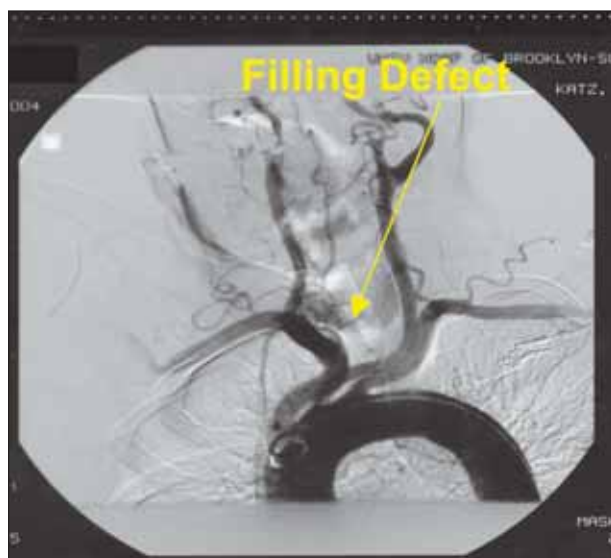


Figure 1. Preoperative angiogram showing a filling defect of the distal right CCA.

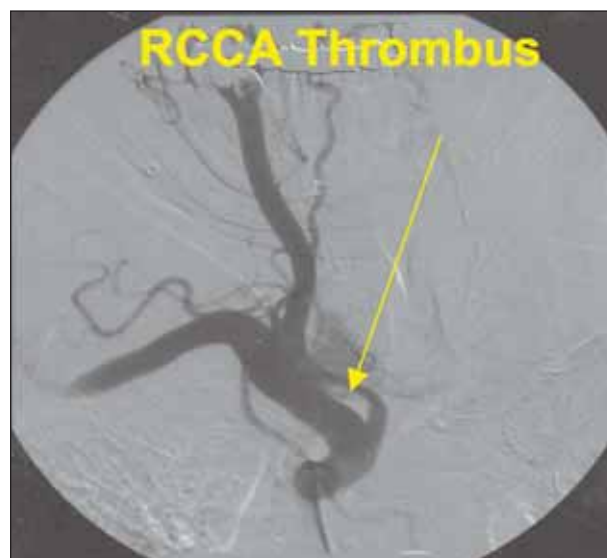
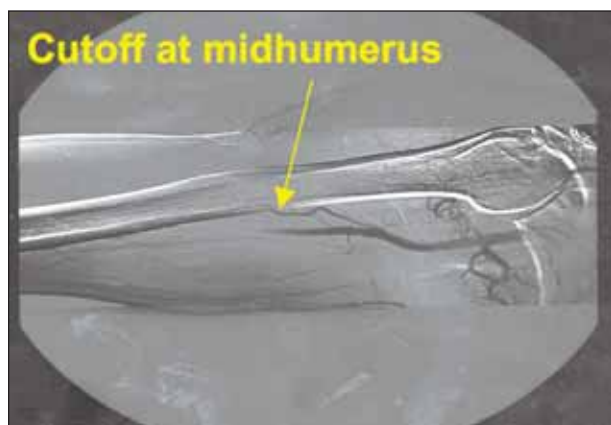


Figure 2. Preoperative angiogram showing a thrombus at the origin of the right CCA.



**Figure 3.** Preoperative angiogram showing occlusion of the right brachial artery.

there are no widely accepted mechanical techniques for the removal of a large thrombus volume in CCAs.<sup>4</sup>

Rheolytic thrombectomy with a commercially available device, the Possis AngioJet, has been used for thrombus removal in many vascular structures. It has been used for thrombus removal in peripheral circulation (arterial and venous),<sup>5-7</sup> the coronary system,<sup>8,9</sup> clotted dialysis fistula grafts,<sup>10</sup> and cases of dural sinus thrombosis.<sup>11,12</sup> In this case report, we demonstrate the use of the AngioJet system in re-establishing the patency of an acutely occluded right internal carotid artery (ICA). To our knowledge, this is the first case report in which this system was used with a successful clinical outcome and improvement of the preexisting clinical condition.

## CASE REPORT

A 72-year-old right-handed man presented to the emergency department with right-hand discomfort of 2-month duration, which progressed to pain and numbness over 48 hours.

The patient had mild hypertension, was diagnosed with prostate cancer 5 years earlier, and had a history of alcohol abuse. The patient did not have any history of trauma, smoking, diabetes, or coronary artery disease.

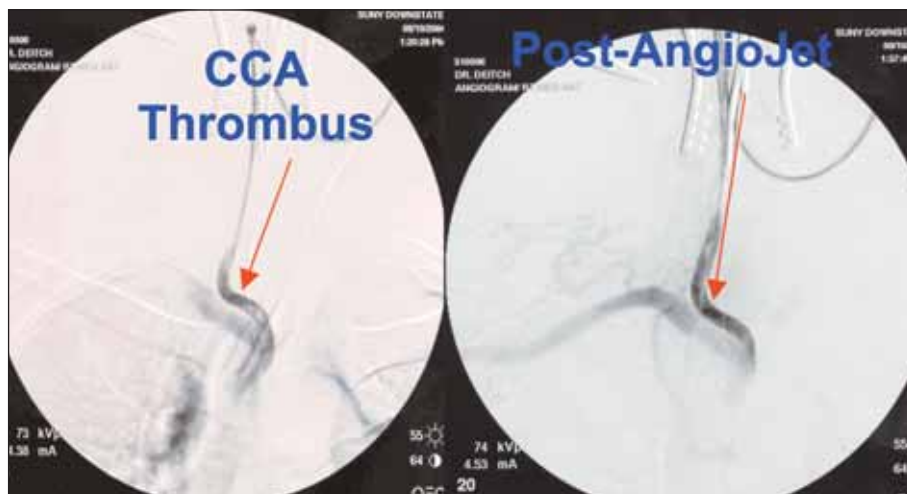
On physical exam, the patient's blood pressure was 150/70 mm Hg bilaterally. The patient had normal

carotid pulses bilaterally without bruits. The patient had normal left axillary, brachial, radial, and ulnar pulses, and had normal right axillary and high brachial pulses. The patient's lower right brachial and wrist pulses were absent. The patient's right hand was warm but painful and slightly cyanotic. The remainder of the vascular exam was unremarkable. The patient had intact motor functions and sensation.

An EKG showed normal sinus rhythm with a heart rate of 60 beats per minute. A Doppler study showed no vascular flow at the wrist or the hand. A duplex Doppler study confirmed a right brachial artery occlusion at the midhumerus and an extensive clot in both right radial and ulnar arteries. In addition, the study yielded soft echoes (indicative of an acute thrombus) just past the origin of the right CCA. The study did not indicate any axillary, subclavian, or distal innominate aneurysm, stenosis, or thrombus.

The patient received heparin and underwent selective aortic arch angiography while he was under general anesthesia. General anesthesia was used because of the decision to use an open exploration approach to the carotid vessels. The angiogram revealed a filling defect just distal to the origin of the right CCA (Figure 1), confirming the presence of a thrombus (Figure 2). The study also revealed a filling cutoff defect of the right brachial artery at the level of the midhumerus. This confirmed that the right brachial artery was occluded (Figure 3).

While the patient was under general anesthesia, intraoperative transesophageal echocardiography was performed; this showed no mural thrombus in the ventricles or in the left atrial appendage. Furthermore, there were no motion abnormalities, no valve abnormalities, no patent foramen ovale on microbubble study, and a good ejection fraction.



**Figure 4.** The right CCA, pre- and post-AngioJet, shows a patent right ICA.

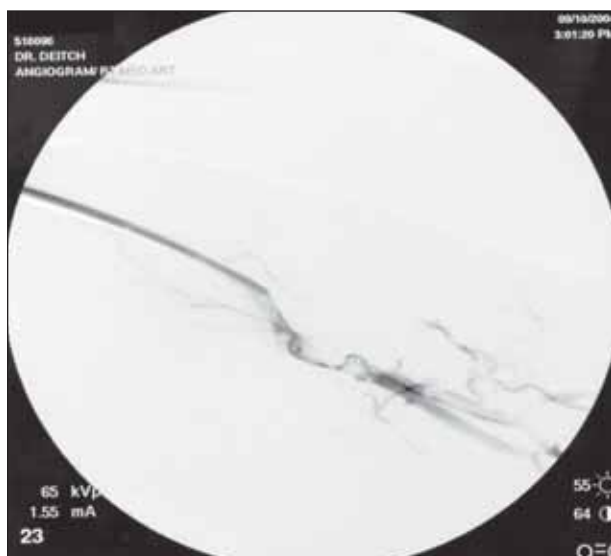


Figure 5. Pre-AngioJet angiogram of the right upper extremity via brachial cutdown.

The clot began approximately 3 cm distal to the origin of the ICA and extended for 2 cm. The possibility of causing the clot to migrate was a concern with using the standard embolectomy technique. The operation began by a cutdown of the right cervical carotid artery, and the right CCA was clamped distally. A 6-F Envoy MPC guide catheter (Cordis Corporation, Warren, NJ) was introduced via retrograde puncture into the right ICA. At this point, a retrograde angiogram confirmed the presence of the clot and its location. A 5-F Possis AngioJet catheter was passed through the guide

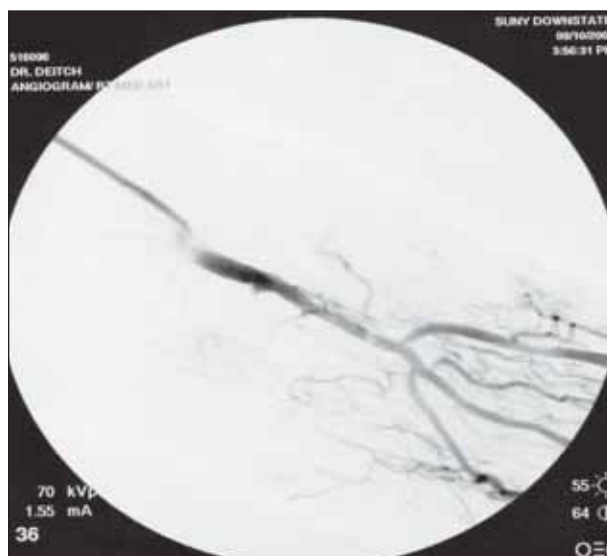

Figure 6. Post-AngioJet angiogram: patent right brachial artery.

catheter. The device was advanced over a Transend EX .014-inch microguidewire (Boston Scientific Corporation, Natick, MA) up to the level of the thrombus, while thrombectomy was performed during a period of a few minutes. Slow to-and-fro movements in the CCA and ICA were performed with the device engaged to promote thrombolysis. This was repeated over a period of 10 minutes, and these maneuvers were successful in the removal of the clot. The introducer was removed and flushed into the external carotid artery before unclamping the ICA. A completion angiography revealed a patent right ICA and a patent right CCA with no filling defects (Figure 4).

The operation continued by a cutdown on the right brachial artery at the midhumerus level. A right upper extremity angiography was performed via a brachial cutdown (Figure 5). The local acute thrombus was removed. A 6-F Envoy MPC guide catheter was introduced antegradely into the right brachial artery. A retrograde angiogram then confirmed the presence of the clot and its location. A 4-F Possis AngioJet catheter was passed through the guide catheter. The device was advanced over a Transend EX .014-inch microguidewire into the brachial, radial, and interosseous arteries. The AngioJet was used as described with successful removal of the thrombus. The patency of the vessels was confirmed by angiography after the AngioJet was removed (Figures 6 and 7). Finally, the right brachial artery was closed with a vein patch.

Postoperatively, the patient was neurologically intact, with complete resolution of pain and numbness of the

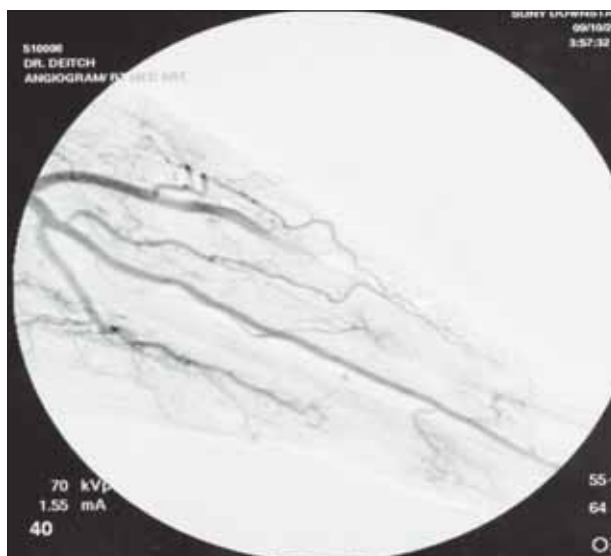

Figure 7. Post-AngioJet angiogram: patent right radial and interosseous arteries.

right hand. The patient was continued on heparin. The patient was investigated for primary and secondary hypercoagulable disorders, all of which were negative. The patient was then maintained on warfarin. At the time of discharge, the patient had palpable pulses, was feeling well, and had very little right-hand discomfort.

"Our greatest concern was that manipulation of a large thrombus would result in its fragmentation and production of distal embolization."

## DISCUSSION

This patient had an incidental finding of a carotid thrombus. This is very rare; for example, one study detected it in 29 of 200 angiographic studies performed in the setting of ischemic cerebral symptoms.<sup>13,14</sup>

There are no published, agreed-upon guidelines for the management of carotid thrombus. However, most interventionists would consider such a condition an emergency and recommend initiating anticoagulation therapy immediately after diagnosis. However, because of our patient's symptoms, we had to consider emergent surgical intervention.

Our greatest concern was that manipulation of a large thrombus would result in its fragmentation and production of distal embolization. The AngioJet system provided a minimally invasive and quick method to avoid significant complications presented by traditional surgical interventions. Complications of opening the carotid artery, such as manipulation of the vagus and hypoglossal nerve, were avoided with the dissection. The suture line of opening a carotid artery can bleed, and a patch, if used, can become infected. A recent pilot study of 16 patients promoted the application of outflow protection filters as a safe, feasible, and efficacious method to prevent distal embolization complications and as a safeguard for the distal capillary bed.<sup>15</sup>

In conclusion, this report describes the feasibility of AngioJet as a minimally invasive technique to safely remove a symptom-free thrombus floating in the carotid arteries. ■

*Emad Kandil, MD, is with the Tulane School of Medicine. He has disclosed that he holds no financial interest in any product or manufacturer mentioned herein. Dr. Kandil may be reached at (504) 988-5187; ekandil@tulane.edu.*

*Ahmed Sawas, MD, is with the Department of Surgery, State University of New York: Downstate Medical Center,*

*in Brooklyn, New York. He has disclosed that he holds no financial interest in any product or manufacturer mentioned herein. Dr. Sawas may be reached at (718) 270-1421.*

*Presley Swann, MD, is with the Tulane School of Medicine. He has disclosed that he holds no financial interest in any product or manufacturer mentioned herein. Dr. Swann may be reached at (504) 988-5187; rswann@tulane.edu.*

*Jonathan Deitch, MD, is with the Department of Surgery, State University of New York: Downstate Medical Center, in Brooklyn, New York. He has disclosed that he holds no financial interest in any product or manufacturer mentioned herein. Dr. Deitch may be reached at (718) 270-1421.*

*Gary Gwertzman, MD, is with the Department of Surgery, State University of New York: Downstate Medical Center, in Brooklyn, New York. He has disclosed that he holds no financial interest in any product or manufacturer mentioned herein. Dr. Gwertzman may be reached at (718) 270-1421.*

1. Lee MS, Singh V, Wilentz JR, et al. AngioJet thrombectomy. *J Invas Cardiol*. 2004;16:587-591.
2. Trouillas P, Nighoghossian N, Derex L, et al. Thrombolysis with intravenous rtPA in a series of 100 cases of acute carotid territory stroke. Determination of etiological, topographical and radiological outcome factors. *Stroke*. 1998;29:2529-2540.
3. Hill M, Hachinski V. Stroke treatment: time is brain. *Lancet*. 1998;352(suppl III):10-14.
4. Bellon RJ, Putman CM, Budzik RF, et al. Rheolytic thrombectomy of the occluded internal carotid artery in the setting of acute ischemic stroke. *Am J Neuroradiol*. 2001;22:526-530.
5. Silva JA, Ramee SR, Collins TJ, et al. Rheolytic thrombectomy in the treatment of acute limb-threatening ischemia: immediate results and six-month follow-up of the multicenter AngioJet registry: Possis Peripheral AngioJet Study AngioJet Investigators. *Cathet Cardiovasc Diagn*. 1998;45:386-393.
6. Mathie AG, Bell SD, Saibil EA. Mechanical thromboembolism in acute embolic peripheral arterial occlusions with use of AngioJet Rapid Thrombectomy System. *J Vasc Interv Radiol*. 1999;10:583-590.
7. Dick A, Neuerburg J, Schmidt-Rode T, et al. Stenting after thrombectomy with the AngioJet catheter for acute myocardial infarction. *Cathet Cardiovasc Diagn*. 1998;33:91-97.
8. Nakagawa Y, Matsuo S, Yokoi H, et al. Stenting after thrombectomy with AngioJet catheter for acute myocardial infarction. *Cathet Cardiovasc Diagn*. 1998;43:327-330.
9. Nakagawa Y, Matsuo S, Kimura T, et al. Thrombectomy with AngioJet catheter in native coronary arteries for patients with acute or recent myocardial infarction. *Am J Cardiol*. 1999;83:994-999.
10. Vesely TM, William D, Weiss M, et al. Comparison of the angiojet rheolytic catheter to surgical thrombectomy for the treatment of thrombosed hemodialysis grafts: peripheral AngioJet Clinical Trial. *J Vasc Interv Radiol*. 1999;10:1195-1205.
11. Opatowsky MJ, Morris PP, Regan JD, et al. Rapid thrombectomy of superior sagittal sinus and transverse sinus thrombosis with a rheolytic catheter device. *Am J Neuroradiol*. 1999;20:414-417.
12. Scarrow AM, Williams RL, Jungreis CA, et al. Removal of a thrombus from sigmoid and transverse sinuses with a rheolytic thrombectomy catheter. *Am J Neuroradiol*. 1999;20:1467-1469.
13. Buchan A, Gates P, Pelz D, et al. Intraluminal thrombus in the cerebral circulation. Implications for surgical management. *Stroke*. 1988;19:681-687.
14. Biller J, Adams HP Jr, Boarini D, et al. Intraluminal clot of the carotid artery. A clinical-angiographic correlation of nine patients and literature review. *Surg Neurol*. 1986;25:467-477.
15. Siablis D, Karnabatidis D, Katsanos K, et al. Outflow protection filters during percutaneous recanalization of lower extremities' arterial occlusions: a pilot study. *Eur J Radiol*. 2005;55:243-249.