

Ischemic Limb Complications in the ICU

How to recognize and manage the risk factors and complications that can lead to limb ischemia in hospitalized patients.

BY DAVID L. DAWSON, MD

Acute limb ischemia (ALI) affects an estimated 14 out of 100,000 people in the general population, which may comprise 10% to 16% of the workload in a peripheral vascular practice. Patients presenting with ALI have poor short-term outcomes, both in terms of limb loss and mortality, with 30-day amputation rates between 10% and 30%, and a mortality rate stable at approximately 15%. Mortality rates after intervention for ALI have remained relatively stable during the past 2 decades, and this is thought to reflect the severity of the comorbidities of these high-risk patients.^{1,2} Although cardiogenic emboli are less common with the increased use of anticoagulation and the decrease in rheumatic heart disease, thrombotic causes of ALI are more common. The overall ALI incidence, thus, is relatively stable.³

Complications of ALI, when they occur in severely ill, hospitalized patients, may be particularly difficult to handle. Limb-threatening ischemia can be the result of iatrogenic injury, thrombotic complications, or hypoperfusion related to the underlying disease state. The patients at greatest risk for acute ischemia are those with underlying peripheral artery disease (PAD), but limb ischemia can also be the consequence of embolism, injury, dissection, or severe vasoconstriction, even in the absence of pre-existing occlusive disease.^{4,5}

The term ALI applies to new manifestations of limb ischemia and ischemic complications that arise during hospitalizations. ALI is graded on the severity of ischemia. The urgency and nature of the management will depend on the clinical findings (Table 1).^{4,6} Grade I acute ischemia, with coolness, mottling, or other manifesta-

tions of ischemia without pain or neurologic deficit, may be observed or managed with anticoagulation alone. Management of some cases of grade II acute ischemia can be delayed if pain is controlled and peripheral nerve symptoms are limited to sensory loss or paresthesias. Severe symptoms or a motor deficit suggests a revascularization is required within a few hours to prevent irretrievable injury. With grade III acute ischemia, the ischemic injury is of such sufficient severity or duration that irreversible tissue injury results. Amputation will be required. If there is extensive muscle infarction or skin necrosis, there is no value and there may be significant harm with attempts at revascularization.⁷

PRE-EXISTING PAD

The primary risk factor for ischemic limb complications during hospitalization is the presence of pre-existing PAD. Of course, PAD may exist without recognized symptoms. It has been estimated that approximately 50% of patients with clinically detectable PAD may not have distinct symptoms, such as claudication.⁸ With or without symptoms, PAD is often unrecognized by primary care providers.⁹ Unless admission history has been adequately thorough and the review systems have asked about functional ability and walking symptoms, even patients with moderately severe PAD may not be recognized as at risk.

Table 2 summarizes classes of chronic limb ischemia.^{4,10} Pre-existing PAD of any severity is relevant because all of these patients have a condition that predisposes them to vascular complications. For example, patients with poor limb perfusion may be at increased risk for skin break-

TABLE 1. CLINICAL CATEGORIES OF ACUTE LIMB ISCHEMIA

Category	Description/Prognosis	Sensory Loss	Muscle Weakness	Arterial Doppler Signals	Venous Doppler Signals
I Viable	Not immediately threatened	None	None	Audible	Audible
IIa Threatened marginally	Salvageable if promptly treated	Minimal (toes) or none	None	Often inaudible	Audible
IIb Threatened immediately	Salvageable with immediate revascularization	More than toes associated with rest pain	Mild, moderate	Usually inaudible	Audible
III Irreversible	Major tissue loss or permanent nerve damage	Profound, anesthetic	Profound paralysis (rigor)	Inaudible	Inaudible

TABLE 2. CLINICAL CATEGORIES OF CHRONIC LIMB ISCHEMIA

Grade	Category	Clinical Description	Objective Criteria
0	0	Asymptomatic: no hemodynamically significant occlusive disease	Normal treadmill or reactive hyperemia test
	1	Mild claudication	Completes treadmill exercise; AP after exercise >50 mm Hg but at least 20 mm Hg lower than resting value
I	2	Moderate claudication	Between categories 1 and 3
	3	Severe claudication	Cannot complete standard treadmill exercise and AP after exercise <50 mm Hg
II*	4	Ischemic rest pain	Resting AP <40 mm Hg, flat or barely pulsatile ankle or metatarsal PVR; TP <30 mm Hg
III*	5	Minor tissue loss: nonhealing ulcer, focal gangrene with diffuse pedal ischemia	Resting AP <60 mm Hg, ankle or metatarsal PVR flat or barely pulsatile; TP <40 mm Hg
	6	Major tissue loss: extending above TM level, functional foot no longer salvageable	Same as category 5

AP=ankle pressure; PVR=pulse volume recording; TP=toe pressure; TM=transmetatarsal.

*Grades II and III, categories 4, 5, and 6, are considered critical limb ischemia.

down when immobilized. Pressure ulcers may occur on the heels, or skin breakdown may be observed in other areas where pressure or shear forces have been applied. Otherwise innocuous medical devices, such as compression (antiembolism) stockings, pneumatic compression devices, dressings, or casts, may produce focal cutaneous necrosis if the skin perfusion is compromised. Further, limbs with circulatory impairment will have a decreased thermoregulatory ability and will be at risk for injury if active warming devices are used.

Thus, recognition of chronic PAD and the implication that a patient is at risk for acute ischemia is the first step. A diagnosis of chronic limb ischemia can be made with routine evaluations. The question, "How far can you walk?" in a review of systems is particularly useful, in addition to reviewing the medical history, which may include PAD risk

factors, a previous diagnosis of PAD, treatment with medicines for claudication symptoms (cilostazol or pentoxifylline), or a previous procedure for PAD. A complete pulse examination should be part of the documentation of the physical examination. For patients with an abnormal pulse examination, an ankle-brachial index (ABI) should be used and recorded.^{4,5,11}

VASCULAR PATIENTS

Hospitalized patients undergoing vascular procedures may be at the highest risk for developing acute ischemia. Access complications during arterial catheterization may result in dissection, thrombosis, or embolization. In addition to complications in patients undergoing intended arterial procedures, venous catheterization procedures can sometimes result in inadvertent arterial injury.

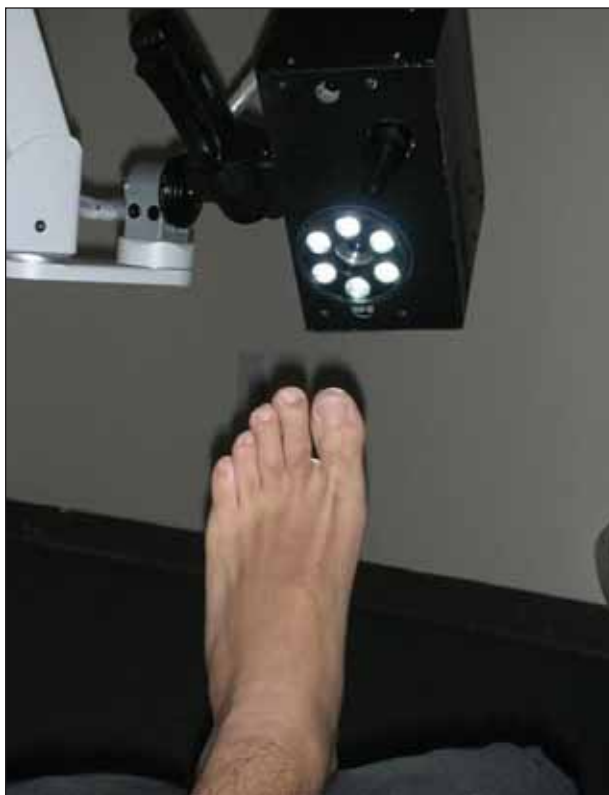

Figure 1. The hyperspectral system uses a digital camera with a spectral separator to vary the wavelength of light admitted. During image acquisition a set of images, each at a separate wavelength, is generated. The visible light spectrum for each pixel in the data set can be compared to standard spectra for oxyhemoglobin (OxyHb) and deoxyhemoglobin (DeoxyHb).

Routine use of ultrasound imaging to guide vascular access may reduce the risk of inadvertent arterial injury during venous procedures.

Large-vessel embolic occlusion may be a complication of heart disease, especially in the absence of adequate anticoagulation. Patients who had been anticoagulated for chronic atrial fibrillation may have their anticoagulation held during the course of an ICU hospitalization for procedures to be performed. Patients with new-onset atrial fibrillation may develop a thrombus within the left atrium or its appendage, which can embolize and cause acute large vessel occlusion.

A low-cardiac-output state or regional hypoperfusion could cause ischemic tissue injury. In particular, patients receiving vasopressors, especially those receiving high-dose pressor support, may have their blood pressure maintained by peripheral vasoconstriction, but at the expense of peripheral hypoperfusion. This may be a particularly severe problem for patients with sepsis. The use of pressors should be avoided unless there is adequate

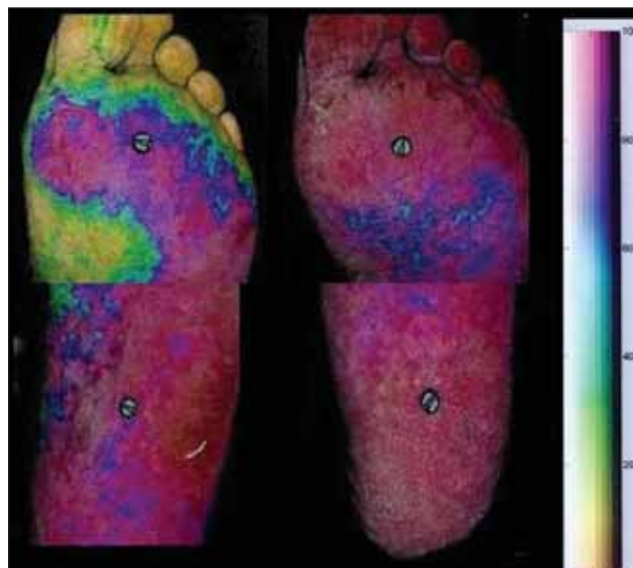


Figure 2. The mean values for OxyHb and DeoxyHb can be determined across a relatively large region of interest.

hemodynamic monitoring. Blood pressure is not the appropriate endpoint for assessing the adequacy of treatment—adequacy of perfusion is.

IMAGING AND DIAGNOSTIC STUDIES

For patients who are not critically ill, all routine imaging modalities can be considered when evaluating acute ischemia. For patients who are in the critical care unit, however, transportation for diagnostic studies may be problematic. MR angiography is less useful and may be less applicable in critically ill patients due to the inability to have certain medical devices with the patient in the area of the magnet. The diagnostic tools of the non-invasive vascular laboratory are often able to detect relevant problems.¹² The ABI and the toe pressures (using photoplethysmography) are particularly useful for providing an object of assessment of the general state of distal perfusion. Iatrogenic arterial problems can be detected with duplex ultrasound, including segments of vascular occlusion, stenosis from intimal flaps, or other manifestations of arterial injuries, such as puncture site pseudoaneurysm.

Pressure measurements, however, are surrogates for measurements of perfusion and tissue oxygen delivery. A new imaging technique (HyperMed, Waltham, MA), medical hyperspectral imaging (HSI), may provide additional useful information about oxygen delivery to the tissues (Figures 1 and 2).^{13,14} FDA approved for clinical use in 2006, HSI has the advantage of being able to assess regional oxygen delivery. HSI has been found useful in a variety of clinical applications and pilot studies that are

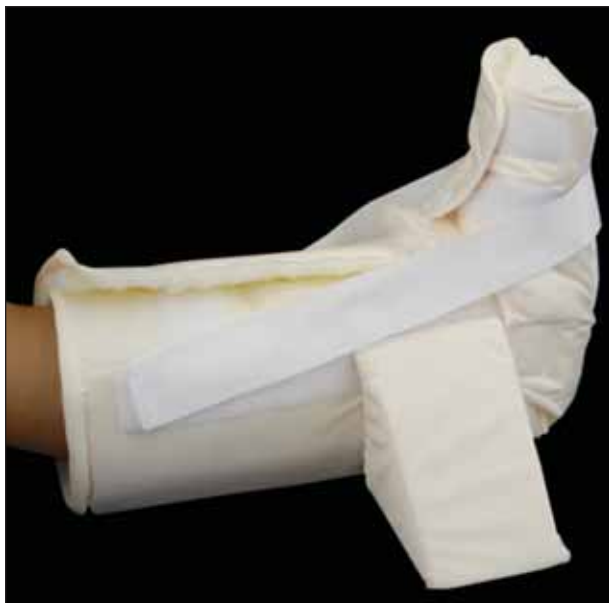

Figure 3. The Rooke boot is an example of a simple device that combines warming with a foam cradle for heel pressure relief. The resultant cutaneous vasodilatation can slightly increase foot $TcpO_2$ in ischemic limbs.

underway to assess a potential role for monitoring tissue oxygen delivery in the critical care setting.¹⁵ HSI is an intriguing new technology with a potential future role for the assessment of ALI.

INDIVIDUALIZED MANAGEMENT

Management of acute ischemia in a hospitalized patient is highly individualized. Anticoagulation is indicated with therapeutic doses of heparin for all patients with acute ischemia, unless there is active bleeding or an immediate bleeding risk.^{4,5,11,16} Simple devices, such as a Rooke boot (Osborn Medical Corporation, Utica, MN) (Figure 3), may help to prevent tissue injury from pressure and shear. Passive warming measures may also be beneficial¹⁷ because cold-induced vasospasm may exacerbate regional hypoperfusion, but active warming measures should be avoided because of the risk of thermal injury.

Procedural interventions can include a full range of surgical and endovascular therapy. Removal of an intravascular device or catheter is a simple intervention that may be beneficial. A large arterial sheath may partially or completely obstruct the lumen of a diseased access vessel, causing limb ischemia. Removal of the sheath may be sufficient to restore perfusion.

CASE 1

A 48-year-old woman with renal failure from lupus nephritis, who was managed with peritoneal dialysis,

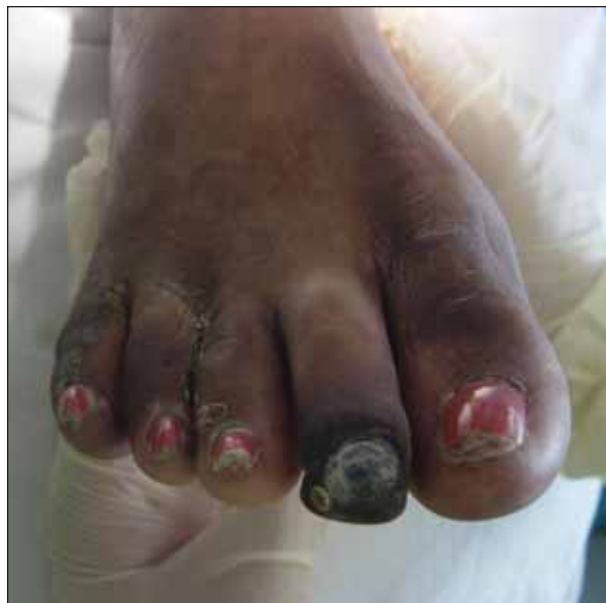

Figure 4. Late tissue loss limited to focal dry gangrene of the second toe and "kissing" ulcers between third, fourth, and fifth toes.

was admitted with septic shock from peritonitis. Her other chronic medical problems included coronary artery disease and hypertension.

Although septic in the intensive care unit, after several days of vasopressor support for hypotension, she was noted to have right forefoot mottling, and the toes became purple, with sluggish or absent capillary refill. Although peripheral perfusion improved with weaning off the pressors, she developed dry gangrene of the second toe and multiple areas of ulceration between the other toes.

During her 4-month hospitalization, she was immunosuppressed from corticosteroids and nutritionally depleted; she developed pressure sores, clostridium difficile colitis, pneumonia, adrenal insufficiency, and delirium. With demarcation of the ischemic injury and limited tissue loss in the right foot (Figure 4), consideration of amputation was delayed until after her acute problems had resolved.

With no palpable pulse distal to the femoral artery, she was evaluated with arteriography before surgical management was considered. Serial 50% stenoses of the mid and distal superficial femoral artery were found, as was a focal, high-grade midpopliteal artery stenosis (Figure 5). Percutaneous transluminal angioplasty of these lesions, including use of a peripheral Cutting Balloon (Boston Scientific Corporation, Natick, MA) for the calcified popliteal artery lesion (Figure 6), was performed before her limited forefoot amputation, which subsequently healed without complication.

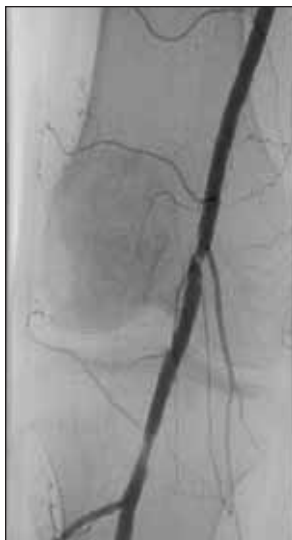

Figure 5. Focal stenosis of the popliteal artery.

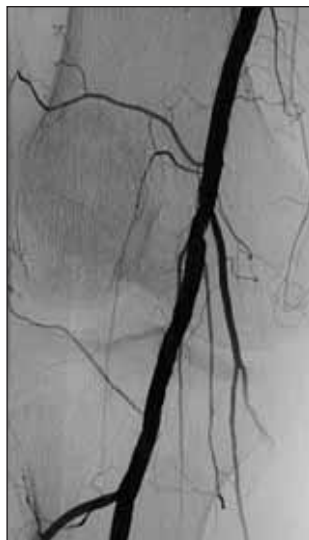

Figure 6. No residual stenosis after cutting-balloon angioplasty.

Key Points

- Compensated, moderately severe peripheral artery disease can be a risk factor for ischemic necrosis with sepsis, hypoperfusion, and use of peripheral vasoconstrictors.
- Progression of tissue loss may be avoided by weaning off vasopressors.
- Delay in management may be beneficial if ischemic tissue loss is limited and there is no infection.
- Endovascular therapy before limited amputation reduces risk of failure of primary wound healing.

CASE 2

A 75-year-old woman in the intensive care unit with aspiration pneumonitis was on her 82nd hospital day with persistent sepsis, respiratory failure, renal failure, and a need for dialysis access. She had severe anasarca. Her serum albumin was 1.7 g/dL, and she was more than 25 kg above her preadmission weight. In attempting to access the femoral vein with a 12-F dialysis catheter, the femoral artery was inadvertently cannulated.

Bedside evaluation with duplex ultrasound confirmed the arterial placement of the catheter (Figure 7) and showed no flow in the common femoral artery (Figure 8). Color-flow duplex could not detect flow in the superficial femoral artery, but low-amplitude monophasic flow was detected in the popliteal artery.

Because of her medical condition and concerns about the morbidity rate of operative femoral artery repair, she was not taken to the operating room for removal of the 12-F catheter. It was removed at the bedside, with hemostasis achieved by prolonged manual compression.

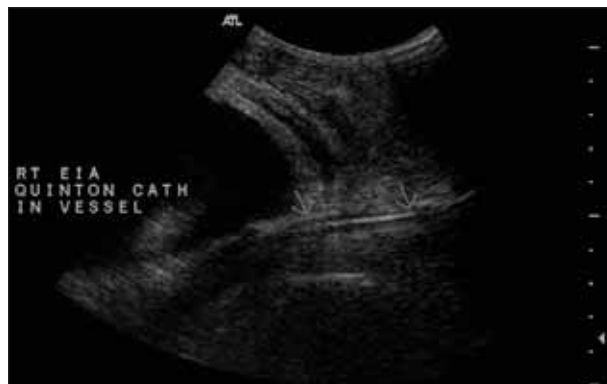

Figure 7. B-mode imaging shows the echogenic catheter within the external iliac artery.

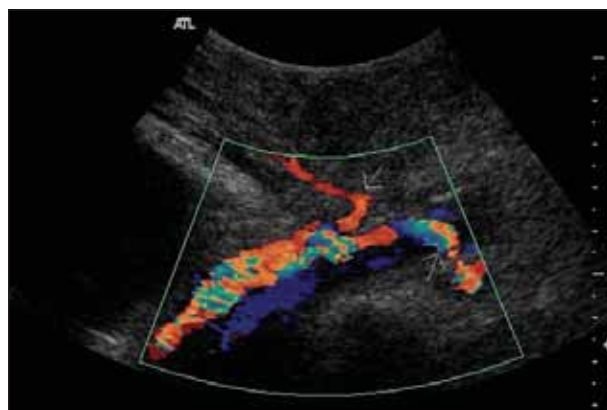


Figure 8. Color-flow Doppler imaging shows common femoral artery occlusion. Flow from the external iliac artery only goes into the inferior epigastric and circumflex iliac arteries.

Although Doppler-flow signals could not be detected at the ankle, the foot appeared viable. Motor function appeared intact. Heparin anticoagulation was initiated, and measures were taken to protect the foot from pressure and shear and to provide passive warming. Serial examination and regular measurements of her ABI found her foot to remain viable. During the next week, the ABI gradually rose to .9 (Figure 9). Also, a repeat duplex scan 3 days after the catheter was removed showed some restored flow in the femoral artery.

The limb remained viable, and she had no further vascular complications related to this episode. However, she remained chronically ventilator dependent.

Key Points

- Limb ischemia associated with an indwelling arterial cannula, especially a large-diameter device, may improve simply with removal of the device.
- Heparin anticoagulation is indicated for acute ischemia, and it may be sufficient therapy in selected cases if limb viability is not acutely threatened.

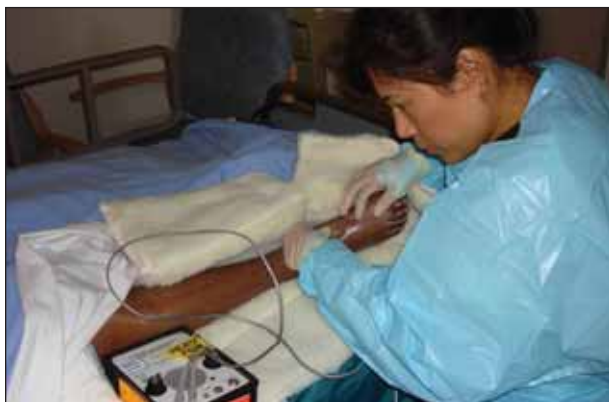

Figure 9. Doppler evaluation and measurement of ABIs should be part of the regular bedside assessment of perfusion in patients with chronic or acute limb ischemia.

- Bedside monitoring with ABI measurements is a simple and noninvasive means to assess the severity of ischemia and change in limb perfusion after procedures or other therapies.

CASE 3

Two days after undergoing percutaneous intervention for an ST-elevation myocardial infarction, a 74-year-old woman developed right foot pain, increasing numbness and sensory deficit, and minimal weakness. The 7-F arterial sheath remained in the right femoral artery. Doppler flow was undetectable at the level of the right foot.

She returned to the cardiac catheterization laboratory, and diagnostic arteriography demonstrated perisheath thrombus and near occlusion of the right external iliac artery. Also noted was chronic occlusion of the contralateral left external iliac artery and bilateral superficial femoral artery occlusions (Figure 10). Tissue plasminogen activator (tPA) was delivered through a 5-F multisided hole (AngioDynamics, Queensbury, NY). An infusion at 1 mg/h followed pulsed-spray delivery of a 5-mg tPA bolus to the segment. Follow-up angiography later the same day showed incomplete resolution of the obstruction. A small iliac artery dissection was also noted, presumably caused by an injury at the time of the arterial access (Figure 11). A residual stenosis remained after balloon angioplasty, so a self-expanding 8-mm X 40-mm stent was placed (Smart Control, Cordis Corporation, a Johnson & Johnson Company, Miami, FL) and postdilated to 7 mm with good angiographic results and improvement in extremity perfusion (Figure 12).

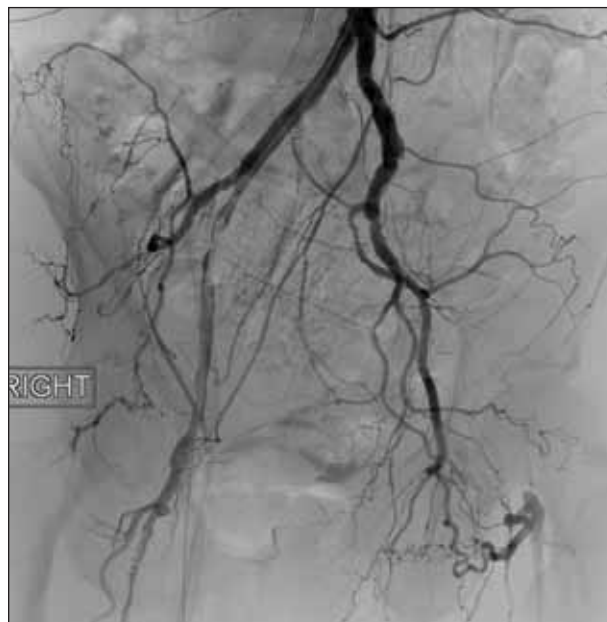

Figure 10. Near occlusion of the right external iliac artery with thrombus around the 7-F sheath.

Key Points

- Delayed removal of an arterial sheath in a patient with pre-existing occlusive disease risks ischemic complications.
- Progressive peripheral nerve dysfunction with ischemia indicates threatened limb viability and the need for urgent revascularization.
- Rapid thrombolysis and adjunctive endovascular techniques may restore flow and avoid the need for operative intervention.

CASE 4

A 46-year-old woman presented with ischemic pain

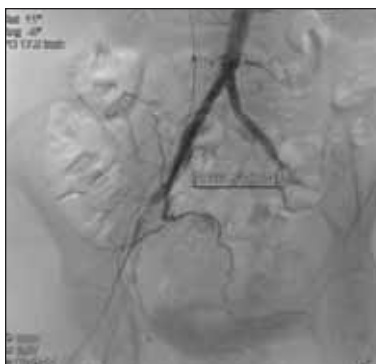

Figure 11. Residual narrowing and focal arterial dissection are found after thrombolysis.

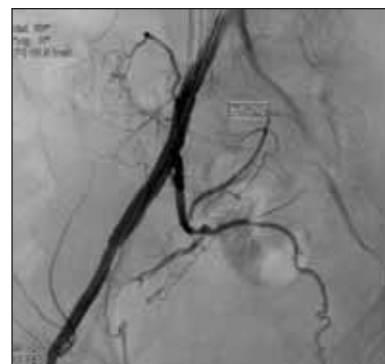

Figure 12. Angioplasty and stent placement resolved the residual stenosis after thrombolysis.

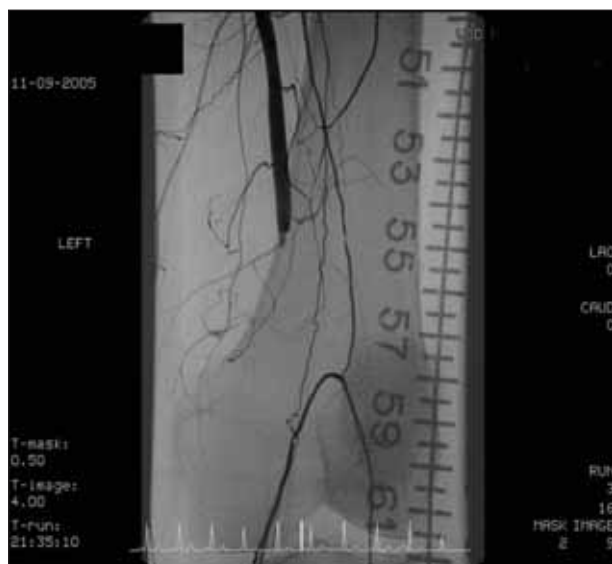


Figure 13. Occluded popliteal interposition vein graft.

and cyanosis of the left first toe. Evaluation showed severe popliteal artery narrowing (thought to be due to entrapment) and embolic occlusion of the anterior tibial artery. She was treated with an open repair of the popliteal artery via a posterior approach, but less than 24 hours after interposition vein graft replacement of the popliteal artery, her ischemic symptoms returned. She was evaluated with arteriography, which confirmed the clinical suspicion of graft occlusion, and endovascular therapy was elected (Figure 13).

From a contralateral femoral access, an 8-F, 55-cm Raabe sheath (Cook Medical, Bloomington, IN) was advanced across the bifurcation and positioned in the superficial femoral artery. Graft thrombolysis was performed with a 6-F AngioJet Xpeedior (Possis Medical, Inc., Minneapolis, MN) rheolytic thrombolysis catheter. Follow-up arteriography demonstrated an approximately 2-cm focal irregularity at the level of the adductor canal. The appearance was consistent with an atherosclerotic plaque that had been disrupted (Figure 14). A prolonged inflation of a 5-mm X 4-cm Ultrathin SDS angioplasty balloon (Boston Scientific Corporation) completely resolved the stenosis (Figure 15). After exchanging for a .014-inch guidewire, angioplasty of an irregularity and narrowing in the distal popliteal artery and tibioperoneal trunk was performed with a 3-cm X 40-mm Amphirion Deep angioplasty balloon (ev3, Inc., Plymouth, MN). Follow-up arteriography showed no residual stenosis. The patient was treated with short-term heparin anticoagulation and discharged on combined antiplatelet therapy with aspirin and clopidogrel.

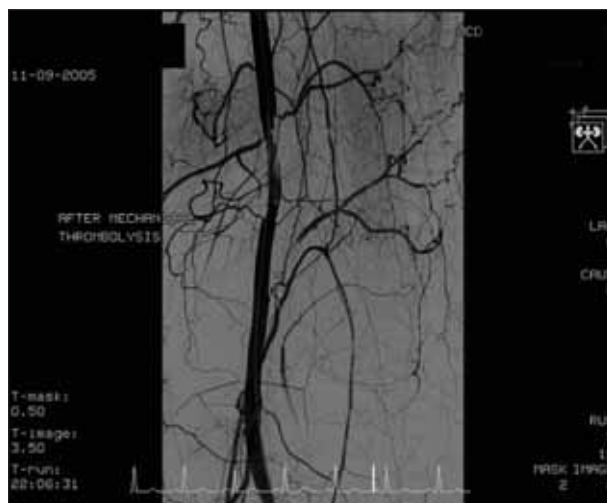


Figure 14. AngioJet thrombus removal cleared most of the thrombus from the occluded graft. A stenosis, either from residual thrombus or a disrupted plaque at the site of the proximal clamping, is noted.

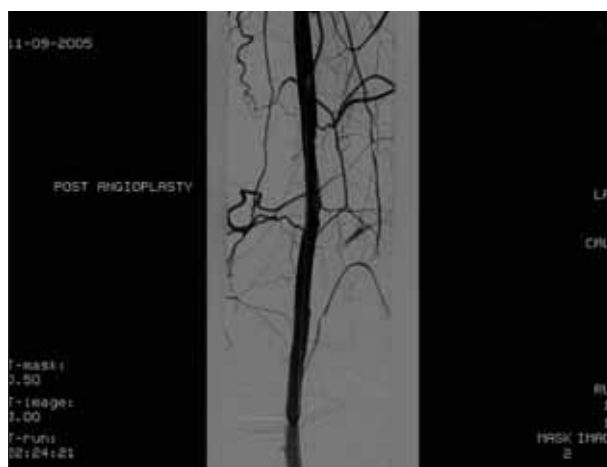


Figure 15. No residual narrowing after adjunctive balloon angioplasty.

Key Point

- Mechanical thrombectomy devices or thrombus aspiration techniques provide a nondrug alternative for patients with contraindications to pharmacologic thrombolysis, such as recent arterial surgery.

CONCLUSION

All types of surgical revascularization procedures have a potential role in managing patients with acute ischemia,¹⁸ but patients who are critically ill may be poorly suited for a major operation. Less-invasive choices (eg, extra-anatomic vs direct bypass or the use of prosthetic conduit rather than autologous vein graft) may shorten the duration of the procedure and reduce the physiologic insult.

TABLE 3. EVALUATION AND TREATMENT

Recognition of Patients at Risk for Ischemic Complications	Avoiding or Managing the Consequences of Limb Ischemia	Revascularization Options
History <ul style="list-style-type: none"> • Previous diagnosis of PAD • Claudication or related walking impairment symptoms • Risk factors for PAD, especially diabetes and renal failure Physical findings <ul style="list-style-type: none"> • Absent lower-extremity pulses • Abnormal ABI Clinical circumstances <ul style="list-style-type: none"> • Arterial surgery • Vascular access procedures • Acute and chronic heart diseases 	<ul style="list-style-type: none"> • PAD screening on admission examination and nursing assessment • Evaluation of extremity perfusion during routine nursing assessments • Documentation of ABI before and after arterial access procedures • Use of ultrasound imaging guidance for vascular access • Skin protection with off-loading (protect from pressure and shear) • Careful monitoring with the use of vasopressors, including measurement of cardiac output and consideration of other measures of perfusion as end points for therapy (not just blood pressure) • Wound management 	Surgical <ul style="list-style-type: none"> • Balloon catheter (Fogarty) thrombectomy • Direct arterial repair (eg, endarterectomy) • Bypass Endovascular <ul style="list-style-type: none"> • Catheter-directed thrombolysis • Thrombus aspiration devices • Mechanical thrombolysis devices • Adjunctive techniques • Balloon angioplasty • Stents (balloon-expandable, self-expanding, covered)

Endovascular therapies may avoid the need for or reduce the extent of open operative revascularization procedures.¹⁹ Catheter-directed thrombolysis delivers a pharmacologic fibrinolytic agent to the clot, but concerns about bleeding complications may limit the use of this approach, especially in the critically ill. Nonpharmacologic approaches to remove fresh clot or emboli include thrombus aspiration devices and mechanical thrombolysis devices.^{20,21} (See the *Endovascular Today 2007 Buyer's Guide* for a summary of available devices.) Adjunctive techniques, including balloon angioplasty, with or without placement of stents, can also be used.

Clinical judgment is needed to guide the selection and timing of interventions for ALI. In the setting of severe concomitant illness, however, less-invasive techniques and temporizing measures have particular benefit. There may be an opportunity for additional therapy at a later date, if needed. Management principles include recognition of patients at risk for ischemic complications, avoiding or managing the consequences of limb ischemia, and surgical or endovascular revascularization, when necessary (Table 3). ■

David L. Dawson, MD, is Professor, Department of Surgery, Division of Vascular and Endovascular Surgery, University of California, UC Davis Vascular Center, in Sacramento, California. He has disclosed that he is a paid consultant to Boston Scientific. Dr. Dawson may be reached at (916) 734-8122; david.dawson@ucdmc.ucdavis.edu.

1. Dormandy J, Heeck L, Vig S. Acute limb ischemia. *Semin Vasc Surg.* 1999;12:148-153.
2. Earnshaw JJ. Demography and etiology of acute leg ischemia. *Semin Vasc Surg.* 2001;14:86-92.
3. Klonaris C, Georgopoulos S, Katsargyris A, et al. Changing patterns in the etiology of acute lower limb ischemia. *Int Angiol.* 2007;26:49-52.

4. Dormandy JA, Rutherford RB. Management of peripheral arterial disease (PAD). TASC Working Group. TransAtlantic Inter-Society Consensus (TASC). *J Vasc Surg.* 2000;31:S1-S296.
5. Hirsch AT, Haskal ZJ, Hertzler NR, et al. American Association for Vascular Surgery; Society for Vascular Surgery; Society for Cardiovascular Angiography and Interventions; Society for Vascular Medicine and Biology; Society of Interventional Radiology; ACC/AHA Task Force on Practice Guidelines; American Association of Cardiovascular and Pulmonary Rehabilitation; National Heart, Lung, and Blood Institute; Society for Vascular Nursing; TransAtlantic Inter-Society Consensus; Vascular Disease Foundation. ACC/AHA 2005 guidelines for the management of patients with peripheral arterial disease (lower extremity, renal, mesenteric, and abdominal aortic): executive summary—a collaborative report from the American Association for Vascular Surgery/Society for Vascular Surgery, Society for Cardiovascular Angiography and Interventions, Society for Vascular Medicine and Biology, Society of Interventional Radiology, and the ACC/AHA Task Force on Practice Guidelines (Writing Committee to Develop Guidelines for the Management of Patients With Peripheral Arterial Disease) endorsed by the American Association of Cardiovascular and Pulmonary Rehabilitation; National Heart, Lung, and Blood Institute; Society for Vascular Nursing; TransAtlantic Inter-Society Consensus; and Vascular Disease Foundation. *J Am Coll Cardiol.* 2006;47:1239-1312.
6. Katzen BT. Clinical diagnosis and prognosis of acute limb ischemia. *Rev Cardiovasc Med.* 2002;3(suppl 2):S2-S6.
7. Blaisdell FW, Steele M, Allen RE. Management of acute lower extremity arterial ischemia due to embolism and thrombosis. *Surgery.* 1978;84:822-834.
8. Criqui MH, Fronek A, Barrett-Connor E, et al. The prevalence of peripheral arterial disease in a defined population. *Circulation.* 1985;71:510-515.
9. Hirsch AT, Criqui MH, Treat-Jacobson D, et al. Peripheral arterial disease detection, awareness, and treatment in primary care. *JAMA.* 2001;286:1317-1324.
10. Rutherford RB, Baker JD, Ernst C, et al. Recommended standards for reports dealing with lower extremity ischemia: revised version. *J Vasc Surg.* 1997;26:517-538.
11. Norgren L, Hiatt WR, Dormandy JA, et al for the TASC II Working Group. Inter-Society Consensus for the Management of Peripheral Arterial Disease (TASCII). *J Vasc Surg.* 2007;45(suppl):S5-S67.
12. Davison BD, Polak JF. Arterial injuries: a sonographic approach. *Radiol Clin North Am.* 2004;42:383-396.
13. Greenman RL, Panasyuk S, Wang X, et al. Early changes in the skin microcirculation and muscle metabolism of the diabetic foot. *Lancet.* 2005;366:1711-1717.
14. Zuzak KJ, Schaeberle MD, Lewis EN, et al. Visible reflectance hyperspectral imaging: characterization of a noninvasive, in vivo system for determining tissue perfusion. *Anal Chem.* 2002;74:2021-2028.
15. Cancio LC, Batchinsky AI, Mansfield JR, et al. Hyperspectral imaging: a new approach to the diagnosis of hemorrhagic shock. *J Trauma.* 2006;60:1087-1095.
16. Clagett GP, Sobel M, Jackson MR, et al. Antithrombotic therapy in peripheral arterial occlusive disease: the Seventh ACCP Conference on Antithrombotic and Thrombolytic Therapy. *Chest.* 2004;126(suppl):609S-626S.
17. Rooke TW, Hollier LH, Osmundson PJ. The influence of sympathetic nerves on transcutaneous oxygen tension in normal and ischemic lower extremities. *Angiology.* 1987;38:400-410.
18. Eslami MH, Ricotta JJ. Operation for acute peripheral arterial occlusion: is it still the gold standard? *Semin Vasc Surg.* 2001;14:93-99.
19. Ouriel K. Endovascular techniques in the treatment of acute limb ischemia: thrombolytic agents, trials, and percutaneous mechanical thrombectomy techniques. *Semin Vasc Surg.* 2003;16:270-279.
20. Laird JR. The management of acute limb ischemia: techniques for dealing with thrombus. *J Interv Cardiol.* 2001;14:539-546.
21. Kasirajan K, Haskal ZJ, Ouriel K. The use of mechanical thrombectomy devices in the management of acute peripheral arterial occlusive disease. *J Vasc Interv Radiol.* 2001;12:405-411.