

## IVC Filter Retrieval:

# Long-Term Data on Today's Filters are Needed

BY ANDY C. CHIOU, MD

**P**ulmonary embolism (PE) as a result of deep venous thromboembolism (DVT) is a known and sometimes preventable cause of patient morbidity and mortality. The incidence of PE in the US has been reported to be at least 355,000 patients per year, with an estimated annual mortality of 240,000.<sup>1</sup> Development of safe and effective means of preventing or reducing PE has lead to the latest generation of optional and retrievable vena cava filters. Prophylactic inferior vena cava (IVC) filter placement offers a protection rate of up to 99% against fatal PE.<sup>2-4</sup>

Increased utilization of IVC filters and the option of filter removal add some complexity to the decision of filter placement—whether to remove a filter and the timing of the filter removal. Additionally, there are increasing data detailing the possible long-term morbidity of IVC filters, such as increased risk of DVT.<sup>5</sup> A review of the clinical indications for IVC filter placement is helpful in discussing the considerations for short- versus long-interval implantation.

### CLINICAL INDICATIONS FOR IVC FILTER PLACEMENT

Therapeutic level anticoagulation with heparin (fractionated or unfractionated) or warfarin is considered first-line therapy for

patients with DVT and PE. There are several indications for vena caval filter placement.

(1) Patients who have a recurrent PE despite therapeutic anticoagulant treatment (failure of anticoagulation).

(2) Documented DVT or PE with a contraindication to anticoagulation, such as patients with increased risk for hemorrhage (ie, central nervous system or intracranial hemorrhage, massive hemoptysis, overt gastrointestinal bleeding, or retroperitoneal hemorrhage). These patients cannot safely undergo therapeutic level anticoagulation. In addition, patients with bleeding disorders or significant thrombocy-

topenia (<50,000 platelets/uL) who are in need of protection from thromboembolic complications should be considered for vena caval filter placement.<sup>6</sup>

(3) Failure of an already existing IVC filter.

(4) High-risk patient populations, such as patients with severe pulmonary hypertension with reduced cardiac reserve who are undergoing surgery for morbid obesity or orthopedic trauma. Multitrauma patients who have sustained a closed head injury, central nervous system injuries such as spinal cord trauma, multiple long bone fractures, pelvic fracture, or direct venous trauma are also included in this group.<sup>7</sup> Patients in this group accounted for up to 92% of PEs at one trauma center.<sup>8</sup>

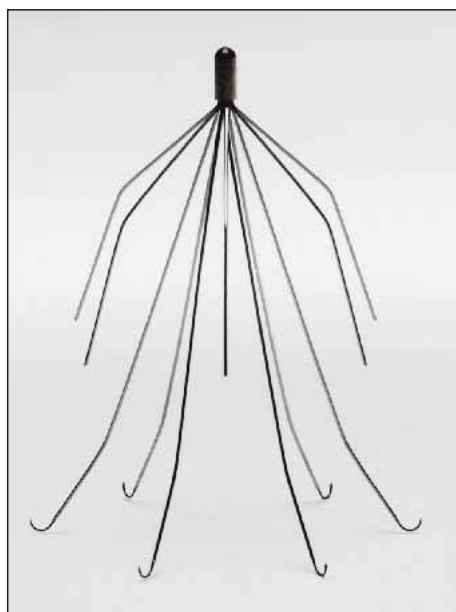


Figure 1. The Recovery nitinol filter (Bard Peripheral Vascular, Tempe, AZ).

## RETRIEVABLE OR OPTIONAL FILTERS

One reason retrievable or optional filters were developed was to allow for prophylaxis of pulmonary emboli in the patient with a temporally limited risk profile, such as with young multitrauma patients. Some clinicians prefer to have optional filters retrieved once there is resolution of the indications for which the filter was originally placed. Initially, animal studies in prototypes found that some retrievable filters were firmly incorporated into the IVC wall after just 3 weeks of implantation.<sup>9</sup> Thus, retrieval after 14 days of implantation should be performed with caution due to concerns over the amount of filter incorporation.<sup>10</sup> The animal data and early reports are now contrasted by several reports of successful late retrievals (>14 days) in patients. Many different models of retrievable filters exist, including the Recovery nitinol filter (Figure 1), the Günther Tulip Retrievable Filter (GTF; William Cook Europe, Bjaeverskov, Denmark) (Figure 2), and the OptEase filter (Cordis Corporation, a Johnson & Johnson company, Miami, Florida) (Figure 3).

### Recovery Filter

Approved in 2003 as a retrievable filter in the US, the Bard Peripheral Vascular Recovery Filter retains the proven conical shaped filtering design that has been adopted by several permanent IVC filters. The Recovery filter is nitinol based and utilizes a low-profile, 7-F delivery system via the femoral vein. The retrieval unit is a 10-F retrieval cone built around nine spring-loaded hooks encircled by a polyurethane lining. The Recovery retrieval cone is delivered from the jugular approach. The retrieval cone opens to a maximal 15-mm diameter and captures the nose of the Recovery filter in a method similar to the technique used by fighter aircraft to mid-air refuel with air tankers. The filter is then retracted into a central lumen of the retrieval cone.

In differentiation with the GTF, the Recovery filter has been reported to be safely retrieved up to 134 days after implantation.<sup>11</sup> This same group reported 100% technical success in both placement and retrieval of the filter, with a mean implantation period of approximately 53 days.

### Günther Tulip Retrievable Filter

The GTF has a hook at the conical apex that allows for retrieval using a snare and a specialized retrieval kit. The GTF utilizes an 8.5-F carrier and is delivered via a 10-F sheath. The filter measures 45 mm in length and can be placed in vena cava smaller than 30 mm in diameter.

The Canadian Registry for the GTF reported on the results of 91 of these filters placed, with an average implantation time of 9 days (range, 2-25 days).<sup>10</sup> Retrieval was attempted in only 52 patients. Technically successful




Figure 2. The Günther tulip retrievable filter.

retrieval was achieved in 98% of 53 GTFs. All retrieved specimens had fibrinous material on the legs and at the apex of the filter, which was identified as organizing thrombus.

### OptEase Filter

The OptEase Filter is a retrievable version founded on a modified design of the TrapEase Filter (Cordis). The filter is laser cut from a single piece of nitinol and has a dual-conical, dual-filtration, self-centering design. The OptEase filter utilizes a low-profile, 6-F delivery sheath and can be deployed via the jugular, brachial, or femoral approaches. One advantage of this design is that it may be retrieved via the femoral or jugular approach.

## COMPLICATIONS FROM IVC FILTERS

Initially and over time, IVC filters can become a source for morbidity and in rare instances, mortality. Complications that are frequently procedure related, such as DVT at the insertion site, arteriovenous fistula formation at the insertion site, and hematoma have been reported in the early period. In determining short versus longer retrievable IVC filter implantation intervals, several issues must be considered. As discussed previously, there should be resolution of the indications or risk factors for which the IVC filter was placed. Several possible late complications should be considered for determining implantation interval.

### Deep Venous Thrombosis

Recently, an 8-year follow-up of the PREPIC (Prevention du Risque d'Embolie Pulmonaire par Interruption Cave) randomized study was published, concluding that IVC filters reduced the risk of PE but increased the risk of DVT. Additionally, no overall survival benefit was found.<sup>5</sup> It should be noted that all 400 patients in this study received permanent IVC filters and that all patients initially had proximal DVT with or with-

out PE as an indication for randomization into the study. Of note, the patients receiving IVC filters were found to have significantly fewer symptomatic PEs (cumulative rate, 6.2%) than those in the non-IVC filter group (cumulative rate, 15.1%).

Another randomized study of vena cava filters in the prevention of PE found that, despite the short-term reduction in incidence of PE, there was an increase in recurrent DVT in patients who had IVC filters compared to the group that did not have filters placed.<sup>4</sup> Blebea reported a 40% (14 of 35 patients) incidence of DVT after filter insertion in patients without evidence of DVT prior to filter insertion. Seventy-one percent of these DVTs were located in the ipsilateral common femoral vein.<sup>12</sup> In a long-term follow-up of IVC filters in trauma patients at one center, 28 of 64 patients (44%) developed a DVT after filter placement.<sup>13</sup>

### IVC Thrombosis

Caval thrombosis rates vary dramatically depending on filters, ranging from 0.4% to 50%.<sup>14-20</sup> Complications of caval thrombosis include postphlebotic syndrome, characterized by leg swelling and ulceration and, more severely, phlegmasia cerulea dolens, which involves massive thrombosis of the venous outflow and collaterals of an extremity. Total thrombosis of the vena cava can lead to a severe impairment of venous return, potentially resulting in hypovolemic shock and cardiac arrest.

### Device Migration

IVC filters, both initially and over time, may become dislodged from their original deployed position in the vena cava and embolize to remote locations, such as the heart and lungs.<sup>21,22</sup> This can result in severe morbidity or possible mortality. Additionally, migrated devices may be technically complex to remove or reposition.

### Filter Strut Fracture

There are only a handful of reports of device fracture in the literature, most cases from the longer history of permanent IVC filters.<sup>15</sup> Poletti et al found that six of 38 patients (15.8%) with Simon nitinol filters had fracture of one strut, but no rupture of a filter basket was observed.<sup>23</sup> Usually, no adverse events resulted from strut fracture.

### IVC Wall Penetration or Perforation

IVC wall penetration by hooks or struts of filters is usually found incidentally and has been described to occur in up to 40% to 95% of cases.<sup>15,23</sup> The Simon nitinol filter had radiographic strut penetration of the vena cava wall in 95% (36 of 38) and was in contact with adjacent organs in 76% (29 of 38).<sup>23</sup> However, there were no clinical symptoms attributable to caval penetration. A large series of 1,731 patients who received caval filters found no patient to have symptomatic IVC penetration.<sup>25</sup> Although IVC penetration appears to be fairly common with filter placement, many authors deny that it causes adverse symptomatology.

Severe morbidity has been reported from filter erosion or complete perforation through the vena cava. Laceration of a lumbar artery by a stainless steel Greenfield filter strut resulted in a near fatal hemorrhage on the seventh postoperative day after filter placement in one patient.<sup>26</sup> A similar case was described by Howerton et al.<sup>27</sup> Aortic penetration has also been reported by several authors.<sup>28-30</sup> Retroperitoneal hematoma and small-bowel obstruction have been reported from filter struts penetrating the ureter or duodenum.<sup>31-34</sup>

### Prosthetic Infection

As with any indwelling prosthesis, IVC filters can be subject to infection. Strict aseptic technique should be maintained during the insertion of IVC filters. One case of septic death was reported from a filter placed using a previous central venous line access, rather than a de novo percutaneous puncture.<sup>35</sup>

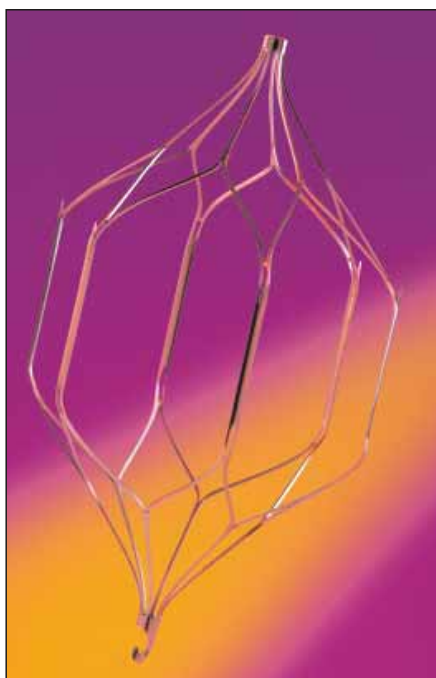

Figure 3. The OptEase filter.

## DISCUSSION

Lower-profile, retrievable or optional filters have led to some expanding indications for filter placement. New questions such as short versus long interval implantation, or if a filter should be removed, require more clinical experience and data. Most of the current longer-term data available are based on previous-generation permanent filters. Except for some small series, there is a relative paucity of data for the newer generation of retrievable or optional IVC filters. Some manufacturers have set up limited registries for their filters, whereas others have no formal central tracking mecha-

nism. The US FDA's Manufacturer and User Facility Device Experience Database (MAUDE) database has its limitations. MAUDE data represent reports of adverse events involving medical devices. The data consists of all voluntary reports since June 1993, user facility reports since 1991, distributor reports since 1993, and manufacturer reports since August 1996. Clearly, the voluntary nature of this reporting limits the overall power of this publically accessible database. Without better postmarket release data, most of the clinical decision making regarding this new generation of IVC filters has been based on previous principles, personal experience, and anecdotal data.

As for short versus longer interval implantation, the current data available present a mixed message. In the early animal studies, filters implanted for greater than 14 or 21 days were found to be firmly incorporated into the IVC wall, suggesting that removal may be more perilous after these short implantation intervals. Since the early reports, there have been several studies anecdotally reporting much longer implantation times with successful filter removal in patients. On the other hand, the possible complications associated with longer implantation intervals or permanent filters add to the overall morbidity from IVC filters and make an argument for short implantation intervals.

## CONCLUSION

The immediate and delayed possible complications of filter placement are well worth considering prior to the decision to place a filter in a patient. It is critical that these potential complications be weighed against the benefit of filter placement, be it a permanent or optional filter. There is a clear need to obtain better, more device-specific, long-term data on these new filters to assist in guiding clinical decision making. ■

*Andy C. Chiou, MD, is Assistant Professor of Surgery and Radiology, Vascular and Endovascular Surgery Section, Department of Surgery, University of Illinois College of Medicine at Peoria, Peoria, Illinois. He has disclosed that he hold no financial interest in any product or manufacturer mentioned herein. Dr. Chiou may be reached at (309) 624-9839; achiou@uic.edu.*

1. Bick RL. Hereditary and acquired thrombophilia. Part I. Preface. *Semin Thromb Hemost*. 1999;25:251-253.
2. Langan III EM, Miller RS, Casey III WJ, et al. Prophylactic inferior vena cava filters in trauma patients at high risk: follow-up examination and risk/benefit assessment. *J Vasc Surg*. 1999;30:484-490.
3. Velmahos GC, Kern J, Chan LS, et al. Prevention of venous thromboembolism after injury: an evidence-based report—part II: analysis of risk factors and evaluation of the role of vena caval filters. *J Trauma*. 2000;49:140-144.
4. Decousus H, Leizorovicz A, Parent F, et al. A clinical trial of vena caval filters in the prevention of pulmonary embolism in patients with proximal deep-vein thrombosis. *N Engl J*

- Med. 1998;338:409-415.
5. PREPIC (Prevention du Risque d'Embolie Pulmonaire par Interruption Cave) Study Group. Eight-year follow up of patients with permanent vena cava filters in the prevention of pulmonary embolism. *Circulation*. 2005;112:416-422.
6. Streiff MB. Vena caval filters: a comprehensive review. *Blood*. 2000;95:3669-3677.
7. Duperier T, Mosenthal A, Swan KG, et al. Acute complications associated with Greenfield filter insertion in high-risk trauma patients. *J Trauma*. 2003;54:545-549.
8. Rogers FB, Shackford SR, Wilson J, et al. Prophylactic vena cava filter insertion in severely injured trauma patients: indications and preliminary results. *J Trauma*. 1993;35:637-642.
9. Neuberger J, Gunther RW, Rassmussen E, et al. New retrievable percutaneous vena cava filter: experimental in vitro and in vivo evaluation. *Cardiovasc Intervent Radiol*. 1993;16:224-229.
10. Millward SF, Oliva VL, Bell SD, et al. Gunther Tulip retrievable vena cava filter: results from the Registry of the Canadian Interventional Radiology Association. *J Vasc Interv Radiol*. 2001;12:1053-1058.
11. Asch, MR. Initial experience in humans with a new retrievable inferior vena cava filter. *Radiology*. 2002;225:835-844.
12. Blebea J, Wilson R, Waybill P, et al. Deep venous thrombosis after percutaneous insertion of vena caval filters. *J Vasc Surg*. 1999;30:821-829.
13. Wojcik R, Cipolle MD, Fearen I, et al. Long-term follow-up of trauma patients with a vena caval filter. *J Trauma*. 2000;49:839-843.
14. Greenfield LJ, Proctor MC. Recurrent thromboembolism in patients with vena cava filters. *J Vasc Surg*. 2001;33:510-514.
15. Streiff MB. Vena caval filters: a comprehensive review. *Blood*. 2000;95:3669-3677.
16. Hawkins SP, al-Kutoubi A. The Simon nitinol inferior vena cava filter: preliminary experience in the UK. *Clin Radiol*. 1992;46:378-380.
17. Kim D, Edelman RR, Margolin CJ, et al. The Simon nitinol filter: evaluation by MR and ultrasound. *Angiology*. 1992;43:541-548.
18. Grassi CJ, Matsumoto AH, Teitelbaum GP. Vena caval occlusion after Simon nitinol filter placement: identification with MR imaging in patients with malignancy. *J Vasc Interv Radiol*. 1992;3:535-539.
19. Wojtowycz MM, Stoeck T, Crumley AB, et al. The bird's nest inferior vena caval filter: review of a single-center experience. *J Vasc Interv Radiol*. 1997;8:171-179.
20. Mohan CR, Hoballah JJ, Sharp WJ, et al. Comparative efficacy and complications of vena caval filters. *J Vasc Surg*. 1995;21:235-246.
21. Gelbfish GA, Ascer E. Intracardiac and intrapulmonary Greenfield filters: a long-term follow-up. *J Vasc Surg*. 1991;14:614-617.
22. James KV, Sobolewski AP, Lohr JM, et al. Tricuspid insufficiency after intracardiac migration of a Greenfield filter: case report and review of the literature. *J Vasc Surg*. 1996;24:494-498.
23. Poletti PA, Becker CD, Prina L, et al. Long-term results of the Simon nitinol inferior vena cava filter. *Eur Radiol*. 1998;8:289-294.
24. Hirsch SB, Harrington EB, Miller CM, et al. Accidental placement of the Greenfield filter in the heart: report of two cases. *J Vasc Surg*. 1987;6:609-610.
25. Athanasoulis CA, Kaufman JA, Halpern EF, et al. Inferior vena cava filters: review of a 26-year single-center clinical experience. *Radiology*. 2000;216:54-66.
26. Woodward EB, Farber A, Wagner WH, et al. Delayed retroperitoneal arterial hemorrhage after inferior vena cava (IVC) filter insertion: case report and literature review of caval perforations by IVC filters. *Ann Vasc Surg*. 2002;16:193-196.
27. Howerton RM, Watkins M, Feldman L. Late arterial hemorrhage secondary to a Greenfield filter requiring operative intervention. *Surgery*. 1991;109:265-268.
28. Chintalapudi UB, Gutierrez OH, Azodo MV. Greenfield filter caval perforation causing an aortic mural thrombus and femoral artery occlusion. *Cathet Cardiovasc Diagn*. 1997;41:53-55.
29. Kurgan A, Nunnelee JD, Auer AI. Penetration of the wall of an abdominal aortic aneurysm by a Greenfield filter prong: a late complication. *J Vasc Surg*. 1993;18:303-306.
30. Dabbagh A, Chakfe N, Kretz JG, et al. Late complication of a Greenfield filter associating caudal migration and perforation of the abdominal aorta by a ruptured strut. *J Vasc Surg*. 1995;22:182-187.
31. Goldman HB, Hanna K, Dmochowski RR. Ureteral injury secondary to an inferior vena cava filter. *J Urol*. 1996;156:1763.
32. Flanagan D, Creasy T, Chataway F, et al. Caval umbrella causing obstructive uropathy. *Postgrad Med J*. 1996;72:235-237.
33. Sarkar MR, Lemminger FM. An unusual cause of upper gastrointestinal haemorrhage—perforation of a vena cava filter into the duodenum. *Vasa*. 1997;26:305-307.
34. Bianchini AU, Mehta SN, Mulder DS, et al. Duodenal perforation by a Greenfield filter: endoscopic diagnosis. *Am J Gastroenterol*. 1997;92:686-687.
35. Millward SF, Peterson RA, Moher D, et al. LGM (Vena Tech) vena caval filter: experience at a single institution. *J Vasc Interv Radiol*. 1994;5:351-356.