

Endovascular Repair of the Thoracic Aorta

Use of endovascular techniques to repair thoracic aorta impingement after spinal surgery.

BY PAYAM JARRAHNEJAD, MD; SAMIR GADEPALLI, MD;
ROCCO TUTELA, JR, MD; AND MICHAEL RESNIKOFF, MD

Injury to the lower abdominal aorta and iliac vessels is a well-documented complication of spinal surgery; however, injury to the upper abdominal or thoracic aorta is far less common and poorly reported. Furthermore, aortic repair is usually performed via an open approach (either transperitoneal or retroperitoneal). We present a case of endovascular repair of a thoracic aortic impingement after spinal surgery.

CASE REPORT

A 48-year-old woman presented to the emergency department with weakness and fatigue. She had been discharged to a rehabilitation facility 1 month earlier after undergoing several operations resulting from a motor vehicle collision, including a small-bowel resection, splenectomy, diaphragmatic and esophageal repair, inferior vena cava filter placement, and an open reduction and internal fixation of a T11 to L3 fracture. On evaluation, the patient was noted to have stable vital signs and a hemoglobin level of 7.5 mg/dL. A computerized tomography (CT) scan of the chest, abdomen, and pelvis revealed that the screws used to fix the spinal column were impinging on the lower thoracic aorta. A repeat CT scan with 1.5-mm cuts showed that the left lateral interpedicular screws at the T12-L1 level were causing deformity of the posterolateral aspect of the aortic lumen and penetration into the lumen could not be excluded, although there was no periaortic hematoma visualized (Figure 1). A subsequent mag-

netic resonance image also revealed that the screws were impinging on the aorta (Figure 2).

Vascular surgery was consulted and the consensus was that the screws required removal to avoid erosion into the aorta and potential catastrophic bleeding. However, simply removing the screws could also increase the potential for bleeding; therefore, protection of the aorta must be accomplished prior to screw removal. Due to the screw's location, a thoracotomy would provide poor exposure, and the potential for placing an extra-anatomic graft was high. Endovascular stenting before screw removal was the safest option, and the patient agreed to the procedure.

PROCEDURE

The patient was taken to the operating room and was initially placed in the supine position. She was intubated under general anesthesia and monitoring lines were placed, including large-bore intravenous catheters and an arterial line. The right arm was then prepared and draped in a normal sterile fashion.

The right brachial artery was then accessed via a micropuncture needle and a 4-F sheath was inserted over the starter wire. A stiff-angle Glidewire (Boston Scientific Corporation, Natick, MA) and Omni flush catheter (Angiodynamics Incorporated, Queensbury, NY) were fed into the descending thoracic aorta just above the pedicle screws. The sheath and catheter were then secured in place.

The patient was then moved into a right lateral decubitus

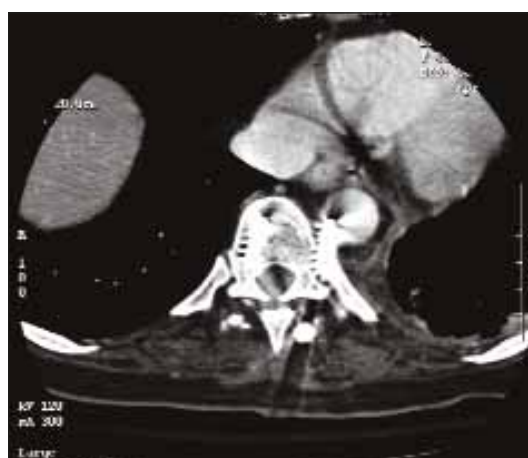

Figure 1. CT scan shows the left lateral interpedicular screws protruding into the posterolateral aspect of the aortic lumen at the T12-L1 level. Although periaortic hematoma is not visualized, penetration into the lumen cannot be excluded.

position. The chest, back, left flank, and left groin were prepared and draped in a normal sterile fashion. The spine surgeon exposed the two screws at the separate levels through the old spinal incision.

A left transverse groin incision was made and the common femoral artery was exposed. After administering systemic heparin, the artery was cannulated, a starter wire was placed, and an 11-F sheath was fed into position. A guidewire was fed through the iliac artery into the aorta up to the aortic arch and was then exchanged for a Lunderquist wire (Cook Group Inc., Bloomington, IN). An angiogram obtained via flush catheter showed the sites of involvement.

A 26-cm-diameter AneuRx aortic cuff (Medtronic, Inc., Santa Rosa, CA) was fed over the Lunderquist wire and positioned just over the caudal screw. The cuff was then removed, runners taken down, and expansion onto the vessel lumen was noted (Figure 3). The caudal pedicle screw was removed. An angiogram revealed brisk flow of contrast through the covered stent, without evidence of a leak. The cephalad screw was removed in a similar manner. Another 26-cm-diameter AneuRx aortic cuff was deployed over this screw as it was backed out (Figure 4). Repeated angiography revealed no evidence of a leak (Figure 5).

At this point, the wires were removed, the femoral artery primarily was repaired, and the leg was revascularized. The wounds were then closed and dressings were applied. The patient was returned to the supine position. The flush catheter was removed over a wire, followed by the wire and sheath; hemostasis was then achieved.

The patient tolerated the procedure well and was extu-

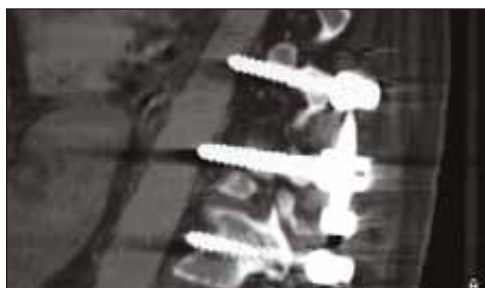

Figure 2. Magnetic resonance imaging reveals screws impinging on the aorta.

bated in the operating room. At completion, the patient was noted to have good perfusion in both upper and lower extremities. The patient was awake, had appropriate mental functioning, and was capable of unaffected movement of her upper and lower extremities. At 3- and 6-month follow-up, the patient continued to do well in rehabilitation, with patency of the endovascular aortic stent graft and no further episodes of anemia. A

repeat CT scan at that time demonstrated stability of the spine and acceptable position of the stent without evidence of a leak (Figure 6).

DISCUSSION

Major vascular injuries such as hemorrhage, arteriovenous fistula formation, and chronic pseudoaneurysm formation are possible after spinal surgery because of the immediate anatomical proximity of the aorta, vena cava, and iliac vessels to the spine. In cases of major vascular injury, the mortality rate can range from 50% to 75%, based on the time of diagnosis.¹ Pseudoaneurysm formation due to injury via a spinal procedure, however, is extremely rare.

Vascular injury near the diaphragmatic crura in the distal thoracic or upper abdominal aorta may have an increased chance of pseudoaneurysm formation as compared to other sites. This may be due to the tamponading effect of the retroperitoneal space and prevention of free intraperitoneal hemorrhage by the muscular crura.^{1,2} Furthermore, pseudoaneurysms may present several weeks to months from the time of injury; in fact, one study describes presentations ranging from 16 days to 21 months from the original injury, including four fatal presentations of a rupture.³

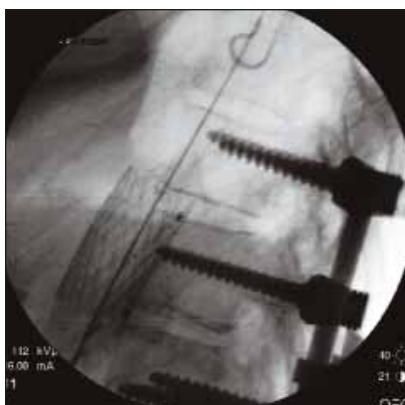


Figure 3. Angiography demonstrates initial stent placement over the caudal screw.

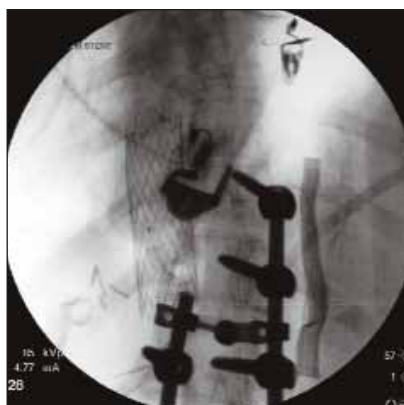

Figure 4. Angiography demonstrates both stents in the aorta after removal of the two screws.

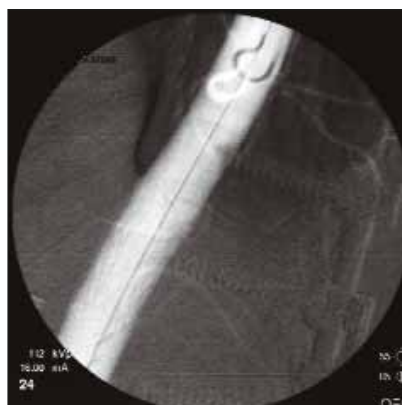

Figure 5. Final angiogram reveals no evidence of a leak.

Most injuries to the aorta after spinal surgeries reported in the literature are located in the lower abdominal aorta or the iliac vessels involving L3-5 disc spaces.³⁻⁸ However, recent improvements in biomaterials and surgical technique may lead to a decrease in these injuries and result in a relative increase in the more proximal aortic injuries.⁹

Any injury to the aorta must be acted on, even if it is only based on a high index of suspicion. Those aortic injuries involving retroperitoneal injuries, as in this case, carry the highest risk of morbidity and mortality.² Other clues that suggest a possibility of vascular injury include unexplained hypovolemia, tachycardia, and hypotension with abdominal or back pain, nausea, vomiting, and occasionally a palpable abdominal mass, indicating a retroperitoneal hematoma or pseudoaneurysm.¹

Diagnosis of any suspected aortic injury should be confirmed quickly with a contrast-enhanced CT scan or aortography. Doppler imaging is usually inaccurate due to bowel gas and other overlying visceral interference. Magnetic resonance imaging may be limited due to hardware from the spinal procedure.² In our patient, an initial CT scan revealed the injury sites and further detailed images were obtained with thinner cuts to better understand the relation of the screws to the aorta.

Finally, immediate repair is warranted if a potential danger to the aorta is identified. In our case, an endovascular approach was used to stent the areas near the two screws. There are major advantages to using an endovascular approach, including reduced blood loss, earlier recovery, and decreased postoperative pain. Furthermore, accessibility of the screws using a thoracotomy would have led to a difficult and complex technical procedure, increasing the patient's risk of morbidity and mortality. The endovascular approach also facilitates access to the proximal aorta for control. Most importantly, it avoids aortic cross clamping, reducing the risk of ischemia, paralysis, and other associated morbidities. Therefore, the endovascular procedure performed was ideal in this situation for the repair of the injuries by the two pedicle screws.

CONCLUSION

We present a case of endovascular repair of the aorta after iatrogenic injury via a spinal procedure. Early intervention and a coordinated plan between all the services helped increase the chance of successful removal of the pedicle

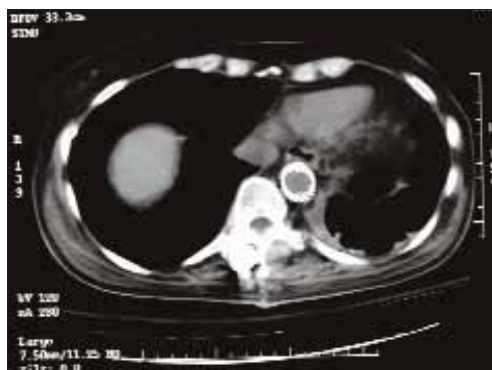

Figure 6. CT scan demonstrates stability of the spine and acceptable position of the stents without evidence of a leak.

screws in this patient. A high index of suspicion and immediate evaluation are also important in the care of such a patient. In the future, endovascular repair of the aorta may be attempted with successful results for other iatrogenic injuries, especially in patients with difficult open accessibility or possible prolonged recovery time, and even in those patients with exceedingly proximal injury of the aorta. ■

Payam Jarrahnajad, MD, is from the Department of Surgery,

Morristown Memorial Hospital, Morristown, New Jersey. He has disclosed that he holds no financial interest in any product or manufacturer mentioned herein. Dr. Jarrahnajad may be reached at (973) 971-5684; payamjarrahnajad@yahoo.com.

Samir Gadepalli, MD, is from the Department of Surgery, Morristown Memorial Hospital, Morristown, New Jersey. He has disclosed that he holds no financial interest in any product or manufacturer mentioned herein. Dr. Gadepalli may be reached at samir.gadepalli@ahsys.org.

Rocco Tutela, Jr, MD, is from the Department of Surgery, Morristown Memorial Hospital, Morristown, New Jersey. He has disclosed that he holds no financial interest in any product or manufacturer mentioned herein. Dr. Tutela, Jr may be reached at rocco.tutela@ahsys.org.

Michael Resnikoff, MD, is from the Department of Surgery, Morristown Memorial Hospital, Morristown, New Jersey. He has disclosed that he holds no financial interest in any product or manufacturer mentioned herein. Dr. Resnikoff may be reached at mikers1@optonline.net.

1. Lim K-E, Fan K-F, Wong Y-C, et al. Iatrogenic upper abdominal aortic injury with pseudoaneurysm during spinal surgery. *J Trauma*. 1999;46:729-731.
2. Smythe WR, Carpenter JP. Upper abdominal aortic injury during spinal surgery. *J Vasc Surg*. 1997;25:774-777.
3. Potts RG, Alguire PC. Pseudoaneurysm of the abdominal aorta: a case report and review of the literature. *Am J Med Sci*. 1991;4:265-268.
4. Boyd DP, Forka GJ. Arteriovenous fistula and isolated vascular injuries secondary to intervertebral disk surgery. *Ann Surg*. 1965;161:524-531.
5. Brewster DC, May ARL, Darling RC, et al. Variable manifestation of vascular injury during lumbar disc surgery. *Arch Surg*. 1979;114:1026-1030.
6. Chaikof EL, Shamberger RC, Brewster DC. Traumatic pseudoaneurysms of the abdominal aorta. *J Trauma*. 1985;25:169-173.
7. Linton RR, White PD. Arteriovenous fistula between the right common iliac artery and the inferior vena cava: report of a case of its occurrence following an operation of a ruptured intervertebral disk with cure by operation. *Arch Surg*. 1945;50:6-13.
8. Salander JM, Youkey JR, Rich NM, et al. Vascular injury related to lumbar disk surgery. *J Trauma*. 1985;24:624-631.
9. Choi JB, Han JO, Jeong JW. False aneurysm of the thoracic aorta associated with an aorto-chest wall fistula after spinal instrumentation. *J Trauma*. 2001;50:140-143.