

# A New Pathway for Central Venous Occlusion

After the failure of conventional techniques, a radiofrequency energy guidewire may be a useful treatment option.

BY JAMES F. MCGUCKIN, MD; ADRIENNE M. GOSNEAR, BS, RTC; AND RENEE L. WILLIAMS, BA, RT

Central venous occlusions (CVOs) are a common complication that may be observed subsequent to the placement of central venous catheters. Previous studies have reported the incidence of venous thrombosis, the formation of which may result in CVOs, to be between approximately 3% and 38% after the placement of peripherally inserted central venous catheters and venous ports.<sup>1</sup> The most common etiology of symptomatic lesions results from the long-term catheterization of patients for hemodialysis to treat end-stage renal disease (ESRD).<sup>2</sup> The presence of an ipsilateral vascular access greatly increases the blood flow in an upper extremity such that 70% of patients who have an ipsilateral hemodialysis access will become symptomatic with a CVO as compared to the 10% of nondialysis patients that become symptomatic.<sup>2</sup> Ipsilateral hemodialysis access with a pacemaker is a compounding risk variable. Symptoms that may develop due to a CVO include an acutely swollen arm, neck pain, facial swelling, and chest wall varicosities. Percutaneous treatment is a more common choice than thoracic surgery for alleviating these symptoms due to the high morbidity and mortality rates in ESRD patients with high upper extremity blood flow.<sup>3</sup>

However, chronically occluded veins are often difficult to cross using guidewires and catheters, with some reported failure rates as high as 24%.<sup>4</sup> In our institution, using conservative techniques with a stiff Glidewire (Terumo Interventional Systems, Somerset, NJ) with catheter support and, if necessary, sharp recanalization techniques using the back end of the Glidewire, we have been successful in recanalizing CVOs in approximately 75% of cases via the ipsilateral hemodialysis access alone and with an overall successful recanalization rate of 87.5% when using the

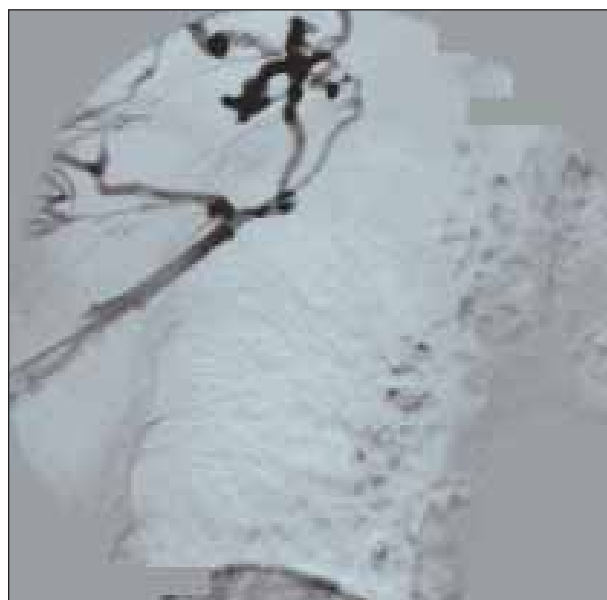
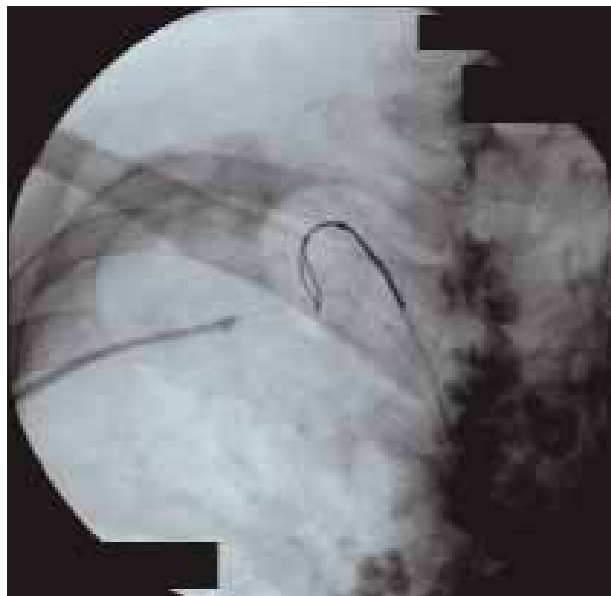

Figure 1. Preangiogram demonstrating right brachiocephalic vein occlusion with collaterals.

combined right common femoral vein and ipsilateral hemodialysis approaches. This high overall success rate, however, yields a 12.5% failure rate with the associated residual morbidity of arm/facial swelling, poor-quality dialysis, and possibly the need for banding or surgery for a new contralateral access.

The recently developed PowerWire radiofrequency (RF) guidewire (Baylis Medical Company, Inc., Montreal, Quebec, Canada) augments the mechanical properties of a typical guidewire with the penetrating ability of RF cutting energy to facilitate the recanalization of fibrotic

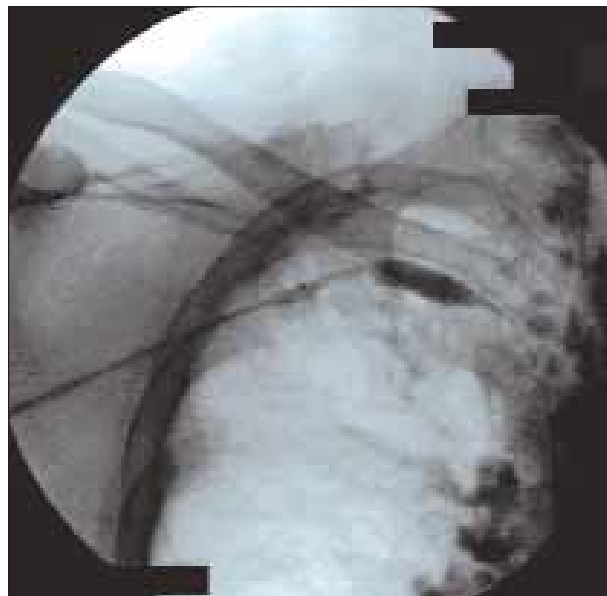


**Figure 2.** Baylis RF PowerWire being passed through the occlusion in the plane of the retrieval snare.

and chronic CVOs.<sup>5</sup> We are using the RF PowerWire in patients with chronic CVOs who had failed recanalization using conventional wire and sharp recanalization techniques. We have had an 84% success rate in a series of prospective patients in which aggressive conservative techniques have failed.

Patients typically present with CVOs involving the subclavian/brachiocephalic veins or superior vena cava (SVC) with or without ipsilateral access thrombosis (Figure 1). If the access is thrombosed, it is not declotted until central recanalization has been achieved. If there is arm swelling, and it is related to a CVO secondary to a pacemaker/defibrillator wires, the ipsilateral hemodialysis access is used to navigate centrally, or the native basilic vein can be accessed if there is not a hemodialysis access. Adequate mapping of the central vasculature was performed with delayed imaging obtained to show reconstitution of the medial vessels or SVC.

A snare was used in all cases via the right common femoral vein to act as a target for the safe passage of the RF PowerWire. The snare was typically placed into the most lateral and/or cephalad position and used as a linear target for the PowerWire in one projection and a formed loop in the orthogonal projection. Biplane fluoroscopy was used, as well as a road-mapping technique, when possible, to aid passage of the PowerWire through the CVO. A long Terumo 7-F, 25-cm Pinnacle R/O sheath was combined coaxially with a 55-cm arm access/90-cm groin access 7-F Brite Tip guide catheter (Cordis Corporation, Warren, NJ), which was coupled with an angled-taper 5-F 65-cm arm access/100-cm



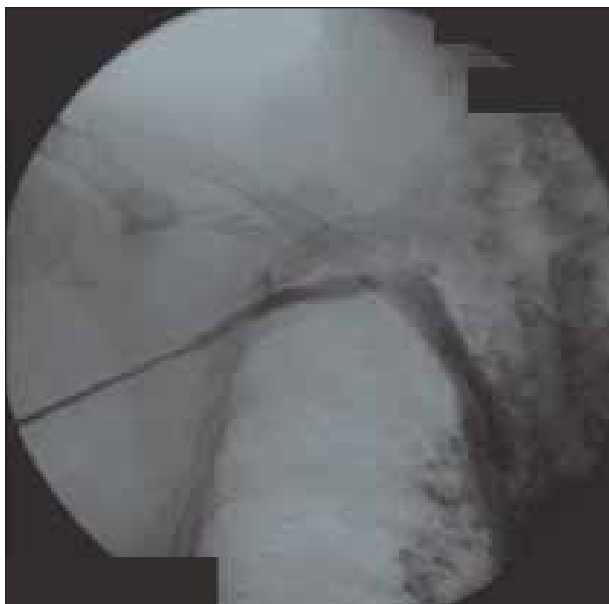**Figure 3.** Angioplasty of the occluded right brachiocephalic vein tract.

groin access Glidecath (Terumo Interventional Systems). The PowerWire was controlled with a torque device before coupling it with the Baylis RF generator. The RF generator was set at 25 W, and the pulse was set for a 2-second duration. The torque device was set on the PowerWire to control the wire, but it was also used to limit the excursion of the wire advancement. The wire was advanced under the cutting power setting, and the Glidecath and guide catheter were advanced sequentially to support the PowerWire and enable it to start by coming out “hot” from the catheter housing (Figure 2). Lesions ranged from 2 to 10 cm, and occluded stents were traversed safely as well.

This technique has been 84% successful in patients that have had previous failure of recanalization using conservative techniques, yielding an over-CVO recanalization rate of approximately 97%. Failure modes have included hemothorax, fractured stents that prevented safe passage of the wire due to power shut-off, inability to pass the PowerWire through the occlusion, and poor angulation at the apex of the subclavian/brachiocephalic junction leading to increased risk of safe wire passage. After the PowerWire was passed through the target snare, the 260-cm wire was passed “through and through” out the second 7-F groin sheath, and then conventional high-pressure angioplasty and stenting were then used to maintain patency (Figures 3 and 4).

## DISCUSSION

An escalation of symptomatic CVOs is likely related to the increased use of long-term central venous catheters



**Figure 4.** SVC angiogram demonstrating recanalization of the right brachiocephalic vein with absence of collaterals.

in patients with ESRD.<sup>3,6</sup> Unfortunately, many centers have come to view central venous catheters as a “necessary evil” because many patients commencing hemodialysis require immediate treatment despite lengthy maturation times for an arteriovenous fistula.<sup>3</sup>

With a primary goal of CVO treatment being to provide symptomatic relief for this increasing patient demographic, endovascular techniques, including percutaneous transluminal angioplasty, offer a minimally invasive alternative to surgery and are recommended by many physicians as a first-line treatment with a high success rate.<sup>7,8</sup> Surgical bypass procedures have a high morbidity rate related to the deep location of the vessels in the thorax; another report presents a 31% mortality rate at 1 year after bypass graft surgery in a study of patients with ESRD and CVO disease.<sup>9,10</sup>

Endovascular techniques, however, are not unsusceptible to complications and concerns. The occasional failure of a guidewire to cross the proximal cap of an occlusion is a chief contributor to the abandonment of a procedure or, at the very least, prolonged procedure times, which are further associated with increased radiation exposure to both the patient and the operator. Radiation dosages have been well documented as a possible cause of injuries such as temporary erythema, deep ulcerations, or permanent scarring.<sup>11</sup>

Alternatives to using traditional guidewires for the percutaneous treatment of CVOs are varied and include hydrophilic catheters and wires, sharp needle recanalization, blunt dissecting catheters, or subintimal re-entry catheters.<sup>3,12</sup>

Apart from the consensus of using a traditional guidewire as

a first-line treatment for CVOs, there is uncertain opinion on the use of any alternative treatments except that mechanical thrombectomy should not be used as a primary therapy because of the sharp angles and thin walls of the vessels in the region. The use of thrombolytic agents to treat CVOs is also not recommended as a primary treatment.<sup>13</sup>

## CONCLUSION

This article is limited by the fact that it was nonrandomized and carried out by a single operator on a small number of selected patients. Despite the aforementioned limitations, the PowerWire RF guidewire shows potential as a feasible and relatively safe tool for the experienced physician to improve procedural success when recanalizing CVOs. ■

*James F. McGuckin, MD, is Medical Director of the Philadelphia Vascular Institute and Vascular Access Centers and Founder of Rex Medical. He has disclosed that he holds no financial interest in any product or manufacturer mentioned herein; this article was supported with product only from Baylis Medical. Dr. McGuckin may be reached at (609) 882-1770; jamesmcguckin@earthlink.net.*

*Adrienne M. Gosnear, BS, RTC, is Senior Radiology Technologist and Director of Procurement at Vascular Access Centers in Philadelphia, Pennsylvania. She has disclosed that she holds no financial interest in any product or manufacturer mentioned herein.*

*Renee L. Williams, BA, RT, is Senior Radiology Technologist at Vascular Access Centers in Philadelphia, Pennsylvania. She has disclosed that she holds no financial interest in any product or manufacturer mentioned herein.*

- Gonsalves CF, Eschelman DJ, Sullivan KL, et al. Incidence of central vein stenosis and occlusion following upper extremity PICC and port placement. *Cardiovasc Interv Radiol.* 2003;26:123-127.
- Lumsden AB, MacDonald MJ, Isiklar H, et al. Central venous stenosis in the hemodialysis patient: Incidence and efficacy of endovascular treatment. *Cardiovasc Surg.* 1997;5:504-509.
- Altman SD. A practical approach for diagnosis and treatment of central venous stenosis and occlusion. *Semin Vasc Surg.* 2007;20:189-194.
- Criado E, Marston WAS, Jaques PF, et al. Proximal venous outflow obstruction in patients with upper extremity arteriovenous dialysis access. *Ann Vasc Surg.* 1994;8:530-535.
- Veldtman GR, Hartley A, Visram N, et al. Radiofrequency applications in congenital heart disease. *Expert Rev Cardiovasc Ther.* 2004;2:117-126.
- Sprouse LR, Lesar CJ, Meier GH, et al. Percutaneous treatment of symptomatic central venous stenosis. *J Vasc Surg.* 2004;39:578-582.
- Haage P, Vorwerk D, Piroth W, et al. Treatment of hemodialysis-related central venous stenosis or occlusion: results of primary Wallstent placement and follow-up in 50 patients. *Radiology.* 1999;212:175-180.
- Dammers R, de Haan MW, Planken NR, et al. Central vein obstruction in hemodialysis patients: results of radiological and surgical intervention. *Eur J Vasc Endovasc Surg.* 2003;26:317-321.
- Currier CB, Widder S, Ali A, et al. Surgical management of subclavian and axillary vein thrombosis in patients with a functioning arteriovenous fistula. *Surgery.* 1986;100:25-28.
- Bhatia DS, Money SR, Ochsner JL, et al. Comparison of surgical bypass and percutaneous balloon dilation with primary stent placement in the treatment of central venous obstruction in the dialysis patient: one-year follow-up. *Ann Vasc Surg.* 1996;10:452-455.
- den Boer A, de Feijter PJ, Serruys PW, et al. Real-time quantification and display of skin radiation during coronary angiography and intervention. *Circulation.* 2001;104:1779-1784.
- Honnef D, Wingen M, G  nther RW, et al. Sharp central venous recanalization by means of a TIPS needle. *Cardiovasc Interv Radiol.* 2005;28:673-676.
- Haage P, G  nther RW. Radiological intervention to maintain vascular access. *Eur J Vasc Endovasc Surg.* 2006;32:84-89.