

# Stent Placement After DVT Thrombolysis/Mechanical Thrombectomy

Which patients should be stented and which should not?

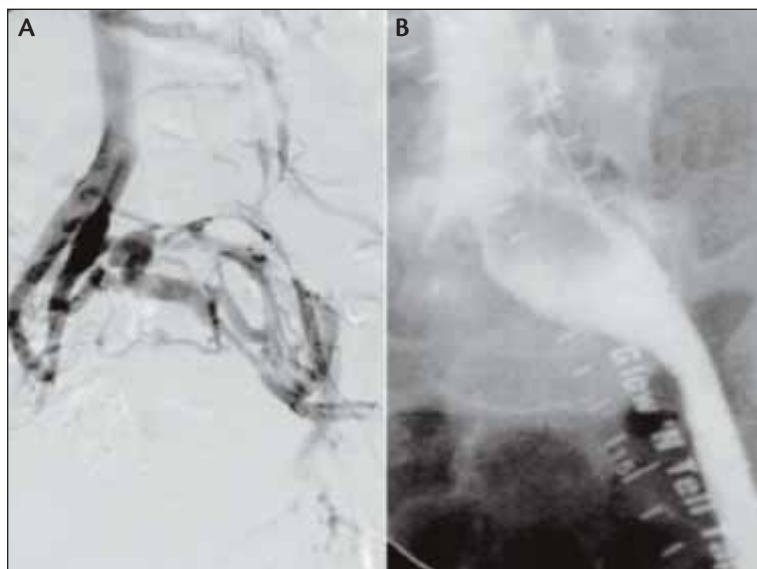
BY DAVID GILLESPIE, MD; MARCIA JOHANSSON, RN, MS; AND CAROLYN GLASS, MD

It is an exciting time to be an endovascular therapist who deals with venous disease. As endovascular technologies continue to evolve, practitioners have an ever-increasing armamentarium of techniques available to help patients. One patient population in particular who benefits from this revolution is the group with venous outflow obstruction. The venous outflow from the lower extremity includes the external iliac vein, internal iliac vein, the common iliac vein, and the vena cava. For the past several decades, the obstructive component in patients with venous claudication or chronic venous ulcers has been underdiagnosed and undertreated by many clinicians. This is usually due to unfamiliarity with the entity and the challenges that operative techniques entail. Now, with the upswing of techniques such as percutaneous mechanical thrombectomy (PMT), intravascular ultrasound (IVUS), and venous stenting, clinicians are able to help an increasing number of these patients.

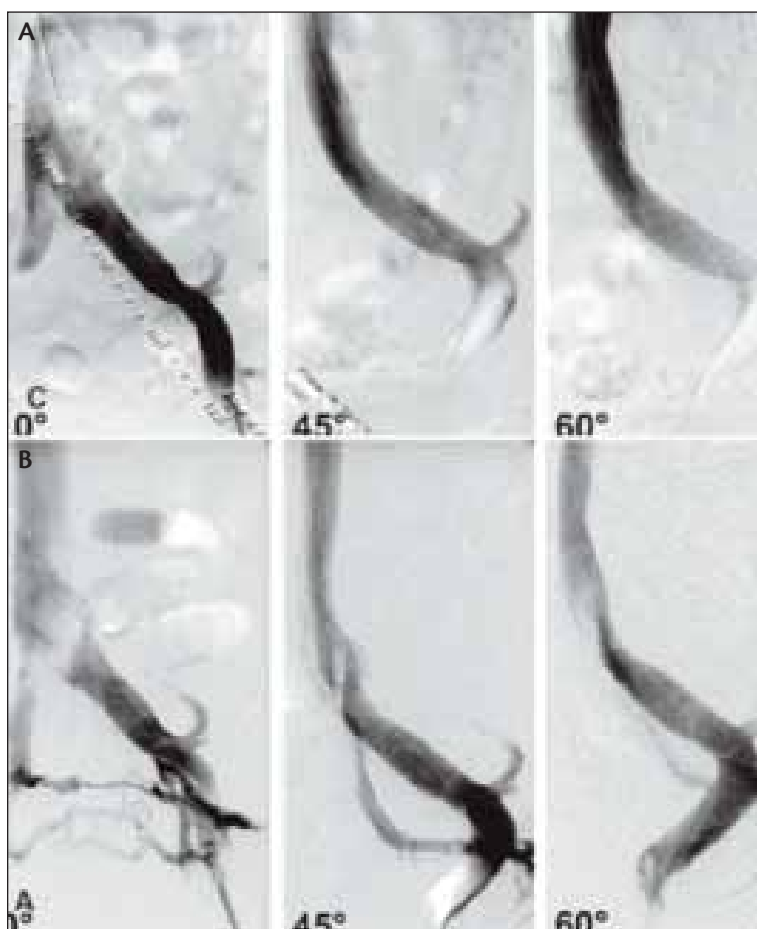
Deep venous thrombosis (DVT) is the most common cause of venous outflow obstruction. Venous outflow obstruction may be either acute or chronic. Patients with acute DVT usually present with sudden onset of unilateral leg swelling. This is often painful, associated with cyanosis of the extremity, and often after prolonged immobilization or sedentary activity. Chronic venous outflow obstruction

usually occurs months to years after an initial DVT. In symptomatic patients, recanalization of thrombosed veins is incomplete, and the collateral circulation is inadequate. The proximal obstruction results in distal venous hypertension, lower extremity swelling, and pain worsened after ambulation. Although venous outflow obstruction of the lower extremity may involve the entire venous system, current endovascular techniques are most effective in treating thrombosis of the largest veins—namely the inferior vena cava (IVC), common iliac vein, and external iliac veins. Thrombotic venous outflow obstruction may be associated with thrombophilia. Less commonly, it may be associated with IVC filter thrombosis resulting in caval occlusion. Nonthrombotic venous obstruction of the vena cava or left common iliac vein may occur from abnormal reaction to the overlying right common iliac artery (May-Thurner syndrome) with resultant intravenous web formation.<sup>1</sup>

Several years after having DVT, an estimated 20% to 40% of patients develop chronic postthrombotic syndrome (PTS), which is characterized by hemosiderin pigment deposition, leg pain, heaviness, swelling, and in severe cases, skin ulcers.<sup>2-5</sup> Chronic venous ulceration has been reported to occur in as many as 4% to 6% of these patients.<sup>6</sup> Several studies have shown encouraging data that demonstrate that early clot removal results in relief of venous outflow



**Figure 1.** Venographic findings of outflow obstruction. Transpelvic collaterals (A); pancaking of left common iliac vein (B).



**Figure 2.** Multiplanar venography before (A) and after (B) ilio caval stenting. Note the loss of collaterals.

obstruction in patients with acute DVT and prevention of PTS.<sup>7-10</sup> The National Institutes of Health-sponsored ATTRACT trial is designed to answer this question more definitively through its large, prospective, multicenter study design.

Today, catheter-directed thrombolysis and PMT have become important therapies in patients with acute DVT, largely replacing bypass venous surgery. Initial clinical and technical success can be achieved in most patients with acute DVT. Early thrombus removal results in relief of lower extremity venous hypertension and improved long-term patency of the venous system.<sup>11-15</sup> Rethrombosis or stenosis of the thrombosed vein may occur. The National Venous Registry showed an overall thrombosis-free survival in 65% of patients at 6 months and 60% of patients at 12 months after thrombolysis. Thrombosis-free survival was most favorable in the subgroup of patients with acute, first-time iliofemoral DVT who had successful lysis. In an effort to improve long-term patency after thrombolysis, the venous system should be evaluated for areas of stenosis. Despite the absence of grade 1 evidence, clinical experience has shown that venous stenoses of the lower extremity do not respond to angioplasty alone, and therefore, stenting is recommended.

The decision when to stent venographic findings of the lower extremity after successful thrombolysis can be difficult. Measuring pressure gradients across lesions can be performed, but due to the low pressure in the venous system and the high capacitance of the vessels, it is unclear how to interpret the results. Currently, there are no reporting standards for these lesions. Color-flow duplex is another methodology that could be used to investigate stenoses in the venous system. Labropoulos et al reported the best criterion by color-flow duplex to detect a > 50% stenosis was a poststenotic to prestenotic peak vein velocity ratio of 2.5. In this study, they found when they used this criteria alone, diagnosis of a > 50% venous stenosis was 90% and could be improved to 100% when combined with conventional phlebography.<sup>16</sup> Despite this new research, diagnosis and

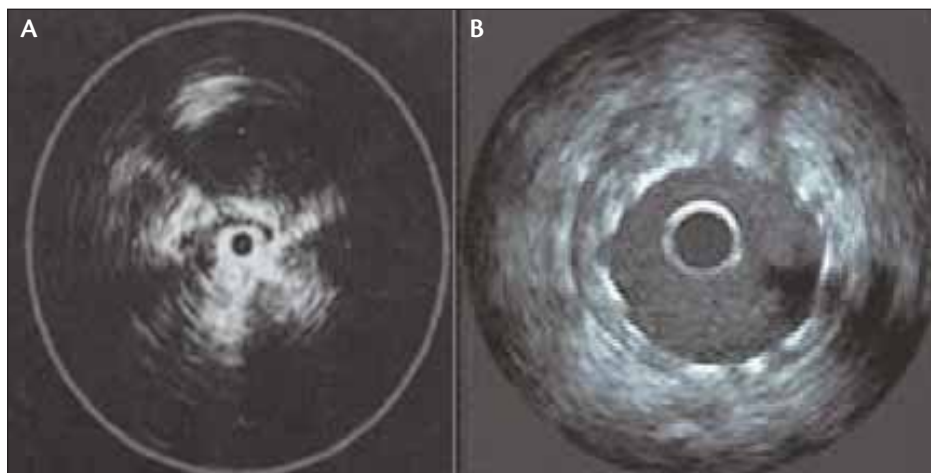


Figure 3. IVUS before (A) and after (B) stenting.

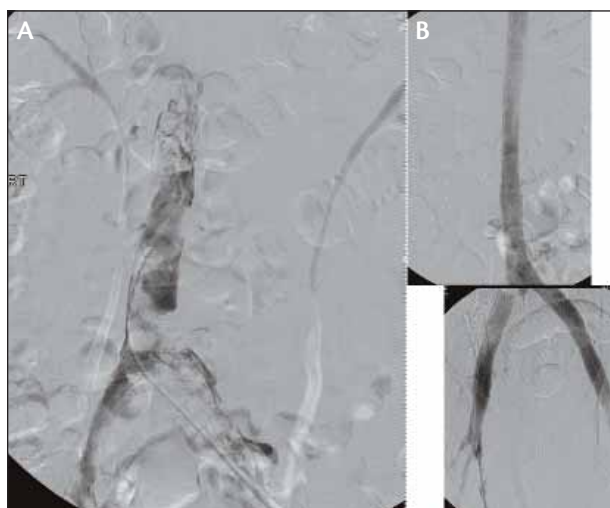


Figure 4. Extensive acute on chronic thrombosis before (A) and after (B) PMT and ilio caval stenting.

treatment of venous outflow stenosis is usually based on venographic findings. Venous outflow obstruction can be identified using standard transfemoral venography by finding a definite obstruction or the development of transpelvic collaterals. Other findings suggestive of an underlying venous obstruction, however, are often much more subtle. Such findings include widening of the iliac vein, pancaking or thinning of the contrast dye, partial intraluminal defect or septum, and minimal filling of transpelvic collaterals (Figure 1). The vagaries of single-plane venography often lead to the misdiagnosis or non-detection of significant venous stenoses. Morphologic assessment of venous stenoses has recently shown to be improved by using multiplane venography. Using multiple angled projections often reveals surprisingly tight stenoses on oblique projections, even though venography in the

anteroposterior view is normal (Figure 2).<sup>17</sup>

IVUS is a promising technique for the evaluation of venous stenoses that is superior to single-plane venography. It allows the detection of lesion morphology and degree of stenosis (Figure 3). Neglen et al compared the use of IVUS to venography for the evaluation of patients with venous outflow obstruction.<sup>18</sup> In this study,

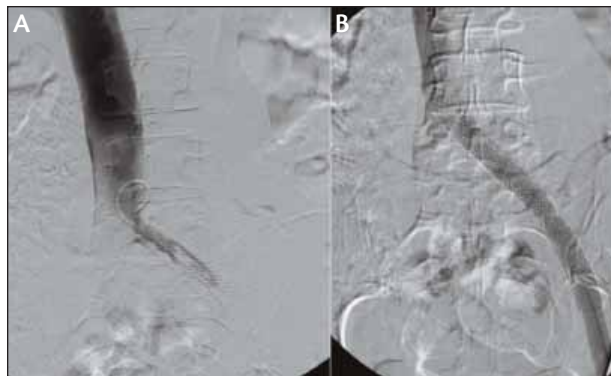
they found that venography underestimated stenosis by

30%. In addition, they reported that venography was considered normal in one-fourth of limbs despite the fact that IVUS showed more than 50% of obstruction. IVUS shows intraluminal details, trabeculations, and webs that may be hidden by the contrast dye. Other advantages of IVUS are its ability to demonstrate external compression directly, wall thickness, and neointimal hyperplasia. To date, IVUS seems to be the best available method for diagnosing clinically significant chronic iliac vein obstruction.

Unlike the arterial system, immediate recoil of venous stenoses occurs after balloon venoplasty in the majority of cases. The National Venous Registry Grading Scale for DVT thrombolysis is referenced by most studies (< 50% lysis, grade I; 50%–99% lysis, grade II; and 100% lysis, grade III). A venous stent is usually indicated if grades I and II are present at the conclusion of thrombolytic therapy. Vedantham et al noted that residual short-segment (< 10 cm) iliac vein thrombus and/or stenosis should be treated with stent placement after thrombolysis.<sup>12</sup> In the treatment of iliac vein or vena cava stenosis, placement of a self-expanding stent should be considered in any case requiring venoplasty. Although published reports have included nitinol stents, most clinicians agree that the use of the stainless steel Wallstent (Boston Scientific Corporation, Natick, MA) is superior to other stents based on its greater radial force and available assortment of larger diameter of stents.

## TECHNIQUE

Retrograde and antegrade approaches to ilio caval venous stenting have been described. Benefits of a jugular approach include ease of access to either iliac vein, whereas disadvantages include limited catheter lengths needed to deliver venous stents. The antegrade approach involves ipsilateral cannulation of the femoral vein (previously known as the



**Figure 5. Thrombosis of the iliac vein stent before (A) and after (B) PMT and extending stenting across the lesion into the vena cava.**

superficial femoral vein). Low thigh access is necessary to allow stent deployment up to and below the inguinal ligament without being impeded by the sheath. Popliteal vein access is rarely used and often not possible due to segmental occlusion of the proximal femoral vein. We use ultrasound guidance to avoid inadvertent arterial puncture. Ultrasound guidance also aids in femoral vein location, which can be variable in the posterolateral or posteromedial location in reference to the femoral artery. The use of regional or general anesthesia should be based on both patient and physician preference. Chronic cases can often be long, and general anesthesia has its benefits. However, sedation with local anesthesia is a viable option. Heavy intravenous sedation or general anesthesia is useful because many patients will experience some discomfort when undergoing angioplasty of tight or long venous lesions. Without this, clinicians are usually limited in the diameter to which patients will tolerate percutaneous transluminal angioplasty. We use IVUS to assess the vein before and after stent placement and look for adequate recanalized vein lumen diameter, apposition of the stent against the vein wall, need for further stenting, and any thrombotic debris that might need to be treated.

There are two main schools of thought when considering stenting of the iliac vein outflow tract. The first believes in limiting stent placement to the common iliac vein. This technique minimizes the length of iliac vein segment that has the potential for restenosis from stent placement. The second school believes in stenting longer segments of the venous outflow tract to maintain lumen diameter. In this technique, stents are not only used in the common iliac vein but also across the iliac vein confluence into the infrarenal vena cava. Our bias is to stent more of the venous outflow and especially across the common iliac vein confluence into the vena cava. In their experience, Neglen and Raju found that patency rate is not related to the length of stented area

or the placement of the stent across the inguinal ligament but that it depends on the etiology and whether the treated postthrombotic obstruction is occlusive or nonocclusive.<sup>19</sup>

Predilation is usually necessary in order to allow delivery of the larger stents that are required to re-establish venous outflow. Unlike the artery, the vein accepts extensive dilation without rupture. We use standard noncompliant angioplasty balloons for venous dilation. For PTA before stent delivery, we use small-diameter balloons (eg, 3–4 mm X 10 cm). After this, we place the stents. Stents are placed well into the inferior vena cava to avoid migration and early restenosis. Insertion of a large-diameter stent is recommended with stent sizes ranging from cava (18–24 mm), common iliacs (16–18 mm), and external iliacs (14–16 mm) (Figure 4). Currently, only the Wallsent is large enough to accommodate this range of sizes. Stents are delivered distally first in the external iliac and build proximally to and into the vena cava. After delivery of the most distal stent, postdilation is recommended before delivery of the next stent due to the foreshortening that occurs as lumen diameter increases. It should be noted that the disease is often more extensive than venography would suggest. It is essential that the entire diseased segment is covered as outlined by IVUS. Inadequate stenting has been shown to be the most common cause of restenosis. It is important to avoid short skip segments (< 5 cm) in between two stents because they are also prone to secondary stenosis.<sup>15</sup>

“Ultrasound guidance also aids in femoral vein location, which can be variable in the posterolateral or posteromedial location in reference to the femoral artery.”

Long-term patency rates of ilio caval stents have been reported in many series.<sup>11,15,20-24</sup> In 2004, Neglen and Raju reported on their series of 324 iliac vein stents. In this large series, primary, primary-assisted, and secondary patency was 75%, 92%, and 93% at 3 years, respectively. Restenosis of ilio caval stents was a major cause of stent failure. At 3.5 years, > 75% had some degree of in-stent restenosis with the highest in patients with PTS.<sup>21</sup> The reported early rethrombosis rate (< 30 days) with ilio caval stenting is 11% to 15%, which is lowest in patients with chronic venous obstruction. Factors associated with early rethrombosis may include patients with thrombophilia, stent length, extension below the inguinal ligament, and complete occlusions. In their retrospective analysis, Knipp et al did find long stent length to be a significant risk factor for thrombosis in univariate analysis, as was thrombophilia ( $P < .10$ ); in multivari-



ate analysis, however, neither was independently associated with stent patency.<sup>24</sup> Inadequate stent dilation, inadequate inflow, and failure to stent entire diseased vein are the most common causes of stent thrombosis. Currently, there are no data comparing a single iliac vein stent to the use of multiple stents across the bifurcation of the iliac veins into the vena cava. In our experience, restenosis or stent thrombosis occurs commonly because of failure to stent across the lesion and into the vena cava adequately. In these cases, salvage can be achieved using standard PMT to open an acutely thrombosed stent followed by restenting across the lesion and into the vena cava (Figure 5).

Due to poor experience with placing stents across joints, extension of venous stents below the inguinal ligament has long been avoided. In their study, Neglen et al, however, found no effect on patency rate or stent fracture when stenting across the inguinal ligament with the braided stainless steel Wallstent.<sup>19</sup>

Posttreatment therapeutic anticoagulation is usually recommended in thrombotic patients to prevent recurrent thrombosis. Anticoagulation should be continued indefinitely in patients with underlying hypercoagulable states. The duration of anticoagulation recommended in other patients is not agreed upon but should be individualized for each patient.

## CONCLUSION

Recent advancements in the endovascular treatment of venous outflow obstruction have the potential for making a major impact on an underserved segment of our patients. Despite these advances, numerous questions remain. Only through the careful application of these techniques, close follow-up, and critical analyses of our results will these therapies improve. ■

*David Gillespie, MD, is the Program Director of Vascular Surgery, Integrated Residency and Fellowship, and a professor of vascular surgery at the University of Rochester, School of Medicine and Dentistry, in Rochester, New York. He has disclosed that he holds no interest in any product or manufacturer mentioned herein. Dr. Gillespie may be reached at (585) 275-6772; david\_gillespie@urmc.rochester.edu.*

*Marcia Johansson, RN, MS, is the Research Coordinator for the Division of Vascular Surgery at the University of Rochester, in Rochester, New York. She has disclosed that she holds no financial interest in any product or manufacturer mentioned herein.*

*Carolyn Glass, MD, is a third-year vascular surgery resident at the University of Rochester, School of Medicine and Dentistry, in Rochester, New York. She has disclosed that she holds no financial interest in any product or manufacturer mentioned herein.*

1. Raju S, Neglen P, Gagne P. High prevalence of nonthrombotic iliac vein lesions in chronic venous disease: a permissive role in pathogenicity. *J Vasc Surg.* 2006;44:136-143; discussion 144.
2. Kahn SR, Shbaklo H, Lamping DL, et al. Determinants of health-related quality of life during the 2 years following deep vein thrombosis. *J Thromb Haemost.* 2008;6:1105-1112.
3. Partsch H, M Kaulich, W Mayer. Immediate mobilisation in acute vein thrombosis reduces post-thrombotic syndrome. *Int Angiol.* 2004;23:206-212.
4. Prandoni P, Lensing A, Cogo A, et al. The long-term clinical course of acute deep venous thrombosis. *Ann Intern Med.* 1996;125:1-7.
5. Prandoni P, Lensing A, Prins M, et al. Below-knee elastic compression stockings to prevent the post-thrombotic syndrome: a randomized, controlled trial. *Ann Intern Med.* 2004;141:249-256.
6. Kahn SR. The post-thrombotic syndrome: the forgotten morbidity of deep venous thrombosis. *J Thromb Thrombolysis.* 2006;21:41-48.
7. AbuRahma AF, Perkins SE, Wulu JT, et al. Iliofemoral deep vein thrombosis: conventional therapy versus lysis and percutaneous transluminal angioplasty and stenting. *Ann Surg.* 2001;233:752-760.
8. Comerota AJ, Throm RC, Mathias SD, et al. Catheter-directed thrombolysis for iliofemoral deep venous thrombosis improves health-related quality of life. *J Vasc Surg.* 2000;32:130-137.
9. Elsharawy M, Elzayat E. Early results of thrombolysis vs anticoagulation in iliofemoral venous thrombosis. A randomised clinical trial. *Eur J Vasc Endovasc Surg.* 2002;24:209-214.
10. Meuwissen MW, Seabrook GR, Meissner MH, et al. Catheter-directed thrombolysis for lower extremity deep venous thrombosis: report of a national multicenter registry. *Radiology.* 1999;211:39-49.
11. Delis KT, Bjarnason H, Wennberg PW, et al. Successful iliac vein and inferior vena cava stenting ameliorates venous claudication and improves venous outflow, calf muscle pump function, and clinical status in post-thrombotic syndrome. *Ann Surg.* 2007;245:130-139.
12. Vedantham S, Thorpe PE, Cardella JF, et al. Quality improvement guidelines for the treatment of lower extremity deep vein thrombosis with use of endovascular thrombus removal. *J Vasc Interv Radiol.* 2006;17:435-447; quiz 448.
13. Vedantham S, Millward SF, Cardella FJ, et al. Society of Interventional Radiology position statement: treatment of acute iliofemoral deep vein thrombosis with use of adjunctive catheter-directed intrathrombus thrombolysis. *J Vasc Interv Radiol.* 2006;17:613-616.
14. Vedantham S, Grassi CJ, Ferral H, et al. Reporting standards for endovascular treatment of lower extremity deep vein thrombosis. *J Vasc Interv Radiol.* 2006;17:417-434.
15. Raju S, Hollis K, Neglen P. Obstructive lesions of the inferior vena cava: clinical features and endovenous treatment. *J Vasc Surg.* 2006;44:820-827.
16. Labropoulos N, Borge M, Pierce K, et al. Criteria for defining significant central vein stenosis with duplex ultrasound. *J Vasc Surg.* 2007;46:101-107.
17. Neglen P, Raju S. Proximal lower extremity chronic venous outflow obstruction: recognition and treatment. *Semin Vasc Surg.* 2002;15:57-64.
18. Neglen P, Thrasher TL, Raju S. Venous outflow obstruction: An underestimated contributor to chronic venous disease. *J Vasc Surg.* 2003;38:879-885.
19. Neglen P, Tackett TP Jr, Raju S. Venous stenting across the inguinal ligament. *J Vasc Surg.* 2008;48:1255-1261.
20. Neglen P, Hollis KC, Olivier J, et al. Stenting of the venous outflow in chronic venous disease: long-term stent-related outcome, clinical, and hemodynamic result. *J Vasc Surg.* 2007;46:979-990.
21. Neglen P, Raju S. In-stent recurrent stenosis in stents placed in the lower extremity venous outflow tract. *J Vasc Surg.* 2004;39:181-187.
22. Vedantham S, Vesely TM, Parti N, et al. Endovascular recanalization of the thrombosed filter-bearing inferior vena cava. *J Vasc Interv Radiol.* 2003;14:893-903.
23. Husmann MJ, Heller G, Kalka C, et al. Stenting of common iliac vein obstructions combined with regional thrombolysis and thrombectomy in acute deep vein thrombosis. *Eur J Vasc Endovasc Surg.* 2007;34:87-91.
24. Knipp BS, Furguson E, Williams D, et al. Factors associated with outcome after interventional treatment of symptomatic iliac vein compression syndrome. *J Vasc Surg.* 2007;46:743-749.

## SHARE YOUR FEEDBACK

Would you like to comment on an author's article? Do you have an article topic to suggest? We are interested in your feedback. Please e-mail us at [evteditorial@bmctoday.com](mailto:evteditorial@bmctoday.com) with any thoughts or questions you have regarding this publication.